



Radiographic Evaluation of Postoperative Alignment in Total Knee Arthroplasty*

Avaliação radiográfica do alinhamento pós-operatório na artroplastia total de joelho

Leonardo Dalla Giacomassa Rocha Thomaz¹ João Guilherme Brochado Geist²
 Rafael De Luca De Lucena³ Carlos Roberto Schwartzmann^{4,5} Geraldo Luiz Schuck de Freitas⁶
 Leandro de Freitas Spinelli^{7,8,9}

¹Orthopedics and Traumatology Service, Santa Casa de Misericórdia de Porto Alegre, Porto Alegre, RS, Brazil

²Orthopedics and Traumatology Service, Regina Hospital, Novo Hamburgo, Porto Alegre, RS, Brazil

³Orthopedics and Traumatology Service, Santa Casa de Misericórdia de Porto Alegre, Porto Alegre, RS, Brazil

⁴Department of Orthopedics and Traumatology, Universidade Federal de Ciências da Saúde de Porto Alegre, Porto Alegre, RS, Brazil

⁵Orthopedics and Traumatology Service, Complexo Hospitalar Santa Casa de Misericórdia de Porto Alegre, Porto Alegre, RS, Brazil

⁶Knee Group, Santa Casa de Misericórdia de Porto Alegre, Porto Alegre, RS, Brazil

⁷Faculty of Medicine, Universidade Federal de Ciências da Saúde de Porto Alegre, Porto Alegre, RS, Brazil

Address for correspondence Leonardo Dalla Giacomassa Rocha Thomaz, MD, Serviço de Ortopedia e Traumatologia, Santa Casa de Misericórdia de Porto Alegre, Rua Professor Annes Dias, 135 /2o andar, Centro Histórico, Porto Alegre, RS, 90460-150, Brazil (e-mail: leorochat@hotmail.com).

⁸Hip Surgery Group, Orthopedics and Traumatology Service, Complexo Hospitalar Santa Casa de Misericórdia de Porto Alegre, Porto Alegre, RS, Brazil

⁹Laboratory of Bioengineering, Biomechanical and Biomaterials, Graduate Program in Design and Manufacturing Processes, University of Passo Fundo, RS, Brazil

Rev Bras Ortop 2022;57(4):656–660.

Abstract

Objective To demonstrate the greater accuracy of panoramic radiographs of the lower limbs (long) in relation to short radiographs of the knee in the measurement of the mechanical axis of the lower limb after total knee arthroplasty (TKA).

Methods A retrospective study was conducted to evaluate the accuracy of long and short postoperative radiographic images of 70 patients submitted to TKA in our service. The images were analyzed at random, at different times, by three orthopedists. In all images, the mechanical axis of the limb, femur and tibia were traced and femorotibial angles (FTAs) were calculated. The intraclass correlation coefficient (ICC) was calculated to evaluate the agreement of the measurement of the inter- and intra-observer mechanical axis.

Keywords

- ▶ arthroplasty, replacement, knee
- ▶ knee joint
- ▶ radiography

* Work developed at the Orthopedics and Traumatology Service of Santa Casa de Misericórdia de Porto Alegre and Universidade Federal de Ciências da Saúde de Porto Alegre, Rio Grande do Sul, Brazil.

received
August 15, 2020
accepted
October 28, 2020
published online
April 19, 2021

DOI <https://doi.org/10.1055/s-0041-1726061>.
ISSN 0102-3616.

© 2021. Sociedade Brasileira de Ortopedia e Traumatologia. All rights reserved.

This is an open access article published by Thieme under the terms of the Creative Commons Attribution-NonDerivative-NonCommercial-License, permitting copying and reproduction so long as the original work is given appropriate credit. Contents may not be used for commercial purposes, or adapted, remixed, transformed or built upon. (<https://creativecommons.org/licenses/by-nc-nd/4.0/>)

Thieme Revinter Publicações Ltda., Rua do Matoso 170, Rio de Janeiro, RJ, CEP 20270-135, Brazil

Results It was observed that there was high intra and interobserver agreement when panoramic radiographs were used, with minimum intra and interobserver ICC of 0.89, equivalent to a very strong agreement. On short radiographs in the anteroposterior incidence (AP) of the knee, the ICC showed moderate agreement, obtaining a maximum value of 0.75.

Conclusion There is a significant difference in accuracy for the measurement of the mechanical axis of the lower limb, comparing long and short radiographs of the lower limb. Thus, for the proper measurement of the mechanical axis of the lower limb, we suggest the performance of long radiography in the postoperative period of TKA.

Resumo

Objetivo Demonstrar a maior acurácia das radiografias panorâmicas de membros inferiores (longa) em relação às radiografias curtas do joelho na medida do eixo mecânico do membro inferior após a artroplastia total de joelho (ATJ).

Métodos Foi realizado um estudo retrospectivo para avaliar a acurácia de imagens radiográficas longas e curtas pós-operatórias de 70 pacientes submetidos à ATJ em nosso serviço. As imagens foram analisadas ao acaso, em momentos distintos, por três ortopedistas. Em todas as imagens, o eixo mecânico do membro, do fêmur e da tíbia foram traçados e os ângulos femorotibiais (AFTs) foram calculados. O coeficiente de correlação intraclassa (CCI) foi calculado para avaliar a concordância da medida do eixo mecânico inter e intraobservador.

Resultados Observou-se que existe alta concordância intra e interobservador quando foi utilizado as radiografias panorâmicas, apresentando CCI mínimo intra e interobservador de 0,89, equivalente a uma concordância fortíssima. Já nas radiografias curtas na incidência anteroposterior (AP) do joelho, o CCI mostrou-se com concordância moderada, obtendo valor máximo de 0,75.

Conclusão Existe uma diferença significativa na acurácia para a medida do eixo mecânico do membro inferior, comparando-se radiografias longas e curtas do membro inferior. Assim, para a adequada mensuração do eixo mecânico do membro inferior, sugerimos a realização de radiografia longa no pós-operatório de ATJ.

Palavras-chave

- ▶ artroplastia do joelho
- ▶ articulação do joelho
- ▶ radiografia

Introduction

Total knee arthroplasty is a type of surgery widely performed worldwide, with high success rates. It is estimated that in the USA there will be an increase of 673% (approximately 3.48 million) in the surgical demand for this procedure in the period from 2005 to 2030.¹ The surgical postoperative evaluation requires a few steps in its care. In addition to the control of the surgical wound, measures of range of motion and evaluation of pain scales, the postoperative evaluation of the radiographic alignment of the mechanical and anatomical axes is also a fundamental part for the success of the procedure.¹⁻³

Panoramic radiography of the lower limbs has been shown to be essential in preoperative planning. In addition to the radiological measurement of the axes, possible femoral and tibial deformities can be identified that may hinder the surgical procedure.⁴ Short radiographs in anteroposterior incidence (AP) and profile with monopodal support, in addition to the incidence of Rosenberg, are great for staging and classification of degenerative pathology.

In postoperative evaluations, it is extremely common to find only short radiographs of the knee, making it impossible

to establish a comparison with preoperative alignment and to identify those implants that may be at risk of premature failure.⁵ Many authors justify the non-performance of long radiographs because they increase costs to the health system, besides the fact that this type of test is not available in all imaging centers.

Studies in the literature differ in relation to the level of inter and intraobserver agreement on the mechanical and anatomical alignment of the lower limb using long and short radiographs of the knee.^{6,7} The aim of the present study is to compare the intra and interobserver accuracy of the evaluation of the mechanical axis between panoramic radiographs of the lower limbs and knee radiographs in the postoperative period of patients submitted to TKAs performed at our service.

Materials and Methods

The present study was submitted and approved by the Research Ethics Committee of our institution under the number CAAE 33420820.5.0000.5535. The postoperative radiographs of 70 patients submitted to TKA were

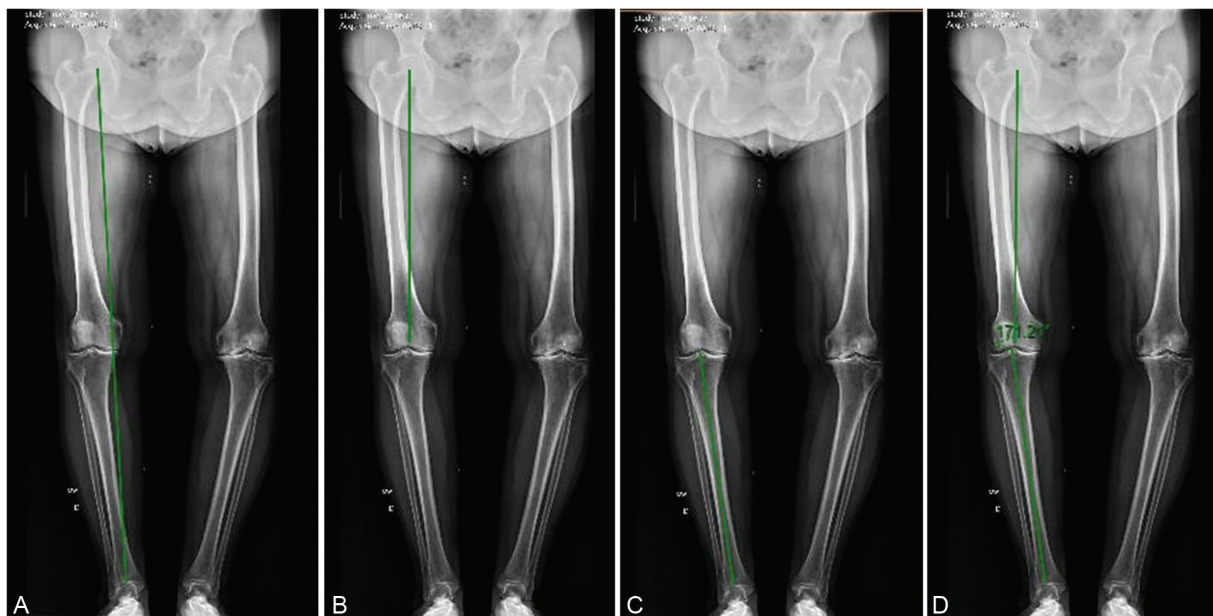


Fig. 1 Panoramic radiographs presenting: (A) mechanical axis of the limb; (B) mechanical axis of the femur; (C) mechanical axis of the tibia; (D) femorotibial angle-FTA.

retrospectively analyzed. The inclusion criteria included patients presenting primary gonarthrosis as the cause of surgery and classified, according to the Ahlback classification,⁸ between stages 3 and 5. The exclusion criteria were low-quality radiological images and long-ilinear patients, whose panoramic radiographs did not include hip, knee and ankle joints in the same image.

All 70 patients underwent long radiographs in bipodal support when they were still staying in our hospital during the postoperative period of TKA. The radiographs were digitized and observed through the PixvieweR imaging program (PixvieweR Web Solutions, The Bronx, NY, USA). The short radiographs of the knee were made from the long radiographs, using the joint line as reference and cutting the image 10 centimeters above and 10 centimeters below it, according to a previous study by Ishii et al.⁹ Thus, we avoided the influence of possible rotations from the performance of a new radiography.

The radiographs were performed at the imaging diagnostic center of our institution. The 140 images were randomly analyzed, at different times, by three generalist orthopedists. All images were reevaluated by the same orthopedists in a period of 15 days. On all radiographs, the mechanical axis of the limb, femur and tibia were traced and the femorotibial angles calculated (► **Figure 1**).

The mechanical axis of the limb was traced by a line that passes through the center of the femoral head to the center of the ankle (► **Figure 1A**). The mechanical axis of the femur was defined as the line that joins the center of the femoral head to the apex of the femoral intercondyle (► **Figure 1B**). The mechanical axis of the tibia was defined as a line between the center of the tibial plateau and the center of the talus (► **Figure 1C**). The measurement of the femorotibial angle (FTA) was performed from the mechanical axes of the femur and tibia (► **Figure 1D**). In the short radiography of the knee,

as it is not possible to visualize the image of the hip and ankle, an image was traced inferring the location of these points to trace the mechanical axis (► **Figure 2**).

The statistical analysis was performed using the SPSS Statistics for Windows, Version 13.0 software (SPSS Inc., Chicago, IL, USA). The intraclass correlation coefficient (ICC) was calculated to evaluate the agreement of the measurement of the inter and intraobserver mechanical axis. It is known that the closer the ICC is to 1, the stronger the agreement among the observers. On the contrary, the closer to 0 (zero), the weaker the agreement becomes.

Results

A mean femorotibial angle of 2.5 degrees was observed on short radiographs, while on panoramic radiographs we observed a value of 1.8 degrees. Considering each examiner alone, the measurement of the mechanical axis varied 8 degrees at most between the long and short radiographs (► **Figure 3**). After the statistical analysis, it was observed that there was high intra and interobserver agreement when panoramic radiographs were used, presenting minimum intraobserver ICC of 0.89 and interobserver of 0.92, equivalent to a very strong agreement. On short radiographs of the knee in AP incidence, the minimum intraobserver ICC was 0.70 and maximum of 0.75, evidencing a moderate–good agreement. The interobserver ICC showed a value of 0.80, which is considered good (► **Table 1**).

Discussion

The present study compared the intra and interobserver accuracy of the evaluation of the mechanical axis between panoramic radiographs of the lower limbs and knee radiographs in the postoperative period of patients submitted to

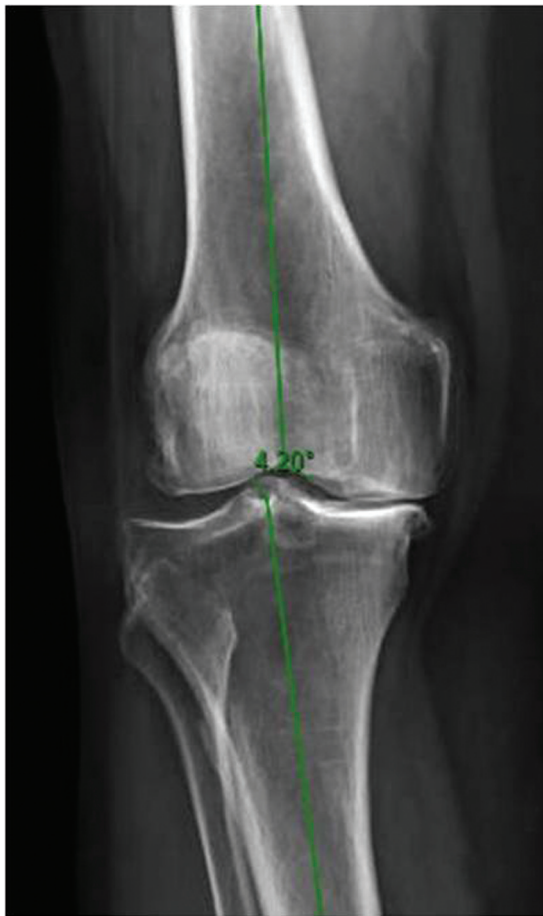

Fig. 2 Preoperative femorotibial mechanical axis on short radiography.

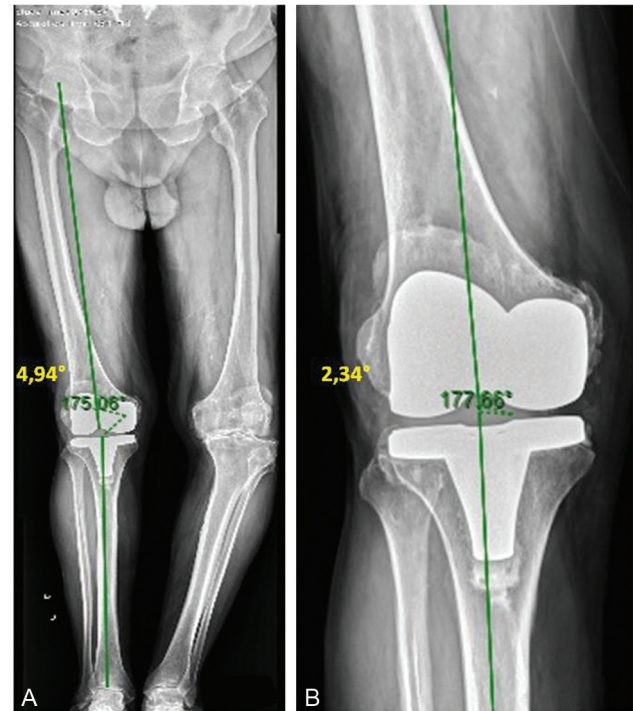


Fig. 3 Comparison of femorotibial angle on long (A) and short (B) postoperative radiographs.

Table 1 Values obtained for intra and interobserver agreement

		ICC (intraclass correlation coefficient)
Intraobserver		Mechanical
1	Long Short	0.90 0.73
2	Long Short	0.89 0.75
3	Long Short	0.92 0.70
Interobserver	Long Short	0.92 0.80

Observations: $ICC \leq 0.20$ - no agreement; $0.20 < ICC \leq 0.40$ - weak agreement; $0.40 < ICC \leq 0.60$ - moderate agreement; $0.60 < ICC \leq 0.80$ - strong agreement (good); $ICC > 0.80$ - very strong agreement (optimal). 95% confidence interval for ICC; $p < 0.001$.

TKAs performed in our service. Panoramic radiographs of the lower limbs are classically used when one wants to analyze mechanical and anatomical axes accurately.¹⁰⁻¹² However, it is known that such radiographic images increase the actual cost to the institution, add unnecessary radiation to pelvic organs, and require special rooms and equipment for their

performance.² Due to these limitations, several studies have proposed alternative ways to long radiographs to make a reliable mechanical axis.⁹

One of the pioneering studies in the evaluation of the mechanical axis was that of Abu-Rajab et al.⁵ The group evaluated 50 consecutive radiographs of patients in the postoperative period of TKA and compared the ICC of panoramic radiographs and standardized radiographs of the knee. The interobserver ICC of lower limbs radiography was 0.95, compared to 0.51 when only knee radiographs were evaluated. Dargel et al.¹³ obtained results similar to those of the present study but compared the ICC of panoramic radiographs and radiographs cut in 80%, 60% and 40% of the total length of the lower limb. An ICC of 0.95 was found when analyzing the mechanical axis with panoramic imaging, compared with 0.89 radiography at 80%, 0.76 radiography at 60% and 0.61 radiography cut at 40% of the limb. These data strongly suggest that the axis evaluation becomes more accurate as larger segments of the lower limbs are shown on radiography. The group concluded that knee radiography is insufficient to evaluate the mechanical axis, suggesting routine panoramic examination in the postoperative period of TKA.

The present study found results similar to those described in the international literature. Our results showed a very strong intra and interobserver agreement of the measurements of the axes in panoramic radiographs, which is in accordance with the studies previously described.^{5,13} In addition, we demonstrated that short radiographs were lower in the ability to accurately assess the coronal alignment of the lower limb, since they showed only a moderate intra and interobserver level.

One of the criticisms in relation to alignment evaluation studies is that it is performed in only one plane, but arthroplasties are part of a three-dimensional procedure. Chauhan et al.¹⁴ used tomographic evaluation in 12 operated knees of 6 cadavers using the Perth Protocol. Six positional parameters of the components were found, which, individually or summed, may interfere with the clinical results of the patients. They are the positions of the femoral and tibial components in flexion or extension, in varus or valgus, in external or internal rotation and, finally, the poor selection of the components' sizes. Despite the numerous information that computed tomography can provide, it is important to highlight that it is not routinely used in the postoperative period, because, in addition to not being an easily accessible examination in our country due to its high cost, it still significantly increases the radiation to which the patient is submitted.

Among the positive aspects of the present study, it is worth mentioning that it is the first national study evaluating the mechanical alignment in the postoperative period of TKAs. Furthermore, our results are in agreement with those published in the international literature and with a similar sample. Among its limitations, we highlight that the evaluation of postoperative alignment was performed only in the coronal plane, while we know that a good functioning of TKA needs balance and good positioning in the three planes. In addition, other significant indicators of clinical results, such as evaluation of pain scores in the pre and postoperative periods and evaluation of complications were not measured.

Conclusion

Panoramic radiographs of the knee are more accurate to evaluate the mechanical axis of the limb in the postoperative period of patients undergoing TKA. Following the previously conducted international studies, we suggest the inclusion of panoramic radiography in the postoperative routine of this procedure.

Financial Support

There was no financial support from public, commercial, or non-profit sources.

Conflict of Interests

The authors declare that there is no conflict of interests.

References

- 1 Fernandes DA, Poeta LS, Martins CAQ, Lima F, Rosa Neto F. Equilíbrio e qualidade de vida após artroplastia total de joelho. *Rev Bras Ortop* 2018;53(06):747-753
- 2 Carvalho Júnior LH, Castro CAC, Gonçalves MJB, Rodrigues LCM, Lopes FL, Cunha FVP. Complicações de curto prazo da artroplastia total de joelho: avaliação de 120 casos. *Rev Bras Ortop* 2006;41(05):162-166
- 3 Fang DM, Ritter MA, Davis KE. Coronal alignment in total knee arthroplasty: just how important is it? *J Arthroplasty* 2009;24(6, Suppl):39-43
- 4 Lotke PA, Ecker ML. Influence of positioning of prosthesis in total knee replacement. *J Bone Joint Surg Am* 1977;59(01):77-79
- 5 Abu-Rajab RB, Deakin AH, Kandasami M, McGlynn J, Picard F, Kinninmonth AW. Hip-Knee-Ankle Radiographs Are More Appropriate for Assessment of Post-Operative Mechanical Alignment of Total Knee Arthroplasties than Standard AP Knee Radiographs. *J Arthroplasty* 2015;30(04):695-700
- 6 Felson DT, Cooke TD, Niu J, et al; OAI Investigators Group. Can anatomic alignment measured from a knee radiograph substitute for mechanical alignment from full limb films? *Osteoarthritis Cartilage* 2009;17(11):1448-1452
- 7 Sheehy L, Felson D, Zhang Y, et al. Does measurement of the anatomic axis consistently predict hip-knee-ankle angle (HKA) for knee alignment studies in osteoarthritis? Analysis of long limb radiographs from the multicenter osteoarthritis (MOST) study. *Osteoarthritis Cartilage* 2011;19(01):58-64
- 8 Alhåck S. Osteoarthritis of the knee. A radiographic investigation. *Acta Radiol Diagn (Stockh)* 1968(Suppl 277):7-72
- 9 Ishii Y, Ohmori G, Bechtold JE, Sherman RE, Gustilo RB. Accuracy of the short radiograph in the measurement of the tibiofemoral angle. *Knee* 1995;2(02):81-84
- 10 Maquet PG. Biomechanics of the knee. New York: Springer-Verlag; 1976
- 11 Moreland JR, Bassett LW, Hunker GJ. Radiographic analysis of the axial alignment of the lower extremity. *J Bone Joint Surg Am* 1987;69(05):745-749
- 12 Sharma L, Song J, Felson DT, Cahue S, Shamiyeh E, Dunlop DD. The role of knee alignment in disease progression and functional decline in knee osteoarthritis. *JAMA* 2001;286(02):188-195
- 13 Dargel J, Pennig L, Schnurr C, Boese CK, Eysel P, Oppermann J. [Should we use hip-ankle radiographs to assess the coronal alignment after total knee arthroplasty?] *Orthopade* 2016;45(07):591-596
- 14 Chauhan SK, Clark GW, Lloyd S, Scott RG, Bredahl W, Sikorski JM. Computer-assisted total knee replacement. A controlled cadaver study using a multi-parameter quantitative CT assessment of alignment (the Perth CT Protocol). *J Bone Joint Surg Br* 2004;86(06):818-823