



Endoscopic Transnasal Resection of Trigeminal Schwannoma

Satoshi Kiyofuji¹ Masahiro Shin¹ Kenji Kondo² Taichi Kin¹ Tatsuya Uchida¹ Nobuhito Saito¹

¹Department of Neurosurgery, The University of Tokyo, Tokyo, Japan

²Department of Otolaryngology and Head and Neck Surgery, The University of Tokyo, Tokyo, Japan

Address for correspondence Masahiro Shin, MD, PhD, Department of Neurosurgery, The University of Tokyo, 7-3-1 Hongo, Bunkyo-ku, Tokyo 113-8655, Japan (e-mail: shin-nsu@h.u-tokyo.ac.jp).

J Neurol Surg B Skull Base 2022;83(suppl S3):e637–e638.

Abstract

Trigeminal schwannoma is a rare skull base tumor that can be managed in a variety of treatments including image observation, surgery, stereotactic radiosurgery, such as gamma knife radiosurgery (GKS), and combination of these. Endoscopic transnasal resection is very effective when the tumor is not invading far laterally, or the risk of cerebrospinal fluid (CSF) leak is estimated to be low. A 74-year-old man with a history of prostate cancer and diabetes presented with left oculomotor nerve palsy over a month. Magnetic resonance images (MRI) demonstrated a 25-mm mass in the left cavernous sinus protruding to the left orbit via the superior orbital fissure (►Fig. 1). The patient underwent endoscopic transnasal surgery to decompress the mass. The surgery was uneventful, and postoperative MRI demonstrated satisfactory subtotal resection of the mass (►Fig. 2). The final pathology returned as schwannoma. At 1-year follow-up, the tumor slowly enlarged, and the patient underwent GKS with a marginal dose of 14 Gy. At the last follow-up, 4 months after GKS, the tumor was stable. Unfortunately the patient deceased from the known prostate cancer. Endoscopic transnasal surgery was especially useful in this case, considering the preoperative known cancer state that management of this benign tumor did not ruin the quality of life of this patient while minimizing hospitalization, as achieving satisfactory tumor control with aid from postoperative GKS, minimizing complications.

The link to the video can be found at: <https://youtu.be/Q0Ugc2VFV4w>.

Keywords

- endoscopic transnasal surgery
- gamma knife radiosurgery
- transsphenoid surgery
- trigeminal schwannoma



www.thieme.com/skullbasevideos

www.thieme.com/jnlsbvideos

received
September 15, 2020
accepted after revision
December 1, 2020
published online
May 3, 2021

DOI <https://doi.org/10.1055/s-0041-1727122>.
ISSN 2193-6331.

© 2021. The Author(s).

This is an open access article published by Thieme under the terms of the Creative Commons Attribution-NonDerivative-NonCommercial-License, permitting copying and reproduction so long as the original work is given appropriate credit. Contents may not be used for commercial purposes, or adapted, remixed, transformed or built upon. (<https://creativecommons.org/licenses/by-nc-nd/4.0/>)

Georg Thieme Verlag KG, Rüdigerstraße 14, 70469 Stuttgart, Germany

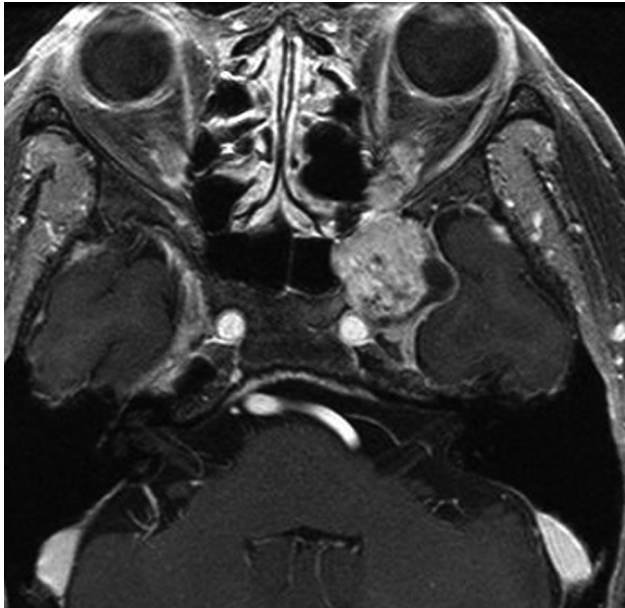


Fig. 1 Preoperative magnetic resonance imaging (MRI) in T1-weighted image with contrast enhancement demonstrated a 25-mm mass in the left cavernous sinus protruding to the left orbit via the superior orbital fissure.

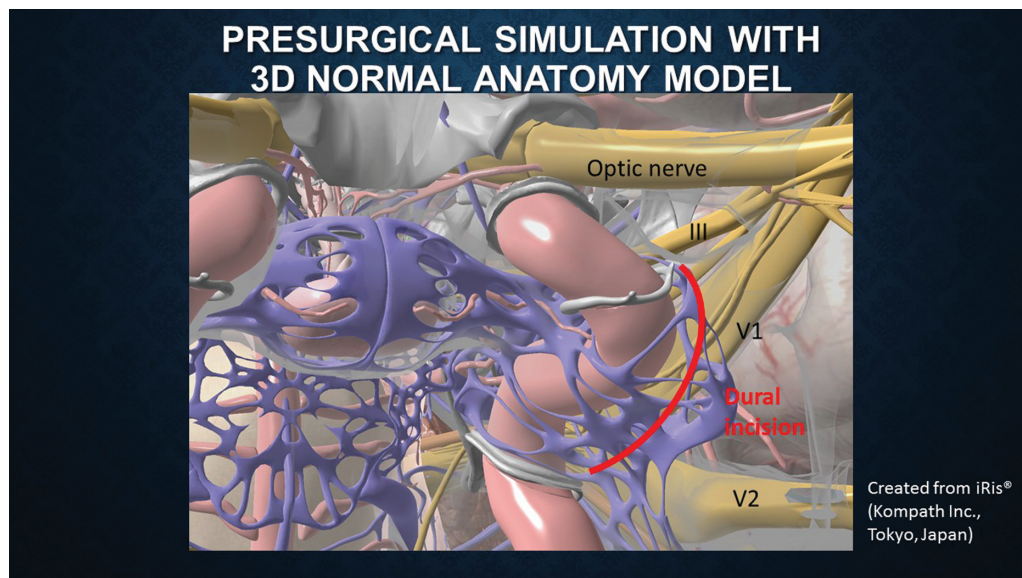


Fig. 2 Presurgical simulation illustration constructed from a three-dimensional computer graphics (3DCG) atlas. Red line demonstrates the dural incision. *Image courtesy: iRis (Kompath Inc., Tokyo, Japan).*

Conflict of Interest
None declared.