




# Kagami-Ogata Syndrome: Case Series and Review of Literature

Rishika P. Sakaria, MBBS<sup>1</sup>  Roya Mostafavi, MS, CGC<sup>2</sup> Stephen Miller, MD, FRCPC<sup>3,4</sup>  
Jewell C. Ward, MD, PhD<sup>4</sup> Eniko K. Pivnick, MD<sup>4,5</sup> Ajay J. Talati, MD<sup>6</sup>

<sup>1</sup> Department of Pediatrics, Division of Neonatal-Perinatal Medicine, University of Tennessee Health Science Center, Memphis, Tennessee

<sup>2</sup> Department of Oncology, Division of Cancer Predisposition, St. Jude Children's Research Hospital, Memphis, Tennessee

<sup>3</sup> Department of Radiology, Le Bonheur Children's Hospital, University of Tennessee Health Science Center, Memphis, Tennessee

<sup>4</sup> Department of Pediatrics, Division of Medical Genetics, University of Tennessee Health Sciences Center, Memphis, Tennessee

<sup>5</sup> Department of Ophthalmology, University of Tennessee Health Sciences Center, Memphis, Tennessee

<sup>6</sup> Department of Pediatrics, Division of Neonatal-Perinatal Medicine, University of Tennessee Health Science Center, Memphis, Tennessee

**Address for correspondence** Rishika Sakaria, MBBS, Neonatal and Perinatal Medicine, 853 Jefferson Avenue, Suite 201, Memphis, TN 38103 (e-mail: rsakaria@uthsc.edu; rishika.sakaria@gmail.com).

Am J Perinatol Rep 2021;11:e65–e75.

## Abstract

Kagami-Ogata syndrome (KOS) (OMIM #608149) is a genetic imprinting disorder affecting chromosome 14 that results in a characteristic phenotype consisting of typical facial features, skeletal abnormalities including rib abnormalities described as “coat hanger ribs,” respiratory distress, abdominal wall defects, polyhydramnios, and developmental delay. First identified by Wang et al in 1991, over 80 cases of KOS have been reported in the literature. KOS, however, continues to remain a rare and potentially underdiagnosed disorder. In this report, we describe two unrelated male infants with differing initial presentations who were both found to have the characteristic “coat hanger” rib appearance on chest X-ray, raising suspicion for KOS. Molecular testing confirmed KOS in each case. In addition to these new cases, we reviewed the existing cases reported in literature. Presence of polyhydramnios, small thorax, curved ribs, and abdominal wall defects must alert the perinatologist toward the possibility of KOS to facilitate appropriate molecular testing. The overall prognosis of KOS remains poor. Early diagnosis allows for counseling by a multidisciplinary team and enables parents to make informed decisions regarding both pregnancy management and postnatal care.

## Keywords

- ▶ paternal UPD(14)
- ▶ coat-hanger ribs
- ▶ 14q32.2
- ▶ omphalocele

Wang et al first described paternal uniparental disomy of chromosome 14 (UPD(14)pat) in a 9-year-old girl.<sup>1</sup> In 2008, Kagami et al showed that microdeletions and epimutations affecting the maternally inherited 14q32.2 locus result in

UPD(14) pat-like phenotype.<sup>2</sup> Recently, the European Network of Imprinting Disorders designated the term “Kagami-Ogata” (KOS) (OMIM #608149) to encompass UPD(14)pat and related methylation and epigenetic imprinting

received  
December 28, 2020  
accepted after revision  
February 8, 2021

DOI <https://doi.org/10.1055/s-0041-1727287>.  
ISSN 2157-6998.

© 2021. The Author(s).

This is an open access article published by Thieme under the terms of the Creative Commons Attribution-NonDerivative-NonCommercial-License, permitting copying and reproduction so long as the original work is given appropriate credit. Contents may not be used for commercial purposes, or adapted, remixed, transformed or built upon. (<https://creativecommons.org/licenses/by-nc-nd/4.0/>)

Thieme Medical Publishers, Inc., 333 Seventh Avenue, 18th Floor, New York, NY 10001, USA

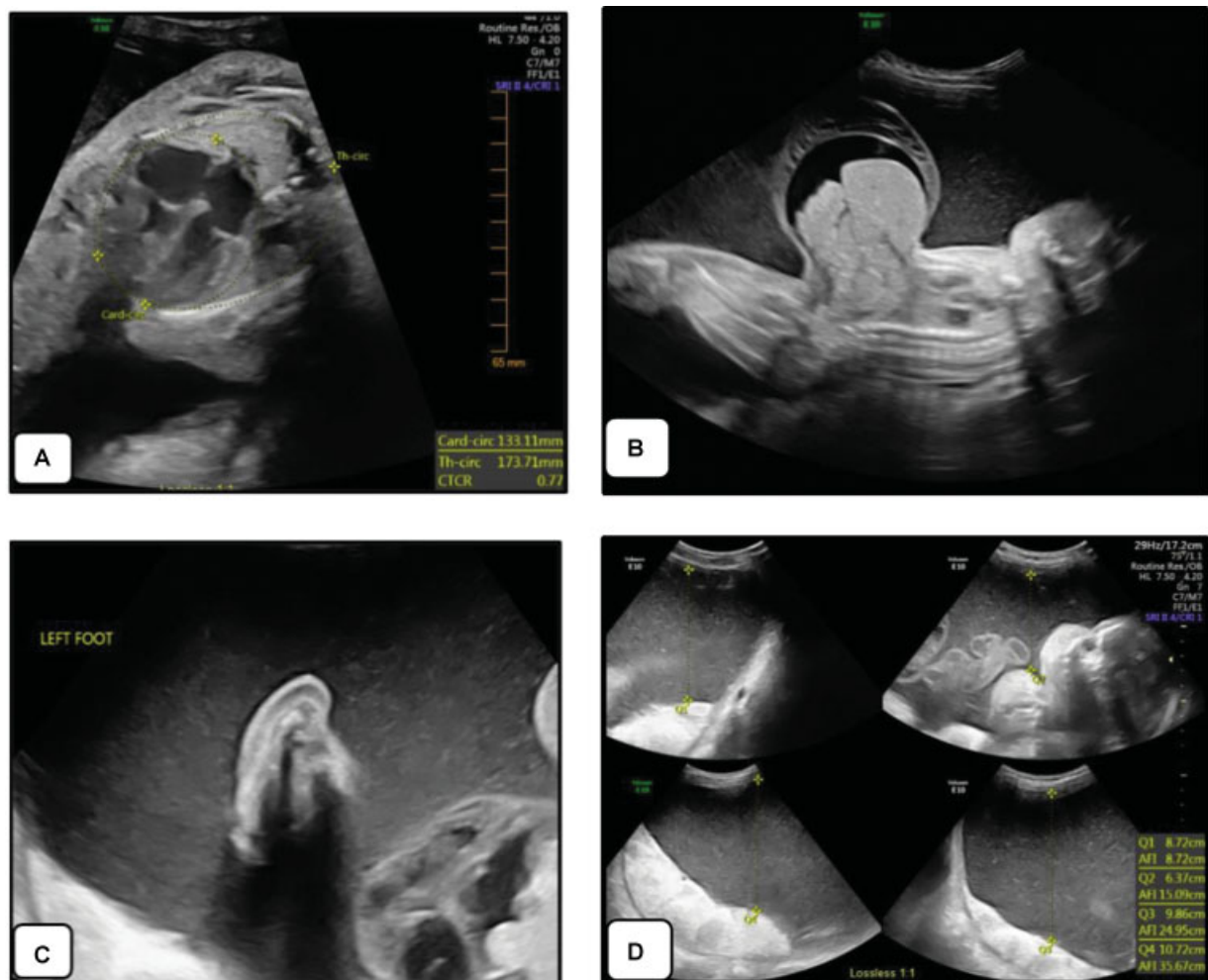
disorders.<sup>3</sup> With a reported prevalence of <1 in 1,000,000, KOS is a rare imprinting disorder of 14q32.2, which results in a classical phenotype.<sup>4,5</sup> To date over 80 cases of KOS have been reported in the literature. Here we describe two new cases, a male infant born at 28<sup>6/7</sup> weeks with a large omphalocele and a second male infant born at 37<sup>1/7</sup> weeks of gestation with large diastasis recti, who were both subsequently diagnosed with KOS. We also reviewed 75 previously reported cases. We aim to review this rare and possibly underdiagnosed genetic condition to raise awareness of this condition among perinatologists, who will then be able to counsel parents regarding management options and promote informed decision making.

### Case 1

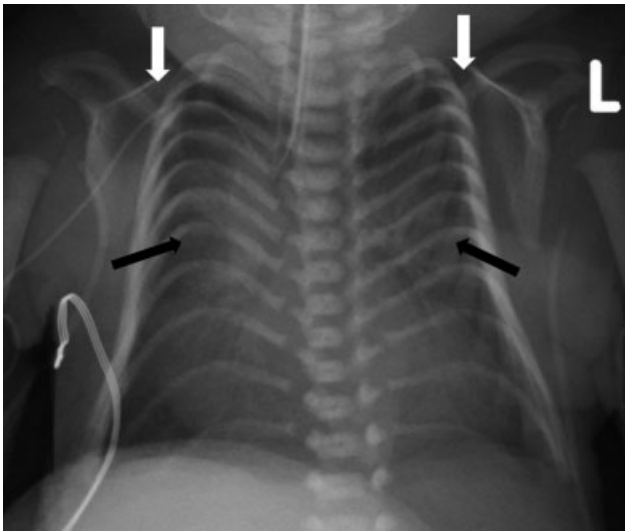
A male infant was born at 28<sup>6/7</sup> weeks of gestation via C-section to a 21-year-old gravida 1 now para 1 female. Pregnancy was complicated by the presence of a large omphalocele, overlapping digits, rocker bottom feet and polyhydramnios, detected at 22 weeks of gestation (→Fig. 1). Fetal echocardiogram was not performed. Patient's

mother declined prenatal genetic testing. Prenatal screening tests for infections were negative.

At birth, the infant was noted to have bradycardia with no respiratory effort, which improved with positive pressure ventilation. Apgar scores were 2, 4 and 6 at 1, 5 and 10 minutes, respectively. Physical exam was significant for anasarca, micrognathia, short neck, small dysplastic, low-set, posteriorly rotated ears, ocular hypertelorism, depressed nasal bridge, narrow bell-shaped chest, clenched hands, rocker bottom feet and large omphalocele containing part of the liver and the bladder. Chest X-ray showed narrow abnormally shaped ribs, "handlebar" clavicles and pronounced hypoplasia of the scapular necks (→Fig. 2). The infant was placed on high frequency oscillatory ventilator within hours of birth due to severe respiratory acidosis and high oxygen requirement and was given surfactant. Echocardiogram on admission showed severe pulmonary hypertension, a small ventricular septal defect and a patent ductus arteriosus. Head ultrasound was significant for mild ventriculomegaly. Upper gastrointestinal contrast study for feeding intolerance showed midgut malrotation with failure of passage of barium beyond the duodenojejunal junction.



**Fig. 1** Prenatal ultrasound of case 1 at 27.1 weeks of gestation showing (A) thoracic circumference at lower limit of normal, (B) large omphalocele, (C) rocker-bottom left foot, and (D) polyhydramnios.



**Fig. 2** Chest radiograph of the patient 1 showing the classic “coat hanger” appearance of the ribs. Black arrows show the abnormally shaped thin ribs with cranial apex angulation. White arrows show “handlebar” clavicles.

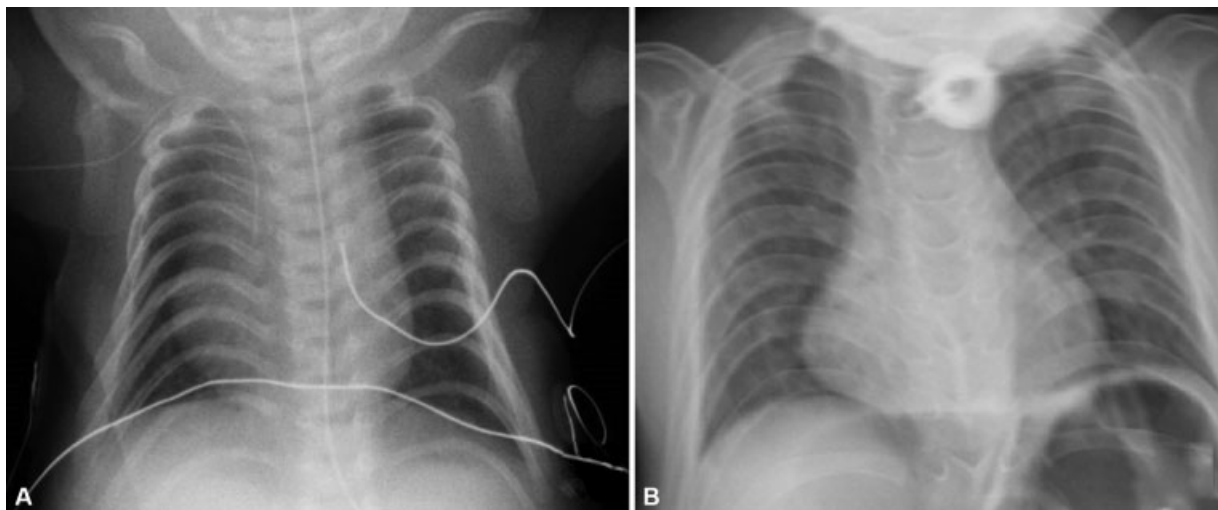
Surgical correction of the malrotation was not possible due to the presence of large omphalocele. The infant required mechanical ventilation with oxygen throughout his stay. Due to initial suspicion of trisomy 18, blood was sent for chromosomal analysis that resulted a normal male karyotype. Chromosomal microarray (CMA) (Integrated Genetics, Cypress, CA) showed a 71Kb duplication at 10q24.2 of uncertain significance. After further discussion with the consulting geneticist, methylation studies for Beckwith–Wiedemann syndrome (Mayo Clinic Laboratories, Rochester, MN) were requested, which were negative. Abnormal cranial apex angulation of the ribs, representing the “coat-hanger sign,” was later identified on chest radiograph (→**Fig. 2**) and the diagnosis of UPD(14)pat was suggested by the radiologist (SM). Subsequent methylation studies for UPD14 (EGL Genetics, Tucker, GA) showed absence of unmethylated

*MEG3* differentially methylated region (DMR). Only the methylated (paternal) copy of the *MEG3* DMR was detected, consistent with a diagnosis of KOS. Confirmatory testing by microsatellite analysis to determine whether this infant had UPD(14)pat or an epimutation was not possible.

Due to lack of improvement in the infant’s clinical status and the poor prognosis associated with KOS, after discussion with the patient’s mother, life-sustaining measures were discontinued at 2.5 months of life. The family declined autopsy.

## Case 2

A male was born at 37.1 week of gestation with birth weight of 3.09 kg. Pregnancy was complicated by polyhydramnios and suspected omphalocele. He was intubated in the delivery room due to absent respiratory effort and was admitted to the neonatal intensive care unit (NICU). Apgar scores were 3, 6, and 7 at 1, 5, and 10 minutes of life, respectively. Physical exam on admission was significant for large diastasis recti, flattened nasal bridge, narrow chest, short limbs, hypermobile fingers, prominent cheeks, cryptorchidism, and hypotonia. Echocardiogram was normal. He was extubated on day of life 2 and transitioned to room air on day of life 9. Initial chest X-ray (→**Fig. 3A**) with narrow bell-shaped thorax and “handlebar” clavicles was suggestive of Jeune syndrome. He was reintubated ~ 1 month of life for G-tube placement due to poor feeding. After multiple failed extubation attempts, tracheostomy tube was placed at ~2 months of life. Chest computed tomography was not consistent with classical Jeune syndrome. CMA (CombiMatrix, Irvine, CA) revealed a male profile with 2.6 Mb duplication on chromosome 12q14.1 of uncertain clinical significance. A skeletal dysplasia ciliopathy panel (Connective Tissue Gene Tests, Allentown, PA) detected heterozygous variants of unknown significance in *WDR35* (c.1624C > G; p.Leu542Val) and *IFT80* (c.880G > A; p.Val294Ile). *WDR35* deletion/duplication analysis via high-density targeted array (Connective Tissue Gene



**Fig. 3** Chest radiograph of patient 2 at (A) 9 days of life and at (B) 3 years of life. Although the coat-hanger appearance of ribs is apparent in both X-rays, the mid-widest (M/W) thorax ratio normalized from 73% at 9 days of life to 98% at 3 years of life. Also note the “handlebar” clavicles in both the X-rays.

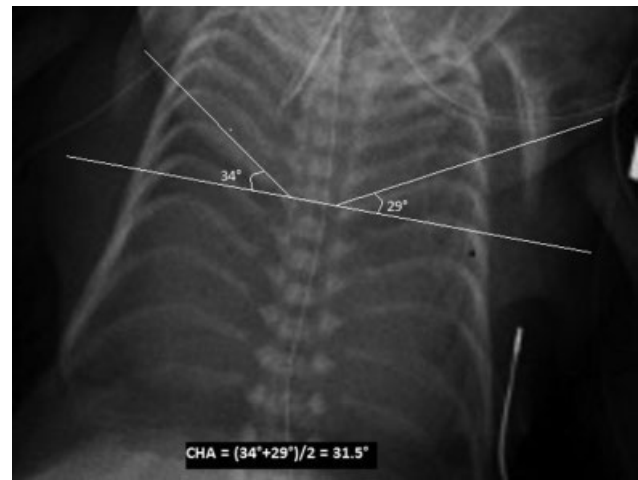Tests, Allentown, PA) was negative. He was discharged from the NICU at 7 months of life on a home ventilator and weaned off the ventilator ~ 16 months of life. He was readmitted multiple times due to respiratory distress associated with respiratory infections. After coat-hanger appearance of the ribs was noted on chest X-ray at the age of 28 months, molecular testing for KOS was initiated. Microsatellite analysis for UPD14 (The University of Chicago Genetic Services Laboratory, Chicago, IL) revealed biparental origin of chromosome 14. Methylation analysis for UPD14 (Emory Genetics Laboratory, Decatur, GA) requested a month later detected the paternally methylated *MEG3* gene with absence of maternal unmethylated *MEG3* DMR, consistent with the diagnosis of KOS. Alpha fetoprotein (AFP) level was 10.3 - ng/mL at 33 months of life (within normal limits), and abdominal ultrasound was negative for hepatoblastoma. The patient died at 39 months of age due to cardiac arrest following dislodgement of the tracheostomy tube.

## Methods

A systematic search was performed on PubMed using the key words: “Kagami Ogata Syndrome,” “Coat Hanger,” “UPD(14),” “UPD14,” and “Uniparental Disomy 14.” Only case reports/case studies/reviews involving original cases of KOS were considered. Forty-three articles were identified consisting of 77 patients. One report consisting of two patients was excluded as the publication was in German language and translation could not be obtained. Seventy-seven patients including the two new cases above were reviewed.

## Discussion

KOS is a rare imprinting disorder that can be caused by paternal UPD14 or microdeletions and epimutations involving the DMRs at 14q32.2.<sup>3</sup> Here, we describe two new cases of KOS, one in a premature male infant who was initially suspected to have trisomy 18 and the other in a term male suspected to have Jeune syndrome. Both infants had characteristic facial features, abdominal wall defects, and abnormal appearance of the ribs. In both patients, the diagnosis of KOS was suspected subsequent to the identification of the coat-hanger sign on chest X-ray. The coat-hanger sign (described below) is pathognomonic of KOS.<sup>6</sup> KOS is associated with an overall poor prognosis. Early diagnosis is key to the management of affected patients and allows for parental decision making. However, diagnosis may be complicated by the phenotypic overlap between KOS and other genetic conditions such as Jeune syndrome, Beckwith–Wiedemann syndrome, and trisomy 18. In the two cases above, diagnosis was delayed until recognition of the coat-hanger sign prompted evaluation for KOS. Perinatal providers caring for infants with multiple congenital anomalies should be aware of the classic features of KOS, as well as those features overlapping with more common genetic conditions, to promptly identify patients with KOS and initiate diagnostic work up in collaboration with radiology and genetics colleagues.



**Fig. 4** Coat-hanger angle (CHA): The average of angles between the peak point (or the center in absence of peak point) of both 6th posterior ribs and the horizontal axis. CHA > 25° must raise suspicion for Kagami-Ogata syndrome (KOS).

## Clinical Features

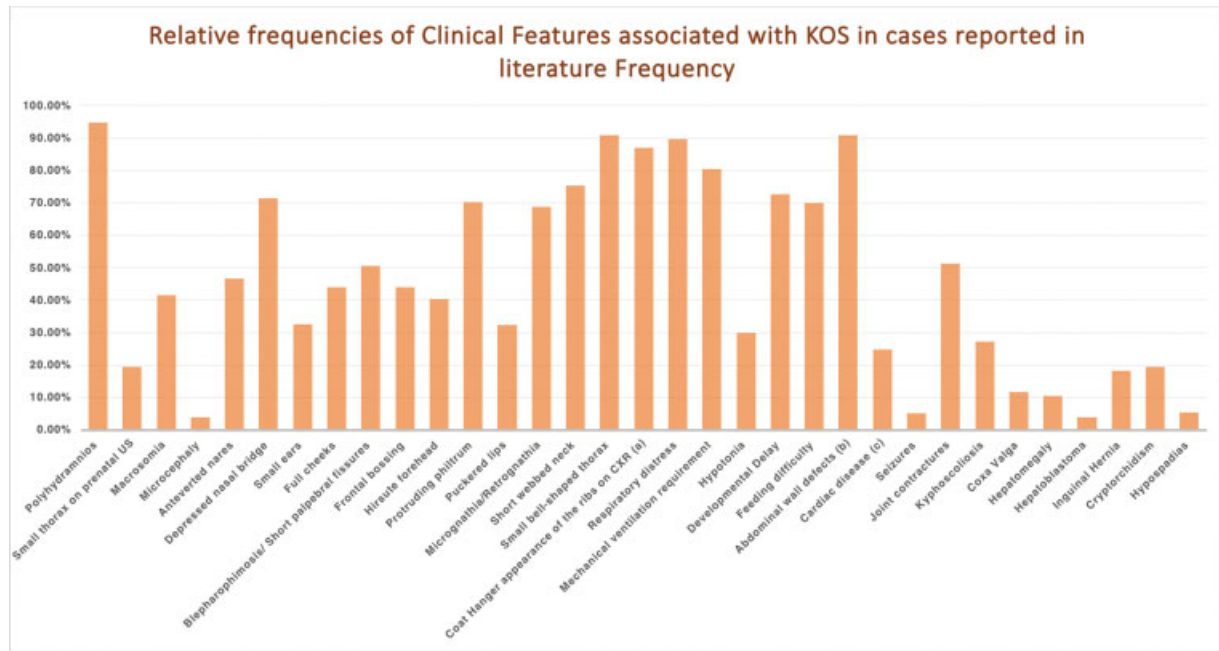
Patients with KOS typically present with a classical phenotype consisting of polyhydramnios, characteristic facial appearance, small narrow bell-shaped thorax, abnormally shaped ribs (described as coat-hanger appearance of the ribs on chest radiograph—see **Fig. 4**), abdominal wall defects, and placentomegaly. Facial dysmorphism includes frontal bossing, hirsute forehead, depressed nasal bridge, micro/retrognathia, full cheeks, webbed neck, blepharophimosis/short palpebral fissures, protruding philtrum, small ears, anteverted nares, and puckered lips.<sup>3</sup> Almost all patients have developmental delay. **Fig. 5** shows the relative frequencies of various features associated with KOS in patients previously reported in the literature.

Other infrequently reported findings include subarachnoid hygroma, single transverse palmar crease, H-shaped skin crease below lower lip, short limbs, camptodactyly, and syndactyly. Male patients with KOS have also been reported to have cryptorchidism, hypospadias, bilateral scrotum (scrotal fission), and penile scrotal transposition.<sup>1,6–21</sup> It is unknown whether KOS affects fertility. To date only four adult cases of KOS have been described and no comments regarding their fertility were made by the authors.<sup>18</sup>

## Genetics

The human chromosome 14 consists of an imprinted region at 14q32.2 that includes the paternally expressed genes (PEGs) *DLK1* and *RTL1* and maternally expressed genes (MEGs) *MEG3* (also known as *GTL2*), *RTL1as* (*RTL1* antisense), and *MEG8*.<sup>22</sup> This region also encompasses the DMRs IG-DMR and *MEG3*-DMR (**Fig. 6**).<sup>23–25</sup> Both DMRs are methylated after paternal transmission and unmethylated after maternal transmission in the body, whereas, in the placenta, the IG-DMR remains as a DMR and the *MEG3*-DMR is hypomethylated regardless of parental origin.<sup>2,25</sup> KOS occurs due to various molecular mechanisms, the most common being UPD(14)pat in ~2/3rd of the cases followed by microdeletions and epimutations. Both inherited and de novo





**Fig. 5** Relative frequencies of various features associated with Kagami-Ogata syndrome (KOS) reported in literature: ( $n = 77$  for all features except cryptorchidism and hypospadias, where  $n = 36$ ). (a) After coat hanger-sign was defined in 2003, 95.7% of patients (67/70) with KOS were reported to have coat-hanger ribs. (b) 61% patients had diastasis recti, 27.3% patients had omphalocele, and 6.5% patients were reported to have umbilical hernia. (c) Atrial septal defects accounted for 31.5% of all cardiac diseases reported; ventricular septal defects for 5.2%, and persistent ductus arteriosus for 10.4%. Other cardiac diseases (6.5%) reported were pulmonic stenosis ( $n = 3$ ), interrupted aortic arch ( $n = 1$ ), and hypertrophic cardiomyopathy ( $n = 1$ ).

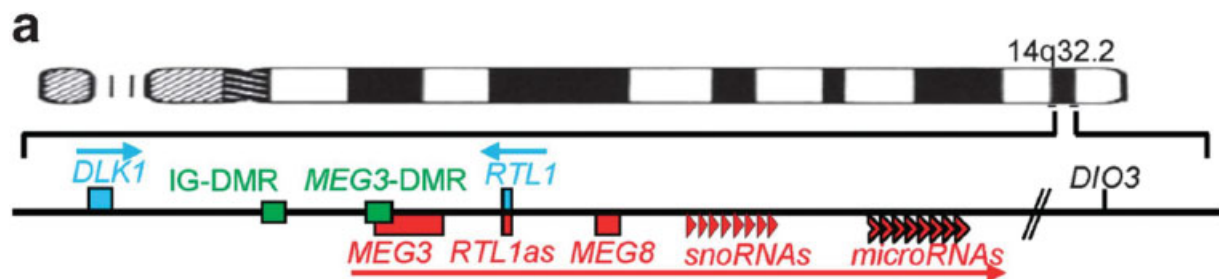
Robertsonian translocations involving chromosome 14 increase risk of KOS due to trisomy and monosomy rescue. Excessive *RTL1* expression due to absence of *RTL1as* expression without the involvement of the 2 DMRs might also lead to development of the UPD(14)pat-like phenotype.<sup>2,26</sup> Paternally inherited Robertsonian translocations and maternally inherited microdeletions are associated with increased recurrence risk in future pregnancies.<sup>17,25–27</sup>

Only two cases of UPD(14)pat mosaicism have been reported to date.<sup>11,28</sup> Our review found that the reported frequency of KOS due to epimutations was lower (8.4% compared with 15.4%) than previously reported.<sup>29</sup> All cases of epimutations previously reported were from Japan. Our second case is the first patient with KOS due to epimutation reported from outside Japan. There is an almost equal

incidence in males and females ( $n = 36$  vs.  $n = 41$ ). ►Table 1 summarizes the previously reported cases of KOS.

### Prenatal Diagnosis

Accurate diagnosis of KOS may be difficult to establish in the prenatal period. To date, only few cases of prenatal diagnosis have been reported in literature.<sup>16,17,30–32</sup> Although polyhydramnios is present in nearly all patients with KOS (►Fig. 5), the presence of polyhydramnios is nonspecific. Facial dysmorphism may or may not be seen on fetal ultrasound. Small thorax on fetal ultrasound, although very sensitive for KOS, has been reported in only 19.5% of the cases. In our first case, the thorax size was at the lower limit of normal (►Fig. 1). However, presence of characteristic facial findings or omphalocele with/without small thorax



**Fig. 6** Schematic representation of physical map of the chromosome 14q32.2 imprinted region. *RTL1* and *DLK1* are paternally expressed genes (PEGs) and shown in blue. Maternally expressed genes (MEGs) including *MEG3*, *MEG8*, and *RTL1as* are shown in red. Differentially methylated regions (DMRs) (*MEG3* and *IG-DMR*) are shown in green. (Courtesy of Ogata T, Kagami M. Kagami-Ogata syndrome: a clinically recognizable up (14)pat and related disorder affecting the chromosome 14q32.2 imprinted region. *J Hum Genet.* 2016;61(2):87–94.)

**Table 1** Summary of previously reported cases of KOS included in this literature review

Reference (year)	Pts (n)	Genetic cause of KOS	Facial gestalt	Mechanical ventilation	Develop-mental delay	At the time of report		Cause(s) of death	
						Age	Alive		Dead
Wang et al <sup>1</sup> (1991)	1	UPD(14) with RT [45,XX,t(13q14q)]	1	Not specified	1	9 y	1	0	n/a
Papenhausen et al <sup>43</sup> (1995)	1	UPD(14) with RT [45,XX,t(14q14q)]	1	1	1	20 mo	1	0	n/a
Walter et al <sup>7</sup> (1996)	1	UPD(14) with RT [45,XY,dic(14)(p11)]	1	1	0	6 mo	1	0	n/a
Cotter et al <sup>9</sup> (1997)	1	UPD(14) with RT [45,XX,der(13;14)(q10;q10)]	1	1	1	6 mo	0	1	Pulmonary complications
Yano et al <sup>44</sup> (2001)	1	UPD(14)pat. with RT [45,XX,der(14;14)(q10;q10)]	1	Not specified	Not specified	Not specified	Not specified	Not specified	
McGowan et al <sup>45</sup> (2002)	1	UPD(14) with RT [45,XX,der(14;14)(q10;q10)]	1	1	n/a	6 wk	0	1	Care withdrawn
Coveler et al <sup>8</sup> (2002)/Towner et al <sup>41</sup> (2001)	1	UPD(14)pat. without RT	1	1	1	19 mo (vegetative state)	1	0	n/a
Offiah et al <sup>6</sup> (2003)	1	UPD(14)pat. without RT	1	1	n/a	6 wk	0	1	Care withdrawn
Chu et al <sup>13</sup> (2004)	1	UPD(14)pat. without RT	1	1	1	3 mo	0	1	Respiratory infection
Stevenson et al <sup>46</sup> (2004)	1	UPD(14) with RT [45,XX,inv(9)(p11q13),dic(14;14)(p11.1;p11.1)]	1	1	1	7 mo	1	0	n/a
Curtis et al <sup>35</sup> (2006)	1	UPD(14)pat. without RT	1	1	1	9 mo	0	1	Care withdrawn
Mattes et al <sup>11</sup> (2007)	1	UPD(14)mosaic 47,XX+mar(14)[44]/46,XX[6]	1	1	1	5 mo	0	1	Respiratory infection
Inving et al <sup>14</sup> (2010)	1	UPD(14)pat. without RT	1	1	n/a	9 wk	0	1	Care withdrawn
Sargar et al <sup>15</sup> (2014)	1	UPD(14)pat. without RT	1	1	Not specified	4 mo	0	1	Comfort care only
Suzumori et al <sup>33</sup> (2010)	1	UPD(14)pat. without RT	1	1	1	8 mo	1	0	n/a
Yamanaka et al <sup>32</sup> (2010)	2 <sup>a</sup>	UPD(14)pat. without RT	Not specified	2/2	1/2 <sup>a</sup>	4 mo-1 y	1	1	Hepatic failure (4 mo)
Boiffard et al <sup>17</sup> (2014)	1	Not reported	1	Not specified	0	2 y	1	0	n/a
Beygo et al <sup>47</sup> (2015)	1	Microdeletion [de novo]	Not specified	1	1	27 mo	1	0	n/a
	2	Microdeletion [maternally inherited]	2	1/2	1/2	10 mo-5.5 y	2	0	n/a
Watanabe et al <sup>34</sup> (2015)	1	Epimutation	1	Not specified	Not specified	Not specified	Not specified	Not specified	
Kagami et al <sup>3</sup> (2015)	2	2 UPD(14)pat. with RT [45,XX,rob(13;14)(q10;q10) and 45,XX,rob(14;21)(q10;q10)]	2/2	1/2	1/2 <sup>b</sup>	8 mo-1 y, 8 mo	1	1	Hepatoblastoma (8 mo)
	20	UPD(14)pat. without RT	20/20	19/20	20/20	6 mo-15 y	17	3	Influenza (3 y, 2 mo), NEC (6 mo), hemophagocytic syndrome (17 mo)

Table 1 (Continued)





















Reference (year)	Pts (n)	Genetic cause of KOS	Facial gestalt	Mechanical ventilation	Developmental delay	At the time of report		Cause(s) of death	
						Age	Alive		Dead
	1	UPD(14)pat with karyotype unknown	1/1	1/1	n/a	2h	0	1	Respiratory failure
	5	Epimutation	5/5	5/5	5/5	9 mo-5.5 y	5	0	n/a
	2	Microdeletion [de novo]	2/2	2/2	1/2 <sup>c</sup>	4 d-3 y, 10 mo	0	2	Intracranial hemorrhage (4 d), care withdrawn (3 y, 11 mo)
	4	Microdeletion [maternally inherited]	4/4	4/4	4/4	9 mo-8 y, 11 mo	3	1	Sudden death due to URI (9 mo)
Schmeh et al <sup>12</sup> (2016)	1	Not reported	1	1	Not specified	4 mo	0	1	Care withdrawn
Yuan et al <sup>21</sup> (2016)	1	UPD(14)pat without RT	1	0	1	2 y	1	0	n/a
Vecchio and Giuffrè <sup>48</sup> (2016)	1	UPD(14)pat without RT	1	0	Not specified	35 d	1	0	n/a
van der Werf et al <sup>18</sup> (2016)	4	Microdeletions [maternally inherited]	4/4	2/4	4/4	3-32 y	4	0	n/a
Haug et al <sup>28</sup> (2017)	1	UPD(14)pat Mosaicism [46,XX/46,XX upd(14)pat]	1	0	0	13 y	1	0	n/a
Chen et al <sup>30</sup> (2019)	1	UPD(14)pat without RT	1	n/a	n/a	n/a	0	1	Termination of pregnancy at 21.5 wk of gestation
Huang et al <sup>49</sup> (2019)	1	Microdeletion [de novo]	1	1	1	2.5 y	1	0	n/a
Luk <sup>27</sup> (2017)	2	Microdeletion [maternally inherited]	2/2	2/2	2/2	3-5 y	2	0	n/a
Yamagata et al <sup>19</sup> (2018)	1	Not reported	Not specified	1	Not specified	2 y	1	0	n/a
Igreja da Silva et al <sup>16</sup> (2019)	1	UPD(14)pat with RT [45,XX,der(13;14)(q10;q10)]	Not specified	n/a	n/a	3h	0	1	Comfort care only
Wang et al <sup>20</sup> (2020)	1	UPD(14)pat with RT [45,XY,der(13;14)(q10;q10)]	1	Not specified	1	20 mo	1	0	n/a
Altmann et al <sup>40</sup> (2020)	1	Microdeletion	1	1	1	15 mo	1	0	n/a
Al-Mudares and Fernandes <sup>50</sup> (2020)	1	Not reported	Not specified	1	n/a	4 wk	0	1	Omphalocele and septic shock
Jung et al <sup>10</sup> (2018)	1	Microdeletion [maternally inherited]	1	1	1	2 mo	1	0	n/a
Corseillo et al <sup>26</sup> (2015)	1	Microdeletion [de novo, not involving the 2 DMRs]	1	1	Not specified	5 mo	1	0	n/a
This report (2021)	2	1 Epimutation 1 Unknown	2/2	2/2	2/2	2.5 mo-3 y, 3 mo	0	2	Care withdrawn (2.5 mo), cardiac arrest (3 y, 3 mo)

Abbreviations: DMrs, differentially methylated regions; KOS, Kagami-Ogata syndrome; n/a, not applicable; NEC, necrotizing enterocolitis; Pts, patients; RT, Robertsonian translocation; UPD(14)pat, uniparental disomy of chromosome 14; URI, upper respiratory infection.

<sup>a</sup>Four cases were reported by Yamanaka et al, of which two cases were also reported by Kagami et al (2015) more comprehensively and have been included below. Developmental status of the infant who died at 4 months of age has not been specified.

<sup>b</sup>Developmental status in one patient not specified.

<sup>c</sup>Developmental delay assessment not possible in infant who died at 4 days of life.

	Paternal DMRs		Maternal DMRs	
	MEG3	IG	MEG3	IG
<b>Normal</b>				
<b>UPD(14)pat</b>				
				
<b>Epimutation</b>				
<b>Microdeletion</b>				
<b>Microdeletion</b>				

**Fig. 7** Pictographic representation of the methylation patterns of differentially methylated regions (DMRs) observed in Kagami-Ogata syndrome (KOS). Hypomethylated (functional DMRs) are shown in green and hypermethylated (nonfunctional) DMRs are shown in red. In normal individuals, paternal DMRs are hypermethylated and maternal DMRs are hypermethylated. In uniparental disomy of chromosome 14 (UPD(14)pat), DMRs of maternal origin are absent with two copies of paternal DMRs, all of which are hypermethylated with absence of hypomethylated DMRs. In case of epimutations derived maternally, both DMRs of maternal origin are hypermethylated. Maternally derived microdeletions (shown as checkered green box) involving the MEG3-DMR lead to inactivation of MEG3-DMR only. However, in those involving the IG-DMR, MEG3-DMR is hypermethylated. (Adapted from Ogata T, Kagami M. Kagami-Ogata syndrome: a clinically recognizable upd(14)pat and related disorder affecting the chromosome 14q32.2 imprinted region. *J Hum Genet.* 2016;61(2):87–94.)

with/without absent/small stomach should raise suspicion for KOS.<sup>32,33</sup>

Three-dimensional ultrasound, fetal X-ray, or fetal magnetic resonance imaging to look for coat-hanger ribs/bell shaped thorax has been used in the past to aid the diagnosis of KOS.<sup>32–34</sup> The coat-hanger sign (usually identified on postnatal chest radiographs) could be visible as early as 23 weeks of gestation by prenatal ultrasound.<sup>35</sup>

If KOS is suspected in a fetus, parents should be offered amniocentesis for karyotype, CMA, and methylation analysis. Methylation analysis to detect the hypermethylation of IG-DMR and MEG3-DMR has been proposed as the first-tier test in the evaluation of suspected KOS (→Fig. 7).<sup>25</sup> Hypermethylation of the IG-DMR and/or MEG3-DMR is diagnostic for KOS; however, in absence of KOS, other genetic etiologies of the fetal malformations will be missed by methylation analysis alone. CMA is indicated in the workup of fetuses or infants with multiple congenital anomalies.<sup>36</sup> Balanced Robertsonian translocations involving chromosome 14 or supernumerary marker chromosome 14 identified on karyotype as well as deletions involving chromosome 14q identified on CMA may point toward the diagnosis of KOS.<sup>11,16,31</sup> Karyotype and CMA may also help identify the other possible genetic etiologies for the malformations detected prenatally. CMA may detect UPD due to isodisomy

but will not detect heterodisomy. Single nucleotide polymorphisms-based microarray has been used for prenatal diagnosis of KOS in the past.<sup>16,30</sup>

Even though prenatal diagnosis is possible, often the clinical features are not seen on ultrasound until 19 to 20 weeks of gestation and the definitive diagnosis requires access to a tertiary genetic testing facility that may further delay diagnosis. Hence, by the time diagnosis is established, termination of pregnancy may not be possible depending on the abortion laws of the country. However, prenatal diagnosis of KOS may aid the neonatologists and the obstetricians to better counsel parents and may enable the parents to make informed decisions regarding the escalation of care after delivery.

Genetic testing should also be offered to parents who had previous children with KOS if the affected child was found to have a deletion of the maternally inherited chromosome 14 or a paternally inherited Robertsonian translocation. In pregnant females with known microdeletions involving chromosome 14q32, chorionic villous sampling for CMA or SNP-microarray may aid in the early detection of KOS in the fetus.<sup>37</sup>

### Postnatal Diagnosis

KOS must be suspected in newborns that present with the facial gestalt described above as well as the classic “coat hanger” appearance of the ribs on chest radiographs and should be confirmed with genetic testing. In both our cases, recognition of the “coat-hanger sign” on chest X-ray prompted the genetic testing for diagnosis of KOS.

### Coat Hanger Sign and M/W Ratio

Offiah et al first introduced the term “coat-hanger sign” for the short abnormally curved ribs seen in patients with KOS.<sup>6</sup> After its initial description, the coat-hanger sign has been recognized in 95.7% patients with KOS (→Fig. 5). In 2011, Miyazaki et al introduced the coat-hanger angle or CHA (the average of angles between the peak point, or the center in absence of peak point, of both 6th posterior ribs and the horizontal axis) and the mid-widest thorax ratio (M/W ratio) (→Fig. 4).<sup>38</sup> A CHA of > 25 degree with/without M/W ratio of ≤ 80% should raise a suspicion for KOS. Chest radiographs often normalize with age.<sup>3,18,38,39</sup> →Fig. 3 shows the chest X-rays of our second patient at 9 days and at 3 years of life.

KOS must also be considered in the differential diagnosis of a patient with omphalocele or other abdominal wall defects along with other phenotypical features of KOS.<sup>40,41</sup> According to the diagnostic flowchart proposed by Ogata and Kagami, methylation analysis should be the first-tier diagnostic testing. Positive methylation analysis (hypermethylation of MEG3/IG DMR with absence of respective hypomethylated DMR) (→Fig. 7) is diagnostic of KOS and must be followed by parent-of-origin analysis to determine biparental inheritance versus UPD(14)pat. In cases where biparental inheritance is confirmed, deletion analysis should be done to distinguish between KOS caused by microdeletions versus epimutations. In cases with confirmed UPD(14) pat, karyotype should be performed to evaluate for



Robertsonian translocations or isochromosome 14. If methylation analysis is negative, diagnosis must be reconsidered, and CMA and testing for other genetic conditions should be considered.<sup>25</sup> However, UPD14 methylation analysis may take weeks to result and it might be reasonable to order CMA and/or karyotype earlier, as they may aid in the early detection of KOS as well as detect other genetic abnormalities in the absence of KOS. Of note, patients with KOS due to small deletions involving only *RTL1as*, *MEG3*, *MEG8*, *snoRNAs*, and/or *miRNAs*, but not the DMRs, or mutations of *RTL1as* leading to excessive *RTL1* expression may be missed by methylation analysis.<sup>25,26</sup>

Unfortunately, in our first case, we were unable to perform the parent-of-origin analysis, as parents declined further testing. Both our patients had unrelated nondiagnostic segmental abnormalities in a different chromosome and karyotype was normal, thus pointing toward either UPD(14)pat without Robertsonian translocation or KOS due to epimutations. UPD(14) microsatellite analysis was negative in our second case, thus confirming KOS due to epimutation.

### Postnatal Management

The management of KOS remains largely supportive and requires a multidisciplinary approach involving the neonatologist, pulmonologist, cardiologist, neurologist, pediatric surgeon, speech therapist, physical therapist, and developmental therapist. Genetic specialists must be consulted to aid in the molecular evaluation and provide pretest counseling, anticipatory guidance, and posttest counseling that should include discussion of recurrence risks and testing of family members when indicated.

Respiratory distress developing due to abnormally shaped ribs and small thorax with/without hypotonia is usually the first sign for which the patient is admitted to the NICU, and most patients require mechanical ventilation (→Fig. 5). Endotracheal intubation in patients with KOS can be complicated by the presence of micrognathia, short neck, kyphoscoliosis, and tracheal deviation.<sup>1</sup> Echocardiogram to evaluate for congenital heart diseases must be performed given a more than normal incidence of septal defects associated with this syndrome (→Fig. 5). Some patients may require gastrostomy and/or tracheostomy tube placement. Male patients with KOS must be evaluated for the presence of cryptorchidism and hypospadias, and if present, urology must be consulted. Due to the possibility of hepatoblastoma and the high mortality associated with this tumor, we recommend regular abdominal ultrasounds and serum AFP levels (every 3 months, until 48 months of age).<sup>3,42</sup> Patients should also be monitored for seizure disorders and must receive appropriate speech, physical and developmental therapy.

### Prognosis

Respiratory distress is the primary cause of morbidity and mortality in patients with KOS. In our review, mortality was reported to be 29.7% at the time of report (22 out of 74; 1 medical termination and outcomes of 2 patients were unknown). Most deaths occurred between 2 hours and

9 months ( $n = 18$ , mean = 3.7 months). However, four deaths occurred after infancy: one at 17 months due to hemophagocytic syndrome in a patient with hepatoblastoma (of note, infant was ventilator-dependent during her life and had a tracheostomy), two others at 3 years, 2 months and 3 years, 10 months, respectively, due to respiratory infections in patients who were successfully weaned off the ventilator, and the fourth (our 2nd case) due to respiratory failure secondary to tracheostomy tube dislodgement at 3 years, 3 months of age.<sup>2,29,42</sup> Consistent with reports by Ogata and Kagami, no deaths occurred in patients > 4 years of age.<sup>25</sup> Of the 52 patients who were alive at the time of report in the literature, 6 were still on mechanical ventilation and ranged in age from 6 months to 55 months.

Most patients with KOS invariably have developmental delay and feeding difficulties. Other long-term complications may include seizure disorder and the need for tracheostomy and/or gastrostomy tubes.

### Conclusion

KOS is a rare imprinting disorder associated with a severe phenotype and poor long-term prognosis. The diagnosis of KOS is often delayed due to the significant overlap with Beckwith–Wiedemann syndrome, trisomy 18, Jeune syndrome, and other congenital thoracic dysplasias. Presence of omphalocele and/or small thorax on fetal ultrasound along with polyhydramnios must alert the perinatologist toward the possibility of KOS. The coat-hanger sign on fetal ultrasound or on chest X-ray is specific to KOS. Recognition of these key findings is integral to early diagnosis of patients and enables parents to make an informed decision regarding management. Genetic evaluation is complicated and should be performed in collaboration with medical genetics professional. Our cases demonstrate the need to recognize KOS in the differential and collaborate with appropriate specialists to come to timely diagnosis.

### Conflict of Interest

None declared.

### Acknowledgments

We would like to acknowledge Dr. Chester Brown for his valuable input toward the diagnosis of our first case.

### References

- 1 Wang JC, Passage MB, Yen PH, Shapiro LJ, Mohandas TK. Uniparental heterodisomy for chromosome 14 in a phenotypically abnormal familial balanced 13/14 Robertsonian translocation carrier. *Am J Hum Genet* 1991;48(06):1069–1074
- 2 Kagami M, Sekita Y, Nishimura G, et al. Deletions and epimutations affecting the human 14q32.2 imprinted region in individuals with paternal and maternal upd(14)-like phenotypes. *Nat Genet* 2008;40(02):237–242
- 3 Kagami M, Kurosawa K, Miyazaki O, Ishino F, Matsuoka K, Ogata T. Comprehensive clinical studies in 34 patients with molecularly defined UPD(14)pat and related conditions (Kagami-Ogata syndrome). *Eur J Hum Genet* 2015;23(11):1488–1498

- 4 McKusick VA, Kniffin CL. #608149: Kagami-Ogata Syndrome. OMIM Johns Hopkins University Accessed March 13, 2021 at <https://www.omim.org/entry/608149#1>
- 5 Orphanet: Kagami Ogata syndrome. Accessed March 13, 2021 at [https://www.orpha.net/consor/cgi-bin/OC\\_Exp.php?lng=EN&Expert=254519](https://www.orpha.net/consor/cgi-bin/OC_Exp.php?lng=EN&Expert=254519)
- 6 Offiah AC, Cornette L, Hall CM. Paternal uniparental disomy 14: introducing the “coat-hanger” sign. *Pediatr Radiol* 2003;33(07):509–512
- 7 Walter CA, Shaffer LG, Kaye CI, et al. Short-limb dwarfism and hypertrophic cardiomyopathy in a patient with paternal isodisomy 14: 45,XY,idic(14)(p11). *Am J Med Genet* 1996;65(04):259–265
- 8 Coveler KJ, Yang SP, Sutton R, et al. A case of segmental paternal isodisomy of chromosome 14. *Hum Genet* 2002;110(03):251–256
- 9 Cotter PD, Kaffe S, McCurdy LD, Jhaveri M, Willner JP, Hirschhorn K. Paternal uniparental disomy for chromosome 14: a case report and review. *Am J Med Genet* 1997;70(01):74–79
- 10 Jung HS, Vallee SE, Dinulos MB, Tsongalis GJ, Lefferts JA. Maternally inherited 133kb deletion of 14q32 causing Kagami-Ogata syndrome. *J Hum Genet* 2018;63(12):1231–1239
- 11 Mattes J, Whitehead B, Liehr T, et al. Paternal uniparental isodisomy for chromosome 14 with mosaicism for a supernumerary marker chromosome 14. *Am J Med Genet A* 2007;143A(18):2165–2171
- 12 Schmeih I, Kidszun A, Lausch E, Bartsch O, Mildenerberger E. Chest radiograph as diagnostic clue in a floppy infant. *J Pediatr* 2016;177:324–324.e1
- 13 Chu C, Schwartz S, McPherson E. Paternal uniparental isodisomy for chromosome 14 in a patient with a normal 46,XY karyotype. *Am J Med Genet A* 2004;127A(02):167–171
- 14 Irving MD, Buiting K, Kanber D, et al. Segmental paternal uniparental disomy (patUPD) of 14q32 with abnormal methylation elicits the characteristic features of complete patUPD14. *Am J Med Genet A* 2010;152A(08):1942–1950
- 15 Sargar KM, Herman TE, Siegel MJ. Paternal uniparental disomy of chromosome 14. *J Perinatol* 2014;34(09):723–725
- 16 Igreja da Silva JI, Ribeiro B, Cadilhe A, Nogueira-Silva C. Paternal uniparental disomy for chromosome 14: prenatal management. *BMJ Case Rep* 2019;12(12):e231705
- 17 Boiffard F, Bénétteau C, Quéré MP, Philippe HJ, Le Vaillant C. Quand faut-il évoquer en anténatal une disomie uniparentale paternelle 14? [When should evoke prenatal paternal uniparental disomy 14?]*Gynécobstét Fertil* 2014;42(04):254–257
- 18 van der Werf IM, Buiting K, Czeschik C, et al. Novel microdeletions on chromosome 14q32.2 suggest a potential role for non-coding RNAs in Kagami-Ogata syndrome. *Eur J Hum Genet* 2016;24(12):1724–1729
- 19 Yamagata K, Kawamura A, Kasai S, Akazawa M, Takeda M, Tachibana K. Anesthetic management of a child with Kagami-Ogata syndrome complicated with marked tracheal deviation: a case report. *JA Clin Rep* 2018;4(01):62
- 20 Wang X, Pang H, Shah BA, Gu H, Zhang L, Wang H. A male case of Kagami-Ogata syndrome caused by paternal uniparental disomy 14 as a result of a Robertsonian translocation. *Front Pediatr* 2020;8:88
- 21 Yuan H, Xie Y, Li Q, et al. Paternal uniparental disomy of chromosome 14 with hypospadias. *Cytogenet Genome Res* 2016;148(04):256–261
- 22 Charlier C, Segers K, Wagenaar D, et al. Human-ovine comparative sequencing of a 250-kb imprinted domain encompassing the callipyge (clpg) locus and identification of six imprinted transcripts: DLK1, DAT, GTL2, PEG11, antiPEG11, and MEG8. *Genome Res* 2001;11(05):850–862
- 23 Murphy SK, Wylie AA, Coveler KJ, et al. Epigenetic detection of human chromosome 14 uniparental disomy. *Hum Mutat* 2003;22(01):92–97
- 24 Lin SP, Youngson N, Takada S, et al. Asymmetric regulation of imprinting on the maternal and paternal chromosomes at the Dlk1-Ct12 imprinted cluster on mouse chromosome 12. *Nat Genet* 2003;35(01):97–102
- 25 Ogata T, Kagami M. Kagami-Ogata syndrome: a clinically recognizable upd(14)pat and related disorder affecting the chromosome 14q32.2 imprinted region. *J Hum Genet* 2016;61(02):87–94
- 26 Corsello G, Salzano E, Vecchio D, et al. Paternal uniparental disomy chromosome 14-like syndrome due a maternal de novo 160 kb deletion at the 14q32.2 region not encompassing the IG- and the MEG3-DMRs: patient report and genotype-phenotype correlation. *Am J Med Genet A* 2015;167A(12):3130–3138
- 27 Luk HM. Familial Kagami-Ogata syndrome in Chinese. *Clin Dysmorphol* 2017;26(02):124–127
- 28 Haug MG, Brendehaug A, Houge G, Kagami M, Ogata T. Mosaic upd(14)pat in a patient with mild features of Kagami-Ogata syndrome. *Clin Case Rep* 2017;6(01):91–95
- 29 Kagami M, Kato F, Matsubara K, Sato T, Nishimura G, Ogata T. Relative frequency of underlying genetic causes for the development of UPD(14)pat-like phenotype. *Eur J Hum Genet* 2012;20(09):928–932
- 30 Chen CL, Lee CN, Lin MW, Hsu WW, Tai YY, Lin SY. Prenatal diagnosis of paternal uniparental disomy for chromosome 14 using a single-nucleotide-polymorphism-based microarray analysis: a case report. *J Formos Med Assoc* 2019;118(03):739–742
- 31 Klein J. Delineation of the paternal disomy 14 syndrome: identification of a case by prenatal diagnosis. *Am J Hum Genet* 1999;65:A179
- 32 Yamanaka M, Ishikawa H, Saito K, et al. Prenatal findings of paternal uniparental disomy 14: report of four patients. *Am J Med Genet A* 2010;152A(03):789–791
- 33 Suzumori N, Ogata T, Mizutani E, et al. Prenatal findings of paternal uniparental disomy 14: delineation of further patient. *Am J Med Genet A* 2010;152A(12):3189–3192
- 34 Watanabe T, Go H, Kagami M, Yasuda S, Nomura Y, Fujimori K. Prenatal findings and epimutations for paternal uniparental disomy for chromosome 14 syndrome. *J Obstet Gynaecol Res* 2015;41(07):1133–1136
- 35 Curtis L, Antonelli E, Vial Y, et al. Prenatal diagnostic indicators of paternal uniparental disomy 14. *Prenat Diagn* 2006;26(08):662–666
- 36 Waggoner D, Wain KE, Dubuc AM, et al; ACMG Professional Practice and Guidelines Committee. Yield of additional genetic testing after chromosomal microarray for diagnosis of neurodevelopmental disability and congenital anomalies: a clinical practice resource of the American College of Medical Genetics and Genomics (ACMG). *Genet Med* 2018;20(10):1105–1113
- 37 Sasaki A, Sumie M, Wada S, et al. Prenatal genetic testing for a microdeletion at chromosome 14q32.2 imprinted region leading to UPD(14)pat-like phenotype. *Am J Med Genet A* 2014;164A(01):264–266
- 38 Miyazaki O, Nishimura G, Kagami M, Ogata T. Radiological evaluation of dysmorphic thorax of paternal uniparental disomy 14. *Pediatr Radiol* 2011;41(08):1013–1019
- 39 Kagami M, Nishimura G, Okuyama T, et al. Segmental and full paternal isodisomy for chromosome 14 in three patients: narrowing the critical region and implication for the clinical features. *Am J Med Genet A* 2005;138A(02):127–132
- 40 Altmann J, Horn D, Korinth D, Eggermann T, Henrich W, Verlohren S. Kagami-Ogata syndrome: an important differential diagnosis to Beckwith-Wiedemann syndrome. *J Clin Ultrasound* 2020;48(04):240–243
- 41 Towner D, Yang SP, Shaffer LG. Prenatal ultrasound findings in a fetus with paternal uniparental disomy 14q12-qter. *Ultrasound Obstet Gynecol* 2001;18(03):268–271
- 42 Horii M, Horiuchi H, Momoeda M, et al. Hepatoblastoma in an infant with paternal uniparental disomy 14. *Congenit Anom (Kyoto)* 2012;52(04):219–220

- 43 Papenhausen PR, Mueller OT, Sutcliffe M, Diamond TM, Kousseff BG, Johnson VP. Uniparental isodisomy of chromosome 14 in two cases: an abnormal child and a normal adult. *Am J Med Genet* 1996;66(01):90
- 44 Yano S, Li L, Owen S, Wu S, Tran T. A further delineation of the uniparental disomy (UPD 14): the fifth reported liveborn case. *Am J Hum Genet* 2001;69(Suppl):A739
- 45 McGowan KD, Weiser JJ, Horwitz J, et al. The importance of investigating for uniparental disomy in prenatally identified balanced acrocentric rearrangements. *Prenat Diagn* 2002;22(02):141–143
- 46 Stevenson DA, Brothman AR, Chen Z, Bayrak-Toydemir P, Longo N. Paternal uniparental disomy of chromosome 14: confirmation of a clinically-recognizable phenotype. *Am J Med Genet A* 2004; 130A(01):88–91
- 47 Beygo J, Elbracht M, de Groot K, et al. Novel deletions affecting the MEG3-DMR provide further evidence for a hierarchical regulation of imprinting in 14q32. *Eur J Hum Genet* 2015;23(02):180–188
- 48 Vecchio D, Giuffrè M The Coat-Hanger angle sign. *J Pediatr* 2016; 177:325–325.e1
- 49 Huang H, Mikami Y, Shigematsu K, et al. Kagami-Ogata syndrome in a fetus presenting with polyhydramnios, malformations, and preterm delivery: a case report. *J Med Case Reports* 2019;13(01): 340
- 50 Al-Mudares F, Fernandes CJ. “Coat Hanger” appearance of the ribs. *N Engl J Med* 2020;382(13):1257