Article published online: 2021-06-22

Sacroiliac Joint Pain: An Updated Review of the Clinical Approach for Diagnosis

Dolor sacroilíaco: Revisión actualizada del enfrentamiento diagnóstico

Enrique Blanco[1] Sebastián Frías[2] Facundo Álvarez[3] José Fleiderman[4]

[1] Medical student, Universidad de Chile, Santiago, Chile
[2] Traumatology and Orthopedics Resident, Clínica Universidad de los Andes, Hospital Militar de Santiago, Santiago, Chile
[3] Fellow de Columna, Clínica Universidad de los Andes, Santiago, Chile
[4] Centro de columna, Traumatología y Ortopedia, Clínica Universidad de los Andes, Hospital del Trabajador. Universidad de los Andes, Santiago, Chile

Address for correspondence Enrique Blanco Errázuriz, Universidad de Chile, avenida Independencia 1.027, Independencia, Región Metropolitana, Santiago, Chile (e-mail: enriqueblancoe@gmail.com).

Rev Chil Ortop Traumatol 2021;62(2):e143–e152.

Abstract

Sacroiliac pain accounts for 15% to 30% of low back pain conditions. Its diagnosis is a challenge for the physician due to its complex anatomy, the wide differential diagnoses list, and its several causes. Diagnosis requires a structured clinical history and an accurate physical examination. Specific sacroiliac physical examination tests should be performed in patients with suspected sacroiliac joint pain and interpreted together, not in isolation. Magnetic resonance imaging can rule out other causes of low back pain or diagnose inflammatory sacroiliitis. Joint infiltration is the gold standard for diagnosis, and it should be performed in patients with a high suspicion of sacroiliac joint pain based on anamnesis, physical examination, and three or more positive specific sacroiliac tests.

Keywords
- sacroiliac pain
- physical examination
- differential diagnosis
- low back pain

Resumen

El dolor sacroilíaco es responsable de 15% a 30% de los cuadros de dolor lumbar bajo. El diagnóstico de esta patología es un desafío para el médico, debido a su compleja anatomía, el amplio diagnóstico diferencial, y las diversas etiologías que pueden provocar dolor en la articulación sacroilíaca. Una anamnesis ordenada y dirigida, asociada a un examen físico preciso, ayuda a orientar el diagnóstico. Las pruebas sacroiliacas específicas deben realizarse en aquellos pacientes con sospecha de dolor sacroilíaco, y deben interpretarse en conjunto y no de manera aislada. La resonancia magnética sirve para descartar otras causas de dolor lumbar bajo o diagnosticar casos de sacroileítis inflamatoria. La infiltración de la articulación es el *gold standard* para el diagnóstico, y debe realizarse en pacientes con alta sospecha de dolor sacroilíaco, por la anamnesis, examen físico, y tres o más pruebas sacroilíacas específicas positivas.

Palabras clave
- dolor sacroilíaco
- examen físico
- diagnóstico diferencial
- dolor lumbar bajo

received
September 2, 2020
accepted
January 21, 2021

DOI https://doi.org/10.1055/s-0041-1728741.
ISSN 0716-4548.

© 2021. Sociedad Chilena de Ortopedia y Traumatologia. All rights reserved.
This is an open access article published by Thieme under the terms of the Creative Commons Attribution-NonDerivative-NonCommercial-License, permitting copying and reproduction so long as the original work is given appropriate credit. Contents may not be used for commercial purposes, or adapted, remixed, transformed or built upon. (https://creativecommons.org/licenses/by-nc-nd/4.0/)
Thieme Revinter Publicações Ltda., Rua do Matoso 170, Rio de Janeiro, RJ, CEP 20270-135, Brazil

Introduction

Low back pain is the main cause of non-oncological chronic pain in Chile.[1,2] Its consequences affect not only the individual with pain, but also the general population, since low back pain is an important factor for absenteeism from work and medical leaves,[3] generating a significant economic cost. Within low back pain etiologies, sacroiliac pain (SIP) is reported in 15% to 30% of the cases.[4] However, despite the impact on the quality of life of patients with this condition,[5] SIP is usually underdiagnosed in the presence of low back pain.[6]

Today, either in primary care or at a general trauma consultation, it is a real challenge to identify the sacroiliac joint (SIJ) as the cause of low back pain. This is due to its low index of suspicion by medical personnel, and to the low specificity and high rate of false-positive results on the anamnesis and physical examination.[7] Other reasons include the following:

1) Heterogeneous clinical manifestation of pain, with variable location, radiation, and intensity.[8,9]
2) Wide range of special physical tests, since none has sufficient diagnostic applicability.[10–13]
3) The highly prevalent coexistence with other degenerative lumbar conditions, with imaging findings which are non-symptomatic or constitute potential sources of pain.[14]
4) The wide list of differential diagnoses that could explain such pain.[15]
5) The lack of clinical recommendations or guidelines in Chile to propose a uniform confrontation.

This article presents a review of the literature with the intention of proposing a diagnostic approach to the patient with SIP, in order to optimize resources and improve diagnostic performance. The review was made based on a search on PubMed for "sacroiliac joint pain" associated with the keywords "physical examination" and "Diagnosis", filtering by Review, Systematic review, clinical trial and Meta-Analysis type articles, obtaining 139 articles, of which they were selected for their impact and relevance according to the criteria of the authors. We will review the anatomy, etiology, anamnesis, physical examination, and supplementary tests to finally propose a diagnostic algorithm to approach the patient with low back pain.

Anatomy and Biomechanics

The SIJ is the largest axial joint in our skeleton, and it distributes the axial load of the spine to both lower extremities. It is a mixed joint, since the anterior third of the articular surface consists of hyaline cartilage and presents a joint capsule, whereas the posterior two thirds are composed of fibrocartilage and a dense network of ligaments, acting as a syndesmosis,[16] as shown in ►**Figure 1**.

Innervation of the SIJ is a matter of debate.[17] Posteriorly, it is innervated by lateral bundles from the dorsal branch of L4-S3; anteriorly, it is postulated to be innervated by L2-S2. However, since the SIJ is close to the lumbosacral plexus and certain muscles, including the piriformis, gluteus maximus and biceps femoris, SIJ inflammation can irritate these structures, resulting in radiation of the joint pain.[18,19]

The range of motion of the SIJ is extremely limited and varies according to gender and age. In children and adolescents, its stabilizing ligaments are more flexible; in older subjects, however, SIJ ankylosis is common, especially in males.[19] Its main movements are nutation and counternutation. Nutation refers to sacral rotation in the sagittal plane, bringing the distal end of the sacrum posteriorly. This movement is scarce under normal conditions, around 1 mm to 4 mm, but it increases considerably in pregnant women to favor vaginal delivery.[20] In counternutation, the sacrum rotates in such a way that its distal portion approaches the symphysis pubis, while its upper portion is directed posteriorly (►**Figure 2**).

Bones and ligaments account for SIJ stability. Vertical stability is supported by the bone structure transmitting axial load forces in lateral compression to the iliac bones and then to the hips, making the sacrum into the cornerstone of pelvic architecture. The reinforced sacroiliac ligament

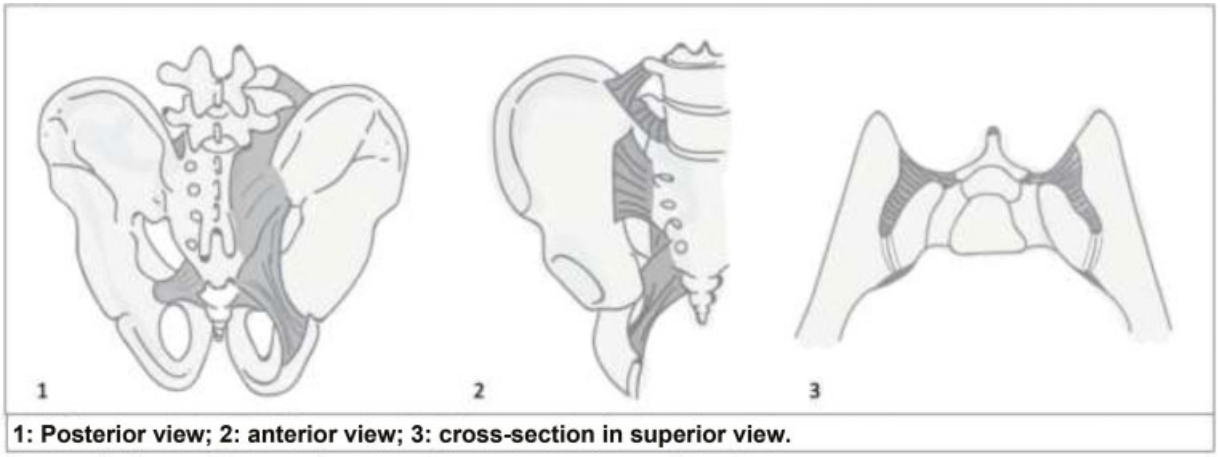

Fig. 1 Sacroiliac joint (SIJ) anatomy. 1: Posterior view; 2: anterior view; 3: cross-section in superior view.

 © 2021. Sociedad Chilena de Ortopedia y Traumatologia. All rights reserved.

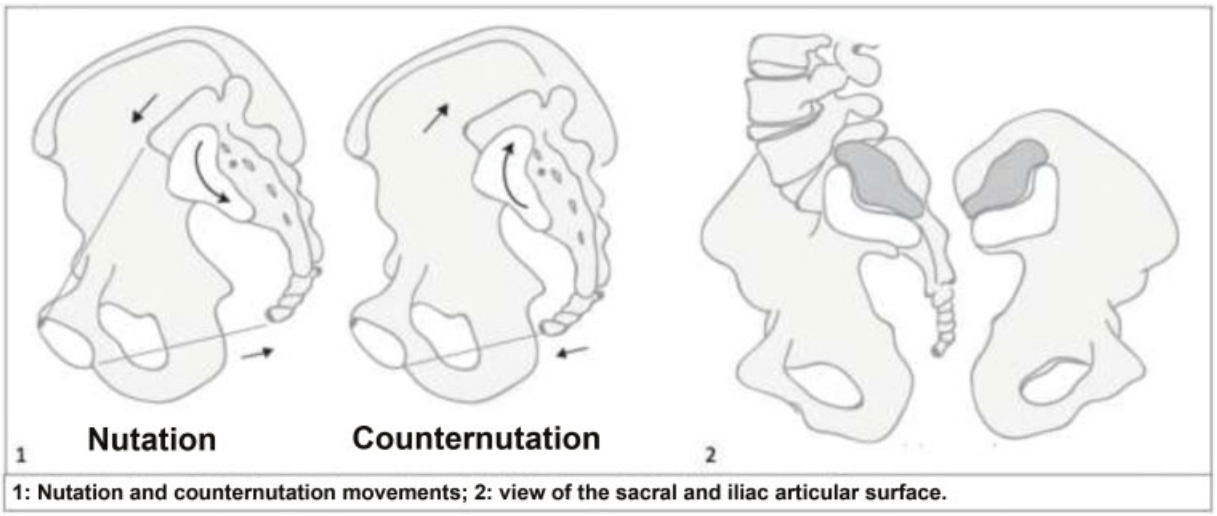

Fig. 2 Sacroiliac joint (SIJ) movement. 1: Nutation and counternutation movements; 2: view of the sacral and iliac articular surface.

complex provides stability at the anteroposterior plane,[21] as shown in ►**Figure 1**.

Sacroiliac Pain Etiology and Differential Diagnosis

When faced with a patient with low back pain, the doctor must determine if this is a true case of SIP or pain from another source. During evaluation, all non-sacroiliac causes of low back pain must be considered, both musculoskeletal, especially lumbar/hip conditions, and visceral or intrapelvic causes, since all of them are part of the list of differential diagnoses.[4,22–24] ►**Table 1** summarizes the causes of low back pain.

The SIJ can be affected by numerous conditions, which can either be primary pathologies or secondary systemic pathologies. For the primary conditions, the causes are eminently mechanical or infectious.[24,25] Sacroiliac pain can result from a phenomenon similar to that observed in transitional syndrome after spinal surgeries, in which hypermobility of a vertebral segment develops secondary to the fixation of adjacent segments. The SIJ may present such hypermobility after lumbosacral arthrodesis, resulting in pain.[26–28] The secondary causes of SIP are systemic diseases, some of them with an inflammatory origin, such as ankylosing spondylitis, or metabolic conditions, including hyperparathyroidism.[15,29] The primary and secondary causes of SIP are summarized in ►**Table 2**.

Clinical History

The proper pain identification requires important historical elements, such as onset, temporal profile, character, triggering or mitigating factors, radiation, and location. Sacroiliac pain usually manifests as mechanical lumbar pain, below L5, specifically lower than the posterior-superior iliac spine (PSIS).[9,12] Studies with sacroiliac infiltration in asymptomatic patients show areas of pain 10 cm caudal and 3 cm lateral to the PSIS,[8] but pain may arise in the unilateral or bilateral gluteal territory, the thigh, the groin, the leg, and the foot.[9,30] In addition, low back pain has been associated with changes in position, such as sitting down or standing up.[31]

During anamnesis, the doctor must ask about some SIP-predisposing elements, including history of pelvic trauma, surgical history, especially lumbosacral arthrodesis,[26] current or recent pregnancy, and sports or manual work activities resulting in pelvic shear or twist, such as weightlifting, contact sports, or skating.[32]

Table 1 Causes of low back pain[4,24–26]

Lumbar pathology:
Lumbar discopathy
Facet syndrome
Myofascial syndrome
Lumbar spine arthrosis
Hip pathology:
Hip arthrosis
Femoroacetabular impingement
Gluteal tendinitis
Trochanteric bursitis
Sacroiliac joint pain
Intrapelvic causes:
Pelvic inflammation
Endometriosis
Retrocecal appendicitis
Diverticulitis
Tubo-ovarian abscesses
Renal colic
Neoplasia

 © 2021. Sociedad Chilena de Ortopedia y Traumatologia. All rights reserved.

Table 2 Causes of sacroiliac pain[17,26–31]

Primary causes
Previous fracture
Microtrauma
Microinstability due to pregnancy-related hypermobility
Infectious sacroiliitis
Chronic osteomyelitis
Hypermobility after lumbosacral arthrodesis
Iliac condensing osteitis
Idiopathic sacroiliac pain
Secondary causes
Ankylosing spondylitis
Psoriatic arthritis
Arthritis associated with inflammatory bowel disease
Reactive arthritis
Chondrocalcinosis
Hyperparathyroidism
Reiter disease

General anamnesis must be thoroughly performed to uncover other morbid or surgical data, or even a family history of autoimmune diseases. Since sacroiliitis can occur as a manifestation of an underlying disease, the concomitant presence of general symptoms, such as fever and weight loss, or specific symptoms, including polyarthralgia, and abdominal, gynecological, or urological symptoms, must be determined.[24]

►**Table 3** shows a series of questions as a first approach to the patient in an attempt to rule out different differential diagnoses for low back pain. If any answer is affirmative, non-sacroiliac causes of pain must be considered, since SIP may result from a systemic condition.

Physical Examination

The physical examination in a patient with suspected SIP must be complete and accurate. Since the length of the consultation is often short, the physical examination is limited to the suspicion based on elements from the anamnesis. However, a complete physical examination of the hip and lumbar spine is essential when the medical history is doubtful.

The physical examination must start with a general examination, evaluating gait, analgesic postures, and obvious deformities, such as significant asymmetry in the length of the lower limbs or lumbar scoliosis.[24] Next, bone and muscle structures at the hip and lumbar levels must be palpated to detect tenderness; palpation may include the abdomen, looking for abdominal tenderness, if a referred pain of abdominopelvic origin is suspected.

Table 3 Approach to rule out sacroiliac pain at anamnesis

Pain in an atypical location? (Cephalic to L5, anterolateral, deep, or non-objective)
Pain with non-mechanical characteristics? (Nocturnal, at rest, not responding to non-steroidal anti-inflammatory drugs)
Presence of constitutional symptoms? (Fever, weight loss, fatigue)
Presence of gastrointestinal, urological, and/or gynecological symptoms?

After palpation, it is important to evaluate the ranges of motion of the lumbar spine and the hip, assessing active and passive movements, and comparing them with the contralateral side. A systematic motor and sensory evaluation of each nerve root is critical so as not to miss any deficit unnoticed by the patient.

Finally, tests must be performed to rule out specific conditions that are part of the list of differential diagnoses, including those to provoke radicular pain or assess femoroacetabular impingement.[23] ►**Table 4** proposes elements of the physical examination that, if altered, indicate a cause of pain other than the SIJ.

Specific SIJ tests are useful when the physical examination does not indicate a hip or lumbar condition. Because of the high rate of false-positive results regarding some SIJ tests, it is important to use them with discretion. This is especially true in the presence of hip disease, because some SIJ tests also diagnose hip conditions, sometimes with greater diagnostic effectiveness.[33]

Various specific tests have been described for the diagnosis of SIP.[7,10,12,13,34–36] When three of these tests are positive, the negative predictive value (NPV) for SIP reaches 87%.[37] The tests most used in the clinical practice are described below. ►**Table 5** summarizes the sacroiliac tests available, and their sensitivity, specificity, reliability, NPV and positive predictive value (PPV); these tests are shown in ►**Figure 3**.

Gaenslen test: the patient is placed in supine position and asked to flex the hip and knee on the affected side, bringing the knee towards the chest and supporting it with the arms. The contralateral leg should hang over the edge of the table. The examiner presses the bent knee toward the chest and

Table 4 Approach to rule out sacroiliac pain on the physical examination

Presence of mass or pain during abdominal palpation.
Limited or painful hip range of motion, pain at musculoskeletal palpation.
Tenderness on palpation of paravertebral lumbar or spinous processes. Painful lumbar range of motion.
Positive signs on provocative tests, impaired strength or sensitivity in lower limbs.

 © 2021. Sociedad Chilena de Ortopedia y Traumatologia. All rights reserved.

Table 5 Pain-evoking sacroiliac tests[10–13,26,36–38]

Test*	Sensitivity	Specificity	Reliability	Positive predictive value	Negative predictive value
Pelvic distraction	23–60%	81–98%	82%	60–93%	57–81%
Pelvic compression	26–69%	69–100%	82–87%	52–100%	59–82%
Thigh thrust	36–88%	69%	84%	58%	92%
Gaenslen test	31–71%	71–94%	82–88%	47–81%	60–77%
Sacral thrust	53%	75%	66–78%	56%	80%
Patrick test (flexion, abduction, external rotation – FABER)	34–69%	92%	74–80%	81%	60%
Drop test	–	–	88–97%	–	–
Posterior superior iliac spine distraction test[37]**	100%	89%	94%	90%	100%

Notes: *Positive results require at least 80% of pain relief after anesthetic infiltration. **The study proposing this test required 50% of pain relief for positive results; this is why its values are higher than the remaining figures.

exerts counterpressure on the other knee. The test is considered positive if it reproduces the exact pain reported by the patient.

Sacral thrust: with the patient in prone position, the examiner pressures the sacrum. The test is considered positive when it reproduces the exact pain reported by the patient.

Thigh thrust: with the patient in supine position, the hip on the affected side is flexed at 90°, and the ipsilateral knee is also flexed. The examiner places one hand on the patient's sacrum and supports the flexed knee with the other hand. The hip is adducted slightly while the examiner exerts force through the main axis of the femur, towards the sacrum. The test is considered positive when it reproduces the exact pain reported by the patient.

Pelvic compression: the patient is placed in lateral recumbency, with the affected side up, hips flexed at 45°, and knees flexed at 90°. The examiner exerts downward pressure on the iliac crest. The test is considered positive when it reproduces the exact pain reported by the patient.

Pelvic distraction: With the patient in supine position, the examiner applies force to both anterior superior iliac spines (ASISs) in a posterolateral direction. The test is considered positive when it reproduces the exact pain reported by the patient.

Patrick test (flexion, abduction, external rotation – FABER): with the patient in supine position, the ankle on the affected side is placed on the contralateral thigh with knee flexion and abduction and external rotation of the ipsilateral hip. Then, the examiner pressures the flexed knee, containing both ASISs. The test is considered positive if the patient reports the same pain in the ipsilateral side.

Fortin finger test: the patient stands up and is asked to point twice with one finger at the spot where they feel the greatest amount of pain. The test is positive when the patient indicates a spot 2 cm inferomedial to the PSIS both times.

Drop test: the patient stands up on the foot of the affected side and is asked to perform metatarsal support (tiptoe) and drop the heel. The test is considered positive when it reproduces the pain.

Gillet test: the examiner stands behind the patient, who is standing up. The examiner places one thumb on the PSIS on the affected side and the other thumb on the spinous process of S2, at the same level, and then asks the patient to flex the ipsilateral hip. Normally, the PSIS descends 1 or 2 cm. The test is considered positive if the spine does not descend, reflecting SIJ hypomobility.

PSIS distraction test:[35] With the patient standing up or in prone position, both thumbs are placed on the PSIS, exerting medial to lateral pressure. The test is considered positive if the pain is reproduced.

Imaging

The use of imaging for SIP diagnosis is a controversial topic. On the one hand, SIJ conditions may not have radiological manifestations, and the same disease may result in different manifestations.[29] On the other hand, different anatomical structures may present altered imaging findings but not cause pain, leading to diagnostic errors. In a study carried out by Boden et al.,[14] 67 assymptomatic individuals were examined through magnetic resonance imaging (MRI), and substantial lumbar spine abnormalities were found in 1/3 of them; this proportion reached 57% among subjects older than 60 years of age. Similarly, in 2015, Eno et al.[38] retrospectively analyzed computed tomography scans of 373 patients without low back pain or pelvic girdle pain. They found that 65.1% of the patients had signs of SIJ degeneration, and that this prevalence increased with age, reaching 100% in those older than 90 years of age.

In case of uncertainty as to whether the patient's pain comes from the SIJ, some authors suggest requesting an anteroposterior hip radiograph, which, together with the clinical history and physical examination, can guide the differential diagnosis.[24] However, this test is not very sensitive, and

 © 2021. Sociedad Chilena de Ortopedia y Traumatologia. All rights reserved.

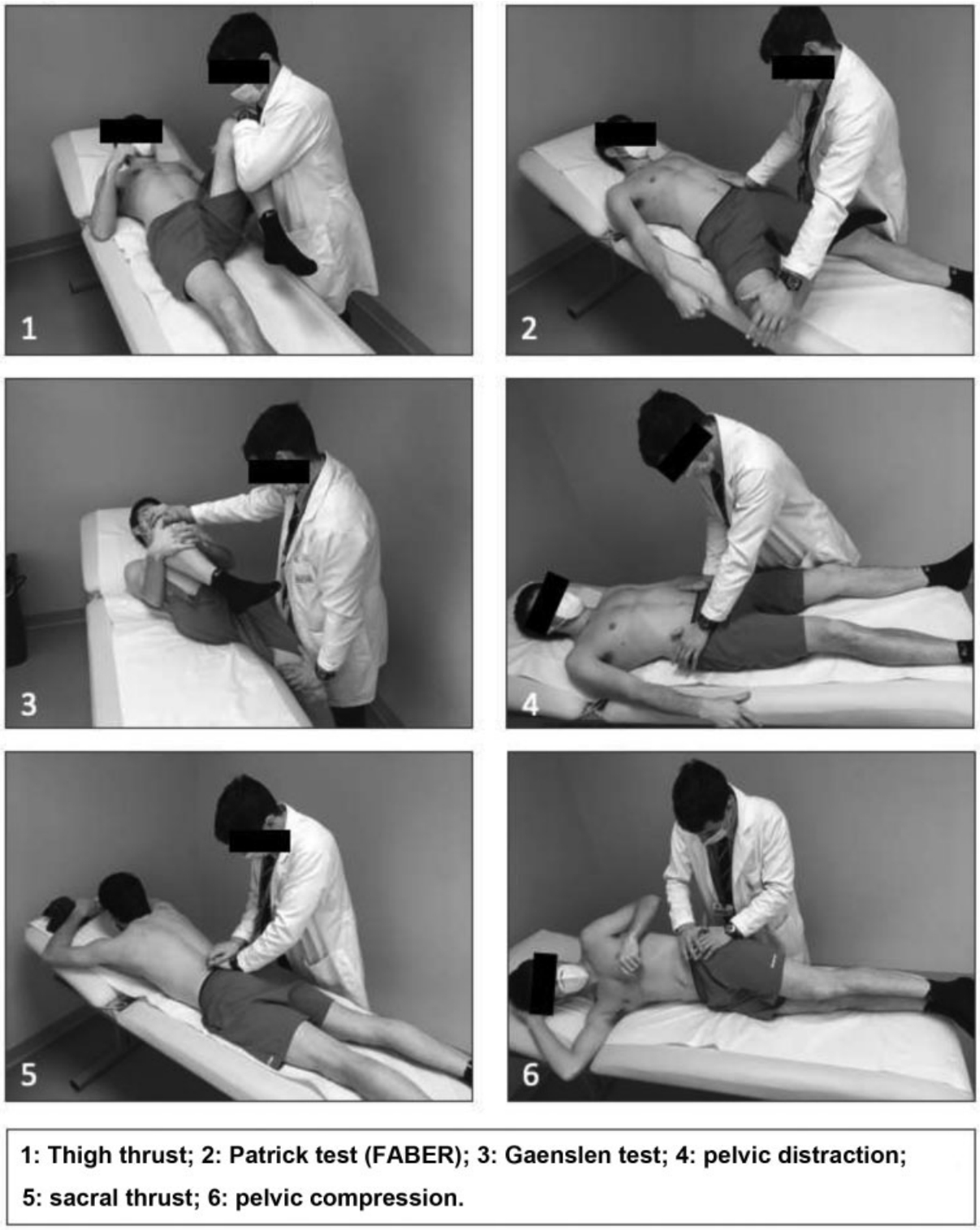

Fig. 3 Sacroiliac pain provocation tests. 1: Thigh thrust; 2: Patrick test (flexion, abduction, external rotation – FABER); 3: Gaenslen test; 4: pelvic distraction; 5: sacral thrust; 6: pelvic compression.

there is no quality evidence to support it. In case of alarming symptoms, including extreme age, chronic pain, disabling pain, recent trauma, neurological deficit, cancer history, and use of corticosteroids, an MRI scan must be requested according to the diagnostic suspicion, with higher sensitivity and specificity.[2] Magnetic resonance imaging scans enable a more precise evaluation of the SIJ, with early identification of inflammatory changes and structural alterations, especially in patients with hip spondylopathy.[39] Lumbar MRI is useful to search for a different source of pain.[24] Another imaging test

 © 2021. Sociedad Chilena de Ortopedia y Traumatologia. All rights reserved.

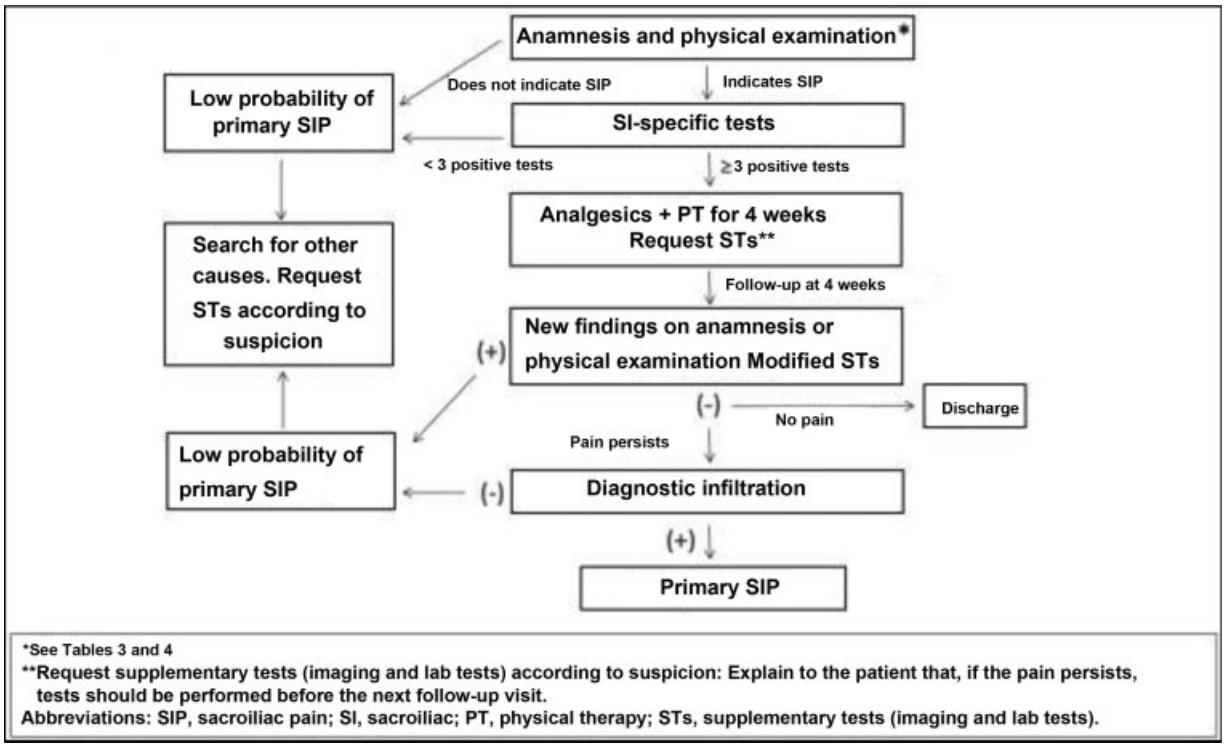

Fig. 4

used in the clinical practice is bone scintigraphy.[40] Since it shows the whole body, scintigraphy is useful in nonspecific conditions with broad diagnostic hypotheses. It has been described to be especially helpful in cases with no access to a diagnostic infiltration, or when the diagnosis is unclear; in addition, it may indicate a mechanical origin for the pain.[41]

Diagnostic Infiltration

Since imaging and specific sacroiliac provocation tests lack diagnostic precision, some cases require diagnostic infiltration, which is considered the gold standard for the diagnosis of SIP.[42] Diagnostic infiltration has several advantages. First, it enables the confirmation or exclusion of the source of pain, which in turn enables the examiner to determine if the patient would benefit from sacroiliac arthrodesis. In addition, it is a simple procedure with few complications. Lastly, not only it helps in the diagnosis, but it can play a therapeutic role. Despite the lack of quality evidence to warrant its use, therapeutic sacroiliac infiltration is performed with increasing frequency in the United States.[43]

To be effective and valid or interpretable, this procedure requires that two fundamental conditions are met: 1) the infiltration must be performed in the operating room with intraoperative radiography to assure, under direct visualization, the deposition of the anesthetic agent with contrast media in the intra-articular space, since blind punctures present a success rate as low as 22%;[44] and 2) the infiltration of a maximum volume of 1 mL to 1.5 mL of local anesthetic agent and corticosteroids, since larger volumes can diffuse into other territories and generate false-positive results.[8]

The procedure must be carried out with the proper technique.[45] First, specific tests are performed, and the patient is asked to rate the intensity of the pain evoked in each test from 1 to 100. The patient is then placed in prone position, and an anteroposterior radiograph is taken. The puncture is oriented toward the lower SIJ recess, 1 cm to 2 cm superior to the lowest aspect of the joint. The puncture is performed with the needle directed from medial to lateral, confirmed with oblique variations of the anteroposterior radiograph with cephalad, caudal, or lateral angulations. Once it has been confirmed that the tip of the needle is in

Table 6 Supplementary tests

Imaging
Sacroiliac magnetic resonance imaging
Lumbosacral magnetic resonance imaging
Hip magnetic resonance imaging
Pelvic and hip radiography
Lumbar spine radiography
Bone scintigraphy
Lab tests
General blood work: complete blood count, erythrocyte sedimentation rate, C-reactive protein, serum biochemistry panel, renal function
Rheumatological tests: human leukocyte antigen (HLA) B27, antinuclear antibody (ANA), extractable nuclear antibody (ENA), rheumatoid factor (RF), antibody anti-cyclic citrullinated peptide (CCP)

 © 2021. Sociedad Chilena de Ortopedia y Traumatologia. All rights reserved.

an intra-articular position in two orthogonal projections, the contrast media solution with the anesthetic agent is injected; the infiltration of the corresponding space with no leak is confirmed radiologically. Finally, the same specific tests are repeated, and the intensity of the pain in each test is recorded.

To minimize the number of diagnostic infiltrations, several authors[31,37] have proposed to perform them in patients with three or more positive provocation tests, since there is a low probability of a sacroiliac origin for the pain when less than three tests are positive. Postinjection pain provocation tests help to distinguish whether or not the pain is originated from the SIJ.[46] An infiltration is considered positive if the postprocedure pain relief exceeds 50% or even 75%[37,47]

Discussion

The clinical diagnosis of SIP is not easy due to its several etiologies and the complex anatomy of the joint. Adequate anamnesis and physical examination guide the diagnostic study, indicating different anatomical or systemic causes for SIP, and defining whether or not to perform sacroiliac tests. Such tests have been the subject of research due to their controversial diagnostic role.

In 1994, Fortin et al.[8,9] demonstrated the location pattern of SIP in two studies. In a later study, Fortin y Falco[12] described the "Fortin finger test" as a successful test for SIP diagnosis. However, some authors[34,48] have postulated that SIP provocation tests are more reliable than palpation. Robinson et al.,[34] in a 2007 study of 61 patients with suspected SIP, concluded that palpation tests have interexaminer agreement rates significantly lower than those of the provocation tests. On the other hand, the usefulness of SIP provocation tests performed in isolation has also been questioned due to their low specificity and sensitivity and high rate of false-positive results.[49,50] Until now, no maneuver alone reportedly had some diagnostic applicability, and several specific tests with various indicators of sensitivity, specificity and predictive values have been described.[10–13,34–36]

Several authors[13,34,37,51] have postulated that performing more than one test and interpreting a combination of tests would result in a reliable SIP diagnosis. In 2006, a study carried out by van der Wurff et al.[37] with 60 patients with a history of low back pain using articular blocks in symptomatic patients and pain provocation tests demonstrated that the performance of less than 3 positive tests had a high NPV (87%), while 3 or more specific positive provocation tests had a high PPV for SIP (from 65% to 93%). Kokmeyer et al.,[13] in a study with 78 patients, reached similar conclusions. The authors pointed out that if three out of a set of five pain provocation tests were negative, the NPV would be higher compared to an isolated test and present greater agreement between examiners. These last two studies enabled the validation of the clinical usefulness of specific sacroiliac tests, and it was concluded that they fulfill their role when performed together.

Sacroiliac tests must be correctly interpreted in each individual patient, according to the diagnostic suspicion suggested by the anamnesis and the physical examination. This is why proposing the performance of an anamnesis and systematic physical examination prior to specific tests is critical, for it enables the proper selection of patients with SIP who would benefit from more invasive procedures, such as infiltration. ►**Figure 4** shows an algorithm summarizing the diagnostic approach to low back pain in a context of suspected SIP. ►**Table 6** lists supplementary tests that can be requested according to the clinical suspicion.

Conclusion

Sacroiliac pain is an important cause of low back pain. It can result from several conditions, and it is often underdiagnosed. Its specific diagnosis is a challenge for doctors, so an orderly and sequential approach to these patients is essential. An accurate diagnosis requires a detailed anamnesis and physical examination to help rule out the main differential diagnoses. Several specific sacroiliac tests are useful in subjects with a clear suspicion of SIP, provided that other potential sources of pain are ruled out because they have a high rate of false-positive results. This is why the combined use of these tests optimizes their diagnostic performance, which may reach negative predictive values of up to 87%. Imaging is not usually required for the diagnosis, but it should be considered to investigate other causes of pain, especially in the presence of alarming signs. Diagnostic infiltration of the joint is the gold standard technique, and it must be reserved for patients in whom the suspicion of SIP persists. In addition, it can play both diagnostic and therapeutic roles in SIP.

Conflict of Interests
The authors have no conflict of interests to declare.

References

1 Miranda J, Quezada P, Caballero P, et al. Revisión Sistemática: Epidemiología de Dolor Crónico No Oncológico en Chile. El Dolor. 2013;59:10–17
2 Bilbeny N. Dolor Crónico en Chile. Rev Med Clin Las Condes 2019; 30:397–406
3 Diaz-Ledezma C, Urrutia J, Romeo J, Chelen A, González-Wilhelm L, Lavarello C. Factors associated with variability in length of sick leave because of acute low back pain in Chile. Spine J 2009;9(12): 1010–1015
4 Sembrano JN, Polly DW Jr. How often is low back pain not coming from the back? Spine 2009;34(01):E27–E32
5 Cher D, Polly D, Berven S. Sacroiliac joint pain: burden of disease. Med Devices (Auckl) 2014;7:73–81
6 Weksler N, Velan GJ, Semionov M, et al. The role of sacroiliac joint dysfunction in the genesis of low back pain: the obvious is not always right. Arch Orthop Trauma Surg 2007;127(10): 885–888
7 Dreyfuss P, Michaelsen M, Pauza K, McLarty J, Bogduk N. The value of medical history and physical examination in diagnosing sacroiliac joint pain. Spine 1996;21(22):2594–2602

 © 2021. Sociedad Chilena de Ortopedia y Traumatologia. All rights reserved.

8 Fortin JD, Dwyer AP, West S, Pier J. Sacroiliac joint: pain referral maps upon applying a new injection/arthrography technique. Part I: Asymptomatic volunteers. Spine 1994;19(13):1475–1482
9 Fortin JD, Aprill CN, Ponthieux B, Pier J. Sacroiliac joint: pain referral maps upon applying a new injection/arthrography technique. Part II: Clinical evaluation. Spine 1994;19(13): 1483–1489
10 Laslett M, Aprill CN, McDonald B, Young SB. Diagnosis of sacroiliac joint pain: validity of individual provocation tests and composites of tests. Man Ther 2005;10(03):207–218
11 Dreyfuss P, Cole AJ, Pauza K. Sacroiliac Joint Injection Techniques. Phys Med Rehabil Clin N Am 1995;6:785–813
12 Fortin JD, Falco FJ. The Fortin finger test: an indicator of sacroiliac pain. Am J Orthop 1997;26(07):477–480
13 Kokmeyer DJ, Van der Wurff P, Aufdemkampe G, Fickenscher TCM. The reliability of multitest regimens with sacroiliac pain provocation tests. J Manipulative Physiol Ther 2002;25(01):42–48
14 Boden SD, Davis DO, Dina TS, Patronas NJ, Wiesel SW. Abnormal magnetic-resonance scans of the lumbar spine in asymptomatic subjects. A prospective investigation. J Bone Joint Surg Am 1990; 72(03):403–408
15 Campos-Correia D, Sudoł-Szopińska I, Diana Afonso P. Are We Overcalling Sacroillitis on MRI? Differential diagnosis that every rheumatologist should know – Part II. Acta Reumatol Port 2019; 44(01):42–56
16 Puhakka KB, Melsen F, Jurik AG, Boel LW, Vesterby A, Egund N. MR imaging of the normal sacroiliac joint with correlation to histology. Skeletal Radiol 2004;33(01):15–28
17 Vleeming A, Schuenke MD, Masi AT, Carreiro JE, Danneels L, Willard FH. The sacroiliac joint: an overview of its anatomy, function and potential clinical implications. J Anat 2012;221 (06):537–567
18 Fortin JD, Tolchin RB. Sacroiliac arthrograms and post-arthrography computerized tomography. Pain Physician 2003;6(03): 287–290
19 Ares JDA, Amatriaín GR, González AP, Nieto C. Bloqueo y radiofrecuencia de la articulación sacroilíaca. Rev Soc Esp Dolor. 2012; 19:335–345
20 Le Huec JC, Tsoupras A, Leglise A, Heraudet P, Celarier G, Sturresson B. The sacro-iliac joint: A potentially painful enigma. Update on the diagnosis and treatment of pain from micro-trauma. Orthop Traumatol Surg Res 2019;105(1S):S31–S42
21 Kiapour A, Joukar A, Elgafy H, Erbulut DU, Agarwal AK, Goel VK. Biomechanics of the Sacroiliac Joint: Anatomy, Function, Biomechanics, Sexual Dimorphism, and Causes of Pain. Int J Spine Surg 2020;14(Suppl 1):3–13
22 Simons DG, Travell JG. Myofascial origins of low back pain. 1. Principles of diagnosis and treatment. Postgrad Med 1983;73 (02):66–77, 68–70, 73 passim
23 Molina M, Campos M, Delgado M. Lumbago: Revisión actualizada del diagnóstico, tratamiento y pronóstico. Rev Chil Ortop Traumatol. 2014;55:113–125
24 Thawrani DP, Agabegi SS, Asghar F. Diagnosing Sacroiliac Joint Pain. J Am Acad Orthop Surg 2019;27(03):85–93
25 Mitra R. Osteitis Condensans Ilii. Rheumatol Int 2010;30(03): 293–296
26 Ha K-Y, Lee J-S, Kim K-W. Degeneration of sacroiliac joint after instrumented lumbar or lumbosacral fusion: a prospective cohort study over five-year follow-up. Spine 2008;33(11): 1192–1198
27 Faundez AA, Richards J, Maxy P, Price R, Léglise A, Le Huec J-C. The mechanism in junctional failure of thoraco-lumbar fusions. Part II: Analysis of a series of PJK after thoraco-lumbar fusion to determine parameters allowing to predict the risk of junctional breakdown. Eur Spine J 2018;27(Suppl 1):139–148
28 Charles YP, Yu B, Steib J-P. Sacroiliac joint luxation after pedicle subtraction osteotomy: report of two cases and analysis of failure mechanism. Eur Spine J 2016;25(Suppl 1):63–74
29 Pozo P. Enfermedades reumatológicas más frecuentes en atención primaria: Espondiloartritis. En:Pacheco D, editor. Reumatología para médicos de Atención Primaria. Segunda edición. Chile: Tangram Ediciones; 2015:167–180
30 Slipman CW, Jackson HB, Lipetz JS, Chan KT, Lenrow D, Vresilovic EJ. Sacroiliac Joint Pain Referral Zones. 2000;81:334–338
31 Ou-Yang DC, York PJ, Kleck CJ, Patel VV. Diagnosis and Management of Sacroiliac Joint Dysfunction. J Bone Joint Surg Am 2017; 99(23):2027–2036
32 Correa-Illanes G. Dolor sacroilíaco: Epidemiología, fisiopatología, diagnóstico y tratamiento. Rehabil Integral. 2019;14:91–101
33 Martin RL, Sekiya JK. The interrater reliability of 4 clinical tests used to assess individuals with musculoskeletal hip pain. J Orthop Sports Phys Ther 2008;38(02):71–77
34 Robinson HS, Brox JI, Robinson R, Bjelland E, Solem S, Telje T. The reliability of selected motion- and pain provocation tests for the sacroiliac joint. Man Ther 2007;12(01):72–79
35 Werner CML, Hoch A, Gautier L, König MA, Simmen H-P, Osterhoff G. Distraction test of the posterior superior iliac spine (PSIS) in the diagnosis of sacroiliac joint arthropathy. BMC Surg 2013; 13:52–57
36 Stuber KJ. Specificity, sensitivity, and predictive values of clinical tests of the sacroiliac joint: a systematic review of the literature. J Can Chiropr Assoc 2007;51(01):30–41
37 van der Wurff P, Buijs EJ, Groen GJ. A multitest regimen of pain provocation tests as an aid to reduce unnecessary minimally invasive sacroiliac joint procedures. Arch Phys Med Rehabil 2006;87(01):10–14
38 Eno J-JT, Boone CR, Bellino MJ, Bishop JA. The prevalence of sacroiliac joint degeneration in asymptomatic adults. J Bone Joint Surg Am 2015;97(11):932–936
39 Poddubnyy D, Gaydukova I, Hermann K-G, et al. Magnetic resonance imaging compared to conventional radiographs for detection of chronic structural changes in sacroiliac joints in axial spondyloarthritis. J Rheumatol 2013;40(09):1557–1565
40 Zilber K, Gorenberg M, Rimar D, et al. Radionuclide Methods in the Diagnosis of Sacroiliitis in Patients with Spondyloarthritis: An Update. Rambam Maimonides Med J 2016;7(04):e0037
41 Maigne JY, Boulahdour H, Chatellier G. Value of quantitative radionuclide bone scanning in the diagnosis of sacroiliac joint syndrome in 32 patients with low back pain. Eur Spine J 1998;7 (04):328–331
42 Rupert MP, Lee M, Manchikanti L, Datta S, Cohen SP. Evaluation of sacroiliac joint interventions: a systematic appraisal of the literature. Pain Physician 2009;12(02):399–418
43 Manchikanti L, Hansen H, Pampati V, Falco FJE. Utilization and growth patterns of sacroiliac joint injections from 2000 to 2011 in the medicare population. Pain Physician 2013;16(04):E379–E390
44 Rosenberg JM, Quint TJ, de Rosayro AM. Computerized tomographic localization of clinically-guided sacroiliac joint injections. Clin J Pain 2000;16(01):18–21
45 Schwartz A, Zlomislic V, Reckling WC, Cher D. Sacroiliac Joint Pain: Pathophysiology and Diagnosis. En:Rothman RH, Simeone FA, Herkowitz HN, editores. Rothman-Simeone and Herkowitz's, The Spine. Seventh edition. Philadelphia, PA: Elsevier; 2018:383–396
46 Polly DW Jr. The Sacroiliac Joint. Neurosurg Clin N Am 2017;28 (03):301–312
47 Simopoulos TT, Manchikanti L, Singh V, et al. A systematic evaluation of prevalence and diagnostic accuracy of sacroiliac joint interventions. Pain Physician 2012;15(03):E305–E344
48 Potter NA, Rothstein JM. Intertester reliability for selected clinical tests of the sacroiliac joint. Phys Ther 1985;65(11):1671–1675

 © 2021. Sociedad Chilena de Ortopedia y Traumatologia. All rights reserved.

49 van der Wurff P, Hagmeijer RH, Meyne W. Clinical tests of the sacroiliac joint. A systematic methodological review. Part 1: Reliability. Man Ther 2000;5(01):30–36
50 Berthelot J-M, Labat J-J, Le Goff B, Gouin F, Maugars Y. Provocative sacroiliac joint maneuvers and sacroiliac joint block are unreliable for diagnosing sacroiliac joint pain. Joint Bone Spine 2006;73 (01):17–23
51 Young S, Aprill C, Laslett M. Correlation of clinical examination characteristics with three sources of chronic low back pain. Spine J 2003;3(06):460–465

 © 2021. Sociedad Chilena de Ortopedia y Traumatologia. All rights reserved.