

# A Rare Presentation of a Common Malignancy

K Pradeep Kumar Reddy<sup>1</sup> Jyosthna Elagandula<sup>1</sup> Runu Sharma<sup>1</sup> BS Ankit<sup>1</sup> Prakash G Chitalkar<sup>1</sup>

<sup>1</sup>Department of Medical Oncology, Sri Aurobindo Institute of Medical Sciences, Indore, Madhya Pradesh, India

**Address for correspondence** K Pradeep Kumar Reddy, MD (General Medicine), Room No. 215, Siddhant Hostel, Sri Aurobindo Institute of Medical, Sciences, Indore 453 555, Madhya Pradesh, India (e-mail: kpkreddy.medonco@gmail.com).

Ind J Med Paediatr Oncol 2021;42:108–109.

## Case History

A 50-year-old female without any comorbidities presented with a history of skin lesions over the face, trunk, and limbs (►Fig. 1) for 4 months with generalized weakness and weight loss over a period of 2 months. On examination, there were multiple erythematous skin lesions on the face that coalesced to form nodular plaque of varying sizes from 2 mm to 4 cm over the erythematous base with mild scaling and yellowish black crusting. She also had hyperpigmented macules over the trunk and limbs. Other findings were pallor and splenomegaly.

## Differential Diagnosis

- Pyoderma gangrenosum
- Vasculitis
- Drug reaction
- Urticaria
- Viral exanthem
- Hidradenitis
- Erythema multiforme
- Erythema nodosum
- Infections due to immunosuppression: cellulitis, herpes zoster, and herpes simplex

## Workup

Complete hemogram showed a total leukocyte count of 80,000/mm<sup>3</sup> along with shift to left. Peripheral smear examination showed blasts with increase in myeloid precursors and basophilia. Bone marrow aspirate revealed increased myeloid precursors with the presence of all the stages of maturation (myelocytes, metamyelocytes, and neutrophils). Blasts constituted around 86% of nucleated marrow cells.

Karyotyping and fluorescence in situ hybridization showed translocation t(9:22), confirming the diagnosis of chronic myeloid leukemia (CML). Skin biopsy showed diffuse blast cell infiltration in the superficial dermis (►Fig. 2A–D).

## Diagnosis

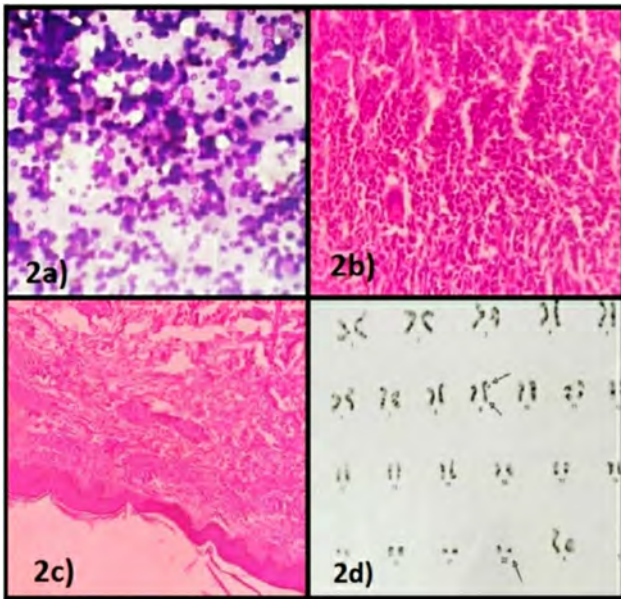
Based on the above investigations, she was diagnosed as a case of CML in blast crisis with leukemia cutis as an extramedullary deposit. CML in blast crisis has a dismal prognosis with a median survival of 9.4 months. Our patient finally succumbed to death after 4 months of presentation. This case emphasizes the fact that a high degree of suspicion and expertise is important for diagnosing such uncommon presentation of common malignancies. Hence, early diagnosis of such rarer presentations helps in appropriate treatment, which ultimately leads to better chance of survival and reduces the risk of fatality.

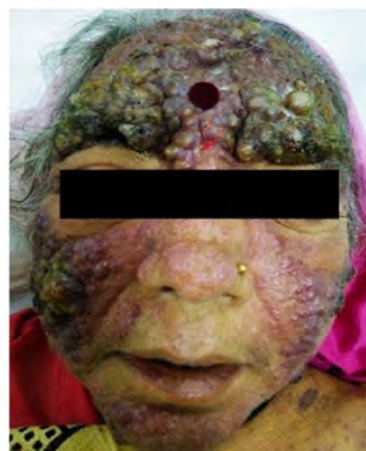

Fig. 1 Multiple nodular skin lesions over the face.

DOI <https://doi.org/10.1055/s-0041-1729438>  
ISSN 0971-5851

© 2021. Indian Society of Medical and Paediatric Oncology  
This is an open access article published by Thieme under the terms of the Creative Commons Attribution-NonDerivative-NonCommercial-License, permitting copying and reproduction so long as the original work is given appropriate credit. Contents may not be used for commercial purposes, or adapted, remixed, transformed or built upon. (<https://creativecommons.org/licenses/by-nc-nd/4.0/>).  
Thieme Medical and Scientific Publishers Pvt. Ltd. A-12, 2nd Floor, Sector 2, Noida-201301 UP, India



**Fig. 2** (a) Photomicrograph of bone marrow aspirate showing suppressed erythroid, myeloid, and megakaryocytic series and replaced by blast cells; (b) photomicrograph of bone marrow biopsy showing diffuse sheets of large blast cells; (c) photomicrograph of skin biopsy with dermis showing perivascular and diffuse infiltration by large blast cells; and (d) karyotype of bone marrow analysis showing a Philadelphia chromosome.

#### Disclaimer

The authors certify that they have obtained all appropriate patient consent forms. In the form, the legal guardian has given his consent for images and other clinical information to be reported in the journal. The guardian understands that names and initials will not be published and due efforts will be made to conceal identity, but anonymity cannot be guaranteed.

#### Financial Support and Sponsorship

Nil.

#### Conflict of Interest

None declared.