





Comparative Clinical Evaluation of Two Techniques of Arthroscopic Treatment of Partial Articular Rotator Cuff Tears*

Avaliação clínica comparativa de duas técnicas no tratamento artroscópico das lesões parciais articulares do manguito rotador

Guilherme do Val Sella¹  Luciana Andrade da Silva¹  Caio Santos Checchia¹
Hector Carmona Marmille¹ Cláudio Santili² Alberto Naoki Miyazaki¹

¹ Shoulder and Elbow Surgery Group, Department of Orthopedics and Traumatology, Faculty of Medical Sciences, Santa Casa de São Paulo, São Paulo, SP, Brazil

² Department of Orthopedics and Traumatology, Faculty of Medical Sciences, Santa Casa de São Paulo, São Paulo, SP, Brazil

Address for correspondence Luciana Andrade da Silva, Dra., Rua Estuário, 519 - Chácara Monte Alegre, São Paulo, SP, 04645-100, Brazil (e-mail: lucalu@terra.com.br).

Rev Bras Ortop 2021;56(6):726–732.

Abstract

Objectives To evaluate the clinical results of patients submitted to arthroscopic treatment of partial lesion of the articular part of the rotator cuff by transtendon suture techniques and after completing the lesion and to compare the postoperative recovery time of the two techniques.

Method Retrospective study based on the identification of all cases with partial lesion of the articular part of the rotator cuff submitted to arthroscopic treatment from October 1999 to December 2016 at the Shoulder and Elbow Group of our institution. Thirty-nine patients were included and divided into two groups: those who underwent the transtendon technique and those in whom the lesion was completed. The two groups were statistically similar. The respective medical records were analyzed as well as the identification of the applied technique, the postoperative results, and the related complications. The functional evaluation was performed using the score of the University of California at Los Angeles (UCLA).

Results There was no statistically relevant difference between the groups, with a mean UCLA score of 32, and no difference in the time required for rehabilitation.

Keywords

- ▶ rotator cuff
- ▶ arthroscopy
- ▶ treatment

* Study carried out in the Shoulder and Elbow Surgery Group of the Department of Orthopedics and Traumatology of the Faculty of Medical Sciences of Santa Casa de São Paulo, "Pavilhão Ferdinando Simonsen" (DOT - FCMSCSP) (Director: Professor Maria Fernanda Silber Caffaro), São Paulo/SP, Brazil.

received
June 6, 2019
accepted
December 1, 2020

DOI <https://doi.org/10.1055/s-0041-1729583>.
ISSN 0102-3616.

© 2021. Sociedade Brasileira de Ortopedia e Traumatologia. All rights reserved.

This is an open access article published by Thieme under the terms of the Creative Commons Attribution-NonDerivative-NonCommercial-License, permitting copying and reproduction so long as the original work is given appropriate credit. Contents may not be used for commercial purposes, or adapted, remixed, transformed or built upon. (<https://creativecommons.org/licenses/by-nc-nd/4.0/>)

Thieme Revinter Publicações Ltda., Rua do Matoso 170, Rio de Janeiro, RJ, CEP 20270-135, Brazil

Conclusion There was no difference between the clinical outcome of the patients, regardless of the technique used to repair the partial lesions of the articular part of the rotator cuff, with satisfactory results in 93% of the cases.

Resumo

Objetivos Avaliar os resultados clínicos dos pacientes submetidos ao tratamento artroscópico da lesão parcial da porção articular do manguito rotador pelas técnicas de sutura transtendão e após completada a lesão e comparar o tempo de recuperação pós-operatório das duas técnicas.

Método Estudo retrospectivo baseado na identificação de todos os casos com lesão parcial da porção articular do manguito rotador submetidos a tratamento artroscópico no período de outubro de 1999 a dezembro de 2016 pelo Grupo de Ombro e Cotovelo da nossa instituição. Foram incluídos 39 pacientes divididos em 2 grupos: os que foram submetidos à técnica transtendão e aqueles nos quais a lesão foi completada. Os dois grupos foram estatisticamente semelhantes. Foi realizada a análise dos respectivos prontuários, da identificação da técnica aplicada, dos resultados pós-operatórios e das complicações relacionadas. A avaliação funcional foi realizada através do escore da University of California at Los Angeles (UCLA).

Resultados Não houve diferença estatisticamente relevante entre os grupos, com escore UCLA médio de 32, não havendo diferença também no tempo necessário para reabilitação.

Conclusão Não houve diferença entre o resultado clínico dos pacientes, independente da técnica empregada para o reparo das lesões parciais da porção articular do manguito rotador com resultados satisfatórios em 93% dos casos.

Palavras-chave

- ▶ manguito rotador
- ▶ artroscopia
- ▶ tratamento

Introduction

Partial rotator cuff injury is recognized as an important cause of shoulder dysfunction and pain.¹ Its incidence is not yet consensus in literature, although there are several studies about it.²⁻⁴ Sher et al.,³ analyzing 96 asymptomatic shoulders by ultrasound, found 20% of partial lesions. By dissecting 249 shoulders of corpses, Lohr and Uhthoff² found 32% of partial injuries, while Fukuda⁵ found 13%. These authors described that around 1/3 (27%) of these lesions affect the joint part.

Ellman⁶ was the first to propose, based on arthroscopic findings, a partial lesion classification system in relation to its location (A, articular; B, bursal; C, intratendinous) and its extension (grade 1: < 3 mm; grade 2: 3–6 mm; grade 3: > 6 mm).

As for the pathophysiology of partial lesions of the articular part (PLAP) of the rotator cuff, it is believed that they can occur either with intrinsic mechanisms (area of hypovascularization and metabolic alterations related to age) and extrinsic (posterolateral superior internal impact, acute traumatic events, and recurrent microtraumas), or even a combination between them.⁷ Weinreb et al.,⁸ in 2014, published an article showing that there is evidence that intrinsic factors related to the tendon lead to the degeneration of its fibers in the articular face with tapering and disorientation of these, resulting in the anatomical injury of this region. Corroborating this evidence, Ozaki et al.⁹ did not find signs of subacromial impact in the articular lesions of the rotator cuff, so they exclude it as a possible cause for these lesions. Another mechanism that leads to PLAP of the

rotator cuff is found in pitchers, who can have a posterolateral superior internal impact.^{4,10}

The initial treatment for PLAP of the rotator cuff is performed with conservative measures, such as physiotherapy and change of habits to prevent the progression of the lesion.¹¹ Surgical treatment is indicated in the failure of conservative treatment and in cases in which the lesion takes up more than 50% of the tendon thickness, due to a higher risk of progression of the lesion; 40% of the PLAP of the rotator cuff evolve to complete lesions, according to Mall et al.¹² and Stuart et al.¹³

Different arthroscopic surgical techniques have been described to approach this type of lesion, from a simple arthroscopic debridement of the tendon, believing in its healing capacity (since performed in low-grade lesions¹⁴), to a transtendon repair of the lesion, initially described by Stephen Snyder,¹⁵ or even the disinsertion of the affected tendon area (“completing the lesion”) followed by its repair.¹⁶

The main objective of the present study is to evaluate the clinical results of patients submitted to arthroscopic treatment of PLAP of the rotator cuff by transtendon suture techniques and after the lesion is completed and to compare the postoperative recovery time of the two techniques.

Casuists and Methods

From October 1999 to December 2016, 39 patients with diagnosis of PLAP of the rotator cuff underwent arthroscopic

surgical treatment performed by the Shoulder and Elbow Group of the Department of Orthopedics and Traumatology of our institution.

The patients, all with partial joint lesion of the supraspinal muscle tendon, were divided into two groups: group I, those who underwent transtendon repair, and group II, patients submitted to treatment with repair after turning the partial lesion into complete.

The inclusion criteria were patients diagnosed with PLAP of the rotator cuff, performed by means of magnetic resonance imaging (MRI) in the preoperative period, submitted to arthroscopic treatment, and who had minimal follow-up ≥ 2 years.

In group I, there were 19 patients with mean follow-up of 4.61 years. Thirteen of these patients were male (68%) and 6 were female. The mean age was 48 years, ranging from 34 to 70 years. The dominant side was affected in 73% of the cases; 16 patients (84%) practiced sports and 9 patients (47%) reported traumatic event as triggering the condition.

Group II had 20 patients with mean follow-up of 4.35 years. Eleven of these were male (55%) and 9 were female. The mean age was 52 years, ranging from 29 to 75 years. The dominant side was affected in 85% of the cases, 11 patients (55%) practiced sports and only 3 patients reported a traumatic event.

There were no statistically significant differences between the samples in relation to age, gender, and affected limb, and in 78% of the cases, the dominant side was affected. All patients were submitted to the surgical procedure in beach chair position, under general anesthesia associated with anesthetic block

of the brachial plexus. Articular arthroscopic inspection was performed, followed by subacromial inspection and partial bursectomy. In group I, seven patients presented SLAP-type lesion, two with arthrosis of the acromioclavicular joint, one with major tubercle fracture, already consolidated and which was treated conservatively, one patient with long biceps head injury and one patient with Bankart injury. In group II, six patients presented SLAP-type lesions, four had rupture of the long head of the biceps, and three had arthrosis of the acromioclavicular joint. From this point, the techniques differ: in group I patients, the wires of the anchors were passed through the transtendon, through the joint space to the bursal surface, following with the repair. When we opted for this type of repair, we increased the pressure of the serum infusion pump to close to 80 mmHg, which causes the joint space to increase and the tendon to lift from its insertion bed and allows intra-articular visualization of the passage of the anchors from subacromial to intra-articular and its correct positioning in the so-called *footprint*. Once the anchor is fixed, a wire is caught with *birdbick* tweezers and passed through the tendon at a point of tissue considered healthy, that is, outside of the lesion area. We return the pump pressure to normal value, to avoid an exaggerated and rapid edema that prevents the rest of the surgery. Then, the optics are positioned again in the subacromial space, and the wires are tied with simple sliding points. The procedure is repeated as many times as deemed necessary (→ **Figure 1**). In group II patients, the disinsertion of the bursal fibers, which remained intact, was performed, transforming it into a complete lesion, followed by repair through the passage of

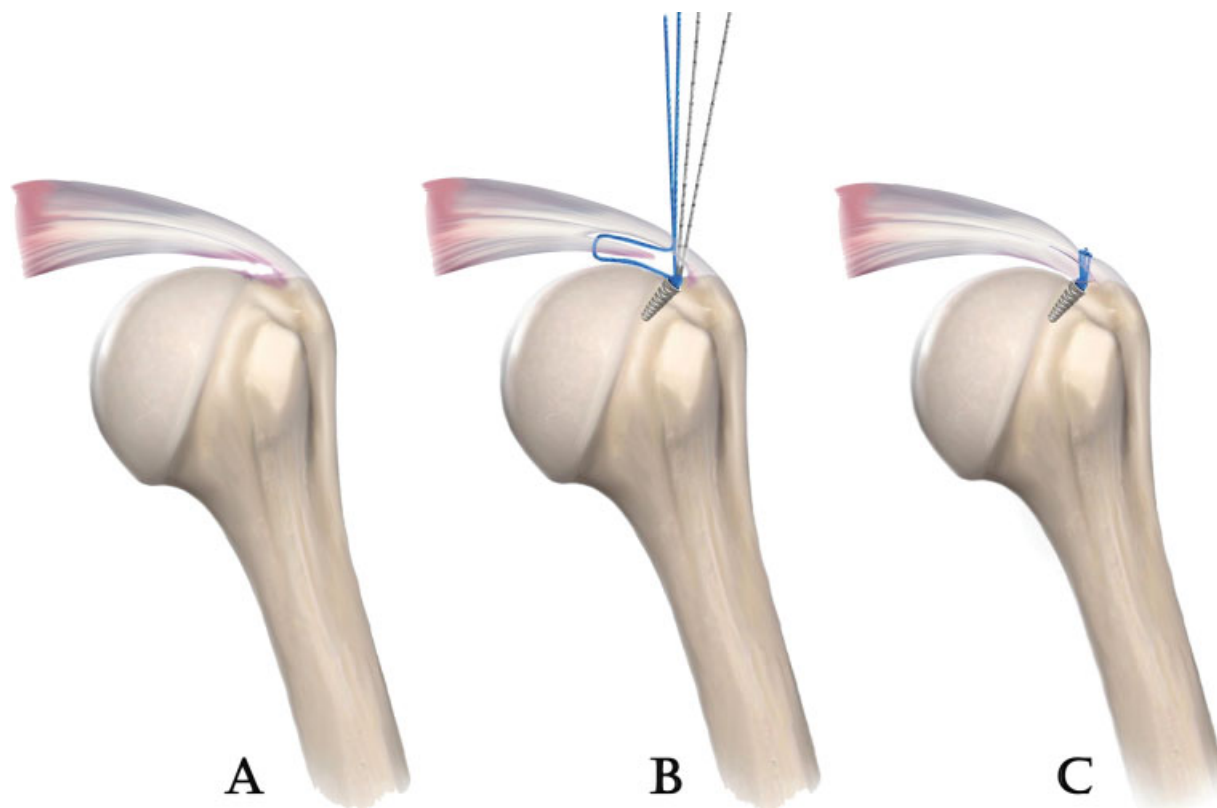


Fig. 1 Transtendon repair of the partial joint lesion of the supraspinal muscle tendon. A - Representation of partial joint injury, B - Way of passage of suture threads according to this technique, C - Sutured lesion.

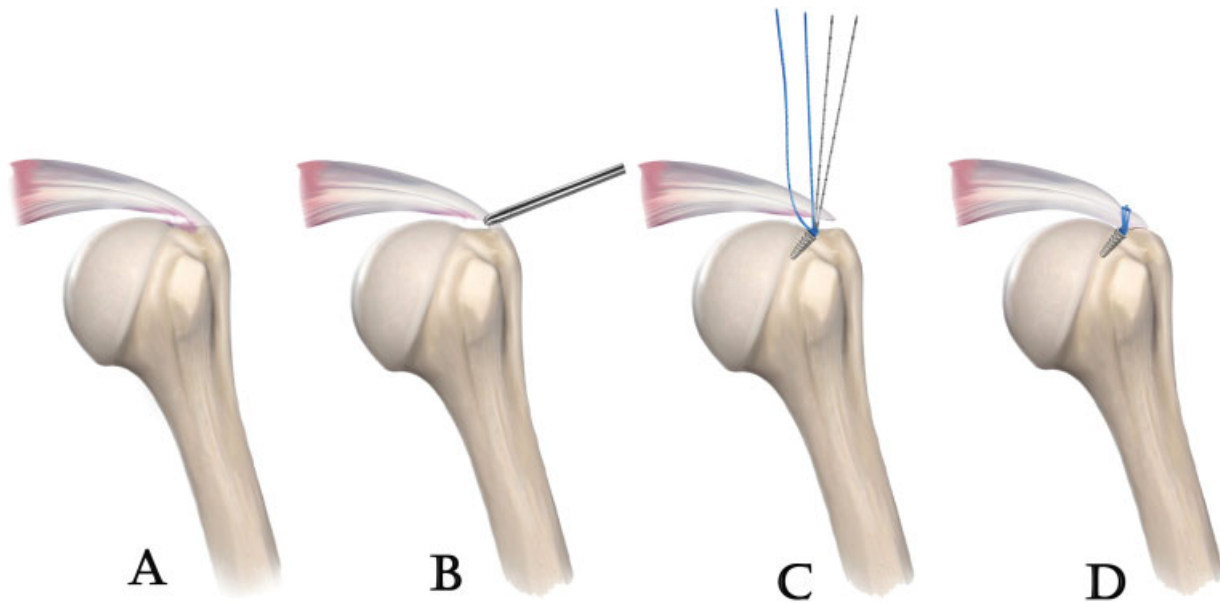


Fig. 2 Repair after transforming the partial lesion into complete in the partial joint lesion of the supraspinal muscle tendon. A - Representation of partial joint injury, B - Partial lesion being completed, C - Way of passage of suture threads in the lesion already completed, D - Sutured lesion.

the suture threads through the bursal face (►Figure 2). All of them were repaired by simple points technique via arthroscopy.

In the postoperative period, the patients were immobilized with functional sling between 4 and 6 weeks, continuing rehabilitation.

The amplitude of the range of motion was evaluated by measuring elevation, lateral and medial rotations. Clinical evaluation was performed using the University of California at Los Angeles (UCLA) score.¹⁷ To evaluate the recovery time, we used the comparison of the time that patients in both groups took to reach their “maximum” value of the UCLA score,¹⁷ per specific statistical test listed below.

Initially, a descriptive analysis was performed with calculation of the percentage distribution for each variable. The qualitative variables (gender, dominance, sport, intra and postoperative capsulitis) were analyzed by the chi-Squared independence test, when the hypotheses of independence of the sample were respected, and by Fisher exact test when not respected. The quantitative and qualitative ordinal variables (elevation, medial and lateral rotations, pre- and postoperative, follow-up time, UCLA value and UCLA time) were analyzed by the Mann-Whitney nonparametric test, when the distribution did not adhere to the normal distribution, and by the F-test, when there was adherence to the normal distribution, followed by analysis of the equality of means by Student t-test.

The analyses were performed using the statistical software Minitab (Minitab, LLC, State College, PA, USA), v.17. All hypotheses with descriptive levels (*p*-value) lower than 0.05 were rejected, which was the level of significance adopted.

The study was submitted to the Research Ethics Committee and approved according to CAEE: 79428617.2.0000.5479.

Results

Using the UCLA score,¹⁷ group I had 9 excellent results (42%), 8 good results (38%), and 2 unsatisfactory results (►Table 1).

The mean time for rehabilitation was 6 months, postoperative range of motion with an average elevation of 142° (110–160°), lateral rotation of 59° (45–70°), and medial rotation of T8 (T3–L5).

In group II, we had 5 excellent results (25%), 14 good results (70%), and an unsatisfactory result (►Table 2). The mean time for rehabilitation was 5.2 months, postoperative range of motion with an average elevation of 146° (130–160°), lateral rotation of 56° (45–70°), and medial rotation of T8 (T5–L2).

As a complication, we had two cases of adhesive capsulitis, one in each group. The patient in group I underwent arthroscopic release after 8 months of repair of the lesion reaching a UCLA¹⁷ score of 33 after 1 year. The patient in group II showed improvement after performing suprascapular nerve blocks and physiotherapy, reaching a UCLA¹⁷ score of 33 7 months postoperatively.¹⁸

After the statistical analysis, there was no difference between the average UCLA¹⁶ score for both groups, with a result of 32, ranging in group I from 22 to 35, and in group II from 23 to 35. In the analysis of the time required to achieve the result of UCLA,¹⁷ there was a difference of 3 weeks in the mean, but without statistical relevance, with a *p*-value = 0.336.

Discussion

Surgical treatment for PLAP of the rotator cuff is indicated in the failure of conservative treatment and, commonly, in cases in which the lesion affects more than 50% of the tendon fibers,¹³ due to a 40% risk in progression to complete injury, as described by Mall et al.¹² Mazzoca et al.¹⁹ also demonstrated in cases with more than 50% of injury to the tendon fibers, the remaining tendon presents an increase in its tension, which would lead to its eventual complete rupture.

In the operative act, PLAP of the rotator cuff can be approached in two ways in relation to the tendon: either

Table 1 Clinical data of patients undergoing transtendon repair

Nr. of patients	Gender	Age	Dominant side	Δtt	UCLA	Δt	COMPLICATIONS
1	F	50		03 a.	TOTAL:35	4 m	
2	M	70		02 a.	TOTAL: 35	5 m	
3	F	49	+	03 a.	TOTAL: 35	5 m	
4	F	39	+	02 a.	TOTAL: 35	5 m	
5	M	51	+	03 a.	TOTAL: 35	4 m	
6	M	43	+	07 a.	TOTAL: 22	9 m	
7	M	49	+	02 a.	TOTAL: 35	4 m	
8	M	40	+	09 a.	TOTAL: 32	6 m	
9	M	34	+	2 a.	TOTAL: 35	5 m	
10	M	44	+	09 a.	TOTAL: 32	4 m	
11	F	56		09 a.	TOTAL: 31	5 m	
12	M	41	+	12 a.	TOTAL: 34	4 m	
13	F	54	+	02 a.	TOTAL: 32	9 m	
14	M	52	+	09 a.	TOTAL: 31	8 m	
15	M	58		04 a.	TOTAL: 23	10 m	
16	M	59	+	09 a.	TOTAL: 34	5 m	
17	F	53		05 a.	TOTAL: 33	6 m	
18	M	44	+	05 a.	TOTAL: 33	4 m	
19	M	35	+	07 a.	TOTAL: 33	12 m	REVIEW FOR RELEASE WITH 8 MONTHS DUE TO CAPSULITIS

Abbreviations: a: years; F: female; m: months; M: male; Δt: time for rehabilitation; Δtt: postoperative follow-up time; UCLA, University of California at Los Angeles.

by maintaining its integrity in the insertion—a technique known as transtendon fixation of the lesion—or by a second technique in which there is complete disinsertion of the remaining fibers, transforming it into a complete lesion.

Studies such as those by Sethi et al.²⁰ and Mihata et al.²¹ show biomechanical advantages of transtendon repair. In this technique, the bursal (intact and uninjured) and articular (containing the lesion) fibers are sutured separately (→ **Figure 1**), which provides less tension at the end of the suture in the bursa fibers, in addition to a larger contact surface in the insertion area. But as observed by Shin,²² these patients present a more painful postoperative period and a slower recovery of the range of motion, which could be related to lesions with great retraction of the affected joint part, with an unbalance between the fibers repaired and those that were kept intact. In our study, we observed that patients in group I took 1 month longer, on average, to recover and reach the final UCLA¹⁷ than patients in group II, but this difference was not statistically significant.

Shin²² also mentions that the disinsertion of the entire lateral margin of the rotator cuff, by turning the partial lesion into complete, can lead to the risk of non-anatomical repair, altering the biomechanics and thus resulting in an early degeneration of the tendon. However, in our opinion, as in Shin's,²² such a maneuver allows a better view and facilitates repair due to greater familiarity with the technique.^{11,20} Although good functional result is not a specific factor for

knowing whether or not there was anatomical repair of the lesion, we did not suspect any important biomechanical alteration, since patients in group II presented good postoperative evolution, with return of the usual activities, as found in the study by Godinho et al.,²³ who obtained 100% satisfaction and good/excellent results with the technique.

There is no consensus in the literature on the best technique for repairing this type of lesion. The comparative works between the two techniques, such as those of Shin,²² Ono et al.,²⁴ and Castagna et al.,¹⁶ do not present statistically significant differences among them, presenting similar results in the postoperative period, with the same healing rate, re-ruptures, and results. Our study demonstrates that both techniques enable good results, without statistical differences when evaluating the UCLA score¹⁷ between the two groups, with a p -value = 0.321, including similar postoperative rehabilitation time, with p -value = 0.336.

Despite the good result obtained with both techniques, we had in our study three cases with unsatisfactory results, two from group I and one from group II. In group I, the 1st patient was 43 years old, a non-professional tennis player with injury affecting the dominant side and with symptoms presenting for about 20 years. With good preoperative mobility (140°, 80°, T3), he evolved with a loss in the postoperative period of 110°, 45° and L5, which remained. It evolved with the patient presenting pain when doing low-intensity work, with the patient being able to perform all

Table 2 Clinical data of patients submitted to repair after the injury was completed

Case	Sex	Age	Dominant side	Δtt	UCLA	Δt	COMPLICATIONS
1	M	58	+	02 a.	TOTAL: 32	6 m	
2	F	63	+	02 a, 10 m	TOTAL: 31	5 m	
3	F	65	+	02 a.	TOTAL: 32	4 m	
4	F	67	+	02 a.	TOTAL: 33	5 m	
5	M	75		03 a.	TOTAL: 34	4 m	
6	F	57		05 a.	TOTAL: 34	6 m	
7	M	39	+	08 a.	TOTAL: 32	6 m	
8	F	73	+	05 a.	TOTAL: 35	5 m	
9	F	59	+	02 a.	TOTAL: 32	5 m	
10	M	43	+	04 a.	TOTAL: 32	7 m	
11	M	38	+	02 a.	TOTAL: 33	7 m	
12	F	29	+	11 a.	TOTAL: 34	4 m	
13	M	44		13 a.	TOTAL: 23	6 m	
14	M	42	+	02 a.	TOTAL: 32	5 m	
15	F	51		08 a.	TOTAL: 33	4 m	
16	M	39	+	06 a.	TOTAL: 32	4 m	
17	M	49	+	02 a.	TOTAL: 33	4 m	
18	M	51	+	03 a.	TOTAL: 32	5 m	
19	M	56	+	03 a.	TOTAL: 33	7 m	CAPSULITIS AFTER 3 MONTHS, PERFORMING BLOCKS AND PHYSIOTHERAPY.
20	F	47	+	02 a.	TOTAL: 35	5 m	

Abbreviations: a: years; F: female; m: months; M: male; Δt: time for rehabilitation; Δtt: postoperative follow-up time; UCLA, University of California at Los Angeles.

domestic activities, but with limitation in movements above the shoulder line (grade IV strength). The second case of group I was a 58-year-old patient, a non-professional swimmer, presenting symptoms in the non-dominant side for 3 years. Good pre and postoperative range of motion, without limitation. He also developed pain to light work, with grade IV loss of strength above the shoulder. After all, the two said they are satisfied with the result. The case of group II was a 44-year-old patient with no history of sports practice, presenting symptoms for 1 year. Preoperative range of motion 160°, 70°, T7. It evolved postoperatively with pain to low-intensity work, and slight decrease in elevation and lateral rotation, without loss of strength. However, he is dissatisfied with the result due to the persistence of pain. What caught our attention in all three cases is that we did not find an objective cause for the maintenance of pain. All patients' imaging showed normal healing of the lesion.

Conclusion

Both the transtendinous suture and suture after completing the lesion led to satisfactory results in 93% of the patients in our series. We did not find a statistically significant difference in rehabilitation time between the two groups.

Financial Support

There was no financial support from public, commercial, or non-profit sources.

Conflict of Interests

The authors declare that there is no conflict of interests.

References

- 1 Stuart KD, Karzel RP, Ganjianpour M, Snyder SJ. Long-term outcome for arthroscopic repair of partial articular-sided supraspinatus tendon avulsion. *Arthroscopy* 2013;29(05):818–823
- 2 Loehr JF, Uhthoff HK. The pathogenesis of degenerative rotator cuff tears. *Orthop Trans* 1987;11:237–243
- 3 Sher JS, Uribe JW, Posada A, Murphy BJ, Zlatkin MB. Abnormal findings on magnetic resonance images of asymptomatic shoulders. *J Bone Joint Surg Am* 1995;77(01):10–15
- 4 Hawi N, Liodakis E, Garving C, Habermeyer P, Tauber M. Pulley lesions in rotator cuff tears: prevalence, etiology, and concomitant pathologies. *Arch Orthop Trauma Surg* 2017;137(08):1097–1105
- 5 Fukuda H. Partial-thickness rotator cuff tears: a modern view on Codman's classic. *J Shoulder Elbow Surg* 2000;9(02):163–168
- 6 Ellman H. Diagnosis and treatment of incomplete rotator cuff tears. *Clin Orthop Relat Res* 1990;(254):64–74
- 7 Finnan RP, Crosby LA. Partial-thickness rotator cuff tears. *J Shoulder Elbow Surg* 2010;19(04):609–616

- 8 Weinreb JH, Sheth C, Apostolakis J, et al. Tendon structure, disease, and imaging. *Muscles Ligaments Tendons J* 2014;4(01):66–73
- 9 Ozaki J, Fujimoto S, Nakagawa Y, Masuhara K, Tamai S. Tears of the rotator cuff of the shoulder associated with pathological changes in the acromion. A study in cadavera. *J Bone Joint Surg Am* 1988;70(08):1224–1230
- 10 Carvalho CD, Cohen C, Belangero PS, et al. Lesão parcial do manguito rotador no atleta – bursal ou articular? *Rev Bras Ortop* 2015;50(04):416–421
- 11 Kim YS, Lee HJ, Bae SH, Jin H, Song HS. Outcome comparison between in situ repair versus tear completion repair for partial thickness rotator cuff tears. *Arthroscopy* 2015;31(11):2191–2198
- 12 Mall NA, Kim HM, Keener JD, et al. Symptomatic progression of asymptomatic rotator cuff tears: a prospective study of clinical and sonographic variables. *J Bone Joint Surg Am* 2010;92(16):2623–2633
- 13 Stuart KD, Karzel RP, Ganjianpour M, Snyder SJ. Long-term outcome for arthroscopic repair of partial articular-sided supraspinatus tendon avulsion. *Arthroscopy* 2013;29(05):818–823
- 14 Veado MAC, Bertolini FM, Almeida Filho IA. Eficácia do desbridamento artroscópico nas lesões parciais do manguito rotador. *Rev Bras Ortop* 2006;41(1/2):22–28
- 15 Snyder SJ. Arthroscopic repair of partial articular supraspinatus tendo avulsion: Pasta lesion of the rotator cuff tendon. In: *Shoulder arthroscopy*. Philadelphia: Lippincott Williams & Wilkins; 2003: 219–229
- 16 Castagna A, Borroni M, Garofalo R, et al. Deep partial rotator cuff tear: transtendon repair or tear completion and repair? A randomized clinical trial. *Knee Surg Sports Traumatol Arthrosc* 2015;23(02):460–463
- 17 Ellman H, Hanker G, Bayer M. Repair of the rotator cuff. End-result study of factors influencing reconstruction. *J Bone Joint Surg Am* 1986;68(08):1136–1144
- 18 Checchia SL, Fregoneze M, Miyazaki AN, et al. Tratamento da capsulite adesiva com bloqueios seriados do nervo supra-escapular. *Rev Bras Ortop* 2006;41(07):245–252
- 19 Mazzocca AD, Rincon LM, O'Connor RW, et al. Intra-articular partial-thickness rotator cuff tears: analysis of injured and repaired strain behavior. *Am J Sports Med* 2008;36(01):110–116
- 20 Sethi PM, Rajaram A, Obopilwe E, Mazzocca AD. Partial articular-sided rotator cuff tears: in situ repair versus tear completion prior to repair. *Orthopedics* 2013;36(06):771–777
- 21 Mihata T, McGarry MH, Ishihara Y, et al. Biomechanical analysis of articular-sided partial-thickness rotator cuff tear and repair. *Am J Sports Med* 2015;43(02):439–446
- 22 Shin SJ. A comparison of 2 repair techniques for partial-thickness articular-sided rotator cuff tears. *Arthroscopy* 2012;28(01):25–33
- 23 Godinho GG, França FO, Freitas JMA, et al. Avaliação funcional a longo prazo do tratamento videoartroscópico das lesões parciais do manguito rotador. *Rev Bras Ortop* 2015;50(02):200–205
- 24 Ono Y, Woodmass JM, Bois AJ, Boorman RS, Thornton GM, Lo IK. Arthroscopic Repair of Articular Surface Partial-Thickness Rotator Cuff Tears: Transtendon Technique versus Repair after Completion of the Tear-A Meta-Analysis. *Adv Orthop* 2016;2016:7468054