




Correlation Between Implant Positioning and Functional Outcomes in Partial Shoulder Resurfacing

Correlação entre posicionamento do implante das artroplastias parciais de recobrimento do ombro e os resultados funcionais

Gilberto Daniel Luz¹ Amanda S. Cavalcanti² Júlio Ferreira¹ Eduardo Godoy¹
 Marcus Vinicius Galvão Amaral¹ Geraldo da R. Motta Filho¹ 

¹Shoulder and Elbow Surgery Center (CCOC), Instituto Nacional de Traumatologia e Ortopedia (INTO), Rio de Janeiro, RJ, Brazil

²Research Division, Instituto Nacional de Traumatologia e Ortopedia (INTO), Rio de Janeiro, RJ, Brazil

Address for correspondence Geraldo da Rocha Motta Filho, MD, MSc, Rua Raimundo de Magalhães, 92, Rio de Janeiro, RJ, 22451-150, Brazil (e-mail: geraldomotta@terra.com.br).

Rev Bras Ortop 2022;57(3):480–487.

Abstract

Objective The present study aimed to correlate functional outcomes and implant positioning in a case series of partial shoulder resurfacing arthroplasties.

Methods A total of 25 patients were assessed for range of motion, functional outcome per the University of California at Los Angeles (UCLA) score and radiographic findings. Pre- and postoperative data were compared. In addition, patients were grouped according to the cervical-diaphyseal angle (CDA) determined by an anteroposterior radiography and to the retroversion angle (RVA) determined by an axillary radiography. A CDA from 130° to 140° and a RVA from 20° to 40° consisted in ideal positioning (anatomical standard). Data were analyzed using the Wilcoxon signed-rank test, analysis of variance (ANOVA) followed by the Kruskal-Wallis test or the Mann-Whitney test as appropriate.

Results The mean follow-up time was 48.3 months (12 to 67 months). The postoperative functional score (31.5) was higher than the preoperative score (15.5) ($p < 0.001$). In 6 patients, the implant was in anatomical positioning, while implant positioning was considered “nonstandard” in 19 subjects. Seven patients had a CDA $< 130^\circ$, and 14 patients had a CDA ranging from 130° to 140°; in addition, the CDA was $> 140^\circ$ in 4 subjects. The RVA was up to 20° in 15 patients and ranged from 20° to 40° in 10

Keywords

- ▶ arthroplasty, replacement, shoulder
- ▶ shoulder joint
- ▶ shoulder prosthesis
- ▶ prosthesis design

The present study was developed at the Shoulder and Elbow Surgery Center (CCOC, in the Portuguese acronym), Instituto Nacional de Traumatologia e Ortopedia (INTO, in the Portuguese acronym), Rio de Janeiro, RJ, Brazil.

received

July 29, 2020

accepted

January 8, 2021

published online

March 11, 2022

DOI <https://doi.org/10.1055/s-0041-1729589>

ISSN 0102-3616.

© 2022. Sociedade Brasileira de Ortopedia e Traumatologia. All rights reserved.

This is an open access article published by Thieme under the terms of the Creative Commons Attribution-NonDerivative-NonCommercial-License, permitting copying and reproduction so long as the original work is given appropriate credit. Contents may not be used for commercial purposes, or adapted, remixed, transformed or built upon. (<https://creativecommons.org/licenses/by-nc-nd/4.0/>)

Thieme Revinter Publicações Ltda., Rua do Matoso 170, Rio de Janeiro, RJ, CEP 20270-135, Brazil

subjects. Using these criteria to group patients, the postoperative clinical-functional parameters were not statistically different from the preoperative findings ($p > 0.05$).

Conclusion Partial shoulder resurfacing results in significant postoperative functional recovery in patients with degenerative joint diseases. However, implant positioning assessed by CDA and RVA does not correlate with clinical-functional outcomes and, therefore, it is an inaccurate indicator of surgical success.

Level of Evidence IV; Case Series.

Resumo

Objetivo O objetivo do presente estudo é correlacionar os resultados funcionais de uma série de casos de artroplastias parciais de recobrimento do ombro com o posicionamento do implante.

Métodos Um total de 25 pacientes foram avaliados em relação à amplitude de movimentos, à avaliação funcional pelo escore de Universidade da Califórnia Los Angeles (UCLA) e por análise radiográfica. Os dados pré- e pós-operatórios foram comparados. Adicionalmente, os pacientes foram agrupados quanto ao ângulo cervico-diafisário (ACD) avaliado na radiografia em anteroposterior e quanto ao ângulo de retroversão (ARV) avaliado na radiografia em posição axilar. Foi considerado como posicionamento ideal (padrão anatômico) um ACD entre 130° e 140° e um ARV entre 20° e 40° . Os dados foram analisados pelo teste pareado de Wilcoxon, pela análise de variância (ANOVA, na sigla em inglês) seguida pelo pós-teste de Kruskal-Wallis ou pelo teste de Mann-Whitney, quando apropriado.

Resultados O seguimento médio foi de 48,3 meses (12 a 67 meses). A avaliação funcional pós-operatória (31,5) foi melhor do que a pré-operatória (15,5) ($p < 0,001$). Seis pacientes apresentaram posicionamento anatômico do implante, enquanto 19 pacientes foram considerados “fora do padrão.” Sete pacientes apresentaram um ACD $< 130^\circ$, quatorze apresentaram um ACD entre 130° e 140° , e quatro apresentaram um ACD $> 140^\circ$. Quinze pacientes apresentaram um ARV $\leq 20^\circ$, e 10 entre 20° e 40° . Utilizando esses critérios para agrupar os pacientes, a comparação dos parâmetros da avaliação clínico-funcional pós-operatória não foi estatisticamente diferente ($p > 0,05$).

Conclusão A artroplastia parcial de recobrimento do ombro oferece significativa recuperação funcional pós-operatória em pacientes com doenças degenerativas articulares. Entretanto, o posicionamento do implante avaliado pelos ACD e ARV não se correlaciona com o resultado clínico-funcional, sendo, portanto, uma medida imprecisa de sucesso da cirurgia.

Nível de Evidência IV, Série de Casos.

Palavras-chave

- ▶ artroplastia do ombro
- ▶ articulação do ombro
- ▶ prótese de ombro
- ▶ desenho de prótese

Introduction

The general goal of shoulder arthroplasty is to restore joint mechanics and function. This is achieved through proper balance of soft parts, correct implant selection, and restoration of joint anatomical parameters.¹

Partial shoulder resurfacing arthroplasties show functional outcomes equivalent to those obtained with conventional hemiarthroplasties, with the advantage of preserving bone stock, reducing fracture risk, and causing less surgical trauma, resulting in better postoperative recovery and less pain.²⁻⁴ In addition, it provides accurate anatomy reestablishment and corrects humeral articular surface offset, retroversion and inclination, improving the lever arm of

the deltoid muscle and rotator cuff.⁵ However, data from the largest registry of shoulder arthroplasties reveal that partial resurfacing procedures account for only 3% of the total number of shoulder replacements, in contrast to 9.5% for conventional hemiarthroplasties.⁶

The present study aimed to correlate the functional outcomes of partial shoulder resurfacing arthroplasties with radiographic positioning of the implants.

Material and Methods

Study Type and Patient Selection Criteria

This was a retrospective analysis of a case series of patients submitted to partial shoulder resurfacing arthroplasty from

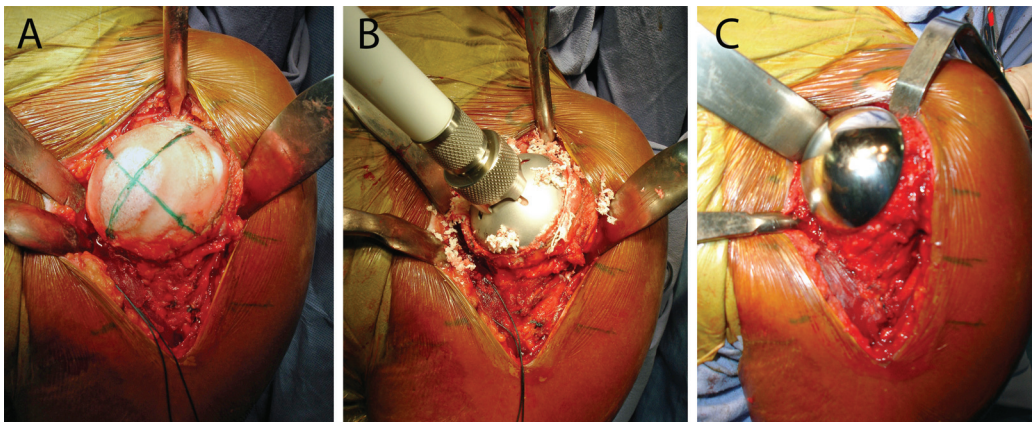


Fig. 1 Partial shoulder resurfacing arthroplasty. (A) Joint exposure. (B) Humeral head milling. (C) Global CAP prosthesis component insertion (DePuy, Warsaw, Indiana, USA).

January 2008 to December 2012 at a tertiary hospital from the Brazilian Unified Health System (SUS, in the Portuguese acronym). All 25 patients identified at the institutional Arthroplasty Registry were included in the study. The exclusion criteria were patients who underwent a resurfacing arthroplasty associated with a procedure for glenoid treatment, shoulder arthroplasty using a humeral component with nails, and those who did not agree to voluntary participation in the research. The present study was approved by the institutional Research Ethics Committee under CAAE number 26207914.0.0000.5273.

Surgical Technique

All patients were submitted to the same surgical technique, consisting of a deltopectoral approach, subscapular tenotomy for joint exposure and its trans-osseous reattachment at the end of the procedure. All cases received a Global CAP prosthesis (DePuy, Warsaw, Indiana, USA) (►Figure 1). Rehabilitation was performed according to the institutional protocol. A sling was used for 6 weeks after surgery to protect the subscapular suture.

Data Collection

Preoperative data were collected from the institutional Arthroplasty Registry database. Patients were invited to attend our Clinical Research Center to answer a questionnaire and perform a late postoperative clinical evaluation and a radiological test.

Clinical-Functional Assessment

The clinical-functional evaluation was based on the University of California at Los Angeles (UCLA) score⁷ and active range of motion (ROM) determination with a goniometer according to the American Academy of Orthopaedic Surgeons (AAOS) criteria.⁸ Medial rotation was measured by vertebral segments and was scored as described by Friedman et al.⁹ Therefore, patients able to reach the hip were scored as 1; buttocks, 2; sacrum, 3; L5 to L4, 4; L3 to L1, 5; T12 to T8, 6; and T7 or higher, 7.

Radiographic evaluation was carried out using anteroposterior (AP), lateral scapular, and axillary views. The cervical-diaphyseal angle (CDA) was measured on AP radiographies,¹⁰

whereas the retroversion angle (RVA) was determined in axillary position as proposed by Rydholm et al.¹¹ (►Figure 2). Measurements were made using the image viewing software mDicon Viewer version 3.0.0 (MicroData, MV Informática Nordeste, PE, Brazil), which allows drawing lines and calculating angles.

Group Stratification

To correlate implant positioning with clinical-functional outcomes, the patients were divided into two groups according to the angles measured by radiographs. Subjects with a CDA ranging from 130° to 140° and with a RVA ranging from 20° to 40° were considered within the “anatomical standard”, while those outside this range were deemed “nonstandard.”

The clinical-functional evaluation was performed based only on the CDA. The patients were divided into three groups: with a CDA < 130°, CDA ranging from 130° to 140°, and CDA > 140°.

Statistical Analysis

Data were organized in a Microsoft Office Excel 2007 (Microsoft Corp., Redmond, WA, USA) electronic spreadsheet, and the statistical analysis was performed using GraphPad Prism software version 8.2.1 for macOS (GraphPad Software, San Diego, CA, USA). Data were analyzed using the Wilcoxon

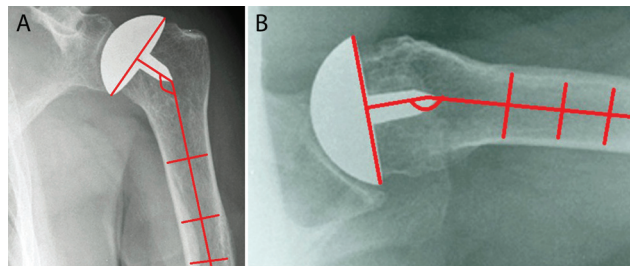


Fig. 2 Radiographic evaluation of implant positioning in partial shoulder resurfacing arthroplasty. (A) Measurement of the cervical-diaphyseal angle in anteroposterior view. (B) Measurement of the retroversion angle in axillary view.

Table 1 Characteristics of patients submitted to partial shoulder resurfacing arthroplasty from January 2008 to December 2012

| Parameter | Number of patients |
|---------------------------|--------------------|
| Age (years old) | |
| mean (standard deviation) | 46.2 (14.67) |
| median (minimum– maximum) | 46 (18–78) |
| Gender | |
| male | 14 (56%) |
| female | 11 (44%) |
| Affected side | |
| right | 15 (60%) |
| left | 10 (40%) |
| Primary diagnosis | |
| osteoarthritis | 13 |
| osteonecrosis | 6 |
| trauma sequela | 3 |
| tumor | 3 |

signed-rank test for pre- and postoperative comparison. Mean values were compared between two groups using the Mann-Whitney test and between three groups using the Kruskal-Wallis test. A p -value < 0.05 was considered statistically significant.

Results

The mean follow-up time was of 48.3 months (from 12 to 67 months). **Table 1** lists demographic data and primary diagnoses. The average time from the onset of symptoms to the surgical procedure was 6 years, 9 months (ranging from 6 months to 20 years). Revision surgery was performed in 8 out of 25 patients (32% of the cases), with an average follow-up time of 48 months. There was 1 case of subscapularis tendon rupture 4 months after surgery. The patient underwent surgical treatment with transosseous tendon reattachment and was kept in the study.

Functional assessment was significantly better at the postoperative than the at the preoperative period (**Figure 3**). The median UCLA score increased from 15.5 at the preoperative period (range: 4 to 27) to 31.5 (range: 14 to 35) at the postoperative period ($p < 0.001$). The median (minimum–maximum) anterior flexion angle increased from 100° (20° to 180°) to 140° (90° to 180°) ($p = 0.0004$). Lateral rotation increased from 40° (-30° to 70°) to 50° (0° to 80°) ($p = 0.009$), whereas the medial rotation score increased from 5 (2 to 6) to 6 (4 to 7) ($p = 0.0007$).

Six patients presented the implant in anatomical position, with the CDA and RVA within the “anatomical standard;” the remaining 19 subjects presented “nonstandard” CDA and/or RVA. Applying this criterion to group patients, postoperative clinical-functional outcomes were not statistically different ($p > 0.05$ in all parameters) between subjects with standard or nonstandard values. In these groups, median values

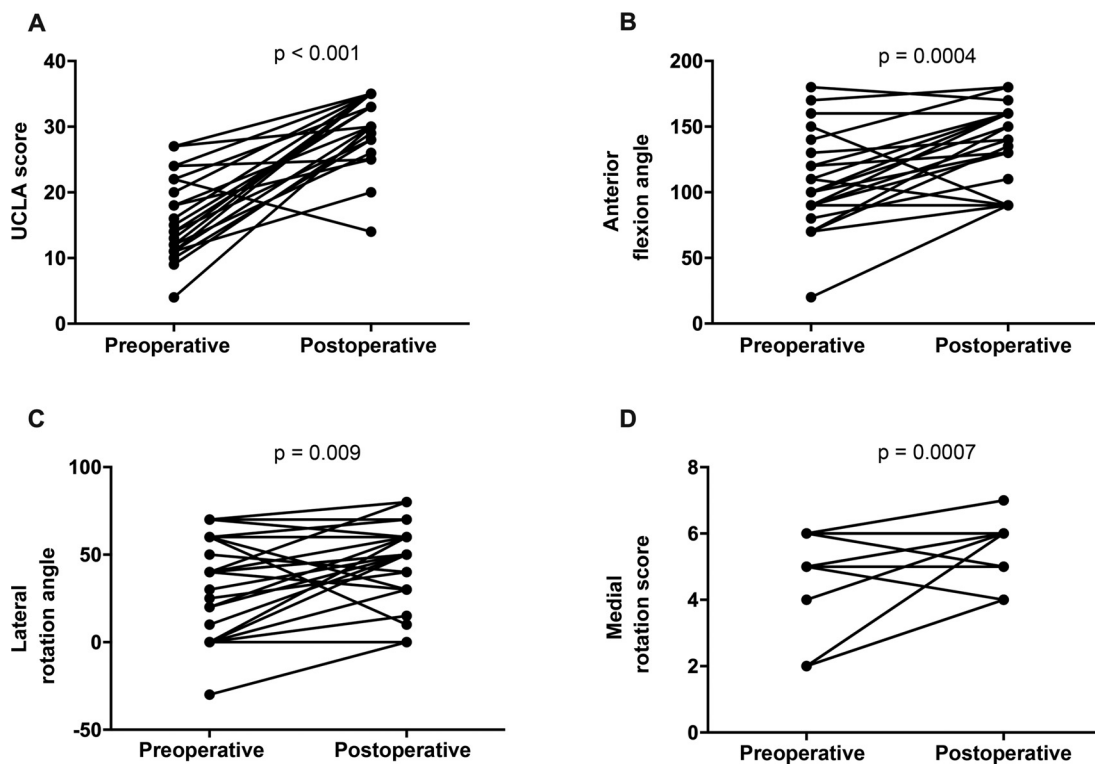


Fig. 3 Pre- and postoperative clinical-functional assessment of patients submitted to partial shoulder resurfacing arthroplasty from January 2008 to December 2012. (A) University of California at Los Angeles (UCLA) clinical score. (B) Anterior flexion angle. (C) Lateral rotation angle. (D) Medial rotation score. A p -value < 0.05 represents a statistically significant difference between groups. Wilcoxon signed-rank test.

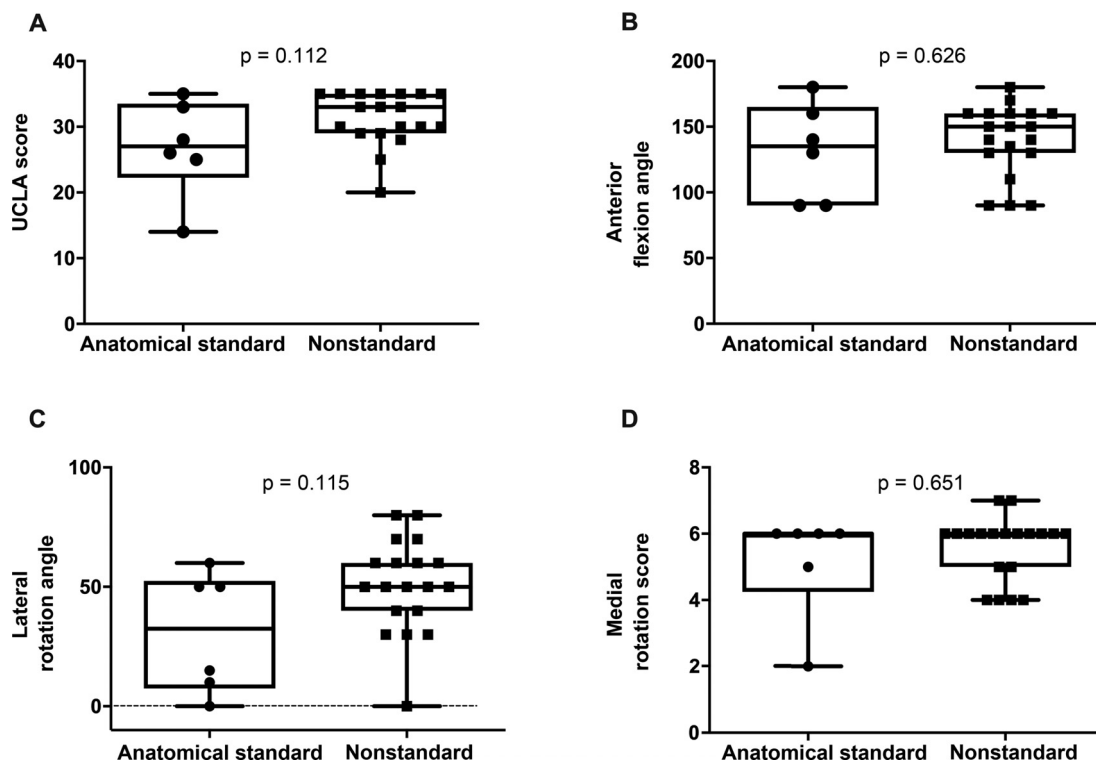


Fig. 4 Postoperative clinical-functional evaluation of patients submitted to partial shoulder resurfacing arthroplasty grouped according to implant positioning. (A) University of California at Los Angeles (UCLA) clinical score. (B) Anterior flexion angle. (C) Lateral rotation angle. (D) Medial rotation score. Prostheses with cervical-diaphyseal angle ranging from 130° to 140° and retroversion angle from 20° to 40° were considered within the anatomical standard. The dotted line indicates a zero value on the y-axis. A p-value > 0.05 represents statistical equality between groups. Mann-Whitney test.

(minimum–maximum) were, respectively, 27 (14 to 35) and 33 (20 to 35) for the UCLA score; 135° (90° to 180°) and 150° (90° to 180°) for anterior flexion angle; 32.5° (0° to 60°) and 50° (0° to 80°) for lateral rotation angle; and 6 (2 to 6) and 6 (4 to 7) for the medial rotation score (→ **Figure 4**).

The patients were grouped according to the CDA to determine whether this parameter could predict functional improvement. The CDA was < 130° in 7 patients, ranged from 130° to 140° in 14 subjects, and was > 140° in 4 patients. The functional evaluation using CDA alone as a parameter for patient stratification revealed no statistically significant difference between groups ($p < 0.05$). In these groups, the median values (minimum–maximum) were, respectively, 29.5 (20 to 35) versus 30 (14 to 35) versus 34 (30 to 35) for the UCLA score; 140 (90 to 180) versus 150 (90 to 180) versus 140 (90 to 160) for anterior flexion angle; 50 (15 to 70) versus 60 (10 to 80) versus 40 (0 to 60) for lateral rotation angle; and 6 (2 to 7) versus 6 (4 to 7) versus 5.5 (4 to 6) for the medial rotation score (→ **Figure 5**).

Likewise, when patients were grouped according to the RVA alone, postoperative clinical-functional outcomes were not significantly different ($p > 0.05$) when the RVA was $\leq 20^\circ$ or ranged from 20° to 40°. The RVA was $\leq 20^\circ$ in 15 patients, and ranged from 20° to 40° in 10 subjects, within the ideal anatomical standard. In these groups, the median values (minimum–maximum) were, respectively,

33 (20 to 35) and 30 (14 to 35) for the UCLA score; 150 (90 to 180) and 135 (90 to 160) for anterior flexion angle; 50 (0 to 80) and 35 (0 to 70) for lateral rotation angle; and 6 (4 to 7) and 5.5 (2 to 6) for the medial rotation score (→ **Figure 6**).

Discussion

Resurfacing arthroplasties are indicated for patients with degenerative or inflammatory diseases of the shoulder. Like stem-based prostheses, resurfacing procedures allow surgeons to manage version and inclination, humeral head thickness and offset^{5,12,13} with the advantage of being a simpler, less invasive technique¹⁴ that provides greater bone stock preservation and presents a lower incidence of complications, such as periprosthetic humeral fractures.¹⁵ However, the main cause of arthroplasty failure is related to the implant technique and positioning.¹⁶ It is extremely difficult to determine the optimal component position during surgery due to the struggle in achieving adequate joint exposure and to the geometric deformity of the humeral head articular surface.^{13,17,18}

Normal shoulder anatomy presents great variability, which hinders reproducibility in surface prosthesis positioning.¹³ These changes in individual anatomy can affect joint biomechanics after surgery, interfering with its function. Inaccurate dimensioning or positioning of a

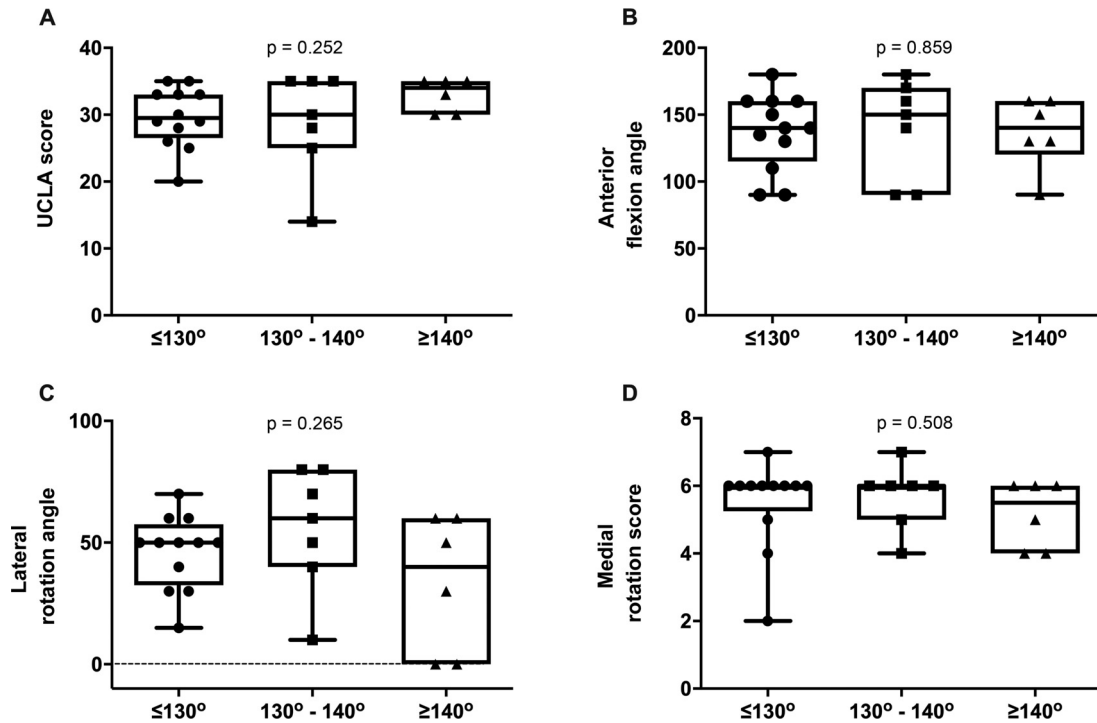


Fig. 5 Postoperative clinical-functional evaluation of patients submitted to partial shoulder resurfacing arthroplasty grouped according to the cervical-diaphyseal angle. (A) University of California at Los Angeles (UCLA) clinical score. (B) Anterior flexion angle. (C) Lateral rotation angle. (D) Medial rotation score. A p-value > 0.05 represents statistical equality between groups. Analysis of variance (ANOVA) followed by the Kruskal-Wallis test.

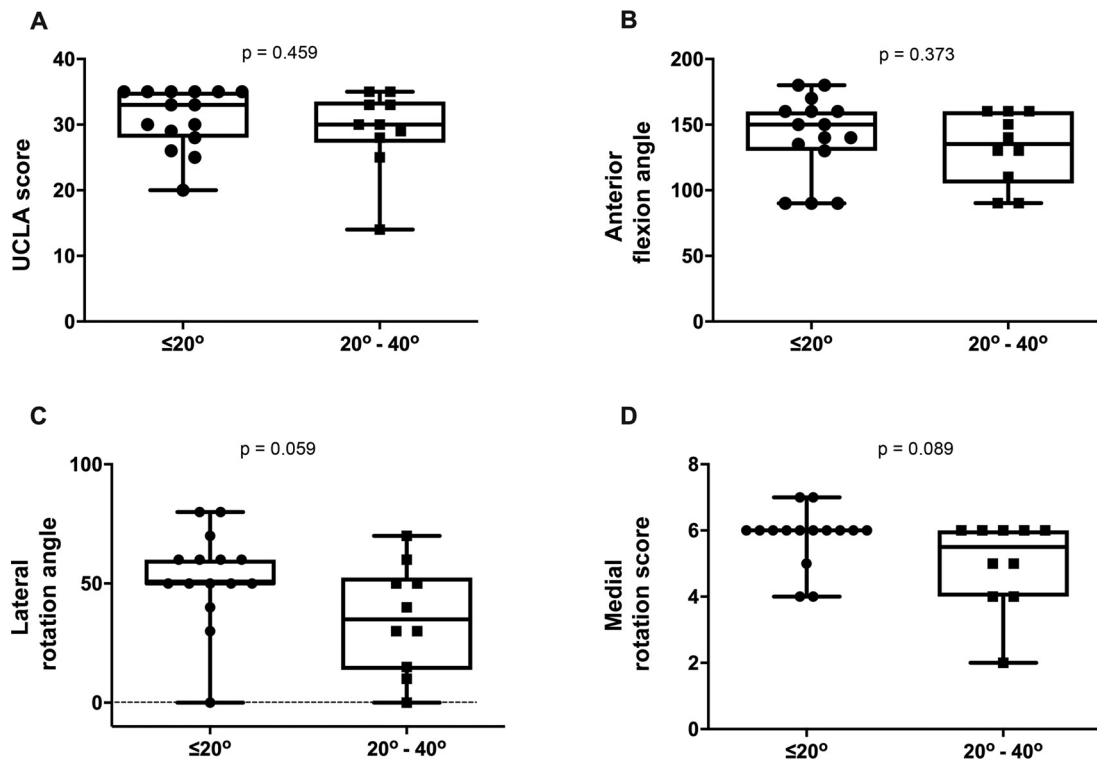


Fig. 6 Postoperative clinical-functional evaluation of patients submitted to partial shoulder resurfacing arthroplasty grouped according to retroversion angle. (A) University of California at Los Angeles (UCLA) clinical score. (B) Anterior flexion angle. (C) Lateral rotation angle. (D) Medial rotation score. A p-value > 0.05 represents statistical equality between groups. Mann-Whitney test.

humeral head resurfacing prosthesis can result in altered joint version and inclination.^{19,20} Therefore, we evaluated the correlation between implant positioning and postoperative ROM in 25 partial shoulder resurfacing arthroplasties operated consecutively in a single reference center and with an average follow-up time of 4 years. Functional outcomes demonstrated that partial shoulder resurfacing arthroplasties improved UCLA scores, which assess pain and functionality. These outcomes are equivalent to those of partial shoulder arthroplasty using stems, and also agree with other series on shoulder resurfacing arthroplasties showing functional improvement.^{12,13,18}

Regarding implant positioning, our series identified only 8 out of 25 patients with anatomical reconstruction of the proximal extremity of the humerus with CDA and RVA values according to the criteria used here. These findings contradict the claim that partial shoulder resurfacing arthroplasties allow a reproduction of the normal humeral anatomy.²¹ Even though angular parameters guide the procedure, there is no correlation with functional outcomes, and, therefore, these values cannot predict surgical success. The lack of correlation between implant positioning and functional outcomes in our study is consistent with other publications. A radiographic study from Coutié et al.²² evaluated 31 partial resurfacing arthroplasties for an average follow-up time of 22 months. The authors concluded that the axillary view was insufficiently reproducible for implant version assessment. Rydholm et al.¹¹ evaluated 72 patients who underwent partial resurfacing arthroplasties with a follow-up time of 4.2 years and found no correlation between implant position and functional outcomes. Deladerrière et al.¹⁰ used computed tomography (CT) images from the pre- and postoperative periods to assess whether the surgical procedure restored anatomical parameters. They demonstrated that, in comparison with initial parameters, there was no statistically significant correlation between the eventual implant version alteration and the lateral offset. In contrast, the medial humeral offset and anteversion increased by 3.47 mm and 4.23°, respectively.

One limitation of our study was the lack of overstuffing evaluation associated with partial resurfacing arthroplasty. Geervliet et al.²³ performed a radiographic study to evaluate the anatomical restoration of the humeral head. A deviation from the rotational center > 5 mm, defined as overstuffing, was a predictor of failure, that is, indication for revision surgery. Another limitation was the use of radiographs for measurements because, theoretically, values may vary according to the positioning of the arm or of the scapula.²²

Finally, our results suggest that the anatomical positioning of the implant is inaccurate. This may be due to natural anatomical variations of the proximal humeral extremity, ongoing deformities from the degenerative joint disease, and procedural technical difficulty.

Conclusion

Our results demonstrate that partial shoulder resurfacing arthroplasties improve UCLA functional scores assessing pain and functionality. Implant positioning, assessed by

cervical-diaphyseal and retroversion angles, is not correlated with clinical-functional outcomes of the prosthesis and, therefore, it is an inaccurate measure of surgical success.

Financial Support

The present study received no financial support from public, commercial, or not-for-profit sources.

Conflict of Interests

The authors have no conflict of interests to declare.

References

- Matsen FA 3rd, Rockwood CA Jr, Wirth MA, Lippitt SB, Parsons M. Glenohumeral arthritis and its management. In: Rockwood CA Jr, Matsen FA 3rd, Wirth MA, Lippitt SB, editors. *The Shoulder*. 3rd ed. Philadelphia: Saunders; 2004:879–1007
- Scalise JJ, Miniaci A, Iannotti JP. Resurfacing Arthroplasty of the Humerus: Indications, Surgical Technique, and Clinical Results. *Tech Shoulder Elbow Surg* 2007;8(03):152–160
- Bailie DS, Llinas PJ, Ellenbecker TS. Cementless humeral resurfacing arthroplasty in active patients less than fifty-five years of age. *J Bone Joint Surg Am* 2008;90(01):110–117
- Copeland SA. Cementless total shoulder replacement. In: Post M, Morrey BF, Hawkins RJ. *Surgery of the Shoulder*. St. Louis: Mosby Year Book; 1990:289–293
- Thomas SR, Sforza G, Levy O, Copeland SA. Geometrical analysis of Copeland surface replacement shoulder arthroplasty in relation to normal anatomy. *J Shoulder Elbow Surg* 2005;14(02):186–192
- Australian Orthopaedic Association National Joint Replacement Registry. Demographics of Hip, Knee & Shoulder Arthroplasty. 2019. (Supplementary report 2019). Available at: <https://aoanjr.sahmri.com/annual-reports-2019/supplementary>
- Constant CR, Gerber C, Emery RJ, Søjbjerg JO, Gohlke F, Boileau P. A review of the Constant score: modifications and guidelines for its use. *J Shoulder Elbow Surg* 2008;17(02):355–361
- AAOS. *Joint Motion: Method of measuring and recording*. Chicago: American Academy of Orthopedics; 1965
- Friedman RJ, Eichinger J, Schoch B, et al. Preoperative parameters that predict postoperative patient-reported outcome measures and range of motion with anatomic and reverse total shoulder arthroplasty. *JSES Open Access* 2019;3(04):266–272
- Deladerrière JY, Szymanski C, Vervoort T, Budzik JF, Maynou C. Geometrical analysis results of 42 resurfacing shoulder prostheses: A CT scan study. *Orthop Traumatol Surg Res* 2012;98(05):520–527
- Rydholm U, Sjögren J. Surface replacement of the humeral head in the rheumatoid shoulder. *J Shoulder Elbow Surg* 1993;2(06):286–295
- Hammond G, Tibone JE, McGarry MH, Jun BJ, Lee TQ. Biomechanical comparison of anatomic humeral head resurfacing and hemiarthroplasty in functional glenohumeral positions. *J Bone Joint Surg Am* 2012;94(01):68–76
- Pearl ML. Proximal humeral anatomy in shoulder arthroplasty: Implications for prosthetic design and surgical technique. *J Shoulder Elbow Surg* 2005;14(1 Suppl S)99S–104S
- Brasil Filho R, Ribeiro FR, Tenor Filho AC. Artrose glenoumeral do paciente jovem – artroplastia de superfície. In: Reginaldo SS, Guerra IP, Miyazaki ANeditores. *Ombro e Cotovelo*. Rio de Janeiro: Elsevier; 2013:215–223
- Levy O, Copeland SA. Cementless surface replacement arthroplasty of the shoulder. 5- to 10-year results with the Copeland mark-2 prosthesis. *J Bone Joint Surg Br* 2001;83(02):213–221
- Bohsali KI, Wirth MA, Rockwood CA Jr. Complications of total shoulder arthroplasty. *J Bone Joint Surg Am* 2006;88(10):2279–2292

- 17 Ohl X, Nérot C, Saddiki R, Dehoux E. Shoulder hemi arthroplasty radiological and clinical outcomes at more than two years follow-up. *Orthop Traumatol Surg Res* 2010;96(03):208–215
- 18 Buchner M, Eschbach N, Loew M. Comparison of the short-term functional results after surface replacement and total shoulder arthroplasty for osteoarthritis of the shoulder: a matched-pair analysis. *Arch Orthop Trauma Surg* 2008;128(04):347–354
- 19 Burgess DL, McGrath MS, Bonutti PM, Marker DR, Delanois RE, Mont MA. Shoulder resurfacing. *J Bone Joint Surg Am* 2009;91(05):1228–1238
- 20 Williams GR Jr, Wong KL, Pepe MD, et al. The effect of articular malposition after total shoulder arthroplasty on glenohumeral translations, range of motion, and subacromial impingement. *J Shoulder Elbow Surg* 2001;10(05):399–409
- 21 Widnall JC, Dheerendra SK, Macfarlane RJ, Waseem M. The use of shoulder hemiarthroplasty and humeral head resurfacing: a review of current concepts. *Open Orthop J* 2013; 7:334–337
- 22 Coutié AS, Mansat P. Conséquences géométriques des prothèses de resurfacement de l'épaule. *Le resurfacement de l'épaule MontpellierSauramps medical*2009
- 23 Geervliet PC, Willems JH, Sierevelt IN, Visser CPJ, van Noort A. Overstuffing in resurfacing hemiarthroplasty is a potential risk for failure. *J Orthop Surg Res* 2019;14(01):474