Article published online: 2021-05-23

Endometriosis and Its Myriad Presentations: Magnetic Resonance Imaging-Based Pictorial Review

Seema Sud[1] Tarvinder Bir Singh Buxi[1] Swapnil Sheth[1] Samarjit Singh Ghuman[1]

[1]Department of CT and MRI, Sir Ganga Ram Hospital, New Delhi, India

Address for correspondence Seema Sud, MBBS, DNB, Department of CT and MRI, Sir Ganga Ram Hospital, Old Rajinder Nagar, New Delhi 110 060, India (e-mail: sudseema@gmail.com).

Indian J Radiol Imaging 2021;31:193–202.

Abstract

Endometriosis is a major cause of infertility and pain in females in the reproductive age group. It is a result of ectopic functional endometrial cells outside the uterus. It consists of a spectrum of findings from superficial to deep implants initiating a fibrotic response and resulting in adhesions. Diagnosis of endometriosis is based on clinical history, noninvasive and invasive techniques. The final diagnosis is based on laparoscopy with histopathological confirmation. Ultrasonography is the first line of investigation, followed by magnetic resonance imaging (MRI) in complex cases. MRI is a noninvasive, multiplanar technique that involves no radiation and provides excellent delineation of the disease process. As deep endometriosis has a similar low signal to adjacent normal organs, it can be easily overlooked by radiologists. They should be aware of the spectrum of diseases so as to provide a roadmap for the surgeons. A structured reporting system helps radiologists organize and standardize their reports.

Keywords
- bladder endometriosis
- endometrioma
- endometriosis
- MRI
- structured reporting
- ureteral endometriosis
- uterine ligaments

Introduction

Endometriosis is the presence of functional endometrial tissue in ectopic locations, that is, outside the uterine cavity, with an estimated prevalence of 5 to 10%.[1,2] The disease is estrogen-dependent, hence seen in the reproductive age group, with a peak incidence between 24 and 29 years.[1] The terms endometriosis and endometriomas are often used interchangeably. Endometriosis is a spectrum of diseases that include ovarian endometriomas, endometrial implants, and adhesions in the pelvic peritoneum and retroperitoneum.[2]

Learning Objectives

This article will address the following:
- Etiology and pathogenesis of endometriosis.
- Optimal magnetic resonance imaging (MRI) protocol and technique for pelvic endometriosis.
- Magnetic resonance (MR) signal characteristics and location of pelvic endometriosis.
- Classification of endometriosis according to location in the pelvis and the imaging appearance.
- Structured reporting system.

Etiology and Pathogenesis

There are numerous theories regarding the etiology of endometriosis, which is still unclear. The most accepted theories are the metastatic, metaplastic, and induction theories. Research is still on regarding other factors that may be responsible for the development of endometriosis like growth factor and immunity.[2] Metastatic theory, which is the most widely accepted, states that implants in the pelvic cavity are as a result of metastatic retrograde menstruation of viable endometrial tissue into the pelvic cavity.[3,4] This theory is corroborated by the fact that the implants are seen in

published online
May 31, 2021

DOI https://doi.org/10.1055/s-0041-1729670
ISSN 0971-3026

© 2021. Indian Radiological Association
This is an open access article published by Thieme under the terms of the Creative Commons Attribution-NonDerivative-NonCommercial-License, permitting copying and reproduction so long as the original work is given appropriate credit. Contents may not be used for commercial purposes, or adapted, remixed, transformed or built upon. (https://creativecommons.org/licenses/by-nc-nd/4.0/).
Thieme Medical and Scientific Publishers Private Ltd. A-12, Second Floor, Sector -2, NOIDA -201301, India

the dependent portion of the pelvic cavity and are commonly seen when there is an obstruction of antegrade menstrual flow in Mullerian anomalies (►**Fig. 1**). The implants which are seen outside the pelvic cavity are believed to be due to metastatic spread of the endometrial tissue via the lymphatics, bloodstream, or iatrogenic spread postsurgery or biopsy.

The metaplastic theory supports the differentiation of the remnant Mullerian tissue or serosal surfaces into endometriotic cells. It suggests that the peritoneal cells differentiate into functional endometrial tissue as the endometrial and peritoneal cells are both derived from the coelomic epithelium. This is supported by the fact that endometriosis is also seen in patients with Turner syndrome, gonadal dysgenesis, and uterine agenesis that lack eutopic endometrium.[2,4]

The induction theory is a mixture of the metastatic and metaplastic theories which states that the ectopic endometrium secretes tissues that initiate the differentiation.[2,4]

Classification of Endometriosis

Endometriosis is a spectrum of diseases which consist of superficial, deep endometriosis which can be peritoneal or extraperitoneal, ovarian endometriomas, and adhesions. Superficial endometriosis (Sampson's disease) is deposited on the surface of pelvic organs or the peritoneum which can be hemorrhagic or nonhemorrhagic. The superficial nonhemorrhagic implants are not visible on imaging and are seen only at laparoscopy. They are seen as white, black, or red spots on laparoscopy depending on the degree of scarring, fibrosis, and hemorrhage within the lesion. Deep infiltrating endometriosis (DIE) by definition is a peritoneal implant extending into the retroperitoneum with a depth of more than 5 mm, with a prevalence of approximately 1% in the reproductive age group; 20% of women are affected by endometriosis.[4] It is the solid, infiltrating type, and is the major contributor to female infertility and pelvic pain.

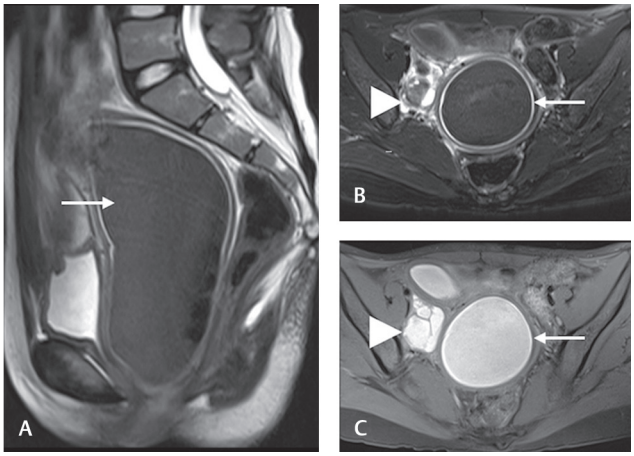

Fig. 1 (**A–C**) T2W sag (A), FS T2W (B), and T1W (C) axial images showing a distended vagina filled with hemorrhage due to outflow obstruction (*arrow*) along with right endometrioma (*arrowhead* in B and C). FS, fat-suppressed; T1W, T1-weighted; T2W, T2-weighted.

Diagnosis of Endometriosis

The presumptive diagnosis of endometriosis is made by imaging. Transvaginal (TVS) and transrectal sonography (TRS) are the first-line imaging modality. TVS is able to pick up implants of 1.5 cm or more. TRS is valuable for the evaluation of the rectosigmoid and rectovaginal septum. It has higher sensitivity than MRI to evaluate the degree of bowel wall infiltration.[4] The overall accuracy of TVS in the detection of DIE is similar to MRI but it requires knowledgeable and experienced operators in interpreting the sliding sign to diagnose adhesions.[5] MRI is the best imaging technique and provides a road map for surgeons of DIE. It is able to pick up lesions hidden by adhesions both in the peritoneal and subperitoneal space. It is performed as a second-line investigation after TVS in complex cases. Definitive diagnosis is made by laparoscopy.

MRI Protocol

Our standard protocol is as per European Society of Urogenital Radiology guidelines.[6] Contrast images were acquired to better illustrate the rectal/ureteral deposits as and when required.

All scans were performed on a 3.0 T scanner (Verio; Siemens, Erlangen, Germany). All patients were scanned irrespective of the menstrual cycle with 4-hour fasting. The patient was placed feet first on the spine coil with the phased array coil placed on the pelvis and images were obtained from the pelvic inlet to 5 cm below the symphysis.

Intravenous (IV) Buscopan (scopolamine-*N*-butyl bromide) was administered on the table at the time of scanning to reduce bowel peristalsis and uterine contraction.[5-7] No rectal enema was administered. Vaginal gel was given to delineate the fornices in a few cases. Bladder should not be over-distended as that may result in detrusor contractions resulting in image degradation and missing of small parietal nodules.[5-7]

Locations of Endometriosis

The common locations of endometriosis are ovarian endometriomas, adhesions at the base of the pouch of Douglas, vesicouterine space, rectovaginal septum, rectosigmoid, urinary bladder, and anterior abdominal wall (►**Fig. 2**).[3-5]

MRI Features of Ovarian Endometriomas

- Endometriomas show high signal on T1 weighted (T1W) images and low signal on T2W images. The characteristic findings include:
- T2 shading effect: the supernatant displays high signal on T2W images and the dependent portion shows low signal intensity (SI; ►**Fig. 3**).[4-8] This is attributed to the repeated cyclical hemorrhages and high concentrations of methemoglobin, protein, and iron products in endometriomas, hence they are bright on T1W images.
- T2 dark spots: referred to low SI foci seen along the periphery of the endometriomas due to chronic hemorrhage (►**Fig. 4**).

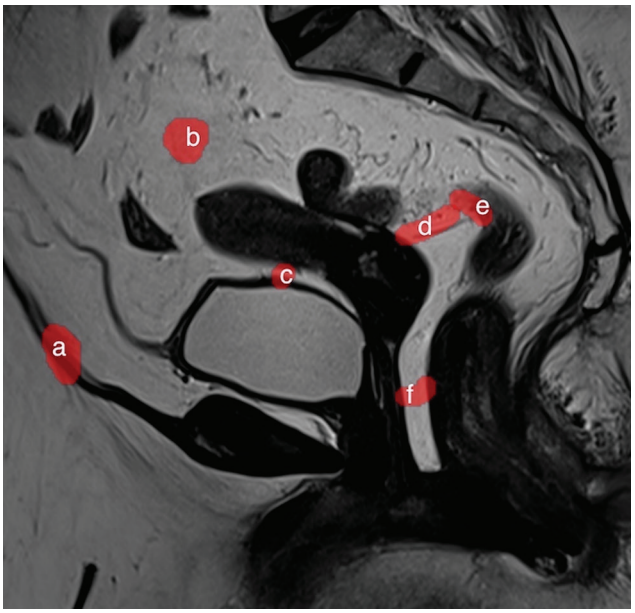

Fig. 2 The common sites of endometriotic deposits include anterior abdominal wall (a), ovaries (b), vesicouterine septum (c), rectouterine septum (d), rectum (e), rectovaginal pouch (f).

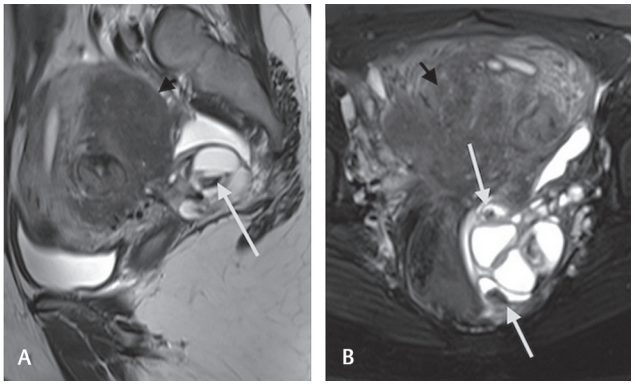

Fig. 4 (**A, B**) T2W sag (A) and T2W FS axial (B) images showing hypointense nodular areas along the periphery of the endometriomas (*arrow*)—"T2 dark spot." Note is also made of a large deep endometriotic deposit in the posterior uterine myometrium (*arrowhead*). FS, fat-suppressed; T2W, T2-weighted.

- T2 dark rim: a hypointense hemosiderin rim is seen around the ovary/endometrioma (►**Fig. 5**).
- Contrast enhancement–peripheral enhancement on IV contrast administration unlike hemorrhagic cysts, which show no enhancement; however, this is not a specific finding.[2]

Differential Diagnosis of Ovarian Endometriomas

- Functional hemorrhagic cyst (FHC): absence of T2 shading, dark spot, and hypointense rim. Usually unilateral and shows no enhancement, unlike endometriomas which are usually bilateral and multifocal. FHC usually disappears in the 4 to 6 weeks follow-up examination. A study by Balaban et al reported significantly lower apparent diffusion coefficient (ADC) values in endometriotic cysts compared to hemorrhagic cysts.[9]
- Mature cystic teratoma: show suppression in signal on T1W fat-suppressed (FS) images.
- Mucinous tumors: show hyperintense signal on T1W pre- and post-FS images but it is lower than that seen in endometriomas.
- Abscess: diffusion-weighted images (DWIs) cannot differentiate an endometrioma from an abscess as both can restrict; however, endometriomas are bright on T1W FS images, whereas abscesses show low SI (►**Fig. 6**). Endometriomas have low SI in parts on ADC because of "T2 blackout effects."

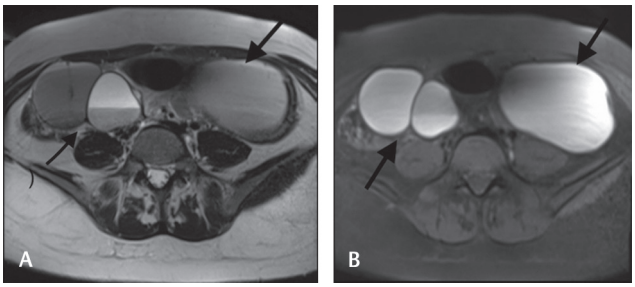

Fig. 3 (**A, B**) T2W (A) and FS T1W (B) axial images showing bilateral endometriomas with T2 shading (*arrow*). FS, fat-suppressed; T1W, T1-weighted; T2W, T2-weighted.

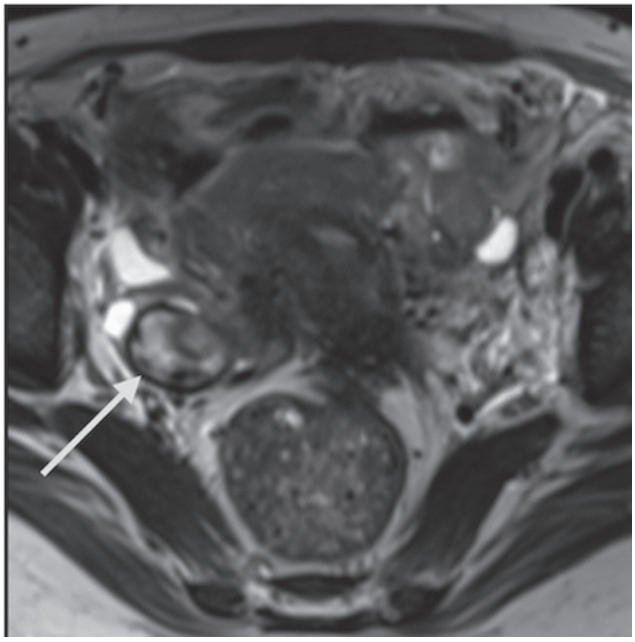

Fig. 5 T2W axial image showing the hemosiderin hypointense rim around the right ovary (*arrow*).

MRI Features of DIE

DIEs are commonly overlooked on MRI as they show low SI and are commonly located adjoining normal low T2W SI structures. They are composed of ectopic endometrial glands and stromal cells which induce a dense fibromuscular

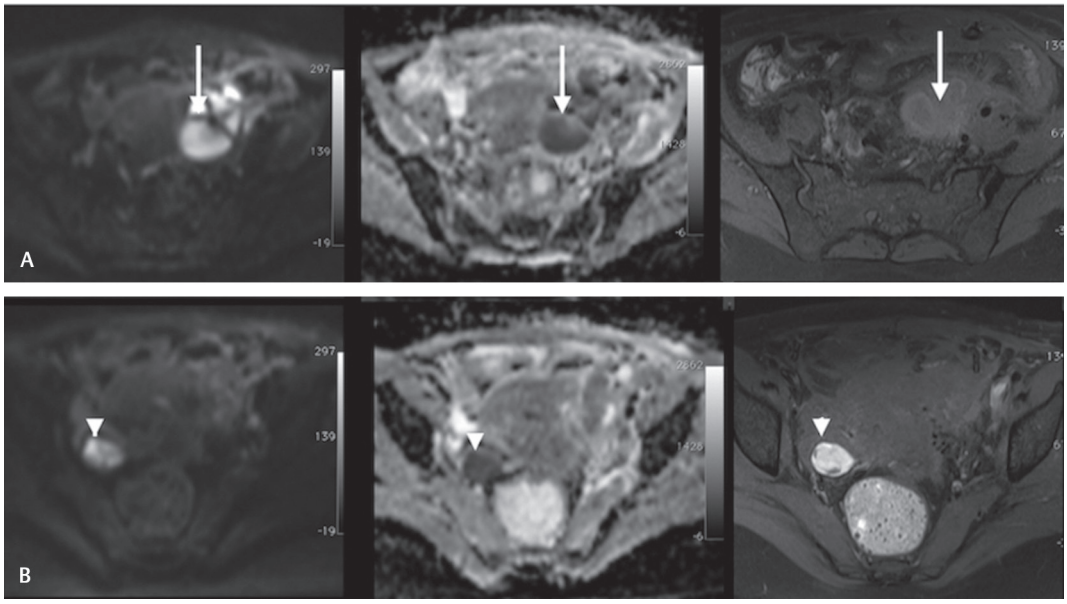

Fig. 6 (**A, B**) (A, top row): DWI, ADC, and FS T1W images in the axial plane showing an abscess with restricted diffusion and peripheral T1W hyperintensity (*arrow*). (B, bottom row): DWI, ADC, and FS T1W images in the axial plane showing an endometrioma with restricted diffusion and T1W hyperintensity (*arrowhead*). ADC, apparent diffusion coefficient; DWI, diffusion-weighted image; FS, fat-suppressed; T1W, T1-weighted.

response. The ectopic endometrial glands appear hyperintense on T2W images and the fibrosis appears low in SI on T2W images (►**Fig. 7**).[2] Depending upon the composition of the deposit, the signal will vary on T2W images. If there is hemorrhage within these masses, they will be seen as hyperintense foci on T1W images. Commonly the surrounding fibrosis and smooth muscle hypertrophy may be so extensive that it minimizes the cyclical bleeding within the ectopic endometrial glands and these deposits are seen as spiculated low SI masses. Intracystic blood clots restrict on DWI. On IV contrast administration, the enhancement depends on the degree of inflammatory reaction, glandular tissue, and fibrosis.[4] Adhesions are commonly seen in endometriosis and are composed of fibrotic tissue containing collagen fibroblasts and macrophages, giving a very low signal on MRI. They appear as spiculated strands arranged at confluent angles or with indirect evidence such as abnormal angulations of pelvic organs such as uterus, rectosigmoid, and ovaries, which may be adherent in the cul-de-sac. Hydrosalpinx and nondependent fluid collections are other signs.[2,10]

Classification of Deep Endometriosis According to Pelvic Location

The pelvic cavity is divided into three compartments: anterior, middle, and posterior, functionally and clinically (►**Fig. 8A**).[11]

Anterior Compartment

It is a virtual space located posterior to the symphysis pubis, with its posterior margin being the anterior surface of the uterus and posterior wall of the bladder. It consists of the urinary bladder, urethra, vesicouterine pouch, and vesicovaginal septum (►**Fig. 8B**). The vesicouterine pouch is also known as the anterior cul-de-sac, formed by the reflection of the peritoneum between the dome of the bladder and the uterus. The vesicovaginal septum is a fat-filled space between the bladder and vagina.

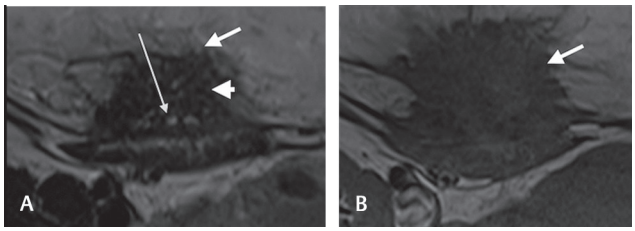

Fig. 7 (**A, B**) T2W (A) and T1W (B) axial images showing a spiculated mass (*short arrow*) with internal hyperintense foci suggestive of ectopic endometrial tissue (*long arrow*) with surrounding hypointensity suggestive of fibrosis and smooth muscle hypertrophy (*arrowhead*). T1W, T1-weighted; T2W, T2-weighted.

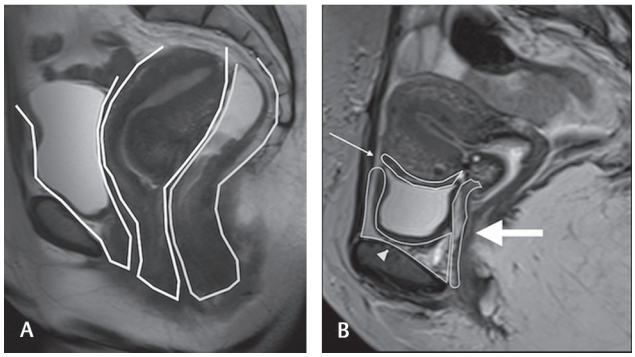

Fig. 8 (**A, B**) Sag T2W image (A) showing the anterior, middle, and posterior compartments and (B) T2W sag image showing the prevesical space (*arrowhead*). Vesicouterine pouch (*thin arrow*) and the vesico-vaginal septum (*solid arrow*). T2W, T2-weighted.

Bladder endometriosis is rare with a reported incidence of 20% of cases.[1] It is the most commonly involved organ in the urinary tract followed by ureter, kidney, and urethra. It is often multifocal with the dome and the trigone most frequently involved. It shows low SI on T2W images (►**Fig. 9**). Foci of hemorrhage may or may not be seen. Depending on the degree of vesical wall infiltration, it can be intrinsic or extrinsic type. The extrinsic variety is confined to the serosal surface. As the extrinsic vesical endometriosis does not invade the mucosa, MRI may show abnormalities but these are not picked up at cystoscopy. The intrinsic type infiltrates the muscular layer and is seen as mural masses that project into the lumen. These are seen on cystoscopy.

The ureters are extraperitoneal, posteromedial to the external iliac vessels, and lateral to the uterosacral ligaments (USLs) in the paracervical space in the pelvis. Ureteral endometriosis is rarely seen with a reported incidence of approximately 10 to 20% of cases.[1] It also is of the extrinsic and intrinsic variety, the most common being the extrinsic which is seen as a dense hypointense signal on T2W images adjoining the ureters (►**Fig. 10**).[12] It almost never extends above the pelvic brim. They may or may not be proximal dilatation depending on the degree of fibrosis. Commonly an associated ipsilateral endometrioma or a rectosigmoid nodule >3 cm is seen. Seracchioli et al[13] described two histological patterns of ureteral involvement: fibrotic pattern where only fibrosis was seen on histopathology and endometriotic type characterized by endometrial glands within the ureteral wall and in the periuterine tissues. They found hydroureteronephrosis was significantly associated with the endometriotic pattern, whereas endometriosis in the rectovaginal septum is associated with the fibrotic ureteral type.

Middle Compartment

It consists of the uterus, fallopian tubes, ovaries, and broad ligament. The ovaries are suspended by the mesovarium which is a double fold of the peritoneum. The broad ligament are also peritoneal folds that suspend the uterus.

Ovarian endometriosis can be superficial implants with adhesions, micro intraovarian endometriomas, or deep implants that have repeated cyclic hemorrhage resulting in endometriomas, also commonly known as chocolate cysts due to its dirty brown contents on laproscopy.[4] Apart from endometriomas, ovarian involvement may also be seen in the form of adhesions. The ovaries are seen pulled posteriorly and are seen adherent to the posterior margin of the uterus also called kissing ovaries (►**Fig. 11**). A sudden increase in the size of endometriomas with nodularity along the walls which show restricted diffusion along with thick enhancing septations suggests malignant change. Clear cell carcinoma and endometrioid carcinomas are associated with endometriosis (►**Fig. 12**).[14]

Uterus-DIE of the uterine serosa is seen as low SI on T2W images with small cystic areas. Involvement of the uterus can mimic adenomyosis. The differentiating factor is that

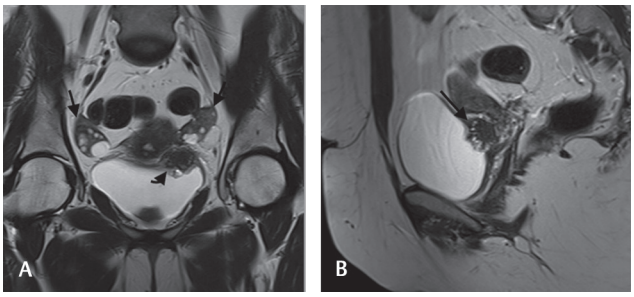

Fig. 9 (**A, B**) Cor (A) and sag (B) T2W images showing a deep extrinsic deposit on the bladder (*arrow* in B) with intact mucosa (*arrowhead* in A). Note that the ovaries are bilaterally normal (*arrows* in A). T2W, T2-weighted.

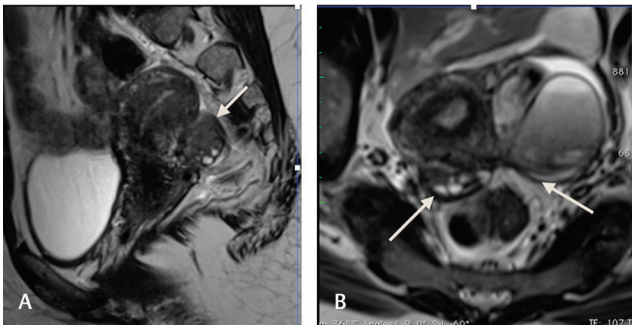

Fig. 11 (**A, B**) T2W sag (A) and axial (B) images showing adherent ovary to the posterior surface of the uterus (*arrow* in A) and both ovaries puckered posteriorly and to the midline (*arrows* in B)—kissing ovaries sign. T2W, T2-weighted.

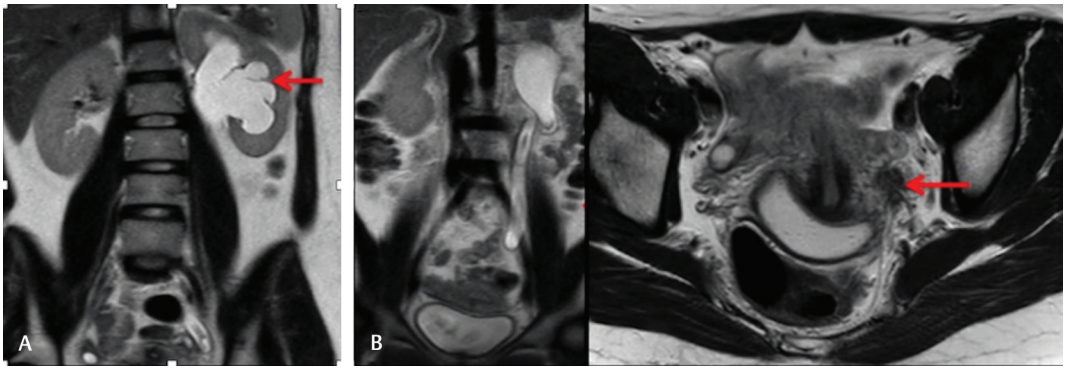

Fig. 10 (**A–C**) Cor (A and B) and axial (C) T2W images showing left-sided hydronephrosis (*arrow* in A), hydroureter (B), and a spiculated mass encasing the left ureter (*arrow* in C). T2W, T2-weighted.

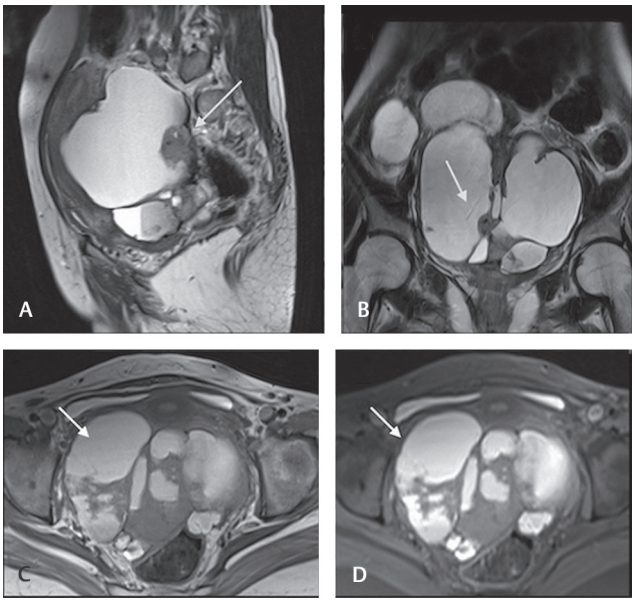

Fig. 12 (**A–D**) T2W sag (A), cor (B), and T1W axial images without and with FS (C and D), showing an endometrioma (*arrows* in C and D) with absence of T2W shading and a solid mural nodule (*arrows* in A and B) suggestive of malignant transformation. FS, fat-suppressed; T1W, T1-weighted; T2W, T2-weighted.

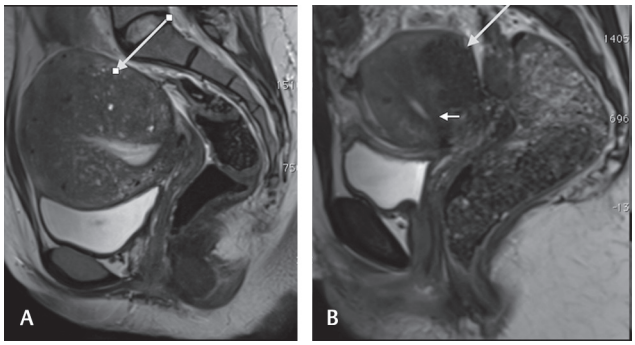

Fig. 13 (**A, B**) T2W sag images (A) showing widening of the junctional zone with diffuse adenomyosis (*arrow*) and in panel (B) there is a deposit in the posterior serosal surface of the uterus (*arrow*) with normal thickness of the junctional zone (*short arrow*). T2W, T2-weighted.

the junctional zone appears normal in thickness in invasive endometriosis of the uterus; however, it shows widening more than 12 mm in adenomyosis (►**Fig. 13**).[5,15] DIE is an "outside-in" process that spares the uterine junctional zone and should not be misdiagnosed as adenomyosis. Adenomyosis in contrast is a process that is an "inside-out process." It is due to the abnormalities that arise from the interface between the endometrium and the subadjacent myometrium as well as due to the presence of ectopic endometrial and stromal tissue outside the endometrial complex but within the uterus.

Cervix and vagina: the sensitivity and specificity of MRI for the diagnosis of involvement of the cervix and vagina is 82%. The posterior vaginal fornix is the deepest part of the vagina which is located posterior to the uterine cervix and is the most commonly affected site as it is the most dependent part of the pelvis. Vaginal involvement can be nodular or polypoidal. They are seen as T2W hypointense lesions with cystic internal appearance. These cystic areas normally show T1W hyperintensity (►**Fig. 14**). The polypoidal lesions display a T2W hypointense rim due to fibrosis.[9,16]

Tubal involvement is also commonly seen in endometriosis. Hematosalpinx should be considered specific for pelvic endometriosis.[4,17-19] The classical T2 shading seen in endometriomas is not often seen in the case of hematosalpinx that occurs in association with endometriosis (►**Fig. 15**). This is attributed to the deposit occurring over the surface of the fallopian tubes opposed to the implants within the tubes. Peritubal adhesions and subsequent tubal obstruction occur due to recurrent hemorrhage within the serosal implants.[4,18]
Uterine ligaments: MR has reported sensitivity of 69% and specificity of more than 90% for diagnosis of implants in the USL.[4,5,19] They are best visualized on T2W images perpendicular to the cervix (discussed in the posterior compartment). The round ligament is more commonly involved on the right side. The explanation for this is the presence of the sigmoid colon which prevents retrograde implantation on the left side. The implants on the ligaments are seen as areas of T2W hypointensity. The ligaments may appear nodular, show significant hypointense signal on T2W images, and measure more than 1 cm (►**Fig. 16**).[4,5,18] Involvement of the extraperitoneal part of the round ligament is seen (canal of Nuck) as a focal round hypointense mass on T2W images.[20]

Posterior Compartment

It is a virtual space which is located between the posterior vaginal wall and the anterior rectal wall. It consists of the rectovaginal pouch, rectocervical space, the rectovaginal septum, the uterine torus, as well as the rectosigmoid (►**Fig. 17**).

The rectocervical space is also a virtual extraperitoneal space. It is seen behind the cervix in the same plane as the rectovaginal pouch and above the rectovaginal septum.[4,5,11] It is a common site of deep endometrial deposit and is often associated with the involvement of the USL.

The rectovaginal septum is located between the posterior vaginal wall and the anterior rectal wall and extends from the deepest part of the pouch of Douglas to the perineal body.[4] Its involvement is of three types according to the location: in the septum (10%), posterior fornix of the vagina (65%), and hour glass-shaped lesion invoking the posterior fornix with extension into the anterior rectal wall (25%).[21]

The pouch of Douglas also called the rectovaginal pouch is part of the peritoneal cavity and it is a deep pouch situated between the rectouterine folds. It is the most inferior part of the peritoneal cavity and is seen to cover part of the vagina and rectum. It extends to the middle third of the vagina and is difficult to delineate on MRI in the absence of peritoneal fluid (►**Fig. 18A**).[4]

The rectosigmoid is the most commonly affected site, followed by appendix, terminal ileum, cecum, and descending colon.[1] Rectosigmoid involvement commonly presents with cyclical hematochezia, constipation, pencil-like stools, and episodes of intestinal subocclusion.[22] The involvement of the rectosigmoid has been described as a "mushroom cap

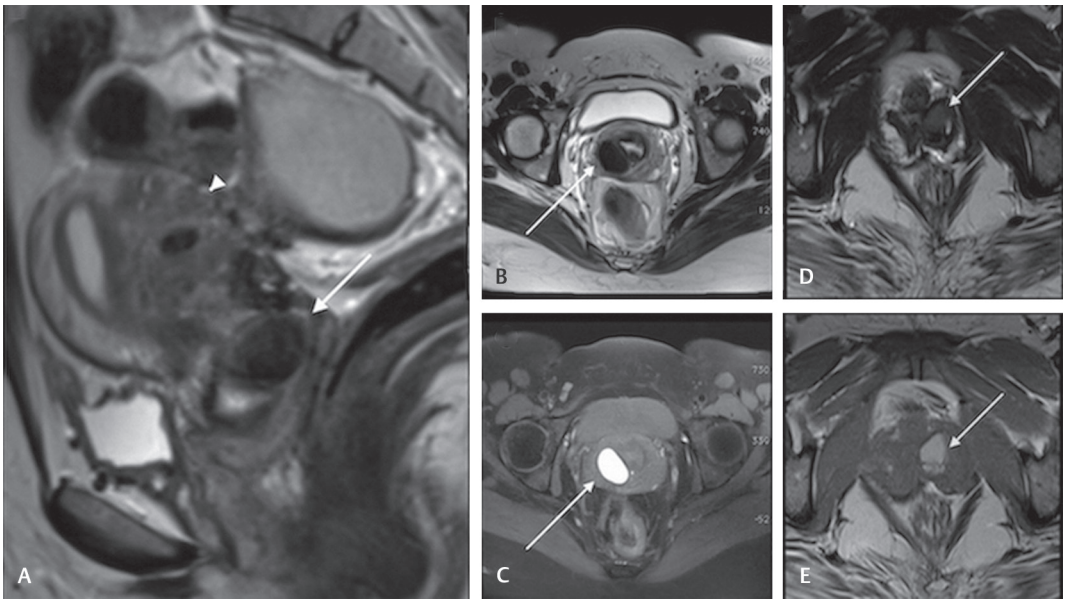

Fig. 14 (**A–E**) T2W sag image (A) showing a cystic deposit in the posterior cervical lip and extending into the posterior fornix (*arrow*). T2W axial (B–D), T1W FS axial (C–E), showing similar deposits in the cervix (*arrows* in B and C) and vagina (D and E). Note is also made of a large deep endometriotic deposit in the posterior uterine myometrium (*arrowhead*). T2W, T2-weighted.

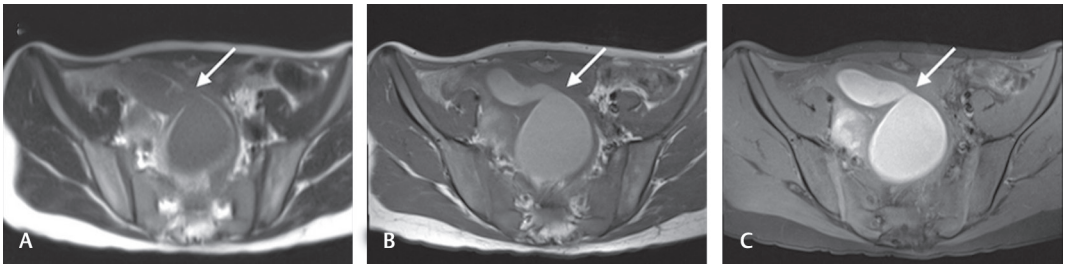

Fig. 15 (**A–C**) T2W (A), T1W (B), and FS T1W (C) images showing a dilated fallopian tube with hemorrhage within it (*arrows*). FS, fat-suppressed; T1W, T1-weighted; T2W, T2-weighted.

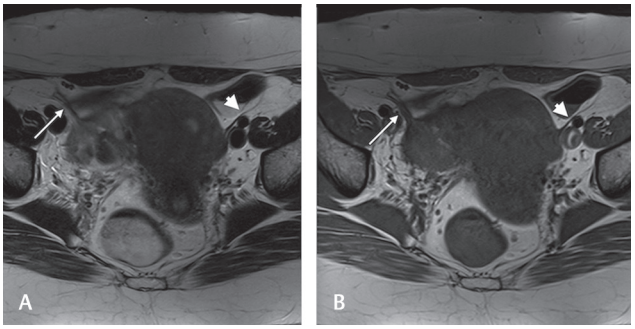

Fig. 16 (**A, B**) T2W (A) and T1W (B) axial images showing a normal thread-like round ligament on the left side (*arrowhead*) and a thickened ligament on the right side (*arrow*). T1W, T1-weighted; T2W, T2-weighted.

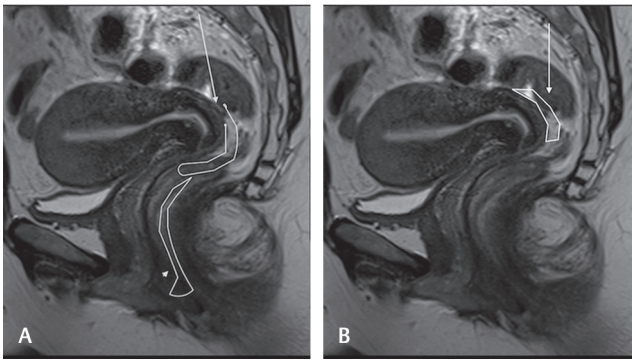

Fig. 17 (**A, B**) T2W sag images showing the recto-vaginal pouch (*arrow* in A), the recto-vaginal septum (*arrowhead* in A), and the retrocervical space (*arrow* in B). T2W, T2-weighted.

sign" (►**Fig. 18**).[22] It is considered a specific finding of solid invasive endometriosis of the rectosigmoid. It is seen as a T2W hypointense lesion involving the serosal surface of the rectum with sparing of the mucosal surface. The low signal intensity base of the mushroom is due to hypertrophy and fibrosis of the muscularis propria, whereas the high signal intensity cap represents the submucosa. The sensitivity of MRI to predict invasion of the muscular propria is 100% and specificity is 75%.[19] It is limited in diagnosing submucosal involvement as edema and endometrial infiltration of the submucosa cannot be differentiated.

Uterine torus is a ridge on the posterior aspect of the cervix where the USLs attach. USL is seen as the in hypointense thread-like bands extending from the uterine torus to the

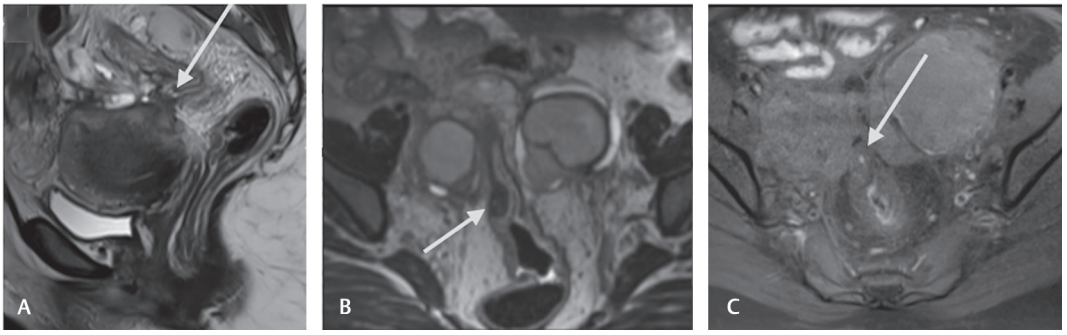

Fig. 18 (**A–C**) T2W sag (A) image showing a deep deposit on the serosal surface of the uterus extending into the wall of the rectosigmoid (*arrow*). Oblique T2W axial image showing an endometriotic deposit in the wall of the rectosigmoid with intact mucosa—mushroom sign (*arrow*). T1W FS axial image (*arrow* in C) showing foci of hyperintensity consistent with endometriosis. T1W, T1-weighted; T2W, T2-weighted.

sacrum (►**Fig. 19A**). Involvement of the USL is seen as thickening and nodularity of the ligaments with foci of hemorrhage within them (►**Fig. 19B**). The involvement of the uterine torus and USLs results in acute retroversion of the uterus or anterior retraction of the rectum due to adhesions.[23]

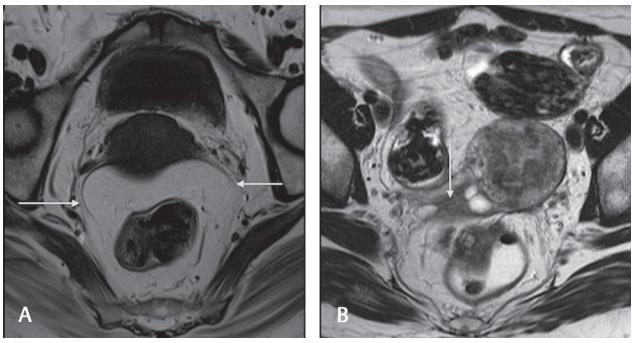

Fig. 19 (**A, B**) T2W oblique axial image (A) showing the normal uterosacral ligaments (*arrows*) and the thickened ligament on the right side with cystic areas within it (*arrow* in B). T2W, T2-weighted.

Anterior Abdominal Wall

Scar endometriosis occurs as a result of the direct implant of functional endometrial tissue into the anterior abdominal wall during pelvic surgery with a reported incidence of 15 to 44%.[24] It can be cystic, mixed, or solid type. The imaging features depend on the phase of the patient's menstrual cycle, the chronicity, the degree of fibrosis, amount of bleeding, and associated inflammation (►**Fig. 20**).[25] The most common differential diagnosis includes a desmoid tumor. The other differentials include a primary tumor of the muscle, suture granuloma, and lymphoma. The presence of subacute hemorrhage in the endometriotic crypts seen as blooming on gradient images and hyperintensity on T1W images helps differentiate scar endometriosis from other lesions.[25]

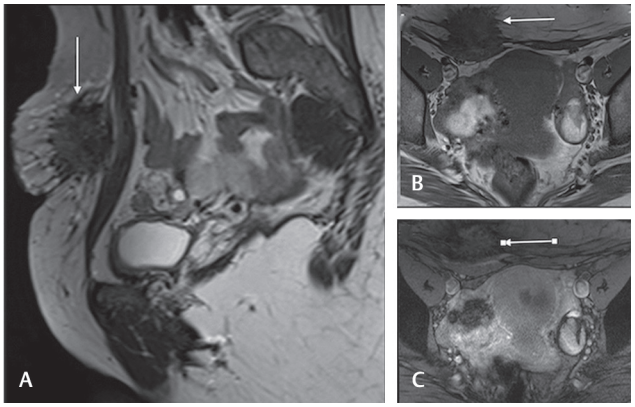

Fig. 20 (**A–C**) T2W sag (A), T1W (B), and gradient (C) axial images showing a spiculated mass in the anterior abdominal wall, involving the rectus abdominis muscle. It shows low SI on T1W and T2W images (*arrows* in A and B) and blooming on the gradient images (*arrow* in C), suggestive of blood products. SI, signal intensity; T1W, T1-weighted; T2W, T2-weighted.

Structured Reporting

Structured MRI (SMR) reports are essential to give clear and comprehensive information to the physician, which can help in treatment planning. The reports should be organized according to the anterior, middle, and posterior compartments which are not true anatomical spaces but mirror the surgeon's approach to treatment and also provide a logical and organized search pattern for the radiologist. ►**Table 1** provides a detailed checklist that the radiologists can refer to while reporting so as to not overlook or miss any lesion.[26]

Conclusion

Endometriosis is a complex benign disease process with varied presentations. It rarely undergoes malignant transformation. Radiologists should be aware of the range of presentations which vary depending on the acuity or chronicity of presentation and the degree of fibrosis. Ultrasonography remains the primary imaging modality, followed by MRI in complex cases. MRI has now emerged as the imaging of choice for deep endometriosis and provides a road map to the surgeon. A SMR helps to organize and standardize reports, and provides essential and precise information to the surgeon.

Table 1 Structured MRI reporting

Anterior compartment				
	Lesion size	**Location**	**Distance from UVJ**	**Hydronephrosis**
Bladder	If present the size in minimum 2 dimensions	Intrinsic/extrinsic	Involved/not involved	Present/absent
Ureters	If present the size in minimum 2 dimensions	Intrinsic/extrinsic	In mm/cm	Present/absent
Vesicouterine space	If present the size in minimum 2 dimensions			
Vesicovaginal space	If present the size in minimum 2 dimensions			
Prevesical space	If present the size in minimum 2 dimensions			

Middle compartment				
Ovaries	Size of ovaries	Presence of follicles	Endometriomas: present/absent Size in three planes	Presence/absence of adhesions Relation to adjoining structures
Fallopian tubes	If dilated then size	Dilated/nondilated	Hydrosalpinx/hematosalpinx: present/absent	Presence/absence of adhesions Relation to adjoining structures
Ligaments	If thickened then length of involvement			Presence/absence of adhesions Relation to adjoining structures
Uterus	Size of uterus Anteverted/ retroverted Endometrial thickness Junctional zone thickness		Lesion: present/absent Size, location and depth	Presence/absence of adhesions Relation to adjoining structures
Cervix			Lesion: present/absent Size, location and depth	
Vagina			Lesion: present/absent Size, location and depth	

Posterior compartment			
	Involved/ not involved	***Size***	***Adjoining structures***
Rectocervical space	Yes/no	If present the size in minimum 2 dimensions	Adhesions, structures involved
Anterior rectal wall	Yes/no	If present the size in minimum 2 dimensions	Circumferential/focal, adhesions, structures involved Muscular layer: invasion present/absent Distance from anal verge
Uterosacral ligament	Yes/no	Length of involvement	Nodularity/diffuse involvement Adhesions, structures involved
Rectovaginal space/ septum	Yes/no	If present the size in minimum 2 dimensions	Adhesions, structures involved

Other locations	
Sigmoid	If present then describe length, size, depth of invasion, and location
Appendix	If present describe size and location
Abdominal wall	If present then describe size and location
Nerves	If involved then describe size and location

Abbreviation: UVJ, ureterovesical junction.

Financial Support and Sponsorship
Nil.

Conflicts of Interest
There are no conflicts of interest.

Acknowledgments
The authors thank Sanjana Sud for helping with the figures and Mini Martin who helped in the formatting of the article.

References

1 Di Paola V, Manfredi R, Castelli F, Negrelli R, Mehrabi S, Pozzi Mucelli R. Detection and localization of deep endometriosis by means of MRI and correlation with the ENZIAN score. Eur J Radiol 2015;84(4):568–574
2 Woodward PJ, Sohaey R, Mezzetti TP Jr. Endometriosis: radiologic-pathologic correlation. Radiographics 2001;21(1): 193–216, 288–294
3 Javiera AF, Cristian MS, Daniel GD, Giancarlo SF, Pablo SS. Endometriosis MRI: pictographic review. Rev Chil Radiol 2012;18:149–156
4 Coutinho A Jr, Bittencourt LK, Pires CE, et al. MR imaging in deep pelvic endometriosis: a pictorial essay. Radiographics 2011;31(2):549–567
5 Collins BG, Ankola A, Gola S, McGillen KL. Transvaginal US of endometriosis: looking beyond the endometrioma with a dedicated protocol. Radiographics 2019;39(5):1549–1568
6 Bazot M, Bharwani N, Huchon C, et al. European Society of Urogenital Radiology (ESUR) guidelines: MR imaging of pelvic endometriosis. Eur Radiol 2017;27(7):2765–2775
7 Bennett GL, Slywotzky CM, Cantera M, Hecht EM. Unusual manifestations and complications of endometriosis–spectrum of imaging findings: pictorial review. AJR Am J Roentgenol 2010;194(6, Suppl):WS34–WS46
8 Glastonbury CM. The shading sign. Radiology 2002;224(1): 199–201
9 Balaban M, Idilman IS, Toprak H, Unal O, Ipek A, Kocakoc E. The utility of diffusion-weighted magnetic resonance imaging in differentiation of endometriomas from hemorrhagic ovarian cysts. Clin Imaging 2015;39(5):830–833
10 Foti PV, Farina R, Palmucci S, et al. Endometriosis: clinical features, MR imaging findings and pathologic correlation. Insights Imaging 2018;9(2):149–172
11 Fritsch H, Clinical anatomy of the female pelvis. In: Hamm B, Forstner R, eds. MRI and CT of the Female Pelvis. New York, NY: Springer; 2007 1–24
12 Wang P, Wang XP, Li YY, et al. Hydronephrosis due to ureteral endometriosis in women of reproductive age. Int J Clin Exp Med 2015;8(1):1059–1065
13 Seracchioli R, Raimondo D, Di Donato N, et al. Histological evaluation of ureteral involvement in women with deep infiltrating endometriosis: analysis of a large series. Hum Reprod 2015;30(4):833–839
14 Tanaka YO, Okada S, Yagi T, et al. MRI of endometriotic cysts in association with ovarian carcinoma. AJR Am J Roentgenol 2010;194(2):355–361
15 Gougoutas CA, Siegelman ES, Hunt J, Outwater EK. Pelvic endometriosis: various manifestations and MR imaging findings. AJR Am J Roentgenol 2000;175(2):353–358
16 Tham WP, Busmanis I, Tan WC, Kwek JW. Polypoid endometriosis of post vaginal fornix: utility of MRI imaging of pelvis with diffusion weighted imaging for diagnosis. Med J Malaysia 2016;71(3):144–146
17 Siegelman ES, Oliver ER. MR imaging of endometriosis: ten imaging pearls. Radiographics 2012;32(6):1675–1691
18 Outwater EK, Siegelman ES, Chiowanich P, Kilger AM, Dunton CJ, Talerman A. Dilated fallopian tubes: MR imaging characteristics. Radiology 1998;208(2):463–469
19 Thalluri AL, Knox S, Nguyen T. MRI findings in deep infiltrating endometriosis: a pictorial essay. J Med Imaging Radiat Oncol 2017;61(6):767–773
20 Kirkpatrick A, Reed CM, Bui-Mansfield LT, Russell MJ, Whitford W. Radiologic-pathologic conference of Brooke Army Medical Center: endometriosis of the canal of Nuck. AJR Am J Roentgenol 2006;186(1):56–57
21 Erkan N, Calişkan C, Yildirim Y, Vardar E, Korkut M. Rectosigmoid endometriosis. Turk J Gastroenterol 2008;19(4):294–296
22 Yoon JH, Choi D, Jang KT, et al. Deep rectosigmoid endometriosis: “mushroom cap” sign on T2-weighted MR imaging. Abdom Imaging 2010;35(6):726–731
23 Del Frate C, Girometti R, Pittino M, Del Frate G, Bazzocchi M, Zuiani C. Deep retroperitoneal pelvic endometriosis: MR imaging appearance with laparoscopic correlation. Radiographics 2006;26(6):1705–1718
24 Blanco RG, Parithivel VS, Shah AK, Gumbs MA, Schein M, Gerst PH. Abdominal wall endometriomas. Am J Surg 2003;185(6):596–598
25 Gidwaney R, Badler RL, Yam BL, et al. Endometriosis of abdominal and pelvic wall scars: multimodality imaging findings, pathologic correlation, and radiologic mimics. Radiographics 2012;32(7):2031–2043
26 Feldman MK, VanBuren WM, Barnard H, Taffel MT, Kho RM. Systematic interpretation and structured reporting for pelvic magnetic resonance imaging studies in patients with endometriosis: value added for improved patient care. Abdom Radiol (NY) 2020;45(6):1608–1622