Article published online: 2021-05-23

Computed Tomography Findings in Intraabdominal Hypertension in Patients with Acute Pancreatitis

Pankaj Gupta[1] Rohan Kamat[1] Jayanta Samanta[2] Harshal Mandavdhare[2] Vishal Sharma[2] Saroj Kant Sinha[2] Usha Dutta[2] Rakesh Kochhar[2]

[1]Department of Radiodiagnosis and Imaging, PGIMER, Chandigarh, India
[2]Department of Gastroenterology, PGIMER, Chandigarh, India

Indian J Radiol Imaging 2021;31:150–156.

Address for correspondence Pankaj Gupta, MD, GE Radiology, Department of Radiodiagnosis and Imaging , PGIMER, Madhya Marg, Sector 12, Chandigarh 160012, India (e-mail: Pankajgupta959@gmail.com).

Abstract

Purpose Intraabdominal hypertension (IAH) in acute pancreatitis (AP) may reduce tissue perfusion and impair organ function and has been shown to portend poor prognosis. We investigated the computed tomography (CT) findings in patients with AP with IAH.

Methods This retrospective study comprised of consecutive patients with AP from June 2016 to June 2018 in whom intraabdominal pressure (IAP) was measured. The patients who underwent a contrast-enhanced CT within 7 days of IAP measurement were included. Using a cutoff of 12 mm Hg for IAP, the patients were divided into IAH and non-IAH groups. Measures of severity and clinical outcome were evaluated. CT parameters were compared between the groups.

Results The IAH group comprised of 41 patients, while there were 20 patients in the non-IAH group. The IAH group was characterized by severe disease, increased incidence of organ failure, increased requirement for drainage and surgery, prolonged hospital and intensive care unit stay. The mortality was not significantly different between the two groups. On univariate analysis, the CT features that were found to be significantly different between the two groups were the presence of collection (p = 0.036), the maximum dimension of collection (p = 0.004), volume of collection (p = 0.019), biliary dilatation (p = 0.011), and the presence of moderate-to-severe pleural effusion (p = 0.009). On multivariate analysis, all these parameters except biliary dilatation were found to be statistically significant.

Conclusion CT findings in patients with AP may suggest IAH. This can be used as an additional marker for severity of AP.

Keywords
- acute pancreatitis
- abdominal compartment syndrome
- computed tomography
- intraabdominal hypertension

Introduction

The steady-state pressure within the abdominal cavity normally ranges between 0 and 5 mm Hg. Body size and muscle tone determine the variability in the abdominal pressures in each individual. Besides, intraabdominal diseases such as ascites, peritonitis, or trauma can affect the intraabdominal pressure (IAP).[1] Change in the volume of any of the contents within the abdominal cavity can alter the IAP.[2] In acute pancreatitis (AP), there is an increase in the capillary permeability and third space volume loss, resulting in visceral and retroperitoneal edema and an elevated IAP.[1,2] The local complications in AP including fluid collections, ascites, and pleural effusion

DOI https://doi.org/10.1055/s-0041-1729768
ISSN 0971-3026

© 2021. Indian Radiological Association
This is an open access article published by Thieme under the terms of the Creative Commons Attribution-NonDerivative-NonCommercial-License, permitting copying and reproduction so long as the original work is given appropriate credit. Contents may not be used for commercial purposes, or adapted, remixed, transformed or built upon. (https://creativecommons.org/licenses/by-nc-nd/4.0/).
Thieme Medical and Scientific Publishers Private Ltd. A-12, Second Floor, Sector -2, NOIDA -201301, India

may also contribute to intraabdominal hypertension (IAH) and abdominal compartment syndrome (ACS).[3,4] Recently, IAH/ACS have been shown to affect the outcomes in patients with AP.[1,2,5,6] IAH and ACS lead to a reduction in tissue perfusion with resultant organ dysfunction, which contributes to the development of ACS.[7] Complications caused by the development of ACS as a result of persistently elevated IAP include reduced pulmonary compliance due to diaphragmatic compression, hepatic and bowel ischemia, cardiovascular and renal dysfunction, thus leading to multiorgan dysfunction syndrome.[1,2,5-10] IAH/ACS can result in prolongation of the hospital stay and can contribute to increase in morbidity and mortality.[9-11] IAH might be predictive of severe disease at an early stage of AP.[5] A few studies have described the computed tomography (CT) features of ACS.[12-17] These studies have been performed in critically ill patients. However, to the best of our knowledge, CT features of IAH in patients with AP have not been described. This study aims to evaluate the CT features of IAH in patients with AP.

Materials and Methods

Our institutional ethics committee approved the protocol of this retrospective observational study (No. INT/IEC/2019/000999 dated 26/04/2019).

Patients

The medical records and imaging files of consecutive patients with AP in whom IAP was measured within 24 hours of admission were evaluated. The study was conducted over 2 years, from June 2016 to June 2018. The patients who underwent a contrast-enhanced CT scan within 7 days of IAP measurement were included in the study. CT scans were performed in patients with mild AP who did not improve within 72 hours of conservative management and in all patients with clinical moderately severe and severe disease. Patients with incomplete clinical details, who underwent a noncontrast CT scan, patients presenting with chronic pancreatitis, and those who underwent drainage procedure or surgical intervention before IAP measurement were excluded from this study. Among 75 patients, 14 patients who did not fulfil any of the predefined criteria were excluded. Finally, 61 patients were evaluated. The IAH and non-IAH groups comprised of 41 and 20 patients, respectively (►**Fig. 1**).

IAP Measurement

IAP was calculated indirectly using intravesicle pressure measurement as has been described previously, within 24 hours of admission.[11] The patient was first asked to lie supine and urinary bladder was catheterized. Through an indwelling Foley catheter, 100 mL of normal saline was injected. A pressure monitoring standpipe was connected to the catheter. The resulting pressure was assessed on this, with zero level of the monitoring device centered at the pubic symphysis. The assessment was performed at the end of expiration. Using a cutoff of 12 mm Hg, the patients were divided into IAH and non-IAH groups.[18]

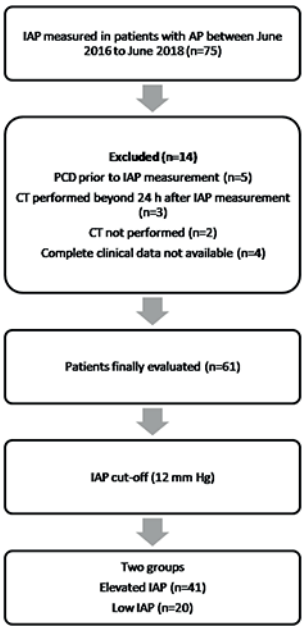

Fig. 1 Flowchart showing patient recruitment. AP, acute pancreatitis; CT, computed tomography; PCD, percutaneous drainage; IAP, intraabdominal pressure.

Abdominal CT

CT scans were performed using one of the 64-, 128-, or 256-detector row CT scanners (Siemens Medical Solutions, Erlangen, Germany or Philips Medical Solution, The Netherlands or GE Healthcare, Milwaukee, WI, United States) at our institution. All patients underwent a contrast-enhanced CT scan following intravenous injection of nonionic contrast agent (body weight × 2 mL) at a rate of 3 mL/s in the antecubital vein. CT scans were acquired 90 seconds after the initiation of contrast injection. The imaging parameters were as follows: tube voltage, 120 kV; tube current, 200 mAs per section; field of view, 42 cm; reconstruction thickness, 2 mm; reconstruction increment, 1 mm; and matrix, 512 × 512. The area scanned extended from the diaphragmatic domes to the ischium.

Two radiologists with 2 years (RK) and 6 years (PG) experience in abdominal imaging reviewed all CT images in consensus. Both the radiologists were blinded to the IAP values and other clinical parameters. CT features studied in each patient are described in ►**Table 1** and ►**Fig. 2**.

Clinical Details and Outcomes

Clinical information recorded in each group were as follows: etiology and severity (based on revised Atlanta classification), bedside index for severity in acute pancreatitis (BISAP), acute physiology and chronic health evaluation (APACHE) II score, Marshall score, type of drainage procedure (percutaneous/endoscopic), indication of drainage, number of percutaneous drainage (PCD), total duration of PCD, C-reactive protein and procalcitonin levels before drainage, blood culture results (sterile or positive), surgery, duration of hospital and intensive care unit (ICU) stay, ventilator requirement and duration of ventilator support, organ failure, number of organ failure, number of hospital admissions, and mortality.

Table 1 CT features studied in each patient

Finding	Definition
Pancreatic necrosis	Hypoenhancing area in the pancreatic parenchyma with attenuation <30 HU. Grade of necrosis was categorized as <30% or >30% according to MCTSI (►**Fig. 3**)
Abdominal collections	Maximum dimension was recorded In cases of multiple collections or collections extending to different spaces, the maximum dimensions of all the collections or all the components of the collection were summed (►**Fig. 4**) The volume of the collection was calculated from its three dimensions using the ellipsoid formula (π/6XLXBXH). In cases of multiple collections, volumes of all the collections were added
Location of collections	Peripancreatic/lesser sac, left, right, and bilateral paracolic gutter
Ascites	Mild (minimal layering of ascites in the gravity-dependent regions such as pelvis and Morrison's pouch) Moderate (presence of fluid in the paracolic gutters) Severe (sufficient ascites to displace the small bowel loops based on the CT grading of ascites as described by Jolles and Coulam[23])
Pleural effusion	Mild (located below the fourth rib), moderate (located below the 2nd rib), severe (extending above the 2nd rib)
Bowel wall thickening	Full thickness of the single wall of the affected bowel, at this level, maximum thickness was measured. Thickness >5 mm in a collapsed loop and >3 mm in a dilated loop were considered abnormal
Bowel dilatation (secondary to gastroparesis, small bowel ileus and large bowel pseudoobstruction)	A cutoff of 3 cm was used for small bowel dilatation and 6 cm for large bowel dilatation except for cecum for which a cutoff of 9 cm was used
Bowel wall enhancement	Hypoenhancement of bowel walls resulting from bowel ischemia was recorded
IHBRD	Caliber of peripheral IHBR >2 mm

Abbreviations: HU, Hounsfield unit; IHBRD, intrahepatic biliary radicle dilatation; MCTSI, modified computed tomography severity index.

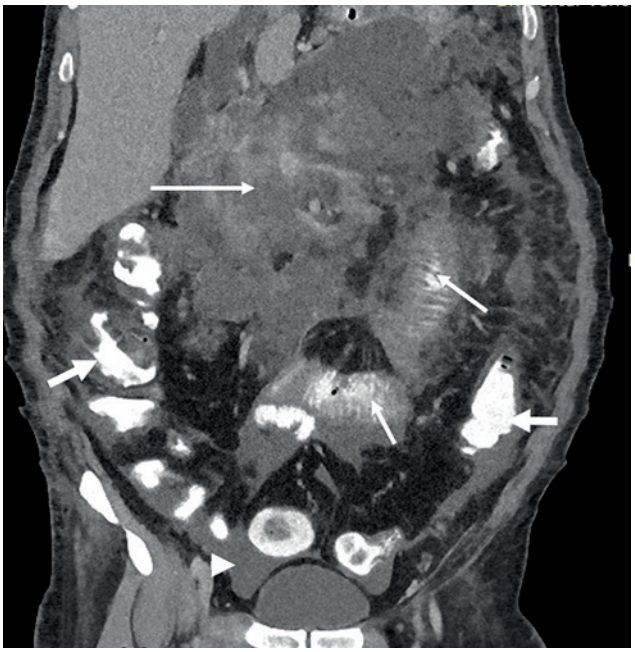

Fig. 2 Coronal computed tomography image in a 40-year-old male with alcohol-induced severe acute pancreatitis with intraabdominal hypertension (intraabdominal pressure was 22 mm Hg) shows a necrotic collection in the lesser sac (arrow), thickening of small bowel (small arrow), and large bowel (thick arrow), as well as ascites (arrowhead).

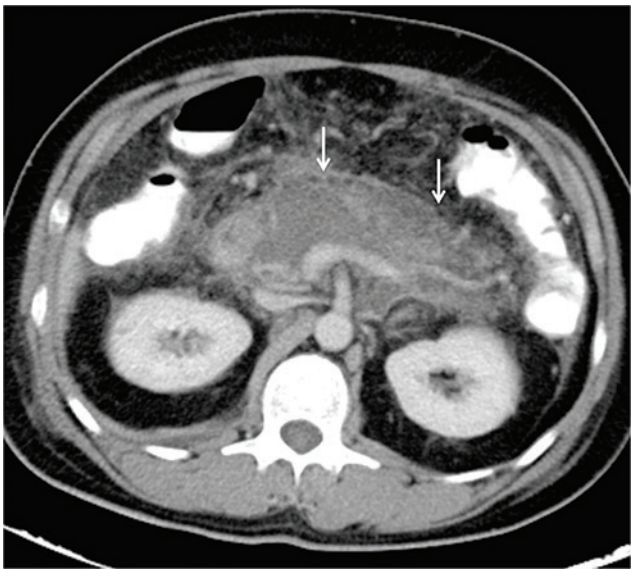

Fig. 3 Axial computed tomography image in a 42-year-old female with gallstone-induced acute pancreatitis and an intraabdominal pressure of 10 mm shows extensive pancreatic parenchymal necrosis (arrow).

All patients were managed as per standard recommendations. These included fluid resuscitation, pain alleviation, support of the organ systems, and nutritional support (enteral or parenteral). Antibiotics were used for extrapancreatic infections and suspected infected pancreatic or extrapancreatic necrosis. Infection of the necrotic collections was suspected whenever the patients' clinical condition worsened and by the presence of gas within the collection on CT. Infection was confirmed by culture of the drain fluid.

Statistical Analyses

Statistical analysis was performed using commercially available software (IBM Statistical Package for the Social Sciences Statistics, release 23; SPSS, Chicago, Illinois, United States). Distribution of categorical data was expressed as frequencies and percentages. The continuous data were expressed as mean with standard deviation or median with range, depending on the distribution. The comparison of categorical data was performed by using the chi-squared test or Fischer's exact test. The comparison of continuous data was performed by using the Mann–Whitney U test or independent Student's *t*-test based on the distribution. Univariate analysis was done to identify the CT features predictive of IAH. Those factors

Fig. 4 Coronal computed tomography image in a 28-year-old with alcohol-induced acute pancreatitis and elevated intraabdominal pressure (IAP) (IAP was 28 mm Hg) shows a large intraabdominal collection (arrow).

that were found to be statistically significant (p-value < 0.05) were evaluated using multivariate analysis.

Logistic regression (LR) analysis with forward LR method was used. All statistical analysis was performed at 5% level of significance and a p-value <0.05 was considered significant.

Results

Baseline Characteristics

The median IAP in the IAH group was 18 mm Hg compared with 10 mm Hg in the non-IAH group (p = 0.001). Both the groups were comparable in terms of age and gender distribution. The median age in the IAH group was 34.5 years and in the non-IAH group was 39 years (p = 0.604). The IAH group was characterized by a severe disease, increased incidence of organ failure, increased requirement for drainage and ICU stay as well as an increased duration of hospital and ICU stay. The median modified computed tomography severity index (CTSI) in the IAH group was 10 compared with 8 in the non-IAH group (p = 0.002). The need for surgery and mortality was however not significantly higher in the IAH group. ►**Table 2** shows the comparison of two groups in terms of baseline characteristics and outcome parameters.

Table 2 Baseline characteristics and outcome parameters in the IAH and non-IAH groups

Parameters	Non-IAH group (n = 20)	IAH group (n = 41)		Confidence interval 25% 75%
Median IAP (mm Hg)	10(6–11)	18(14–29)	0.001	
Median age (y)	39 (30–48.75)	34.5(21–70)	0.604	4.78 8.15
Gender (M/F)	14/6 (70%/30%)	32/9 (78%/22%)	0.537	
Severity (Atlanta)				
Mild	2(10%)	0	0.004	
Moderate	9 (45%)	7(17.1%)		
Severe	9 (45%)	34 (82.9%)		
Modified CTSI	8(2–10)	10(4–10)	0.002	0.81 3.22
Median BISAP score	1.8(0–3)	2(1–4)	0.055	−0.1 0.89
Median APACHE II score	7(0–11)	8(3–18)	0.017	0.39 3.86
Median Marshall score	2 (0–6)	2 (0–6)	0.42	−0.50 1.18
Drainage	13(65%)	39(95.12%)	0.001	
Infected necrosis	10(50%)	11 (26.8%)	0.074	
Surgery	2(10%)	3 (7.3%)	1.00	
Median hospital stay (d)	23.5 (4–52)	29 (7–77)	0.004	−1.23 14.67
Need for ICU stay	8 (40%)	27 (65.8%)	0.01	
ICU stay (d)	2.6(2–15)	5 (2–35)	0.02	0.90 9.99
Organ failure	11 (55%)	34 (83%)	0.041	
Mortality	2(10%)	10(24.4%)	0.305	

Abbreviations: APACHE, acute physiology and chronic health evaluation; BISAP, bedside index for severity in acute pancreatitis; CTSI, computed tomography severity index; ICU, intensive care unit; IAH, intraabdominal hypertension; IAP, intraabdominal pressure.

Table 3 Comparison of CT findings in the IAH versus non-IAH groups

Parameter	Non-IAH group (*n* = 20)	IAH group (*n* = 41)	*p*-Value
Pancreatic necrosis			
Absent	6	8	0.097
<30%	8	10	
>30%	6	23	
Extrapancreatic necrosis	10	31	0.075
Collections	16	40	0.036
Maximum dimension of	8.7	15.32	0.004
collection (cm)			
Volume of collection (cm^3)	119	303.2	0.019
Air foci in collections	4	11	0.56
Peripancreatic/lesser sac collections	16	39	0.56
Left PC gutter collections	4	14	0.25
Right PC gutter collections	1	5	0.37
Bilateral PC gutter collections	1	5	0.37
Bowel wall edema	9	24	0.32
Gastroparesis	0	1	0.48
Ileus	1	2	0.98
Ascites	107	27	0.23
Pleural effusion	16	27	0.25
Grades of ascites			
Mild	9	18	0.23
Moderate	0	7	
Severe	1	2	
Grade of pleural effusion			0.009
Mild	14	11	
Moderate	2	15	
Severe	0	1	
Venous thrombosis	8	18	0.77
Pseudoaneurysm	1	0	0.149
Biliary dilatation	0	11	0.011

Abbreviations: CT, computed tomography; IAH, intraabdominal hypertension; PC, percutaneous.

Table 4 Univariate and multivariate analysis of factors associated with IAH on CT

Parameter	Mean (SD)	Confidence interval		Univariate analysis	Multivariate analysis
		25%	75%		
Presence of collection				$p = 0.036$	$p = 0.041$
Maximum diameter of collection—cm					
IAH	15.32(11.19)	0.836	0.995	$p = 0.004$	$p = 0.036$
Non-IAH	8.7(6.1)				
Volume of collection—cm^3					
IAH	303.24 (422)	31.5	335.25	$p = 0.019$	$p = 0.042$
Non-IAH	119.8(167.9)				
Biliary dilatation				$p = 0.011$	$p = 0.99$
Presence of moderate or severe pleural effusion				$p = 0.009$	$p = 0.045$

Abbreviations: CT, computed tomography; IAH, intraabdominal hypertension; SD, standard deviation.

CT Findings

Pancreatic necrosis was seen in 33 (80.5%) and 14 (70%) patients in the IAH and non-IAH groups, respectively (p = 0.096). The extrapancreatic necrosis was recorded in 31 (75.6) and 10 (50%) patients in the IAH and the non-IAH groups, respectively (p = 0.075). A significantly higher number of patients with IAH had intraabdominal collections (n = 40) compared with those without IAH (n = 16) (p = 0.036). The median dimension of the collection (maximum) was 15.32 cm in the IAH group compared with 8.7 cm in the non-IAH, and the difference was statistically significant (p = 0.004). The grade of pleural effusion and the presence of biliary dilatation were also found to be significantly different between the two groups.

However, there was no statistically significant difference in the presence of ascites, site of collection, the presence of air, bowel dilatation or mural enhancement, and vascular complications between the two groups. ►**Table 3** shows the comparison of CT findings in the two groups.

On univariate analysis, the CT features that were found to be significantly different between the two groups were the presence of fluid collection (p = 0.036), maximum dimension of fluid collection (p = 0.004), volume of collection (p = 0.019), biliary dilatation (p = 0.011), and the presence of moderate-to-severe pleural effusion (p = 0.009). On multivariate analysis, all the above parameters except biliary dilatation reached statistical significance. These results are highlighted in ►**Table 4**.

Discussion

We found that the presence of collection, maximum dimension, volume of the intraabdominal fluid collection, and presence of moderate pleural effusion were the factors that were significantly associated with IAH. The presence or grade of ascites, bowel dilatation, and vascular complications was not significantly different between the two groups.

CT is the mainstay of imaging patients with moderately severe and severe AP. Despite the exposure to ionizing radiations, the lower cost, widespread availability, speed of acquisition, and extensive validation of CT-based grading/scoring systems make it an attractive modality for the evaluation of various aspects of AP.[19-21] Fluid collections represent the most critical local complications of AP.[4] Larger fluid collections will occupy larger space within the abdominal cavity and hence contribute to IAH.[22] In keeping with this hypothesis, both these parameters (viz. presence and size of collection) were found to predict IAH. Ascites and pleural effusion are frequent findings in AP.[23] However, most of these patients have mild amounts of fluid in the abdominal or pleural cavities.[24,25] Severe ascites can be expected to be associated with IAH.[26] However, in the present study, there were only two patients in the IAH group and one patient in the non-IAH group who had severe ascites. The small number of patients with severe ascites did not allow assessment of the significance of this finding.

Similarly, most of the patients with AP have a mild pleural effusion.[25] A similar trend was seen in the present study. Severe pleural effusion was seen in only one patient in IAH group. However, a more significant number of patients with IAH had moderate ascites and pleural effusion. The presence of moderate pleural effusion was found to be significantly different between the two groups on multivariate analysis. Similarly, there were very few patients with gastroparesis and ileus in each group. None of the patients had colonic pseudoobstruction in the present study.

Fluid collection in AP has been reported to be a significant risk factor for IAH in a previous study.[27] The number rather than the size of the collections was assessed in the previous study.[27] However, we do understand that the pancreatic collections do not respect abdominal compartments and invariably extend to multiple retroperitoneal and sometimes peritoneal spaces.[28] Thus, the number of collections may represent the number of retroperitoneal spaces to which the collection extends. We believe that rather than the number of collections, the size of the collection (maximum dimension or volume) would be a better objective criterion.[29] In the study by Zhao et al, CTSI and pancreatic necrosis were found to be significantly associated with IAP.[30] We also found that patients with elevated IAP had a significantly higher modified CTSI.

The worse clinical outcomes in patients with IAH are expected. The mortality in the IAH group in the present study was higher compared with the non-IAH group (24.4 vs. 10%, *p = 0.305).* This may not be entirely explained by the effect of IAH alone. Majority of patients in the IAH group had severe disease compared with 45% of the patients in the non-IAH group who had severe AP that could explain the difference in mortality that was not statistically significant. The longer hospitalization as well as ICU stay and higher organ failure can be similarly explained. These results are in line with previous studies.[7,9,18,27]

We believe that the results of our study will allow identification of patients at risk of IAH early in the course of the illness. This information, in turn, will allow early intervention aimed at reducing IAP in the high-risk group.[31,32] However, prospective studies with larger patient cohorts will validate these findings.

There were a few limitations in the study. There were fewer patients with severe ascites, severe pleural effusion, gastroparesis, and ileus. Though these are less frequently encountered in patients with AP, these findings are likely to contribute to IAH. Thus, a study with a larger number of these findings will allow us to estimate their exact role in IAH.

In conclusion, IAH in AP is associated with a more extended hospital stay and increased morbidity. The presence as well as the size of the fluid collection and moderate pleural effusion were significantly associated with IAH. This knowledge will allow timely interventions in this group of patients.

Financial Support and Sponsorship
Nil.

Conflicts of Interest
There are no conflicts of interest.

References

1 Al-Bahrani AZ, Abid GH, Holt A, et al. Clinical relevance of intra-abdominal hypertension in patients with severe acute pancreatitis. Pancreas 2008;36(1):39–43
2 Chen H, Li F, Sun J-B, Jia J-G. Abdominal compartment syndrome in patients with severe acute pancreatitis in early stage. World J Gastroenterol 2008;14(22):3541–3548
3 Dambrauskas Z, Parseliunas A, Gulbinas A, Pundzius J, Barauskas G. Early recognition of abdominal compartment syndrome in patients with acute pancreatitis. World J Gastroenterol 2009;15(6):717–721
4 Gupta P, Rana P, Bellam BL, et al. Site and size of extrapancreatic necrosis are associated with clinical outcomes in patients with acute necrotizing pancreatitis. Pancreatology 2020;20(1):9–15
5 Bansal A, Gupta P, Singh H, et al. Gastrointestinal complications in acute and chronic pancreatitis. JGH Open 2019;3(6):450–455
6 Aitken EL, Gough V, Jones A, Macdonald A. Observational study of intra-abdominal pressure monitoring in acute pancreatitis. Surgery 2014;155(5):910–918
7 Singh AK, Samanta J, Dawra S, et al. Reduction of intra-abdominal pressure after percutaneous catheter drainage of pancreatic fluid collection predicts survival. Pancreatology 2020;20(4):772–777
8 Burch JM, Moore EE, Moore FA, Franciose R. The abdominal compartment syndrome. Surg Clin North Am 1996;76(4):833–842
9 Sugerman HJ, Bloomfield GL, Saggi BW. Multisystem organ failure secondary to increased intraabdominal pressure. Infection 1999;27(1):61–66
10 Cheatham ML, White MW, Sagraves SG, Johnson JL, Block EF. Abdominal perfusion pressure: a superior parameter in the assessment of intra-abdominal hypertension. J Trauma 2000;49(4):621–626, discussion 626–627
11 Kumar P, Gupta P, Rana S. Thoracic complications of pancreatitis. JGH Open 2018;3(1):71–79
12 Maerz L, Kaplan LJ. Abdominal compartment syndrome. Crit Care Med 2008;36(4, Suppl):S212–S215
13 Iberti TJ, Kelly KM, Gentili DR, Hirsch S, Benjamin E. A simple technique to accurately determine intra-abdominal pressure. Crit Care Med 1987;15(12):1140–1142
14 Pickhardt PJ, Shimony JS, Heiken JP, Buchman TG, Fisher AJ. The abdominal compartment syndrome: CT findings. AJR Am J Roentgenol 1999;173(3):575–579
15 Epelman M, Soudack M, Engel A, Halberthal M, Beck R. Abdominal compartment syndrome in children: CT findings. Pediatr Radiol 2002;32(5):319–322
16 Al-Bahrani AZ, Abid GH, Sahgal E, O'shea S, Lee S, Ammori BJ. A prospective evaluation of CT features predictive of intra-abdominal hypertension and abdominal compartment syndrome in critically ill surgical patients. Clin Radiol 2007;62(7):676–682
17 Wachsberg RH, Sebastiano LL, Levine CD. Narrowing of the upper abdominal inferior vena cava in patients with elevated intraabdominal pressure. Abdom Imaging 1998;23(1):99–102
18 Malbrain MLNG, Cheatham ML, Kirkpatrick A, et al. Results from the international conference of experts on intra-abdominal hypertension and abdominal compartment syndrome. I. definitions. Intensive Care Med 2006;32(11):1722–1732
19 Gupta P, Jain R, Koshi S, et al. Radiation dose from computed tomography in patients with acute pancreatitis: an audit from a tertiary care referral hospital. Abdom Radiol (NY) 2020;45(5):1517–1523
20 Gupta P, Dawra S, Chandel K, et al. Fat-modified computed tomography severity index (CTSI) is a better predictor of severity and outcome in patients with acute pancreatitis compared with modified CTSI. Abdom Radiol (NY) 2020;45(5):1350–1358
21 Gupta P, Chayan Das G, Sharma V, et al. Role of computed tomography in prediction of gastrointestinal fistula in patients with acute pancreatitis. Acta Gastroenterol Belg 2019;82(4):495–500
22 Mallick B, Dhaka N, Gupta P, et al. An audit of percutaneous drainage for acute necrotic collections and walled off necrosis in patients with acute pancreatitis. Pancreatology 2018;18(7):727–733
23 Jolles H, Coulam CM. CT of ascites: differential diagnosis. AJR Am J Roentgenol 1980;135(2):315–322
24 Mortele KJ, Wiesner W, Intriere L, et al. A modified CT severity index for evaluating acute pancreatitis: improved correlation with patient outcome. AJR Am J Roentgenol 2004;183(5):1261–1265
25 Maringhini A, Ciambra M, Patti R, et al. Ascites, pleural, and pericardial effusions in acute pancreatitis. A prospective study of incidence, natural history, and prognostic role. Dig Dis Sci 1996;41(5):848–852
26 Samanta J, Rana A, Dhaka N, et al. Ascites in acute pancreatitis: not a silent bystander. Pancreatology 2019;19(5):646–652
27 Ke L, Ni HB, Sun JK, et al. Risk factors and outcome of intra-abdominal hypertension in patients with severe acute pancreatitis. World J Surg 2012;36(1):171–178
28 Gupta P, Virk M, Gulati A, et al. Unusual sites of necrotic collections in acute necrotizing pancreatitis: association with parenchymal necrosis and clinical outcomes. Dig Dis Sci 2020;•••:Epub ahead of print 10.1007/ S10620–020–06526–6
29 Gupta P, Kumar-M P, Verma M, et al. Development and validation of a computed tomography index for assessing outcomes in patients with acute pancreatitis: "SMART-CT" index. Abdom Radiol (NY) 2020;•••:Epub ahead of print 10.1007/ s00261-020-02740-y
30 Zhao JG, Liao Q, Zhao YP, Hu Y. Mortality indicators and risk factors for intra-abdominal hypertension in severe acute pancreatitis. Int Surg 2014;99(3):252–257
31 Gupta P, Gupta J, Kumar C, et al. Aggressive percutaneous catheter drainage protocol for necrotic pancreatic collections. Dig Dis Sci 2020;65(12):3696–3701
32 Gupta P, Koshi S, Samanta J, et al. Kissing catheter technique for percutaneous catheter drainage of necrotic pancreatic collections in acute pancreatitis. Exp Ther Med 2020; 20(3):2311–2316