



Functional Outcomes of Bilateral Reverse Total Shoulder Arthroplasty: A Systematic Review

Michael-Alexander Malahias¹ Emmanouil Brilakis¹ Dimitrios Chytas² Dimitrios Gerogiannis¹
Grigorios Avramidis¹ Emmanouil Antonogiannakis¹

¹3rd Orthopaedic Department, Hygeia Hospital, Athens, Greece

²2nd Orthopaedic Department, School of Medicine, National and Kapodistrian University of Athens, Athens, Greece

Address for correspondence Michael-Alexander Malahias, MD, PhD,
3rd Orthopaedic Department, Hygeia Hospital, Erythrou Stavrou 4,
Marousi 15123, Greece (e-mail: alexandermalahias@yahoo.gr).

Joints 2019;7:188–198.

Abstract

Purpose To answer the question whether bilateral reverse total shoulder arthroplasty (RTSA) is a safe and effective treatment which results in satisfactory clinical and functional outcomes with low complications rates. A second question to be answered was: what is the quality of the evidence of the already published studies which investigate the use of bilateral RTSA?

Methods Two reviewers independently conducted a systematic search according to the Preferred Reporting Items for Systematic Reviews and Meta-Analyses using the MEDLINE/PubMed database and the Cochrane Database of Systematic Reviews. These databases were queried with the terms “reverse” AND “total” AND “shoulder” AND “arthroplasty” AND “clinical.” Descriptive statistics were used to summarize the data.

Results From the 394 initial studies we finally selected and assessed 6 clinical studies which were eligible to our inclusion–exclusion criteria. The aforementioned studies included in total 203 patients (69% females; mean age range: 67.1–75 years; mean follow-up range: 12–61 months). From those, 168 patients underwent staged bilateral RTSA (mean duration between first and second operation range: 8–21.6 months) and the rest of them a unilateral RTSA as controlled treatment. Almost all mean clinical and functional scores, which were used to assess the therapeutic value of bilateral RTSA, depicted significant postoperative improvement in comparison with the mean preoperative values. The modified Coleman methodology score, which was used to assess the quality of the studies, ranged from a minimum of 36/100 to a maximum of 55/100.

Conclusion Despite the lack of high-quality evidence, staged bilateral RTSA seems to be a safe and effective procedure for patients with cuff tear arthropathy, which results in significantly improved clinical and functional outcomes and low reoperations' rates.

Level of Evidence Systematic review of level III-IV therapeutic studies.

Keywords

- reverse total shoulder arthroplasty
- staged bilateral arthroplasty
- cuff tear arthropathy
- systematic review
- modified Coleman score

received
July 17, 2018
accepted after revision
April 18, 2021
published online
June 18, 2021

DOI <https://doi.org/10.1055/s-0041-1730974>.
ISSN 2282-4324.

© 2021. The Author(s).

This is an open access article published by Thieme under the terms of the Creative Commons Attribution-NonDerivative-NonCommercial-License, permitting copying and reproduction so long as the original work is given appropriate credit. Contents may not be used for commercial purposes, or adapted, remixed, transformed or built upon. (<https://creativecommons.org/licenses/by-nc-nd/4.0/>)

Georg Thieme Verlag KG, Rüdigerstraße 14, 70469 Stuttgart, Germany

Introduction

The Grammont reverse total shoulder arthroplasty (RTSA) was initially used for elderly, low-demand individuals with end-stage rotator cuff tear (RCT) arthropathy.¹ Later on, RTSA was proven effective for the treatment of acute, comminuted proximal humeral fractures in elderly patients, because the design does not rely on a functioning rotator cuff for overhead shoulder range of motion.^{2,3} This prosthetic model has found novel indications for many other pathologies, such as irreparable RCTs⁴ with or without pseudoparalysis, tumors,⁵ and implant failures.^{6,7}

Although RTSA has gained popularity in recent years, providing good shoulder elevation, yet less predictable rotations.⁸ Concerns still exist regarding bilateral RTSA over lack of rotations bilaterally and resultant difficulties with remaining activities of daily living (ADLs).^{8,9} Some surgeons are reluctant to perform a RTSA on both shoulders due to these reasons.¹⁰ Hemiarthroplasty has been suggested as another option to treat rotator cuff deficient shoulders, instead of RTSA. However, previous studies have demonstrated the inferiority of hemiarthroplasty compared with RTSA in patients with cuff tear arthropathy (CTA) with regards to pain and function, making the combination of hemiarthroplasty and reverse arthroplasty in a single individual less than ideal.¹¹

The aim of this systematic review was to answer the question whether bilateral RTSA is a safe and effective treatment which results in satisfactory clinical and functional outcomes with low complication rates. Another question to be answered was: What is the quality of the evidence of the already published studies which investigate the use of bilateral RTSA? Second, we aimed to investigate questions in relation to the optimal time interval between first and second surgery, the role of subscapularis repair in RTSA, the effect of internal rotation (IR) deficit on personal hygiene habits, the comparison between the outcomes of first and second operated shoulder, and the comparison between the outcomes of bilateral RTSA and unilateral RTSA. Our hypothesis was that bilateral RTSA would be proven a safe and effective treatment.

Methods

Two reviewers independently conducted a systematic search according to the Preferred Reporting Items for Systematic Reviews and Meta-Analyses (PRISMA) using the MEDLINE/PubMed database and the Cochrane Database of Systematic Reviews.¹² These databases were queried with the terms “reverse” AND “total” AND “shoulder” AND “arthroplasty” AND “clinical.” To maximize the search, backward chaining of reference lists from retrieved papers was also undertaken. A preliminary assessment of only the titles and abstracts of the search results was initially performed. The second stage involved a careful review of the full-text publications.

The inclusion criteria were: (1) studies describing human subjects of any age and gender and (2) studies that include a population of at least 10 patients who underwent staged

(procedures performed in different hospitalizations) bilateral RTSA. Exclusion criteria were: (1) studies not specifically dealing with the staged bilateral RTSA, (2) preclinical, cadaveric, or animal studies, (3) non-full-text articles, (4) literature or systematic reviews, (5) case reports, (6) technical notes, (7) editorial comments, (8) expert opinions, (9) studies with less than 12 months' follow-up, (10) studies without any clinical outcomes, (11) articles not written in English, and (12) studies published after February 1, 2018 (end of our search).

Differences between reviewers were discussed until agreement was achieved. They independently extracted data from each study and assessed variable reporting of outcome data. Descriptive statistics were calculated for each study and parameters analyzed. The methodological quality of each study and the different types of detected bias were assessed independently by each reviewer with the use of modified Coleman methodology score (CMS).¹³ Selective reporting bias like publication bias were not included in the assessment. The primary outcome measure was the postoperative statistically significant improvement of the clinical and functional scores in comparison with the preoperative scores per study. Secondary outcomes were the complications' and reoperations' rate per study.

Results

From the 394 initial studies we finally chose and assessed 6 clinical studies which were eligible to our inclusion-exclusion criteria. A summary flowchart of our literature search according to the PRISMA guidelines can be found in ►Fig. 1.

The eligible articles included five retrospective studies (83.3%)^{10,14–17} and one prospective (16.7%).¹⁴ All articles were published between 2013 and 2017.^{8,10,14–17} Four out of six studies (66.7%) were level IV,^{8,14,15,17} while two studies (33.3%) were level III.^{10,16} The aforementioned studies included in total 203 patients (►Table 1). From those, 168 patients underwent bilateral RTSA and the rest of them a controlled treatment. The control groups were always treated with unilateral RTSA.

The mean age of the patients who were included in this review ranged between 67.1 and 75 years, whereas the vast majority of these patients were females (69%) (►Table 1). The mean follow-up ranged between 12 and 61 months. The study of Mellano et al was the only one which assessed the 5-year long-term results of staged bilateral RTSA.¹⁴

Approximately three-quarters of patients (75.7%) treated with staged bilateral RTSA were initially suffering from CTA (►Table 1). A small minority (8.1%) was diagnosed with a massive irreparable RCT without any sign of arthritis, whereas 6.5% had a previous failed arthroplasty, 4.9% were suffering from rheumatoid arthritis, and 4.3% from glenohumeral osteoarthritis with an intact rotator cuff. As expected, no one from the patients who were treated with a bilateral RTSA was initially suffering from humeral fracture.

Clinical and Functional Outcome Variables

The most commonly used subjective clinical and functional score was the Constant score (83.3% of the studies),^{8,10,15–17}

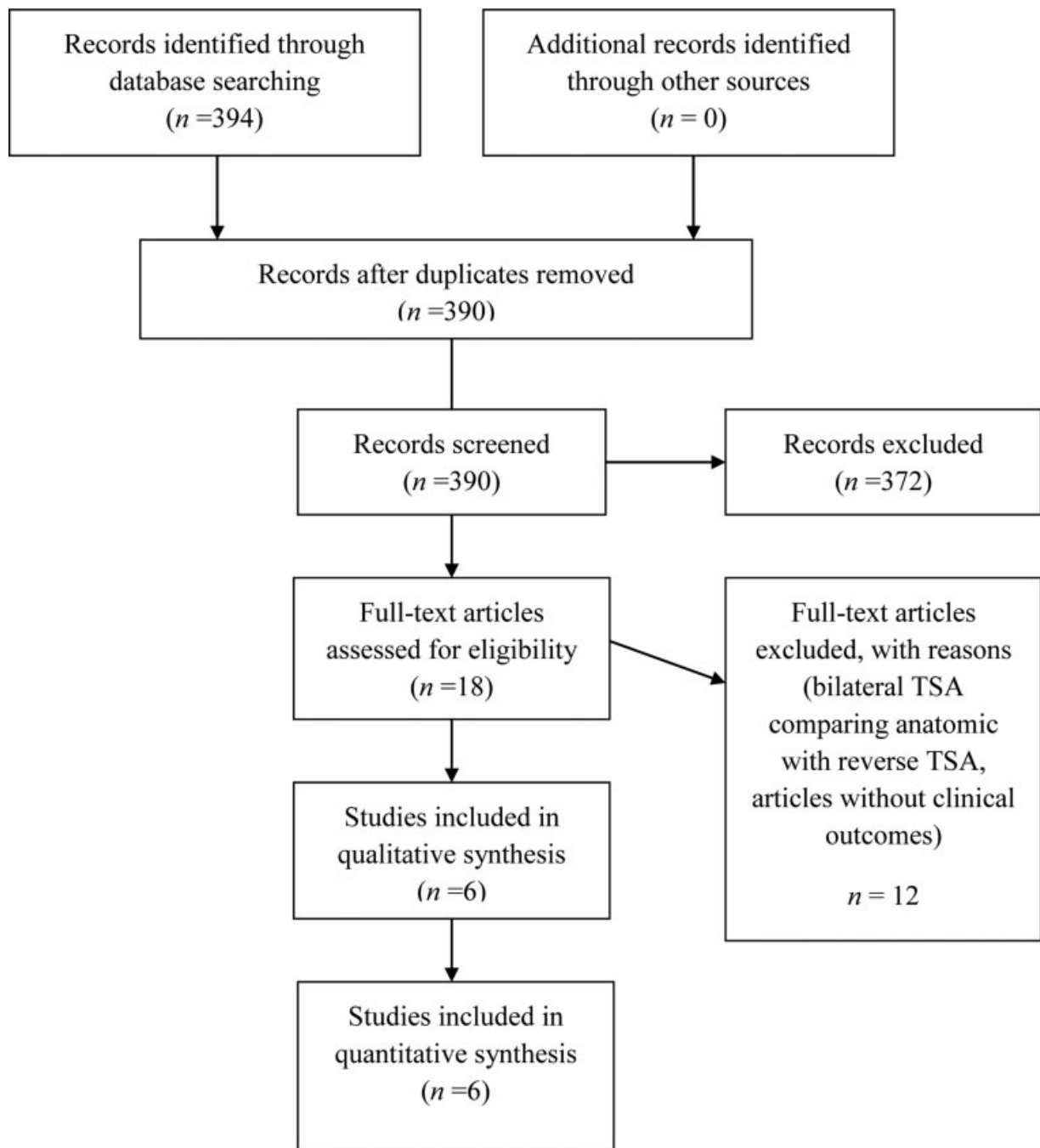


Fig. 1 Preferred Reporting Items for Systematic Reviews and Meta-Analyses (PRISMA) flowchart.

while the American Shoulder and Elbow Surgeons (ASES) score was utilized in four studies (66.7%).^{10,14,16,17} Less commonly used outcome variable was the visual analog scale (VAS) for pain which was deployed in 33.3% of the studies included in this review,^{10,14} as well as the 12-Item Short-Form Health Survey (SF-12; 33.3% of the studies),^{14,17} the Constant and Shoulder Pain and Disability Index score (SPADI; 33.3% of the studies),^{15,17} the Subjective Shoulder Value (SSV; 33.3% of the studies),^{8,10} and the Simple Shoulder Test (SST; 33.3%).^{14,17} One study made use of the University of California–Los Angeles score (16.6% of all studies),¹⁷ and another one the Western Ontario Osteoarthritis of the

Shoulder (16.6% of the studies) and the Single Assessment Numeric Evaluation score (16.6% of the studies)¹⁶ (► **Table 2**).

All mean clinical and functional scores, which were used to assess the therapeutic value of staged bilateral RTSA, depicted significant postoperative improvement in comparison with the mean preoperative values, with the exception of SF-12^{14,17} (► **Table 2**). According to Stevens et al, mean SF-12 did not improve significantly (it increased from 33.3 to 38.8 chronologically for the first RTSA and from 35.5 to 38.3 for the second RTSA).¹⁷ In addition, Mellano et al documented that the only score which was not significantly ameliorated among all postoperative scores of their study

Table 1 Characteristics of included studies

Authors	Year of publication	Type of study	Level of evidence	Number of patients	Sex	Mean age (y)	Follow-up (mo)	Reason for surgery
Mellano et al ¹⁴	2017	Retrospective case series	IV	50	31 F, 19 M	71.8	61	66% CTA, 20% MRCT, 13% OA, 2% prior failed hemiarthroplasty
Levy et al ⁸	2017	Prospective case series	IV	19	15 F, 4 M	74.5	48.4	In 13 patients CTA, in 1 patient failed rotator cuff repairs of MRCT, in 1 patient OA, in 4 patients RA. In 6 patients the RTSA was performed as revision arthroplasty
Wirth et al ¹⁵	2016	Retrospective case series	IV	57	40 F, 17 M	75	12–24	In 51 patients: rotator cuff tear/arthritis, in 4 patients: RA, in 1 patient: 1 humeral head necrosis, in 1 patient: secondary arthritis
Morris et al ¹⁶	2015	Retrospective cohort study	III	11 (bilateral RSA), 19 (unilateral RSA)	8 F, 3 M (bilateral RTSA) 13 F, 6 M (unilateral RTSA)	67.1 (bilateral RTSA) 69.2 (unilateral RTSA)	Bilateral RTSA group: 36.8 Unilateral RTSA group: 38.9	CTA
Stevens et al ¹⁷	2014	Retrospective case series	IV	15	10 F, 5 M	72.9	33.4	CTA
Wiater et al ¹⁰	2013	Retrospective case-control study	III	16 (bilateral group) 16 (unilateral group)	12 F, 4 M (bilateral group) 12 F, 4 M (unilateral group)	71 (bilateral group) 72 (unilateral group)	Bilateral group: 46 (first shoulder), 33 (second shoulder) Unilateral group: 33	12 CTA, 5 failed humeral head replacement, 4 MRCT, 3 RA, 2 RA/CTA, 3 RCT/OA, 1 OA, 1 RCT, 1 RA/RCT

Abbreviations: CTA, cuff tear arthropathy; F, female; M, male; MRCT, massive rotator cuff tear; OA, osteoarthritis; RA, rheumatoid arthritis; RTSA, reverse total shoulder arthroplasty; RCT, rotator cuff tear.

Table 2 Preoperative and postoperative clinical and functional outcomes per study

Authors	Preoperative mean scores	Postoperative mean scores	Significant difference between pre-operative and postoperative scores
Mellano et al ¹⁴	VAS pain: 5.5 ASES: 37.5 ASES function: 9.0 SST: 2.5 SF-12 MCS: 53.6 SF-12 PCS: 31.2	VAS pain: 0.7 ASES: 76.7 ASES function: 19.9 SST: 8.9 SF-12 MCS: 54.7 SF-12 PCS: 41.8	Yes Yes Yes Yes No Yes
Levy et al ⁸	CS: 18.7 SSV: 2.1/10	CS: 65.1 SSV: 9.2/10 Mean ADLEIR score was 33 of 36	Yes Yes Yes
Wirth et al ¹⁵	CS: 30 (first shoulder), 34 (second shoulder) SPADI score: 30 (first shoulder) 34 (second shoulder)	CS: 70 (first shoulder), 62 (second shoulder) SPADI score: 73 (first shoulder) 72 (second shoulder)	Yes Yes Yes Yes
Morris et al ¹⁶	CS-first shoulder-bilateral group: 15.8 CS-second shoulder-bilateral group: 20.6 CS-unilateral group: 18.9 ASES-first shoulder-bilateral group: 24.7 ASES-second shoulder-bilateral group: 25.6 ASES-unilateral group: 26.8 WOOS- first shoulder-bilateral group: 82.4 WOOS- second shoulder-bilateral group: 77.5 WOOS-unilateral group: 75.8 SANE- first shoulder-bilateral group: 24.8 SANE- second shoulder-bilateral group: 33.3 SANE-unilateral group: 27.6	CS-first shoulder-bilateral group: 63.8 CS-second shoulder-bilateral group: 58.4 CS-unilateral group: 56.6 ASES-first shoulder-bilateral group: 73.5 ASES-second shoulder-bilateral group: 68.0 ASES-unilateral group: 64.7 WOOS- first shoulder-bilateral group: 26.0 WOOS- second shoulder-bilateral group: 30.4 WOOS-unilateral group: 32.5 SANE- first shoulder-bilateral group: 56.0 SANE- second shoulder-bilateral group: 53.4 SANE-unilateral group: 53.8	Yes Yes Yes Yes Yes Yes Yes Yes Yes Yes Yes (Regarding all scores, insignificant difference between unilateral and bilateral group was noted postoperatively)
Stevens et al ¹⁷	First RTSA SPADI: 79.0 Constant: 32.2 ASES: 43.5 UCLA: 14.4 SST: 4.1 SF-12: 33.3 Second RTSA SPADI: 86.8 Constant: 33.9 ASES: 28.3 UCLA: 14.0 SST: 3.5 SF-12: 35.5	First RTSA SPADI: 37.0 Constant: 59.7 ASES: 77.7 UCLA: 27.9 SST: 8.6 SF-12: 38.8 Second RTSA SPADI: 33.9 Constant: 59.5 ASES: 81.0 UCLA: 27.7 SST: 8.6 SF-12: 38.3	Yes Yes Yes Yes Yes No Yes Yes Yes Yes Yes Yes No
Wiater et al ¹⁰	First shoulder bilateral group: ASES: 23.50 CS: 22.40 SSV: 24.2 VAS for pain: 7.06 First shoulder control group: ASES: 39.19 CS: 28.63 SSV: 20.58	First shoulder bilateral group: ASES: 83.7 CS: 60.1 SSV: 81.2 VAS for pain: 0.81 First shoulder control group: ASES: 77.4 CS: 62.5 SSV: 81.7	Yes Yes Yes Yes Yes Yes Yes Yes Yes

Table 2 (Continued)

Authors	Preoperative mean scores	Postoperative mean scores	Significant difference between pre-operative and postoperative scores
	VAS for pain: 5.25 Second shoulder bilateral group: ASES: 39.1 CS: 35.4 SSV: 24.0 VAS for pain: 6.63 Second shoulder control group: ASES: 33.9 CS: 25.5 SSV: 14.8 VAS for pain: 6.00	VAS for pain: 1.63 Second shoulder bilateral group: ASES: 68.3 CS: 54.4 SSV: 67.8 VAS for pain: 2.31 Second shoulder control group: ASES: 86.2 CS: 67.40 SSV: 83.4 VAS for pain: 0.19	Yes Yes Yes Yes Yes Yes Yes

Abbreviations: ADLEIR, the Activities of Daily Living External and Internal Rotations score; ASES, American Shoulder and Elbow Surgeons score; CS, Constant score; MCS, mental component subscore of SF-12; PCS, physical component subscore of SF-12; RTSA, reverse total shoulder arthroplasty; SANE, Single Assessment Numeric Evaluation score; SF-12, 12-Item Short-Form Health Survey; SPADI, Shoulder Pain and Disability Index score; SST, Simple Shoulder Test; SSV, Subjective Shoulder Value; UCLA, University of California–Los Angeles; VAS, visual analog scale; WOOS, Western Ontario Osteoarthritis of the Shoulder.

was the mental component subscore of SF-12 (it increased from 53.6 to 54.7).¹⁴ On the other hand, the physical component subscore of SF-12 was significantly increased (from 31.2 to 41.8).¹⁴

Specifically, as for the patients who underwent bilateral RTSA, the mean preoperative VAS pain score ranged from 5.5 to 7.06 and the postoperative one from 0.7 to 2.3 (► **Table 2**). The mean preoperative ASES score varied between 23.5 and 43.5, and the postoperative one between 68 and 83.7. As far as the Constant score is concerned, the mean preoperative values ranged from 15.8 to 35.4 and the mean postoperative ones from 54.4 to 70. Furthermore, from a mean preoperative SPADI score ranging between 30 and 86, we reached to mean postoperative values ranging from 33.9 to 73. Regarding the SST score, its mean preoperative value ranged from 2.5 to 4.1, whereas its mean postoperative one from 8.6 to 8.9. Last but not least, while the mean preoperative SSV score ranged from 21/100 to 24.2/100, the mean final postoperative values ranged between 67.8/100 and 92/100.

Range of Motion

The mean preoperative active forward flexion/elevation, external rotation (ER), and abduction values ranged from a minimum of 35 degrees (for the first shoulder and 48 degrees for the second shoulder) to a maximum of 77 degrees (for the first shoulder and 85 degrees for the second shoulder), from 10 degrees (for the first shoulder or 13.7 degrees for the second shoulder) to 29 degrees (for the first shoulder or 34 degrees for the second shoulder), and from 35 degrees (for the first shoulder or 46 degrees for the second shoulder) to 102 degrees (for the first shoulder or 105 degrees for the second shoulder), respectively. The mean postoperative active forward elevation, ER, and abduction values ranged from a minimum of 121 degrees (for the first shoulder or 112 degrees for the second shoulder) to a maximum of

143 degrees, from 17.1 degrees (for the first shoulder or 19 degrees for the second shoulder) to 45 degrees, and from 112 degrees (for the first shoulder or 107 degrees for the second shoulder) to 142 degrees (for the first shoulder or 121 degrees for the second shoulder), respectively. Regarding IR in abduction, the only study which made use of quantitative measurements documented a preoperative mean value of 39 degrees and a postoperative mean value of 58 degrees¹⁴ (► **Table 3**).

Postoperative Scapular Notching

Postoperative scapular notching, which was graded by the Nerot-Sirveaux system,¹⁸ was assessed in half (50%) of the studies included in this review.^{8,14,15} The vast majority (69.7%) of the patients, who were radiographically assessed, were found without any sign of notching after surgery. From the rest of the patients, 10.6% were classified with a grade 1 postoperative scapular notching, whereas grade 2 had 19.7% and grade 3 only 1.4% of the patients assessed (► **Table 4**).

Complications Rate

The total reoperations rate of patients treated with bilateral RTSA was 8.9%, while 6% of the patients underwent a RTSA revision. The total major complications rate was 14.9% (25 out of 168 patients treated with bilateral RTSA) and the most common complications found were scapular spine insufficiency fractures (3.6%) and acromial fractures (3%). Three cases with nerve palsy (two radial nerves and one brachial plexopathy) resolved nonoperatively (► **Table 5**).

Quality of Evidence, Conflicts, and Possible Bias

A possible high risk of selection, performance, and selection bias was identified in all studies included in this review (100%). One study had also a possible high risk of attrition bias¹⁹ (► **Table 6**).

Table 3 Preoperative and postoperative RoM per study

Authors	Preoperative RoM	Postoperative RoM
Mellano et al ¹⁴	AFE: 72° Active ABD: 84° AER in ADD: 26° Active IR in ABD: 39°	AFE: 136° Active ABD: 121° AER in ADD: 45° Active IR in ABD: 58°
Levy et al ⁸	Elevation: 57.5° IR: 9° ER: 20°	Elevation: 143° IR: 81° ER: 32°
Wirth et al ¹⁵	Anteversion/flexion: 73° (first shoulder), 90° (second shoulder) ABD: 64° (first shoulder), 81° (second shoulder) ER in ADD: 22° (first shoulder), 26° (second shoulder) Muscle strength: 0.4 (first shoulder), from 1.0 (second shoulder)	Anteversion/flexion: 136° (first shoulder), 131° (second shoulder) ABD: 125° (first shoulder), 120° (second shoulder) ER in ADD: 24° (first shoulder), 21° (second shoulder) Muscle strength: 4.6 kg (first shoulder), 4.1 kg (second shoulder)
Morris et al ¹⁶	1st operative side: Forward flexion: 35° External rotation: 10° Abduction: 35° Median internal rotation: buttocks 2nd operative side: Forward flexion: 48° External rotation: 15° Abduction: 46° Median internal rotation: lumbosacral junction Unilateral RTSA: Forward flexion: 51° External rotation: 9° Abduction: 48° Median internal rotation: buttocks	1st operative side: Forward flexion: 144° External rotation: 32° Abduction: 142° Median internal rotation: T12 2nd operative side: Forward flexion: 116° External rotation: 24° Abduction: 116° Median internal rotation: buttocks to lumbosacral junction Unilateral RTSA: Forward flexion: 144° External rotation: 32° Abduction: 134° Median internal rotation: lumbosacral junction. Insignificant change: IR, ABD Significant improvement: ER, FF
Stevens et al ¹⁷	1st operative side: Active forward elevation: 77° Active external rotation: 29° Active abduction: 102° Active internal rotation: L5 2nd operative side: Active forward elevation: 85° Active external rotation: 34° Active abduction: 105° Active internal rotation: L3	1st operative side Active forward elevation: 121° Active external rotation: 29° Active abduction: 112° Active internal rotation: L2 2nd operative side Active forward elevation: 112° Active external rotation: 19° Active abduction: 107° Active internal rotation: T12 AFE: significantly improved in both sides. ER, ABD, and IR: did not change significantly
Wiater et al ¹⁰	First shoulder bilateral group: Strength (lbs): 0.2. AFE (°): 53.8. AER (°): 19.1. IR: To sacral vertebrae: 13 patients, to lumbar vertebrae: 3 patients, to thoracic vertebrae: no patients Second shoulder bilateral group: Strength (lbs): 1.1. AFE (°): 53.8. AER (°): 13.7 IR: to sacral vertebrae: 6 patients, to lumbar vertebrae: 6 patients, to thoracic vertebrae from: 3 patients	First shoulder bilateral group: Strength (lbs): 2.8. AFE (°): 126.5. AER (°): 17.1 IR: To sacral vertebrae: 4 patients, to lumbar vertebrae: 4 patients, to thoracic vertebrae: 8 patients Second shoulder bilateral group: Strength (lbs): 2.4. AFE (°): 120.2. AER (°): 19.1. IR: to sacral vertebrae: 6 patients, to lumbar vertebrae: 3 patients, to thoracic vertebrae: 7 patients

Abbreviations: ABD, abduction; ADD, adduction; AER, active external rotation; AFE, active forward elevation; ER, external rotation; IR, internal rotation; RoM, range of motion; RTSA, reverse total shoulder arthroplasty.

Table 4 Radiological findings

Author(s)	Radiological findings
Mellano et al ¹⁴	X-rays: 62% of patients: no notching, Grade 1 notching: 30%, Grade 2 notching: 7%, Grade 3 notching: 1% of patients
Levy et al ⁸	No radiolucencies, migration, change in position over time, or loosening subsidence, some resorption of the allograft in two patients, glenoid notching in two patients (three shoulders)
Wirth et al ¹⁵	No signs of implant migration or polyethylene erosion. At 24 months, up to grade 2 scapular notching was noted in 45% and 42% of the first and second operated sides, respectively. A significant progression of the degree of notching was noted from 12 to 24 months after the first and second operation each in 13% and 16% of the patients, respectively
Morris et al ¹⁶	The bilateral group had a significantly higher proportion of Hamada grades 1 to 3 (classification of rotator cuff tear arthropathy) than the unilateral group The bilateral group had a significantly higher proportion of type E3 glenoid erosion
Stevens et al ¹⁷	N/A
Wiater et al ¹⁰	N/A

Table 5 Complications

Author(s)	Complications
Mellano et al ¹⁴	Instability in three shoulders (3%): one revision of the humeral insert and placement of a larger glenosphere, one conversion to hemiarthroplasty, one periprosthetic joint infection which required two-stage revision. Acromial fractures occurred in five shoulders (5%), one of which required open reduction–internal fixation
Levy et al ⁸	No intraoperative complications. Late traumatic fracture of the scapular spine in two patients, one was operated
Wirth et al ¹⁵	No intraoperative complications 5 revision surgeries, 1 arthroscopic synovectomy
Morris et al ¹⁶	One patient in the bilateral RSA group had a humeral shaft fracture that required surgery and secondarily had a radial nerve traction injury that resolved
Stevens et al ¹⁷	One greater tuberosity fracture that was repaired at the time of the operation with suture. One polyethylene cup was incorrectly paired with a glenosphere. Two bilateral scapular spine insufficiency fractures occurred in opposite shoulders at 5.5 and 3.5 years postoperatively. One periprosthetic fracture occurred at 1.5 years postoperatively and was treated nonoperatively
Wiater et al ¹⁰	First shoulder: 1 scapular spine nonunion (resolved), 1 transient brachial plexopathy (resolved) Second shoulder: 1 scapular spine nonunion (resolved), 1 transient radial nerve palsy (resolved), 1 instability (revision RTSA needed)

Abbreviation: RTSA, reverse total shoulder arthroplasty.

The modified CMS, which was used to assess the quality of the studies, ranged from a minimum of 36/100¹⁷ to a maximum of 55/100¹⁵ (► **Table 6**).

Finally, conflict of interest was noted in three out of six studies (50%)^{8,16,17} (► **Table 6**).

Staged Bilateral RTSA: First versus Second Operated Shoulder

Four studies (66.7%) documented the differences in clinical and functional subjective scores between the first and the second operated shoulder.^{10,15–17} All studies (100%) reported slightly worse preoperative subjective clinical and functional scores in the first operated shoulder, when compared with the second operated shoulder. Despite that, these differences were found not significantly different.

Wirth et al illustrated that both the Constant and SPADI scores and abduction of the second side were significantly worse 1 year after the second RTSA ($p \leq 0.047$), while at 2 years, there were no differences in functional outcome between shoulders.¹⁵ Wiater et al reported that a total of 15 patients (94%) with bilateral RTSA reported being “satisfied” with the first shoulder and 12 (75%) with the second shoulder.¹⁰ In addition, in patients undergoing bilateral procedures, pain relief and function improved for all shoulders, but this was accompanied by slightly inferior results for the second side after a minimum of 24 months of follow-up.¹⁰

According to Morris et al, there were no significant differences in postoperative shoulder function scores or mobility between the first and second RTSA in the bilateral group (all

Table 6 High risk of bias, modified Coleman methodology score, and relative conflicts of interest per study

Author(s)	Type of bias (high risk)	Modified Coleman score	Conflict of interest
Mellano et al ¹⁴	Selection, detection, performance	49	None
Levy et al ⁸	Selection, detection, performance	52	An author receives equity and royalties from Innovative Design Orthopaedics (IDO) as designing surgeon
Wirth et al ¹⁵	Selection, detection, performance, attrition	55	None
Morris et al ¹⁶	Selection, detection, performance	50	An author received financial support for the database that was used to collect results for the study and receives royalties from and serves as a consultant for Tornier, Inc.
Stevens et al ¹⁷	Selection, detection, performance	36	An author receives royalties from a company, some implants of which were used in the study. This study was not supported by this company
Wiater et al ¹⁰	Selection, detection, performance	54	None

$p > 0.10$).¹⁶ As for Stevens et al, they illustrated that all mean final postoperative scores were similar between the first and the second operated shoulder.¹⁷

Staged Bilateral RTSA versus Unilateral RTSA

All studies included in this review reported clinical and functional outcomes of patients treated with staged bilateral RTSA (100%). Two studies (33.3%) compared the outcomes of bilateral RTSA with those of a control group treated with unilateral RTSA.^{10,16} For the bilateral RTSA group, Wiater et al illustrated that the first shoulder had significantly greater improvement than the controls for ASES ($p = 0.0039$) and VAS pain ($p = 0.0271$).¹⁰ For the second shoulder, the controls showed significantly greater improvement than the study group for CMS ($p = 0.0244$), ASES ($p = 0.0183$), and active forward elevation ($p = 0.0280$).¹⁰ So, there were slightly inferior results after the second RTSA relative to the matched controls.¹⁰ According to Morris et al,¹⁶ there were no significant differences in shoulder function scores or mobility between either shoulder in the bilateral group and the unilateral group (all $p > 0.10$).

Internal Rotation Deficit in Relation to Personal Hygiene Habits

Mellano et al reported that most patients noted no changes of their personal hygiene habits and ADLs.¹⁴ Morris et al showed that the IR deficit is rather small and rare in the midterm follow-up and does not influence the personal hygiene habits of the patients.¹⁶ On the other hand, Wirth et al depicted that a minority of patients did not achieve sufficient IR on at least one side.¹⁵ According to them, staged surgery is justified, especially when the outcome of the initial operation is satisfactory.¹⁵

The results of Stevens et al indicated that perineal care is not a problem for most patients after bilateral RTSA: all patients were able to perform perineal hygiene, and 80%

were able to perform this task “normally” with their RTSA.¹⁷ Similarly, Levy et al reported that all patients were able to perform perineal hygiene after their RTSA.⁸

Subscapularis Repair in Staged Bilateral RTSA

Subscapularis repair was performed as routine practice in the majority (66.6%) of the studies included in this review with satisfactory results regarding postoperative internal and ER.^{8,10,14,15} Two studies (33.3%) did not mention whether this procedure was performed in a part or all patients.^{16,17}

Optimal Time between the First and the Second Operation

Five out of six studies (83.3%) documented the mean interval between the first and the second RTSA,^{8,10,14,16,17} while only the study of Wirth et al did not measure this variable.¹⁵ All five studies reported different mean time spans, whereas there was agreement among the different authors that no optimal time has yet been established regarding this interval. The mean duration between the first and the second operation ranged between 8¹⁶ and 21.6 months.¹⁷

Discussion

To our knowledge, this is the first systematic analysis of the literature to investigate the clinical results of bilateral RTSA. The most important finding of this systematic review was that all studies which dealt with bilateral RTSA illustrated improved postoperative outcomes. Clinical and functional scores were significantly improved in all studies of the review. As a result, all authors of the studies included in this review supported the use of bilateral RTSA in the conclusions section of their studies. According to them, bilateral RTSA is a safe and effective procedure in the short- to midterm follow-up, especially for patients suffering from CTA.

Despite the complete lack of randomized controlled clinical trials, we decided to statistically analyze data from these studies, because we considered it likely to produce results with some measure of validity. Nevertheless, we avoided to combine the available data in a quantitative synthesis through a possible meta-analysis due to the heterogeneous nature of the studies included and the serious risk of bias. As we were investigating a controversial operative technique which gains popularity, we found this topic very appealing for a descriptive systematic review even without any pooling data.

The reoperations and failure rates of bilateral RTSA were rather low. The vast majority of patients who were radiographically assessed were found without any sign of postoperative scapular notching, implant's migration, polyethylene erosion, radiolucencies, change in position over time, or loosening subsidence. On the other hand, a little bit less than one-third of those patients, who were radiographically assessed, had a grade 1 to 3 scapular notching, according to the Nerot-Sirveaux system.¹⁸

Concerns have been raised in the past regarding the bilateral IR deficit after this type of treatment and its possible negative impact on personal hygiene habits. As it is well known, good rotational movements are obligatory for performing ADLs; IR for activities regarding perineal and self-hygiene, and ER for reaching the hand to the mouth and head (for eating, drinking, and combing).²⁰ However, the minimal functional range of movement necessary for performing ADLs remains undetermined.⁸ Our systematic review illustrated that most patients noted no changes of their personal hygiene habits and ADLs after bilateral RTSA. Stevens et al and Levy et al showed that all patients were able to perform perineal hygiene after their RTSA,^{8,17} while Morris et al found out that the IR deficit did not influence the personal hygiene habits of the patients.¹⁶

A relative issue which remains controversial is the necessity of subscapularis repair in RTSA.^{19,21} In our review we noticed that most authors routinely used this technique when performing bilateral RTSA.^{8,10,14,15} In contrast to unilateral RTSA where subscapularis repair still raises concerns about its necessity, we consider that this technique is fundamental in bilateral RTSA to eliminate the possibility of IR deficit and improve the performance of ADLs.

Concerning the differences between first and second operated shoulder, Wiater et al showed that although the outcomes for the first shoulder were comparable to those of matched controls, some outcome measures (CMS, ASES, active forward elevation, and satisfaction) were slightly decreased in the second shoulder relative to the controls.¹⁰ These results regarding the difference between first and second shoulder agreed with the study of Wirth et al, which illustrated slightly inferior postoperative outcomes of the second shoulder, when compared with the first one.¹⁵ A possible explanation could be that the first shoulder had worse preoperative function than the second leading to a more dramatic improvement following the first RTSA, and it may have been difficult or impossible for the second RTSA to meet the high expectations. Another plausible explanation for the phenomenon of a poorer contralateral side could be a reduced motivation of the patient for

rehabilitation after the second procedure, which can delay functional improvement.¹⁵

Staged bilateral RTSA showed no significant differences in comparison with the unilateral RTSA as for the clinical and functional outcomes.^{10,16} So, staged surgery is justified, especially when the outcome of the initial operation is satisfactory.¹⁵

In contrast to other types of arthroplasties (total knee arthroplasty, total hip arthroplasty), in which the simultaneous single-stage operation has already been well-established,^{22,23} there were only very limited data available regarding simultaneous bilateral anatomic total shoulder arthroplasty,¹¹ while we did not find any study dealing with simultaneous bilateral RTSA. All studies included in our review reported outcomes of two-stage bilateral RTSA.^{8,10,14–17}

A point of controversy was the interval between the first and the second operation. All studies used a different mean duration and no optimal interval was identified. We would suggest that a minimum interval of 6 months would be considered appropriate so that the first shoulder will start becoming functional in ADLs before the performance of the second operation.

A general limitation of the aforementioned studies was that the total number of patients who have been treated with bilateral RTSA was low, whereas only two studies used a control group, but without any randomization.^{10,16} On the basis of the available data from follow-up examinations, the time periods (1 to 5 years) were relatively short to form a conclusion on the longevity of the bilateral RTSA implants or the long-standing stability of achieved function. Furthermore, most studies were level IV and only two studies were level III.^{10,16} The modified CMS (MCMS) of the studies was low or average, while no study was rated with a MCMS higher than 55/100.

In conclusion, despite the lack of high-quality evidence, staged bilateral RTSA seems to be a safe and effective procedure for patients with CTA, which results in significantly improved clinical and functional outcomes and low reoperations rates.

Funding

None.

Conflict of Interest

None declared.

References

- Chalmers PN, Keener JD. Expanding roles for reverse shoulder arthroplasty. *Curr Rev Musculoskelet Med* 2016;9(01):40–48
- Wright JO, Ho A, Kalma J, et al. Uncemented reverse total shoulder arthroplasty as initial treatment for comminuted proximal humerus fractures. *J Orthop Trauma* 2019;33(07):e263–e269
- Luciani P, Farinelli L, Procaccini R, Verducci C, Gigante A. Primary reverse shoulder arthroplasty for acute proximal humerus fractures: a 5-year long term retrospective study of elderly patients. *Injury* 2019;50(11):1974–1977
- Gerber C, Canonica S, Catanzaro S, Ernstbrunner L. Longitudinal observational study of reverse total shoulder arthroplasty for irreparable rotator cuff dysfunction: results after 15 years. *J Shoulder Elbow Surg* 2018;27(05):831–838

- 5 Grosel TW, Plummer DR, Everhart JS, et al. Reverse total shoulder arthroplasty provides stability and better function than hemiarthroplasty following resection of proximal humerus tumors. *J Shoulder Elbow Surg* 2019;28(11):2147–2152
- 6 Holschen M, Franetzki B, Witt KA, Liem D, Steinbeck J. Conversions from anatomic shoulder replacements to reverse total shoulder arthroplasty: do the indications for initial surgery influence the clinical outcome after revision surgery? *Arch Orthop Trauma Surg* 2017;137(02):167–172
- 7 Bois AJ, Knight P, Alhojailan K, Bohsali KI. Clinical outcomes and complications of reverse shoulder arthroplasty used for failed prior shoulder surgery: a systematic review and meta-analysis. *JSES Int* 2020;4(01):156–168
- 8 Levy O, Walecka J, Arealis G, et al. Bilateral reverse total shoulder arthroplasty-functional outcome and activities of daily living. *J Shoulder Elbow Surg* 2017;26(04):e85–e96
- 9 Sirveaux F, Mole D. Failures of the reverse prosthesis: identifying the problems. In: Cofield RH, ed. *Revision and Complex Shoulder Arthroplasty*. Philadelphia, PA: Lippincott Williams & Wilkins; 2010:18–28
- 10 Wiater BP, Boone CR, Koueiter DM, Wiater JM. Early outcomes of staged bilateral reverse total shoulder arthroplasty: a case-control study. *Bone Joint J* 2013;95-B(09):1232–1238
- 11 Gerber C, Lingenfelter EJ, Reischl N, Sukthankar A. Single-stage bilateral total shoulder arthroplasty: a preliminary study. *J Bone Joint Surg Br* 2006;88(06):751–755
- 12 Liberati A, Altman DG, Tetzlaff J, et al. The PRISMA statement for reporting systematic reviews and meta-analyses of studies that evaluate healthcare interventions: explanation and elaboration. *BMJ* 2009;339:b2700
- 13 Sambandam SN, Gul A, Priyanka P. Analysis of methodological deficiencies of studies reporting surgical outcome following cemented total-joint arthroplasty of trapezio-metacarpal joint of the thumb. *Int Orthop* 2007;31(05):639–645
- 14 Mellano CR, Kupfer N, Thorsness R, et al. Functional results of bilateral reverse total shoulder arthroplasty. *J Shoulder Elbow Surg* 2017;26(06):990–996
- 15 Wirth B, Kolling C, Schwyzer HK, Flury M, Audigé L. Risk of insufficient internal rotation after bilateral reverse shoulder arthroplasty: clinical and patient-reported outcome in 57 patients. *J Shoulder Elbow Surg* 2016;25(07):1146–1154
- 16 Morris BJ, Haigler RE, O'Connor DP, Elkousy HA, Gartsman GM, Edwards TB. Outcomes of staged bilateral reverse shoulder arthroplasties for rotator cuff tear arthropathy. *J Shoulder Elbow Surg* 2015;24(03):474–481
- 17 Stevens CG, Struk AM, Wright TW. The functional impact of bilateral reverse total shoulder arthroplasty. *J Shoulder Elbow Surg* 2014;23(09):1341–1348
- 18 Sirveaux F, Favard L, Oudet D, Huquet D, Walch G, Molé D. Grammont inverted total shoulder arthroplasty in the treatment of glenohumeral osteoarthritis with massive rupture of the cuff. Results of a multicentre study of 80 shoulders. *J Bone Joint Surg Br* 2004;86(03):388–395
- 19 Clark JC, Ritchie J, Song FS, et al. Complication rates, dislocation, pain, and postoperative range of motion after reverse shoulder arthroplasty in patients with and without repair of the subscapularis. *J Shoulder Elbow Surg* 2012;21(01):36–41
- 20 Langer JS, Sueoka SS, Wang AA. The importance of shoulder external rotation in activities of daily living: improving outcomes in traumatic brachial plexus palsy. *J Hand Surg Am* 2012;37(07):1430–1436
- 21 Friedman RJ, Flurin PH, Wright TW, Zuckerman JD, Roche CP. Comparison of reverse total shoulder arthroplasty outcomes with and without subscapularis repair. *J Shoulder Elbow Surg* 2017;26(04):662–668
- 22 Lindberg-Larsen M, Joergensen CC, Husted H, Kehlet H. Simultaneous and staged bilateral total hip arthroplasty: a Danish nationwide study. *Arch Orthop Trauma Surg* 2013;133(11):1601–1605
- 23 Chua HS, Whitehouse SL, Lorimer M, De Steiger R, Guo L, Crawford RW. Mortality and implant survival with simultaneous and staged bilateral total knee arthroplasty experience from the Australian Orthopaedic Association National Joint Replacement Registry. *J Arthroplasty* 2018;33(10):3167–3173