



# Metallosis in Sequelae of Prosthetic Revision for Ceramic Components Fracture: A Case Report with Clinical Presentation Mimicking Periprosthetic Hip Infection

Stefano Artiaco<sup>1</sup> Federico Fusini<sup>1</sup>  Kristijan Zoccola<sup>1</sup> Alessandro Massè<sup>1</sup> Giulia Colzani<sup>2</sup>

<sup>1</sup> Department of Orthopaedics and Traumatology, Orthopaedic and Trauma Center, Azienda Ospedaliero Universitaria Città della Salute e della Scienza, Turin, Italy

<sup>2</sup> Department of Orthopaedics and Traumatology, Policlinico di Modena, Azienda Ospedaliera Universitaria, Modena, Italy

Address for correspondence Federico Fusini, MD, Department of Orthopaedics and Traumatology, Orthopaedic and Trauma Center, Azienda Ospedaliero Universitaria Città della Salute e della Scienza, Turin 10126, Italy (e-mail: fusinif@hotmail.com).

Joints 2019;7:215–217.

## Abstract

### Keywords

- ▶ metallosis
- ▶ hip synovitis
- ▶ periprosthetic hip infection
- ▶ fracture of ceramic acetabular liner

Ceramic on ceramic total hip arthroplasties have been developed and widely used during last decades because of their long-term survival and biomechanical properties. One of the most dangerous complication of these implants is the fracture of the ceramic components. The management of this condition should be carefully planned and the choice of the new implant is crucial. We describe a rare case of severe hip synovitis due to massive metallosis in sequelae of mismanaged prosthetic revision for fracture of the ceramic acetabular liner with an unusual clinical presentation that simulate a periprosthetic infection.

## Introduction

Ceramic component fracture is a well-described complication of ceramic-on-ceramic hip arthroplasty. Even if it is rare, a rapid identification and treatment is essential to avoid severe complication<sup>1</sup>; the persistence of ceramic debris, can lead to more severe systemic complication, due to release of metallic ions.<sup>2</sup> Symptoms of metal intoxication vary with blood level of metal ions and can lead to patient's death in very severe cases.<sup>3</sup>

We described the unusual clinical presentation, diagnostic, and surgical management of this unique case of hip metallosis presenting as a periprosthetic infection.

## Case Presentation

In March 2014, a 72-year-old Caucasian immune-competent man was referred to our hospital with a suspected diagnosis

of periprosthetic hip infection. The patient underwent in 2010, a primary ceramic-on-ceramic total hip arthroplasty, and 3 years after revision surgery was performed for fracture of ceramic liner with a metal-on-polyethylene bearing surface. The patient presented to our observation with persistent hyperthermia (39.0–39.5°C), local pain, and swelling of the hip and groin. The range of joint motion was slightly limited and little painful. A periprosthetic hip infection was then suspected. An empiric antibiotic therapy was administered for 1 week without improvement.

### Preoperative Assessment

Laboratory examinations revealed increased level of C-reactive protein (325.2 mg/L), erythrocyte sedimentation rate 79 mm/h, white blood cell count (12,000/μL), neutrophils count (8,730/μL), and high level of acute-phase inflammatory proteins. Fever persisted high despite antibiotics. Hip radiographs showed a typical feature of severe metallosis, the

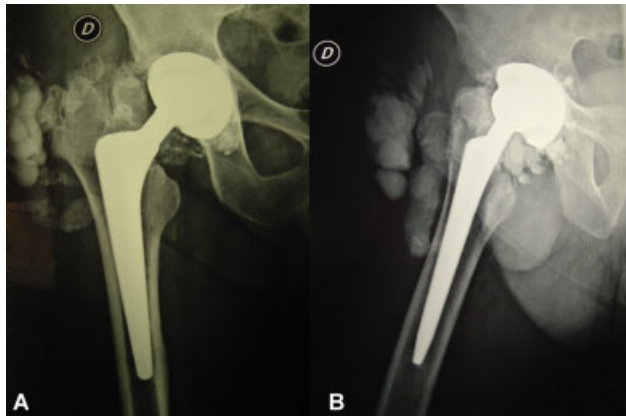
received  
May 1, 2018  
accepted  
April 18, 2021  
published online  
June 18, 2021

DOI <https://doi.org/10.1055/s-0041-1730981>.  
ISSN 2282-4324.

© 2021. The Author(s).

This is an open access article published by Thieme under the terms of the Creative Commons Attribution-NonDerivative-NonCommercial-License, permitting copying and reproduction so long as the original work is given appropriate credit. Contents may not be used for commercial purposes, or adapted, remixed, transformed or built upon. (<https://creativecommons.org/licenses/by-nc-nd/4.0/>)

Georg Thieme Verlag KG, Rüdigerstraße 14, 70469 Stuttgart, Germany

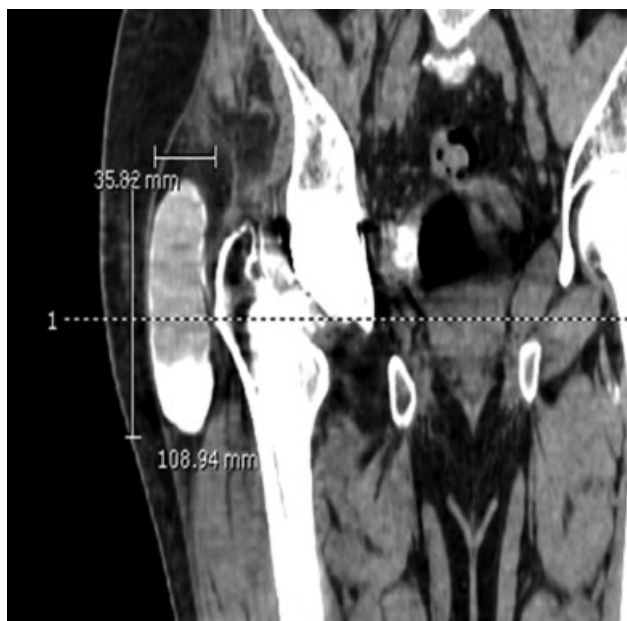


**Fig. 1** (A, B) Preoperative radiographs of the right hip showing the bubble sign.


“bubble sign” surrounding the prosthesis (►Fig. 1).<sup>4</sup> Computed tomography scan of the pelvis revealed a large pseudotumor of the hip (11 cm × 4 cm; ►Fig. 2). Black synovial fluid of 250 cc was aspirated and sent for laboratory evaluation. Microbiological cultures were negative in all five samples, while synovial fluid showed high level of leukocytes (22,000 cell/mm<sup>3</sup>) and metals ions (titanium, 379,100 µg/L; cobalt, 63 µg/L; chrome, 1,379,000 µg/L; molybdenum, 160,400 µg/L; vanadium, 17,180 µg/L; and manganese, 265,500 µg/L). A severe metallosis was than hypothesized and surgical revision was planned.

### Surgical Treatment

A large pseudotumor of the hip was isolated and removed. The soft tissues were black stained and it contained black synovial fluid due to metal debris. After soft tissue debridement and irrigation, the acetabular cup, polyethylene liner, and femoral head were removed. All components showed



**Fig. 2** Preoperative CT scan showing pseudotumor with radiopaque level of synovial fluid. CT, computed tomography.




**Fig. 3** Removed implant showing ceramic debris and sign of metallosis.

macroscopic wear (►Figs. 3 and 4). Some ceramic fragments were identified and removed. A ceramic-on-ceramic bearing surface was then restored after residual ceramic fragments removal.

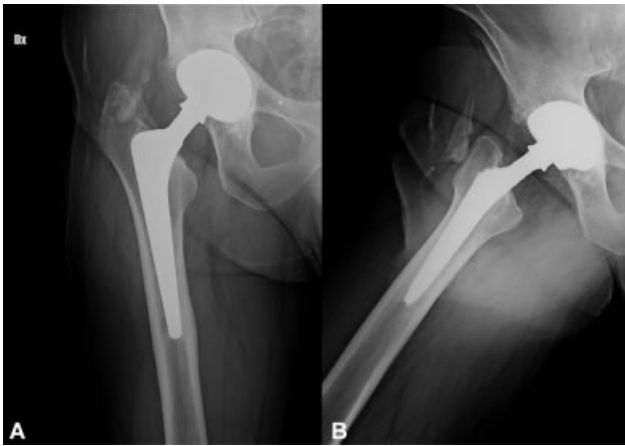### Postoperative Course

Body temperature returned within normal limits in few days. Hip pain disappeared and the patient followed a standard rehabilitation protocol. Blood and urinary concentrations of metal ions were examined during postoperative course. Metal ions concentrations were followed at the time of surgery (T0), 2 weeks (T1), and 4 weeks (T2) after operation. Blood levels of chrome (T0 = 5.07 µg/L; T1 = 4.62 µg/L; and T2 = 3.6 µg/L) and cobalt (T0 = 0.41 µg/L; T1 = 0.62 µg/L; and T2 = 1.02 µg/L) were slightly increased than normal threshold values. During the first 2 months, the patient reported dysgeusia with a persistent metallic taste that progressively disappeared. In 2 months he returned to daily life activities without limitations.

Regular clinical and radiologic follow-up was observed during subsequent years, with no sign of loosening or wear at 3 years of follow-up with an Harris' hip score of 82 (►Fig. 5). The patient was fully satisfied of clinical results and perceived quality of life.



**Fig. 4** (A, B) Retrieved acetabular shell and femoral head with macroscopic metal wear.



**Fig. 5** (A, B) 3-years follow-up radiographs of the right hip with regular appearance.

## Discussion

Fracture of ceramic components may cause catastrophic consequences.<sup>5–10</sup> Revision surgery should be performed promptly with accurate synovectomy and joint irrigation to remove ceramic debris and preserve hip implants from abrasive effects.<sup>5</sup> Some authors reported that revision should be performed with ceramic-on-ceramic implants because early damage and failure of metal and polyethylene may occur because of residual ceramic fragments.<sup>6</sup>

Patients with severe metallosis suffered from serious neurological and cardiac complications which in a case led to patient death.<sup>11</sup>

None of reported cases presented with clinical features simulating periprosthetic infection that were observed in our report. Also initial laboratory examinations supported this hypothesis.

Periprosthetic infection associated with component fracture was already reported in literature but in these cases local and systemic symptoms of inflammation were associated with positive cultures.<sup>12,13</sup> In our case, all symptoms were related to inflammatory response against metal particles and, to the best of our knowledge, this is the first case of severe metallosis simulating a periprosthetic infection.

This report confirms that all patients sustaining a revision hip arthroplasty after fracture of a ceramic component should be carefully controlled with clinical and radiological follow-up and informed about the possibility of future

complications related to residual ceramic fragments. A careful investigation must always be performed to correctly and properly reach the correct diagnosis.

## Funding

None.

## Conflict of Interest

None declared.

## References

- Hannouche D, Zaoui A, Zadegan F, Sedel L, Nizard R. Thirty years of experience with alumina-on-alumina bearings in total hip arthroplasty. *Int Orthop* 2011;35(02):207–213
- Fehring KA, Fehring TK. Modes of failure in metal-on-metal total hip arthroplasty. *Orthop Clin North Am* 2015;46(02):185–192
- Green B, Griffiths E, Almond S. Neuropsychiatric symptoms following metal-on-metal implant failure with cobalt and chromium toxicity. *BMC Psychiatry* 2017;17(01):33
- Su EP, Callander PW, Salvati EA. The bubble sign: a new radiographic sign in total hip arthroplasty. *J Arthroplasty* 2003;18(01):110–112
- Traina F, De Fine M, Di Martino A, Faldini C. Fracture of ceramic bearing surfaces following total hip replacement: a systematic review. *BioMed Res Int* 2013;2013:157247
- Whittingham-Jones P, Mann B, Coward P, Hart AJ, Skinner JA. Fracture of a ceramic component in total hip replacement. *J Bone Joint Surg Br* 2012;94(04):570–573
- Pelclova D, Sklensky M, Janicek P, Lach K. Severe cobalt intoxication following hip replacement revision: clinical features and outcome. *Clin Toxicol (Phila)* 2012;50(04):262–265
- Rizzetti MC, Liberini P, Zarattini G, et al. Loss of sight and sound. Could it be the hip? *Lancet* 2009;373(9668):1052
- Ikeda T, Takahashi K, Kabata T, Sakagoshi D, Tomita K, Yamada M. Polyneuropathy caused by cobalt-chromium metallosis after total hip replacement. *Muscle Nerve* 2010;42(01):140–143
- Oldenburg M, Wegner R, Baur X. Severe cobalt intoxication due to prosthesis wear in repeated total hip arthroplasty. *J Arthroplasty* 2009;24(05):825.e15–825.e20
- Zywił MG, Brandt JM, Overgaard CB, Cheung AC, Turgeon TR, Syed KA. Fatal cardiomyopathy after revision total hip replacement for fracture of a ceramic liner. *Bone Joint J* 2013;95-B(01):31–37
- Donaldson JR, Miles J, Sri-Ram K, Poullis C, Muirhead-Allwood S, Skinner J. The relationship between the presence of metallosis and massive infection in metal-on-metal hip replacements. *Hip Int* 2010;20(02):242–247
- Barba T, Wach J, Lustig S, et al; Lyon BJI Study Group. Metallosis-associated prosthetic joint infection. *Med Mal Infect* 2015;45(11,12):484–487