

Dermal Fillers for Tear Trough Rejuvenation: A Systematic Review

Lily N. Trinh, MD¹  Sarah E. Grond, BS² Amar Gupta, MD³ 

¹Department of Otolaryngology—Head and Neck Surgery, Tulane University, School of Medicine, New Orleans, Louisiana

²Medical College of Wisconsin, Milwaukee, Wisconsin

³Department of Otolaryngology—Head and Neck Surgery, St. Elizabeth's Medical Center, Brighton, Massachusetts

Address for correspondence Amar Gupta, MD, Department of Otolaryngology—Head and Neck Surgery, St. Elizabeth's Medical Center, 736 Cambridge St, SMC-8, Brighton, MA 02135 (e-mail: amar.gupta21@gmail.com).

Facial Plast Surg 2022;38:228–239.

Abstract

There is significant variation in treatment parameters when treating the infraorbital region. Thorough knowledge of these pertinent factors, choice of the optimal filling material, and proper understanding of the anatomy of this unforgiving region will contribute to a safe, effective, and natural result. We aim to conduct a systematic review of published literature related to soft tissue fillers of the tear trough and infraorbital region. A search of published literature was conducted in accordance with PRISMA (Preferred Reporting Items for Systematic Reviews and Meta-Analyses) guidelines and included PubMed, Embase, and Science Direct databases. The Medical Subject Headings (MeSH) terms used were “tear trough” OR “infraorbital” AND “dermal filler” OR “hyaluronic acid” OR “poly-L-lactic acid” OR “calcium hydroxyapatite” OR “Restylane” OR “Radiesse” OR “Perlane” OR “Juvéderm” OR “Belotero.” Different combinations of these key terms were used. The initial search identified 526 articles. Six additional articles were identified through references. Two-hundred twenty-five duplicates were removed. A total of 307 studies were screened by title and abstract and 258 studies were eliminated based on inclusion and exclusion criteria. Forty-nine articles underwent full-text review. The final analysis included 23 articles. Patient satisfaction was high, and duration of effect ranged from 8 to 12 months. Restylane was most commonly used. Injection technique varied, but generally involved placing filler pre-periosteally, deep to orbicularis oculi muscle, anterior to the inferior orbital rim via serial puncture or retrograde linear threading with a 30-gauge needle. Topical anesthetic was most commonly used. Side effects were generally mild and included bruising, edema, blue-gray dyschromia, and contour irregularities. Nonsurgical correction of the tear trough deformity with soft tissue filler is a minimally invasive procedure with excellent patient satisfaction with long-lasting effects. It is essential to have a fundamental understanding of the relevant anatomy and ideal injection technique to provide excellent patient outcomes and prevent serious complications.

Keywords

- tear trough deformity
- infraorbital hollows
- soft tissue fillers
- systematic review

The tear trough and lid–cheek junction are natural anatomical structures that become accentuated with age due to changes in the skin and periorbital region. Over time, a worsening depression can be seen starting at the medial canthus, parallel and just inferior to the infraorbital rim. Skin

and fat atrophy as well as attenuation of the periorbital structures allow herniation of orbital fat and an increase in shadowing. The tear trough and lid–cheek junction are further accentuated by overlying pigmentation, skin texture, and shadow changes. This is a significant concern to patients,

published online
June 30, 2021

Issue Theme Facial Plastic Surgery Original Research; Guest Editors: Anthony P. Sclafani, MD, MBA, FACS, and Alwyn D'Souza, MBBS, FRCS Eng, FRCS (ORL-HNS)

© 2021. Thieme. All rights reserved. Thieme Medical Publishers, Inc., 333 Seventh Avenue, 18th Floor, New York, NY 10001, USA

DOI <https://doi.org/10.1055/s-0041-1731348>.
ISSN 0736-6825.

who often report a “tired” or “aged” under-eye appearance that is not relieved with rest, hydration, or topical therapies.^{1,2} Fortunately, with the proper placement of injectable fillers, effective rejuvenation of the periorbital region by revolumizing and restoring support to the infraorbital hollows is possible.

There is significant variation in treatment parameters when treating the infraorbital region. Though there are general guidelines, factors such as injection technique, choice of product, injection volume, use of blunt cannula versus needle, and type of anesthesia may all vary between providers. In this analysis, we aim to perform a thorough systematic review of the literature to evaluate the published studies related to soft tissue fillers of the tear trough and infraorbital region. Our goals are to determine the techniques, outcomes, and complications associated with these treatment modalities. Thorough knowledge of these pertinent factors, choice of the right filling material, and sound understanding of the anatomy of this unforgiving region will contribute to a safe, effective, and natural result.

Methods

Search Strategy

A systematic review of the published literature was conducted in accordance with the Preferred Reporting Items for Systematic Reviews and Meta-Analyses (PRISMA) guidelines. The literature search was performed in January 2021 and included PubMed, Embase, and ScienceDirect databases. The Medical Subject Headings (MeSH) terms used were “tear trough” OR “infraorbital” OR “malar” and “dermal filler” OR “hyaluronic acid” OR “poly-L-lactic acid” OR “calcium hydroxyapatite” OR “Restylane” OR “Radiesse” OR “Perlane” OR “Juvéderm,” OR “Belotero.” Different combinations of these key terms were used to identify relevant studies.

Study Selection

Studies were included if they met the following criteria: (1) reported patient data on the use of any dermal filler for tear trough rejuvenation, (2) published between the years 2000 and 2021, and (3) included more than 10 subjects. Exclusion criteria included studies which: (1) were published in languages other than English, (2) included nonhuman subjects, (3) were abstract only, book chapters, and review articles, (4) used filler to manage pathologies, (5) involved treatment of other areas of the face or involved other procedures, and (6) included fillers not commercially available in the United States.

Data Abstraction

Titles and abstracts were screened for relevance independently by two investigators (L.N.T. and S.E.G.). Of those articles, the full-texts articles were evaluated. Any discrepancies were resolved by another investigator (A.G.). The reference lists of the full-text articles were also analyzed for any further relevant studies. All studies which met the predetermined criteria were included in the analysis.

Results

The initial search identified 526 articles. Six additional articles were identified through references. Three hundred twenty-five duplicates were removed. A total of 307 studies were screened by title and abstract and 258 studies were eliminated based on inclusion and exclusion criteria. Forty-nine articles underwent full-text review. Twenty-six articles were excluded due to insufficient sample size ($n = 2$), wrong intervention (i.e., included filler not commercially available in the United States) ($n = 6$), and wrong study design (i.e., included multiple treatment modalities or treated a pathology) ($n = 18$). A total of 23 articles were included in the analysis. ►Fig. 1 demonstrates the breakdown of the literature search. A summary of the major findings of the systematic review is demonstrated in ►Table 1.

Study Characteristics

The total number of patients included in our analysis was 2,048, which consisted of 1,409 females and 239 males (one study did not report breakdown of gender). The average study follow-up period was 13.7 months, ranging from 10 days to 5 years. The article publication year ranged from 2005 to 2021. There were 13 prospective studies, nine retrospective studies, and one was a combination of prospective and retrospective studies. The studies were from various countries which are depicted in ►Fig. 2. Patient ages ranged from 21 to 90 years with a mean of 46.3.

►Fig. 3 illustrates the use of specific dermal fillers by number of studies. Among the 23 included articles, use of 28 different fillers was described between studies. The most common HA product used was Restylane 46.4% (13/28),^{3–15} followed by Perlane (four studies),^{5,12,15,16} then Juvéderm (Juvéderm Voluma XC, Juvéderm Volbella XC, Juvéderm Ultra plus XC) (three studies).^{17–19} Other HA products included Belotero (2), Teosyal PureSense Redensity (2), Emervel (1), Glytone (1), and Hylaform (1). Two studies involved the use of calcium hydroxyapatite (Radiesse).^{20,21} The generic and commercial names of the fillers are listed in ►Table 2. A summary of the included studies is depicted in ►Table 3.

Patient Outcomes

All studies reported on patient satisfaction, six studies included the Global Aesthetic Improvement Score (GAIS) scale,^{17,18,20,22–24} and one included three-dimensional (3D) imaging.³ Overall, patient satisfaction was excellent following treatment (85–90%). HA filler had an average duration effect of 10.8 months (eight studies),^{3,4,8,15,17,18,21,25} while CaHA had a duration effect of 15.4 months (two studies).^{20,21} Using 3D imaging, mean duration of volume augmentation with Restylane was 14.4 months, and at an average follow-up of 15 months patients had 85% volume retention.³ Older patients were more likely to be dissatisfied with their results (61 vs. 52 years, $p < 0.01$).¹⁴

Injection Techniques

Type of anesthesia used is described in ►Fig. 4 and ranged from no anesthesia (three studies),^{5,16,21} local infiltration

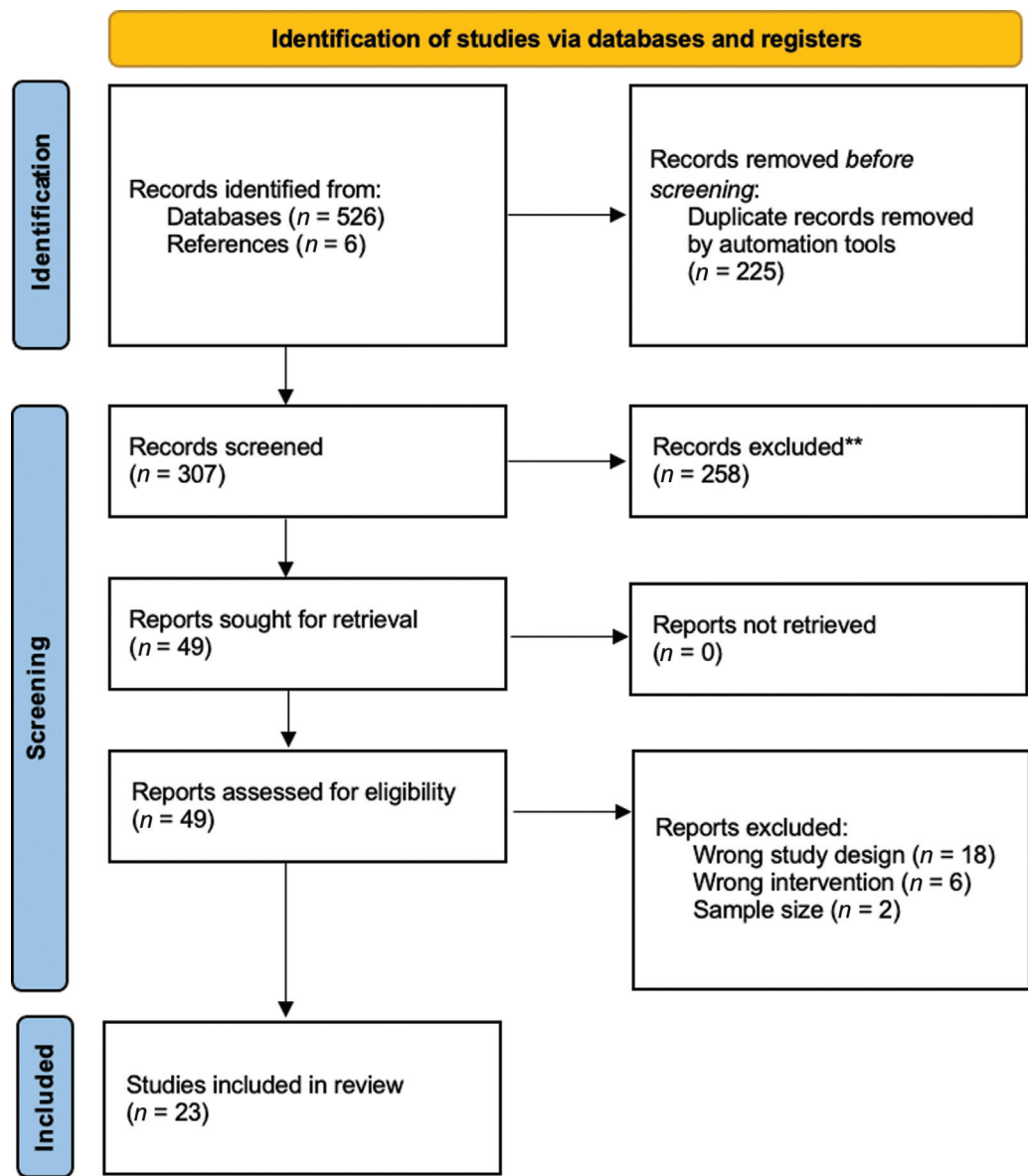


Fig. 1 PRISMA flow diagram for the screening process.

Table 1 Summary of major findings of systematic review

Most common HA filler	Restylane
Average volume per side	0.47 mL
Most commonly reported injection technique	Placement of the filler pre-periosteally between the orbicularis oculi muscle and inferior orbital rim, using the inferior orbital rim or nasojugular groove as injection point landmarks.
Average duration effect of HA on subjective measures	10.8 mo
Average duration effect measured by 3D imaging	85% at 15 mo
Mild adverse effects	Bruising, redness, and edema
Major adverse effects	Tyndall effect (blue-gray discoloration), lump irregularities.

Abbreviations: 3D, three dimensional; HA, hyaluronic acid.

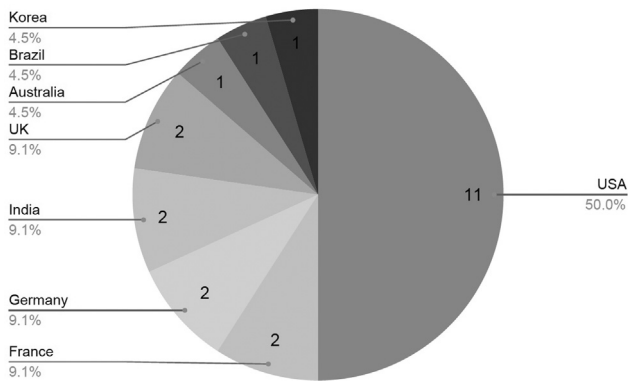


Fig. 2 Country of origin by number of studies. UK, United Kingdom; USA, United States of America.

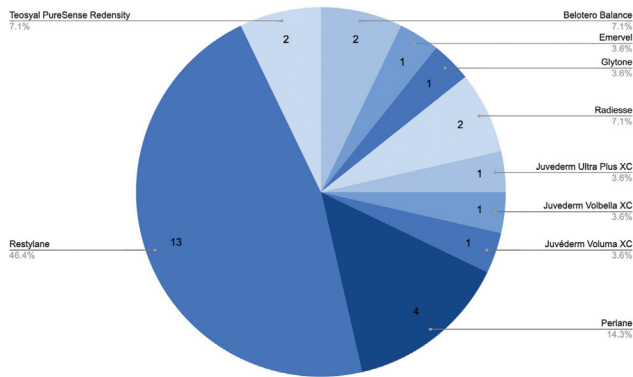


Fig. 3 Filler material used in included studies.

Table 2 Generic and commercial names of the included fillers

Generic name	Commercial name (manufacturer, location)
Hyaluronic acid (HA)	Belotero (Merz Pharmaceuticals GmbH, Frankfurt, Germany) Emervel (Galderma S.A, Lausanne, Switzerland) Glytone (Merz Pharmaceuticals GmbH, Frankfurt, Germany) Juvederm (Allergan Inc, CA) Perlane (Medicis Corporation, AZ) Teosyal Puresense Redensity 2 (Teoxane SA, Geneva, Switzerland)
Calcium hydroxyapatite (CaHA)	Radiesse (Merz Aesthetics, CA)

(three studies),^{12,15,17} nerve block (one study),¹⁹ and topical application (eight studies),^{3,4,6,7,10,11,14,18} One study used topical and local infiltration concurrently,²⁰ while one primarily used 0.3% lidocaine simultaneously injected with filler.²³ Few studies involved multiple techniques, such as none versus local, which demonstrated no major differences in patient satisfaction between anesthetic use.^{8,9,24} Topical anesthetic ointment such as betacaine or lidocaine/prilocaine cream was generally applied 20 to 60 minutes before the procedure and

cleaned off with alcohol immediately before injection. Local anesthesia was commonly performed with 0.2 mL of 1% lidocaine and epinephrine 1:100,000.^{8,9,12} Post-injection massage was frequently completed to mold the filler. One study included the use of post-injection oral corticosteroids (1 mg/kg/d) for 48 hours, which demonstrated decreased swelling and pain compared with those without the use of corticosteroids.⁸

Various injection techniques were used across studies and included retrograde, linear threading, cross-hatching, feathering, fanning, serial puncture and multiple microbolus, and single boluses. Serial puncture (eight studies), microbolus (seven studies), retrograde techniques (six studies), and linear threading (six studies) were most commonly reported.

The mean volume treated per eye was 0.47 mL per side and ranged from 0.21 to 1 mL (19 studies). Depicted in ►Fig. 5, a 30-gauge needle was most commonly used for injections (nine studies), compared with 29-gauge needle (one study), and 31-gauge needle (one study). Cannulas (25-gauge: three studies, 27-gauge: one study) were also reported, which led to comparable patient satisfaction.^{18–20,26}

The most common method described was placement of the filler pre-periosteally between the orbicularis oculi muscle and inferior orbital rim, using the inferior orbital rim or nasojugal groove as injection point landmarks (17 studies). However, two studies describe the placement of filler between the dermis and the orbicularis oculi muscle, both demonstrating high improvement rates (98–100%).^{6,7} Both studies involved the use of Restylane. Additionally, Hill et al revealed that injection of the infraorbital rim led to significant improvement in the depth of the tear trough deformity compared with injection of the deep medial cheek.⁵

Hamman et al studied two different injection technique. One with a single depot through injection point at nasojugal fold ($n = 30$) and another with small aliquots through multiple injection points along inferior orbital rim ($n = 51$). Patient outcomes and satisfaction were similar in both groups. The only major difference was that two patients in the single depot group needed hyaluronidase.⁹

Safety Profile

Overall, complications rate or adverse effect (AE) across studies that reported quantitative data was 30.2% (466/1,545) (►Table 4). A summary of the major reported side effects is depicted in ►Fig. 6. The most common AEs were edema (35.6% of those AEs reported) and bruising (28.5%), which occurred within a few days of treatment and resolved spontaneously within 2 to 3 weeks. Of note, the degrees of reported bruising and swelling were not consistent throughout studies. Some studies reported only major swelling while others reported mild swelling. Hence, the reported edema rates in studies in our analysis ranged from 8 to 91%.^{4,26}

The Tyndall effect, a bluish gray discoloration, is a feared complication of treatment. Among 2,048 patients, Tyndall effect occurred in 65 (3.17%) patients. One 5-year long-term follow-up study accounted for 46 of the 65 occurrences.¹⁰ Berros et al reported that 7/41 (17%) of patients experienced the Tyndall effect following injection of the inferior orbital rim with standard protocol while no patients experienced

Table 3 Summary of major findings of studies included in review

First Author (year)	Study type	No. of patients (female, male)	Average age \pm SD or age range	Follow-up (months)	Material	Volume injected per side (cc)	Injection device	Injection technique	Anesthesia	Results	Complications
Hevia ²³ (2014)	Prospective	46 (38, 8)	51	10	Belotero Balance	0.46	30-gauge needle	Retrograde micro-depot	NA	Mean hollowiness scores for both eyes, at 2, 6, and 10 mo were improved compared with baseline ($p < 0.001$).	NA
Rzany ³⁴ (2012)	Prospective	24 (24, 0)	53 \pm 8.6	6	Emervel Classic or Emervel Deep	0.4 (Classic) or 0.7 (Deep)	Needle	Retrograde linear threading	None (16), topical (5), nerve block (3)	Patients with deep HA more likely satisfied with comfort of injection. However, with classic HA, there was better correction of volume objectively by 3D imaging at 6 mo.	Bruising and edema were most common. Induration that resolved spontaneously (1).
Wollina ¹⁷ (2014)	Retrospective, case series	40 (40, 0)	50 \pm 11.1	6	Glytone (10) Belotero (21), Radiasle (9)	0.4	30-gauge needle	Linear threading, serial punctures and micro-depot	None	38/40 (95%) were very satisfied.	HA: 25/31 patients had minor AE: bruising (13), edema (6), and redness (6). CaHA: 4/9 had minor AE: bruising. No Tyndall. No removal of filler was needed.
Hussain ¹⁸ (2019)	Prospective	150 (132, 18)	38 (24–65)	12	Juvederm Ultra plus XC	NA	31-gauge needle	Three boluses	Local	All patients (immediate–12 mo) were improved by patient and physician assessment.	Localized bruising (3), redness (6), mild swelling (12) immediately after injection. No adverse events after the 1-wk visit. No Tyndall effect, no hyaluronidase used.
Sharad ¹⁹ (2020)	Prospective, clinical trial	10 (10, 0)	30–50	10	Juvederm Volbella XC	NA	30-gauge needle, 25-gauge and 50-mm long cannulas	Vertical suprapariosteal depot technique (VSDT)	Topical	Effect duration was at least for 10 mo. All patients rated as improved, much improved, and greatly improved.	Bruising (1). No Tyndall effects.
Hall ²⁶ (2018)	Prospective	101 (90, 11)	54 (21–85)	12	Juvederm Voluma XC	0.5	27-gauge, 1.5-inch DermaSculpt Microcannula	Layered fashion	Infraorbital nerve block via a gingivobuccal approach.	Overall mean patient satisfaction (based on FACE-Q satisfaction with eyes and decision survey) was 71.1% ($n = 41$) and 65.6% ($n = 42$), respectively.	Bruising (10), contour irregularities (2), swelling (3), and Tyndall effect (1). Three treated with hyaluronidase.
Morley ²⁵ (2011)	Retrospective and prospective, case series	100 (87, 13)	47.8 (23–78)	5	Perlane	0.59	30-gauge needle	Retrograde linear threading	None	85% were satisfied. 8% requested additional treatment within 3 mo. 10% were dissatisfied.	Bruising (7/5), swelling (26), Tyndall (4), lumpiness (33). Seven treated with hyaluronidase.

Table 3 (Continued)

First Author (year)	Study type	No. of patients (female, male)	Average age \pm SD or age range	Follow-up (months)	Material	Volume injected per side (cc)	Injection device	Injection technique	Anesthesia	Results	Complications
Corduff ¹⁶ (2020)	Prospective	12	25–52	18	Radiesse	0.35	25-gauge cannula	Micro-depot	Topical and Local	After 4–6 mo, hyperpigmentation, skin tone, thickness, and color improved noticeably. All patients experienced satisfactory improvements.	Erythema (8), persistent, erythema for 8 mo (1), overt erythema and swelling resolved with antibiotics and hydrocortisone (1).
Donath ³ (2012)	Prospective, case series	10	NA	14.4	Restylane	0.21	30-gauge half-inch needle	Serial puncture	Topical	Mean % of volume retention at final follow-up (avg 14.4, 8–22 mo) was 85%.	No serious adverse events reported. None required hyaluronidase. No Tyndall effect.
Viana ⁴ (2011)	Prospective, clinical trial	25 (25, 0)	46.1 \pm 8.8	12	Restylane	0.58	30-gauge needle	Serial puncture	Topical	88% had overall improvement.	Bruising (13), erythema (10), and local swelling (2).
Kane ⁷ (2005)	Retrospective	23 (23, 0)	41 (35–56)	0.3	Restylane (23), Hyalform (1)	0.25	30-gauge (10), 32-gauge needle (14)	Retrograde, cross-hatched for deep or large defects, feathering in less deep areas.	Topical	All patients were improved.	Two patients were dissatisfied due to irregularities. One was treated with Hyalform, had heavy swelling, and discoloration.
Berros ⁸ (2013)	Retrospective, case report	177 (155, 22)	43.17	48	Restylane	0.6–1.0	25-gauge cannula	Micro-depot	Local (41), none (135)	56.09% of group A (standard) patients were satisfied and 88.1% of group B (preinjection cooling, displacement of the malar fat, corticoids) patients were satisfied.	Edema and swelling were greater in group A. Tyndall effect occurred in 7/41, 17% in group A, and 0% in group B. 20 (48.8%) of group A and 16 (11.9%) of group B needed hyaluronidase.
Hamman ⁹ (2012)	Retrospective	81 (77, 4)	48.5 (29–73)	NA	Restylane	0.47 (Group A: 30 patients) or 0.29 (Group B: 51 patients)	30-gauge needle	Single depot in nasojugal groove (30) or micro-depot along inferior orbital rim (51).	Included in HA (30), none (51)	Patient satisfaction, degree of improvement, and desire to repeat procedure was similar for both techniques.	Two patients treated with single depot required hyaluronidase. No difference in the incidence and severity of side effects.
Mustak ¹⁰ (2018)	Retrospective, case series	147 (130, 17)	57.7 \pm 13	72	Restylane	0.23	30-gauge needle	Fanning	Topical	Treatment was well tolerated long term.	Malar edema (16), Tyndall effect (46), contour irregularities (45). Irregularities were more common with multiple injections and higher volume.

(Continued)

Table 3 (Continued)

First Author (year)	Study type	No. of patients (female, male)	Average age \pm SD or age range	Follow-up (months)	Material	Volume injected per side (cc)	Injection device	Injection technique	Anesthesia	Results	Complications
Steinsapir ¹¹ (2006)	Retrospective, case series	164 (130, 34)	43 \pm 9 for women, 46 \pm 10 for men	24	Restylane	0.4	Needle	Serial puncture	Topical	Most patients had noticeable improvements when blinded observer rated before and after photos.	Swelling and bruising were most common. Cellulitis (1), migraine (1). Seven required hyaluronidase.
Tung ¹² (2012)	Prospective	21 (21, 0)	43	5	Restylane and Perlane	1	Needle	Micro-depot of Restylane along the orbital rim, Perlane in upper malar and lateral zygomatic areas and medial aspect of temporal fossa.	NA	91.7% had overall improvements. Mean satisfaction scores increased by two grades relative to baseline.	Mild bruising (16, 76%), swelling (5, 23%), no lumpiness or blue discoloration. None required hyaluronidase.
Lim ¹³ (2014)	Prospective, randomized controlled trial	10 (10, 0)	31.2 (27–59)	6	Restylane Vital	0.03	Restylane injector	Serial puncture	NA	All patients were satisfied. Melanin index was significantly decreased at 4-wk. Erythema index was lower on treated side immediately after treatment and did not change thereafter.	Redness, swelling, and ecchymosis were commonly reported and lasted <1 wk. No Tyndall effect or use of hyaluronidase.
Goldberg ¹⁴ (2006)	Retrospective, case report	155 (114, 41)	53 (24–83)	12	Restylane	0.45	30-gauge needle	Linear threading, serial puncture	Topical	89% patients were satisfied.	12 patients were unsatisfied because of malar edema (5), irregularity (3), Tyndall (3). 17 (11%) required hyaluronidase.
Diwan ²⁴ (2020)	Prospective	24 (22, 2)	34.8	1	Teosyal PureSense Redensity	0.43	25-gauge cannula	Micro-depot, linear threading	NA	100% of patients noted an overall improvement, 75% were satisfied, 25% required further filler to be satisfied. Older patients were less likely to be satisfied.	Mild swelling (22), moderate swelling (1), immediate bruising (1). At 2 wk, mild asymmetry (1), unilateral watery eye (1).

Table 3 (Continued)

First Author (year)	Study type	No. of patients (female, male)	Average age \pm SD or age range	Follow-up (months)	Material	Volume injected per side (cc)	Injection device	Injection technique	Anesthesia	Results	Complications
Berguiga ²¹ (2017)	Prospective, clinical trial	151 (130, 21)	48	1	Teosyal PureSense Redensity	0.48	30-gauge needle (58%) and cannula (42%)	Retrograde serial puncture	Local	97% patients had marked or moderate satisfaction. At 1 mo, 18% requested touch-up injection.	Immediate side effects were bruising (17), swelling (22), and redness (32), and blue discolorations (4). None required hyaluronidase.
Airan ¹⁵ (2005)	Retrospective, case series	400	NA	NA	Restylane and Perlane	0.35–1.40	Needle	Bolus	Local	Improved contour in all patients and improvement in darkness under lower lid.	Bruising and swelling seen up to 2 wk. No major complications.
Hill ⁵ (2015)	Prospective, clinical trial	12 (8, 4)	NA	1.5	Restylane and Perlane	0.4	29-gauge needle	Serial puncture, retrograde linear threading	None	Significant improvement in the depth of the tear trough rating after treatment of the tear trough ($p=0.0001$), but no difference with only cheek treatment.	Varying degrees of ecchymosis
Shah-Desai ⁶ (2020)	Retrospective, case series	165 (121, 44)	30 (18–45)	6	Restylane vital light	0.1–0.2	31-gauge needle	Serial puncture	Topical	161/165 (98%) of patients had improvements.	Mild bruising (100), mild edema (165), persistent swelling (2). Four patients needed hyaluronidase. Three (2%) had Tyndall effect.

Abbreviations: 3D, three dimensional; AE, adverse effect; HA, hyaluronic acid.

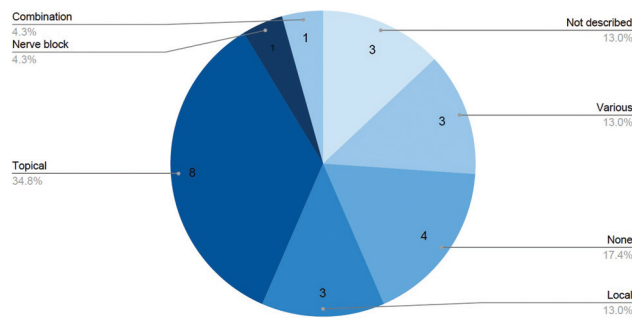


Fig. 4 Type of anesthesia by number of studies.

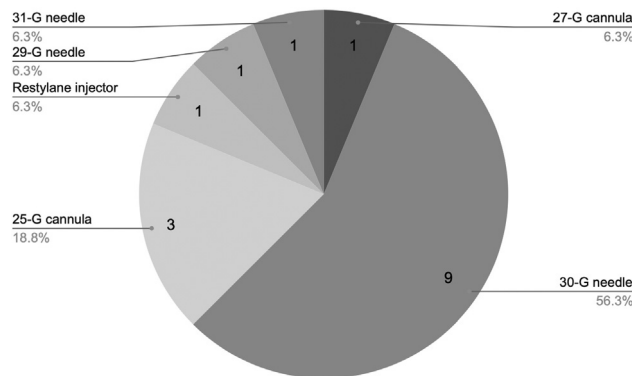


Fig. 5 Type of injection device used by number of studies.

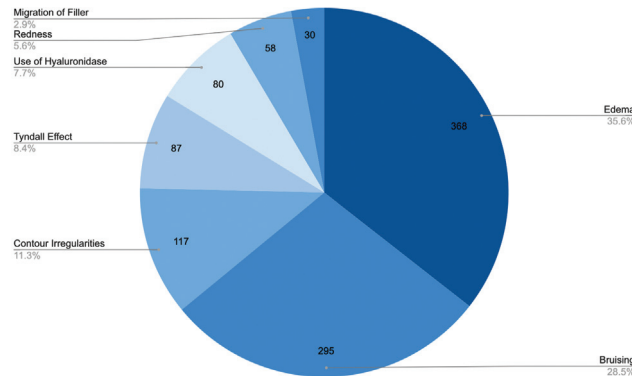


Fig. 6 Reported number of patients who experienced a major side effect.

the Tyndall effect with a modified injection protocol. This modified protocol involved preinjection cooling of the peri-orbital area, no local anesthesia, preincision displaced of malar fat 10 mm below the orbital border, and post-injection oral corticoid therapy (1 mg/kg/d) for 48 hours.⁸

Contour irregularities are another feared complication of tear trough augmentation and are more common following multiple injections and higher volume.¹⁰ Some studies necessitated the use of hyaluronidase to improve lumps and irregularities.^{14,16,19} Overall, among 2,048 patients, 83 (4%) patients required the use of hyaluronidase to dissolve contour irregularities. There were two reported cases of cellulitis and one of migraine following injection of Restylane.¹¹

AEs were more commonly reported with Perlane ($n = 100$) which included bruising (75%), swelling (26%), blue discoloration (4%), and lumpiness (33%) with 7% requiring dissolution of lumps with hyaluronidase.¹⁶ Treatment with HA was well-tolerated long-term and follow-up of 5 years reported long-term complications of malar edema (11%), blue-gray discoloration (31.3%), and contour irregularities (30.5%).¹⁰ The majority (90%) were mild and required no intervention.

Discussion

The tear trough deformity is a challenging area to treat with dermal fillers due to the thin overlying skin and hyperpigmentation in the region. Additionally, important nearby vessels and structures require a thorough understanding of the anatomy and optimal injection technique to prevent complications. Our systematic review evaluated published literature on patient outcomes, safety profile, and injection techniques of the use of dermal fillers in the treatment of tear trough deformities.

Patient Outcomes

In general, patients were highly satisfied with their results following treatment for tear trough augmentation. Factors that affected patient satisfaction were multifactorial. Some patients, who had improved results, remained dissatisfied due to AEs such as bruising and swelling.²⁶ Diwan et al found that one main hindrance to patient satisfaction was financial as some patients required multiple treatments. Almost 40% of patients over 35 years required a second injection for optimal treatment.²⁶ Additionally, older patients were more dissatisfied, which may be related to the thinner skin and propensity for edema in the older population.^{8,14} Therefore, it is important to counsel patients in specific age groups regarding treatment expectations. As well, proper patient selection is critical. Patients with very thin skin, pre-existing pigment issues, or pre-existing eyelid edema may not be good candidates for tear trough treatment.

Injection Techniques

The most common filler used in our analysis was Restylane followed by Perlane and Juvéderm products. Restylane is likely used as the primary filler as it tends to cause less swelling in this sensitive area compared with the Juvéderm products (specifically the Hylacross products Ultra and Ultra Plus).²⁷ The nonanimal stabilized hyaluronic acid (NASHA) processing technology of Restylane may be associated with this effect.²⁸ However, as a caveat, the greater propensity for swelling cannot be generalized to all Juvéderm products. For example, the Vycross derivatives in the Juvéderm family, specifically Volbella, are also often used for the mid-to-deep dermis in the tear trough region. Injecting with a safe and reliable technique plays a pivotal role in achieving optimal outcome. It is commonly accepted that superficial (subcutaneous plane) injections are more likely to produce skin irregularities, whereas deeper injections (submuscular or pre-periosteal planes) place filler where it is less likely to

Table 4 Number of patients who experienced a side effect by study

First author (year)	Number of patients	Bruising	Edema	Redness	Contour irregularities	Migration of filler	Asymmetry	Cellulitis	Migraine	Watery eye	Tyndall effect	Use of HAase
Wollina ²¹ (2014)	40	17	6	6	0	-	-	-	-	-	0	0
Hussain et al ¹⁷ (2019)	150	3	12	6	0	-	-	-	-	-	0	0
Sharad ¹⁸ (2020)	10	1	0	0	0	-	-	-	-	-	0	0
Hall et al ¹⁹ (2018)	101	10	3	-	2	-	-	-	-	-	1	3
Monley and Malhotra ¹⁶ (2011)	100	75	26	0	33	-	-	-	-	-	4	7
Corduff ²⁰ (2020)	12	-	-	10	0	-	-	-	-	-	0	0
Viana et al ⁴ (2011)	25	13	2	10	0	-	-	-	-	-	-	-
Kane ⁷ (2005)	23	0	1	0	2	-	-	-	-	-	1	0
Berros et al ⁸ (2013)	176	0	37	0	18	30	-	-	-	-	7	36
Hamman et al ⁹ (2012)	81	25	19	10	-	-	-	-	-	-	10	2
Mustak et al ¹⁰ (2018)	147	0	16	0	45	-	-	-	-	-	46	5
Steinsapir and Steinsapir ¹¹ (2006)	164	5	18	0	0	-	2	2	1	-	0	7
Tung et al ¹² (2012)	21	16	5	0	0	-	-	-	-	-	0	0
Goldberg and Fiaschetti ¹⁴ (2006)	155	16	23	0	17	-	-	-	-	-	11	16
Diwan et al ²⁶ (2020)	24	2	23	-	-	-	1	-	-	1	-	-
Berguiga and Galatoire ²³ (2017)	151	12	12	16	0	-	-	-	-	-	4	0
Shah-Desai and Joganathan ⁶ (2021)	165	100	165	-	-	-	-	-	-	-	3	4
Total (%)	1,545 (100%)	295 (19%)	368 (24%)	58 (3.75%)	117 (7.57%)	30 (1.94%)	3 (0.19%)	2 (0.13%)	1 (0.06%)	1 (0.06%)	87 (5.63%)	80 (5.18%)

Abbreviation: HAase, hyaluronidase; -, not analyzed or reported by study.

migrate, and minimize the risk of intravascular injection.¹¹ Subcutaneous placement of Restylane was described in the early 2000s by Kane with good results, and more recently with Shah-Desai and Joganathan in younger patients.^{6,29} Shah-Desai and Joganathan proposed that while deep injections led to favorable outcomes in older patients with significant volume loss and skin laxity, younger patients with thin lower eyelid skin from structural volume loss of skin and subcutaneous tissue can benefit from placement of filler into the subcutaneous, preseptal area.⁶

Serial puncture, retrograde linear threading, and microbolus techniques with a 30-gauge needle were commonly reported in our analysis.^{3,4,24} Cannulas were also used and did not display different satisfaction rates.^{18–20,26} Theoretically, cannula may be safer because they are less likely to pierce the periorbital, orbital septum, or vasculature.³⁰ However, a study on human cadavers compared the use of a 30-gauge needle and a 30-gauge blunt cannula on the tear trough augmentation and demonstrated that in both techniques the periorbital was intact and the filler remained within the desired anatomical plane.³¹ However, the risk of intravascular injection and risk of ocular thrombosis were not studied.

Various injection points along the inferior orbital rim have been successfully and safely used. Nonetheless, it is advisable to not inject medially in the inner canthus to avoid compression or emboli of the angular vessels. Most practitioners recommend using a conservative approach using minimal volume with initial treatments, as overcorrection can lead to lumps and contour irregularities. Our study found an average of 0.47 mL of filler used per side. However, this volume may lead to over-correction as some of the included articles treated both the tear trough deformity and palpebromalar groove.^{12,18} Gently post-injection massage was often used to appropriately mold the filler. Most patients were asked to follow-up in 3 to 4 weeks for a potential second injection, if necessary.

Safety Profile

AEs from tear trough treatment were generally mild and self-limiting, and most commonly included bruising and swelling. Notably, age and dermatological characteristics such as wrinkles and hyperlaxity were not factors correlated with complications whereas history of blepharoplasty was correlated with higher incidence of AEs such as edema.⁸ The Tyndall effect, a blue-gray skin dyschromia, is another potential complication of treatment. This discoloration may be exacerbated by patients with pre-existing hyperpigmentation. Injectors have cited that maintaining deep injection planes can decrease the risk of the Tyndall effect.¹⁰ As well, deep periosteal injection can decrease the possibility of blocked lymphatic drainage and intravascular injections further minimizing edema and ecchymosis.³²

Improper injections can lead to devastating and irreversible consequences. For instance, if the injection is performed too inferiorly at the mid-pupillary line, the risk of intra-arterial injection could lead to blindness.²⁷ While no cases were reported in the studies in our analysis, blindness secondary to filler injection in the periorbital region has been described in literature. This complication has been reported in both case

reports and in the MAUDE database during tear trough treatment.^{33–35} For example, a tear trough injection with Juvéderm Vollbella with lidocaine led to a case of unilateral blindness immediately following injection in an otherwise healthy young female.³⁶ Various other reports of blindness have been described with different dermal filler products (i.e., Restylane, Bellafill, Juvéderm) and treatment areas (i.e., nasal dorsum, nasolabial folds, glabella). Diplopia as a result of inferior oblique muscle restriction has also been described following correction of the tear trough deformity, in a 38-year-old female one and a half month following treatment. This patient also had bilaterally lower eyelid swelling and both conditions were successfully treated with hyaluronidase.³⁷ Catastrophic events can occur but are rare with proper technique. Thus, we recommend that practitioners have a thorough understanding of the relevant anatomy, optimal injection techniques, and effective management of complications.

Limitations

This systematic review has a few limitations. First, the quality of the included studies was limited by the homogeneity of patients. Most of the patients included were older Caucasian women with Fitzpatrick skin types I or II. This limits the generalizability of the results to younger men and women, and those with darker complexion (Fitzpatrick skin types III–VI). Second, most of the included studies evaluated their results on subjective and nonvalidated measures such as patient satisfaction. While a patient's perception of improvement is clinically important, objective measures are valuable for critical analysis of results such as effect duration. Additionally, patients with various preinjection tear trough deformities were used. We recommend use of a classification system to objectively grade the pretreated deformities to improve the comparison between treatment results.^{38,39} Lastly, many of the included studies were retrospective case series or case reports. There was only one randomized control study and four controlled trials. Studies with less than 10 subjects were also excluded, which could potentially provide evidence on complication rates. Future studies should focus on diverse patient samples, objective outcome measures, and randomized controlled studies.

Conclusion

Our systematic review demonstrated that nonsurgical correction of the tear trough deformity with soft tissue filler is a minimally invasive procedure with excellent patient satisfaction with long lasting effects. Common reported side effects were mild and transient and include bruising and edema. More serious AEs such as contour irregularities, severe edema, and the Tyndall effect may occur, but are relatively uncommon. It is essential to have a fundamental understanding of the relevant anatomy and ideal injection technique to provide excellent patient outcomes and prevent serious complications.

Conflict of Interest

None declared.

References

- Chung K. *Operative Techniques in Plastic Surgery*. 1st ed. Lippincott Williams & Wilkins; 2018.
- Haddock NT, Saadeh PB, Boutros S, Thorne CH. The tear trough and lid/cheek junction: anatomy and implications for surgical correction. *Plast Reconstr Surg* 2009;123(04):1332–1340.
- Donath AS, Glasgold RA, Meier J, Glasgold MJ. Quantitative evaluation of volume augmentation in the tear trough with a hyaluronic acid-based filler: a three-dimensional analysis. *Plast Reconstr Surg* 2010;125(05):1515–1522.
- Viana GAP, Osaki MH, Cariello AJ, Damasceno RW, Osaki TH. Treatment of the tear trough deformity with hyaluronic acid. *Aesthet Surg J* 2011;31(02):225–231.
- Hill RH III, Cysz CN, Kandapalli S, et al. Evolving minimally invasive techniques for tear trough enhancement. *Ophthal Plast Reconstr Surg* 2015;31(04):306–309.
- Shah-Desai S, Joganathan V. Novel technique of non-surgical rejuvenation of infraorbital dark circles. *J Cosmet Dermatol* 2021;20(04):1214–1220.
- Kane MAC. Treatment of tear trough deformity and lower lid bowing with injectable hyaluronic acid. *Aesthetic Plast Surg* 2005;29(05):363–367.
- Berros P, Lax L, Bétis F. Hyalurostructure treatment: superior clinical outcome through a new protocol—a 4-year comparative study of two methods for tear trough treatment. *Plast Reconstr Surg* 2013;132(06):924e–931e.
- Hamman MS, Goldman MP, Fabi SG. Comparison of two techniques using hyaluronic acid to correct the tear trough deformity. *J Drugs Dermatol* 2012;11(12):e80–e84.
- Mustak H, Fiaschetti D, Goldberg RA. Filling the periorbital hollows with hyaluronic acid gel: long-term review of outcomes and complications. *J Cosmet Dermatol* 2018;17(04):611–616.
- Steinsapir KD, Steinsapir SMGG. Deep-fill hyaluronic acid for the temporary treatment of the naso-jugal groove: a report of 303 consecutive treatments. *Ophthal Plast Reconstr Surg* 2006;22(05):344–348.
- Tung R, Ruiz de Luzuriaga AM, Park K, Sato M, Dubina M, Alam M. Brighter eyes: combined upper cheek and tear trough augmentation: a systematic approach utilizing two complementary hyaluronic acid fillers. *J Drugs Dermatol* 2012;11(09):1094–1097.
- Lim HK, Suh DH, Lee SJ, Shin MK. Rejuvenation effects of hyaluronic acid injection on nasojugal groove: prospective randomized split face clinical controlled study. *J Cosmet Laser Ther* 2014;16(01):32–36.
- Goldberg RA, Fiaschetti D. Filling the periorbital hollows with hyaluronic acid gel: initial experience with 244 injections. *Ophthal Plast Reconstr Surg* 2006;22(05):335–341, discussion 341–343.
- Airan LE, Born TM. Nonsurgical lower eyelid lift. *Plast Reconstr Surg* 2005;116(06):1785–1792.
- Morley AMS, Malhotra R. Use of hyaluronic acid filler for tear-trough rejuvenation as an alternative to lower eyelid surgery. *Ophthal Plast Reconstr Surg* 2011;27(02):69–73.
- Hussain SN, Mangal S, Goodman GJ. The Tick technique: a method to simplify and quantify treatment of the tear trough region. *J Cosmet Dermatol* 2019;18(06):1642–1647.
- Sharad J. Treatment of the tear trough and infraorbital hollow with hyaluronic acid fillers using both needle and cannula. *Dermatol Ther (Heidelb)* 2020;33(03):e13353.
- Hall MB, Roy S, Buckingham ED. Novel use of a volumizing hyaluronic acid filler for treatment of infraorbital hollows. *JAMA Facial Plast Surg* 2018;20(05):367–372.
- Corduff N. An alternative periorbital treatment option using calcium hydroxyapatite for hyperpigmentation associated with the tear trough deformity. *Plast Reconstr Surg Glob Open* 2020;8(02):e2633.
- Wollina U. Improvement of tear trough by monophasic hyaluronic acid and calcium hydroxylapatite. *J Clin Aesthet Dermatol* 2014;7(10):38–43.
- Alam M, Tung R. Injection technique in neurotoxins and fillers: indications, products, and outcomes. *J Am Acad Dermatol* 2018;79(03):423–435.
- Berguiga M, Galatoire O. Tear trough rejuvenation: a safety evaluation of the treatment by a semi-cross-linked hyaluronic acid filler. *Orbit* 2017;36(01):22–26.
- Rzany B, Cartier H, Kestermont P, et al. Correction of tear troughs and periorbital lines with a range of customized hyaluronic acid fillers. *J Drugs Dermatol* 2012;11(Suppl 1):s27–s34.
- Hevia O, Cohen BH, Howell DJ. Safety and efficacy of a cohesive polydensified matrix hyaluronic acid for the correction of infraorbital hollow: an observational study with results at 40 weeks. *J Drugs Dermatol* 2014;13(09):1030–1036.
- Diwan Z, Trikha S, Etemad-Shahidi S, Alli Z, Rennie C, Penny A. A prospective study on safety, complications and satisfaction analysis for tear trough rejuvenation using hyaluronic acid dermal fillers. *Plast Reconstr Surg Glob Open* 2020;8(04):e2753.
- Knotis T, Lacombe V, eds. *Cosmetic Injection Techniques: A Text and Video Guide to Neurotoxins and Fillers*. 2nd ed. New York, NY: Thieme Medical Publisher; 2018.
- Jiang B, Ramirez M, Ranjit-Reeves R, Baumann L, Woodward J. Noncollagen dermal fillers: a summary of the clinical trials used for their FDA approval. *Dermatol Surg* 2019;45(12):1585–1596.
- Kane MAC. Advanced techniques for using Restylane in the lower eyelids. *Aesthet Surg J* 2007;27(01):90–92.
- Funt D, Pavicic T. Dermal fillers in aesthetics: an overview of adverse events and treatment approaches. *Clin Cosmet Investig Dermatol* 2013;6:295–316.
- Brown M, Gatherwright J, Katira K, Rowe D. Evaluation of blunt and sharp needle tips in correction of the tear trough deformity. *J Plast Reconstr Aesthet Surg* 2014;67(12):e310–e311.
- Anido J, Fernández JM, Genol I, Ribé N, Pérez Sevilla G. Recommendations for the treatment of tear trough deformity with cross-linked hyaluronic acid filler. *J Cosmet Dermatol* 2021;20(01):6–17.
- Hu XZ, Hu JY, Wu PS, Yu SB, Kikkawa DO, Lu W. Posterior ciliary artery occlusion caused by hyaluronic acid injections into the forehead: a case report. *Medicine (Baltimore)* 2016;95(11):e3124.
- Chen Y, Wang W, Li J, Yu Y, Li L, Lu N. Fundus artery occlusion caused by cosmetic facial injections. *Chin Med J (Engl)* 2014;127(08):1434–1437.
- Yao B, Shen F, Zhao X, Liu G, Ding Y. Ophthalmic artery occlusion combined with superior sagittal sinus thrombosis caused by hyaluronic acid injection for facial soft tissue augmentation: a case report. *Medicine (Baltimore)* 2019;98(36):e17048.
- Adverse Event Report MAUDE. Allergen, Volbella implant, dermal, for aesthetic use. Accessed May 3, 2021 at: https://www.access-data.fda.gov/scripts/cdrh/cfdocs/cfMAUDE/detail.cfm?mdrfoi__id=11555152&pc=LMH
- Kashkouli MB, Heirati A, Pakdel F, Kiavash V. Diplopia after hyaluronic acid gel injection for correction of facial tear trough deformity. *Orbit* 2012;31(05):330–331.
- Turkmani MG. New classification system for tear trough deformity. *Dermatol Surg* 2017;43(06):836–840.
- Peng PHL, Peng JH. Treating the tear trough: a new classification system, a 6-step evaluation procedure, hyaluronic acid injection algorithm, and treatment sequences. *J Cosmet Dermatol* 2018;17(03):333–339.