



Minimally Invasive Tibiototalcalcaneal Arthrodesis with Blocked Retrograde Intramedullary Nail – Report of Three Cases*

*Artrodese tibiototalcalcaneana minimamente invasiva com haste intramedular retrógrada bloqueada – Relato de três casos**

Fernando Delmonte Moreira¹ Jorge Eduardo de Schoucair Jambeiro¹
Antero Tavares Cordeiro Neto¹ José Augusto Oliveira¹ Felipe Fernandes Leão² Alex Guedes³

¹Foot and Ankle Surgery Group, Orthopedics Service, Hospital Santa Izabel, Santa Casa de Misericórdia da Bahia, Salvador, BA, Brazil

²Medical Residency Program in Orthopedics and Traumatology, Orthopedics Service, Hospital Santa Izabel, Santa Casa de Misericórdia da Bahia, Salvador, BA, Brazil

³Orthopedic Oncology Group, Hospital Santa Izabel, Santa Casa de Misericórdia da Bahia, Salvador, BA, Brazil

Address for correspondence Alex Guedes, PhD, Orthopedic Oncology Group, Hospital Santa Izabel, Santa Casa de Misericórdia da Bahia, Rua Marechal Floriano 212, apt.º 401, Canela, Salvador, BA, 40110-010, Brazil (e-mail: alexguedes2003@yahoo.com.br).

Rev Bras Ortop 2024;59(1):e143–e147.

Abstract

Ankle osteoarthritis (AOA) is associated with pain and variable functional limitation, demanding clinical treatment and possible surgical indication when conservative measures are ineffective – arthrodesis has been the procedure of choice, because it reduces pain, restores joint alignment and makes the segment stable, preserving gait. The present study reports 3 cases (3 ankles) of male patients between 49 and 63 years old, with secondary AOA, preoperative American Orthopaedic Foot and Ankle Society Ankle-Hindfoot Scale (AOFAS AHS) of 27 to 39 points, treated by minimally invasive tibiototalcalcaneal arthrodesis using blocked retrograde intramedullary nail. Hospital stay was of 1 day, and the patients were authorized for immediate loading with removable ambulation orthotics, as tolerated. The physical therapy treatment, introduced since hospitalization, was maintained, prioritizing gait training, strength gain, and proprioception. Clinical and radiographic follow-up was performed at weeks 1, 2, 6, 12 and 24. After evidence of consolidation (between the 6th and 10th weeks), the orthotics were removed. One patient complained of pain in the immediate postoperative period and, at the end of the 1st year, only one patient presented pain during

Keywords

- ▶ ankle joint
- ▶ arthrodesis
- ▶ osteoarthritis
- ▶ minimally invasive surgical procedures
- ▶ surgical procedures, operative
- ▶ ankle

* Work developed in the Groups of Foot and Ankle Surgery and Orthopedic Oncology, Hospital Santa Izabel, Santa Casa de Misericórdia da Bahia, Salvador, BA, Brazil.

received
September 22, 2020
accepted
January 15, 2021

DOI <https://doi.org/10.1055/s-0041-1731356>.
ISSN 0102-3616.

© 2021. The Author(s).

This is an open access article published by Thieme under the terms of the Creative Commons Attribution 4.0 International License, permitting copying and reproduction so long as the original work is given appropriate credit (<https://creativecommons.org/licenses/by/4.0/>).
Thieme Revinter Publicações Ltda., Rua do Matoso 170, Rio de Janeiro, RJ, CEP 20270-135, Brazil

rehabilitation, which was completely resolved with analgesics. Currently, the patients do not present complaints, returning to activities without restrictions – one of them, to the practice of soccer and rappelling. The postoperative AOFAS AHS was from 68 to 86 points.

Resumo

Palavras-chave

- ▶ articulação do tornozelo
- ▶ artrodese
- ▶ osteoartrite
- ▶ procedimentos cirúrgicos minimamente invasivos
- ▶ procedimentos cirúrgicos operatórios
- ▶ tornozelo

A osteoartrite do tornozelo (OAT) está associada a quadro álgico e limitação funcional variável, demandando tratamento clínico e eventual indicação cirúrgica quando as medidas conservadoras são inefetivas – a artrodese tem sido o procedimento de escolha, por reduzir a dor, restaurar o alinhamento articular e tornar o segmento estável, preservando a marcha. O presente estudo relata 3 casos (3 tornozelos) de pacientes do sexo masculino, com entre 49 e 63 anos de idade, portadores de OAT secundária, American Orthopaedic Foot and Ankle Society Ankle-Hindfoot Scale (AOFAS AHS, na sigla em inglês) pré-operatória de 27 a 39 pontos, tratados mediante artrodese tibiotarsal minimamente invasiva utilizando haste intramedular retrógrada bloqueada. A permanência hospitalar foi de 1 dia, e os pacientes foram autorizados para carga imediata com órteses removíveis para deambulação, conforme tolerado. O tratamento fisioterápico, introduzido desde o internamento, foi mantido, priorizando-se treino de marcha, ganho de força e propriocepção. Foi realizado acompanhamento clínico e radiográfico nas semanas 1, 2, 6, 12 e 24. Após evidências de consolidação (entre a 6ª e a 10ª semanas), as órteses foram retiradas. Um paciente queixou-se de dor no pós-operatório imediato e, ao final do 1º ano, apenas 1 paciente apresentou dor durante a reabilitação, resolvida completamente com analgésicos. Atualmente, os pacientes não apresentam queixas, retornando às atividades sem restrições – um deles, à prática de futebol e rapel. A AOFAS AHS pós-operatória foi de 68 a 86 pontos.

Introduction

Primary ankle osteoarthritis (AOA) is rare, and its secondary form¹ is common for traumatic injuries, Charcot, rheumatoid arthritis, and avascular necrosis.^{2,3}

There are numerous treatment options for AOA, from clinical to surgical management, when conservative measures have no effect – the main options for open treatment include arthrodesis and replacement and distraction arthroplasties.⁴

Arthrodesis has been the procedure of choice for reducing pain, restoring alignment and stabilizing the segment, preserving gait.

Ankle arthrodesis can be performed using different types of implants and different access routes, using or not grafts or bone substitutes.²⁻⁴

Minimally invasive tibiotarsal arthrodesis (TTCA) by means of blocked retrograde intramedullary nail (BRIMN) has been indicated due to its biomechanical (shared load, greater bending stiffness, dynamic compression, and rotational stability) and biological (large bone contact area, minimally invasive procedure, articular opening that produces osteocartilaginous "syrup" with hematopoietic potential) advantages.^{3,5}

The aim of the present study is to report the cases of three patients with secondary AOA (three ankles) submitted to minimally invasive TTCA, using BRIMN.

Description of Cases

Three patients (three ankles) with secondary AOA, attended at our institution, were treated by minimally invasive TTCA using BRIMN, after failures in conservative measures (cases 1 and 2) and arthrodesis failure (case 3) (► **Fig. 1**), in 2017.

All patients were male, aged between 49 and 63 years old, with variable functional pain and limitation. The American Orthopedic Foot and Ankle Society Ankle-Hindfoot Scale (AOFAS AHS)⁶ was between 27 and 39 points (► **Table 1**).

The patients were positioned in supine position in a radiotransparent surgical table, under sedation, blockade and antibiotic prophylaxis, without ischemia or traction. The joints were accessed by three portals, one subtalar and two tibiotarsals (anterolateral and anteromedial), previously marked under fluoroscopy with a disposable 40 × 12mm needle. Incisions of 1.0 to 1.5 cm were made in the markings and dissection blunt to the joint capsules was performed, expanding the work area (► **Fig. 2**). A 4.3 mm motorized conical cutter was introduced for joint opening, complemented with curettes and osteotomes, exposing the subcondral bone. Joint preparation was completed by perforations with a 2.0 mm K-wire in the talar dome and tibial joint surface (► **Fig. 2**). It was fixed with BRIMN, in the traditional way. Skin sutures and compressive dressing were made. All procedures evolved without issues.

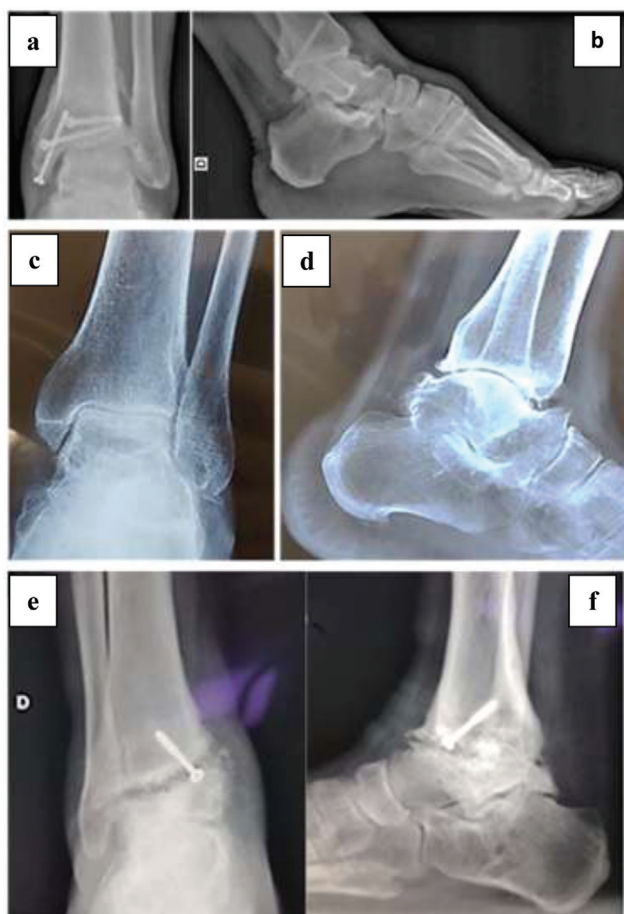

Fig. 1 Preoperative radiographic aspect: case 1 – sequela of tibial pylon fracture (a, b); case 2 – chronic ankle instability (c, d); and case 3 – failure in tibiotalar arthrodesis (e, f).

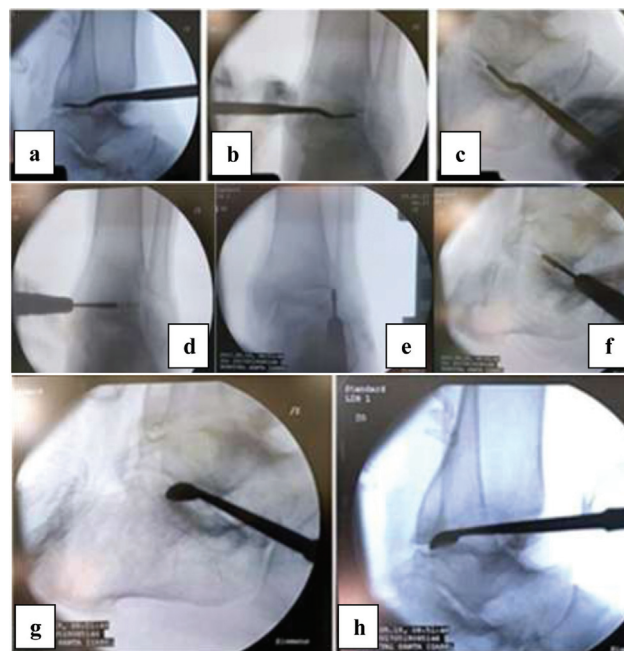


Fig. 2 Identification of the tibiotalar and subtalar joints through the respective portals (a, b, c). A 4.3 mm motorized conical cutter was introduced for joint opening (d, e, f). Complementation of opening with currettes, exposing the subcondral bone (g, h).

The patients were discharged on the 1st postoperative (PO) day. Immediate load initiated, as tolerated, using removable orthotics for ambulation. The stitches were removed on the 15th PO day.

Physical therapy treatment was introduced during hospitalization and continued in outpatient care, prioritizing gait training, strength gain, and proprioception.

Table 1 Description of clinical findings and pre- and postoperative American Orthopaedic Foot and Ankle Society Ankle-Hindfoot Scale and complications

	Case 1	Case 2	Patient 3
Gender	Male	Male	Male
Age (years old)	49	61	63
Main complaint	Pain	Pain	Pain
Side	Left	Left	Right
Arc of motion	5th	25th	10th
Deformity	Valgus	Neutral	Valgus
Diagnosis	Sequela of tibial pylon fracture	Chronic ankle instability	Failure in tibiotalar arthrodesis
Load start (weeks)	1	1	1
Consolidation time (weeks)	10	6	8
Preoperative AOFAS	39	33	27
Postoperative AOFAS	68	72	86
Early complication	No	Pain, resolved with painkillers	No
Late complication	No	No	Pain, resolved with painkillers

Abbreviation: AOFAS, American Orthopaedic Foot and Ankle Society Ankle-Hindfoot Scale

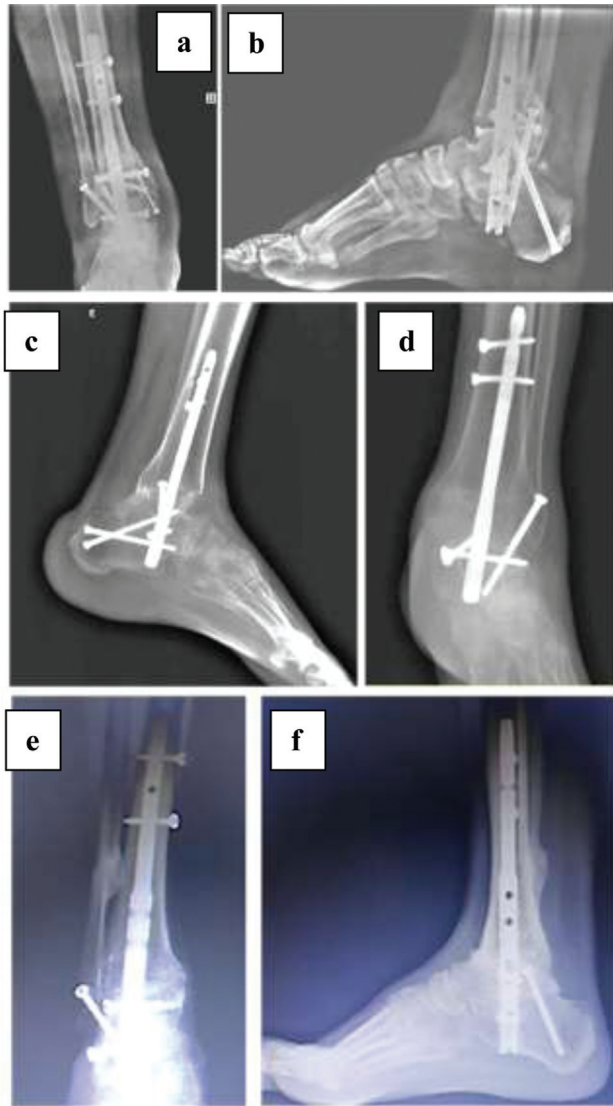


Fig. 3 Radiographic aspect in the late postoperative period of cases 1 (a, b), 2 (c, d) and 3 (e, f).

Clinical and radiographic follow-ups (►Fig. 3) were performed at weeks 1, 2, 6, 12 and 24. After evidence of consolidation, between the 6th and 10th weeks, the orthotics were removed (►Fig. 4).

One patient complained of pain in the immediate PO, which was resolved with analgesics. At the end of the 1st year, only 1 patient presented with pain during rehabilitation, which was completely resolved with analgesics. Currently (3rd PO year), the patients do not present complaints.

All patients returned to activities without restrictions – one of them, to sports (soccer and rappelling). The postoperative AOFAS AHS⁶ was between 68 and 86 points (►Table 1).

Discussion

Open TTCA is well-established in the treatment of AOA, regardless of the cause. It is an excellent alternative in the treatment of patients with poor preoperative conditions (low bone stock, misalignment of the hindfoot or history of multiple procedures).

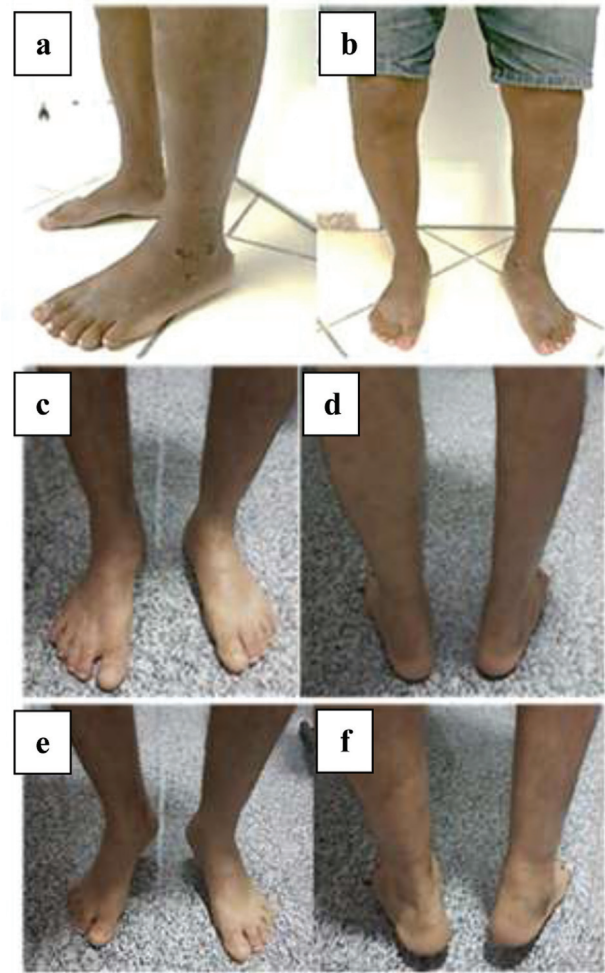


Fig. 4 Postoperative aspect of case 2 (a, b) and case 3 (c, d, and, f).

However, despite providing ample exposure, it demands a longer hospital stay and is subject to complications such as infection, dehiscence, and pseudarthrosis, enhanced by comorbidities, often present in patients undergoing this procedure.³

In a study with 20 patients submitted to open TTCA with BRIMN by AOA, Charcot and deformities, consolidation was observed in 80% of the tibiotalar and subtalar joints and in 20% of the tibiocalcaneans. The AOFAS AHS progressed from 54.20 ± 15.71 to 76.0 ± 11.63 ($p < 0.001$). The average hospital stay was 6.7 days. There was a high rate of complications, especially infections (35%), culminating in an amputation below the knee.⁷

Rammelt et al.⁸ evaluated open TTCA with BRIMN in 38 patients, by nonunion, AOA, deformity, Charcot and postarthroplasty failure. They described adequate alignment in 92% and fusion in 84% of the patients. The average stay was 8.4 days. They identified a risk of 24% of at least one postoperative complication, nonunion being the most common, followed by problems with implants and infection.

In a retrospective study,⁹ 29 patients with deformity underwent open TTCA with BRIMN, obtaining joint consolidation in 96.6%. There was an average increase in the AOFAS AHS from 29.7 to 74.3 ($p < 0.01$). As complications, three

cases of tibial stress, three cases of neuropraxia, and three of infection.

Given the potential for complications, some authors advocate minimally invasive approaches, including percutaneous TTCA through BRIMN.^{3,5}

Biz et al.⁵ presented 28 patients treated with TTCA by percutaneous BRIMN, most of them by post-traumatic AOA. They observed 100% consolidation and 92.85% of plantigrade and stable alignment. As complications, there were one case of screw Protrusion and one case of consolidation retardation, with associated pain.

A systematic review with meta-analysis² included 8 patients treated by open TTCA and 15 by the arthroscopic approach. Three patients submitted to open TTCA and four to the arthroscopic approach had plantar ulcers. The fusion rates were similar (75 versus 67%; $p = 0.679$). Complications occurred in 63% of open TTCAs (80% infections) and in 33% of the arthroscopic TTCA (100% nonunion). The presence of ulcers did not influence the genesis of open TTCA infection (67 versus 60%); however, there was a significant increase in nonunion in arthroscopic TTCA (75 versus 18%; $p = 0.039$). Patients without ulcer had a union rate of 80% for both methodologies.

We presented three cases of AOA treated by percutaneous TTCA with BRIMN. The length of stay (1 day) was considerably shorter than that of the literature for an open approach (between 3 and 8 days). The consolidation time (between 6 and 10 weeks) was lower than that of open procedures (12 weeks). The preoperative AOFAS AHS⁶ evolved from between 27 and 39 to between 68 and 86, a finding corroborated by the literature for TTCA with BRIMN,^{2,3,5,7-10} only observing early pain (1 patient) and late pain (1 patient), which were resolved after 1 year, without other complications so far.

Financial Support

There was no financial support from public, commercial, or non-profit sources.

Conflict of Interests

The authors have no conflict of interests to declare.

References

- 1 Saltzman CL, Salamon ML, Blanchard GM, et al. Epidemiology of ankle arthritis: report of a consecutive series of 639 patients from a tertiary orthopaedic center. *Iowa Orthop J* 2005; 25:44-46
- 2 Baumbach SF, Massen FK, Hörterer S, et al. Comparison of arthroscopic to open tibiototalcaneal arthrodesis in high-risk patients. *Foot Ankle Surg* 2019;25(06):804-811
- 3 Vilà y Rico J, Rodriguez-Martin J, Parra-Sanchez G, Marti Lopez-Amor C. Arthroscopic tibiototalcaneal arthrodesis with locked retrograde compression nail. *J Foot Ankle Surg* 2013;52(04): 523-528
- 4 Coughlin MJ, Nery C, Baumfeld D, Jastifer J. Artrodese tibiotársica compressiva com o uso de placa bloqueada lateral. *Rev Bras Ortop* 2012;47(05):611-615
- 5 Biz C, Hoxhaj B, Aldegheri R, Iacobellis C. Minimally invasive surgery for tibiototalcaneal arthrodesis using a retrograde intramedullary nail: preliminary results of an innovative modified technique. *J Foot Ankle Surg* 2016;55(06):1130-1138
- 6 Rodrigues RC, Masiero D, Mizusaki JM, et al. Translation, cultural adaptation and validity of the american orthopaedic foot and ankle society (AOFAS) ankle-hindfoot scale. *Acta Ortop Bras* 2008; 16(02):107-111
- 7 Lee BH, Fang C, Kunnasegaran R, Thevendran G. Tibiototalcaneal arthrodesis with the hindfoot arthrodesis nail: a prospective consecutive series from a single institution. *J Foot Ankle Surg* 2018;57(01):23-30
- 8 Rammelt S, Pyrc J, Agren PH, et al. Tibiototalcaneal fusion using the hindfoot arthrodesis nail: a multicenter study. *Foot Ankle Int* 2013;34(09):1245-1255
- 9 Brodsky JW, Verschae G, Tenenbaum S. Surgical correction of severe deformity of the ankle and hindfoot by arthrodesis using a compressing retrograde intramedullary nail. *Foot Ankle Int* 2014; 35(04):360-367
- 10 Thomas AE, Guyver PM, Taylor JM, Czipri M, Talbot NJ, Sharpe IT. Tibiototalcaneal arthrodesis with a compressive retrograde nail: A retrospective study of 59 nails. *Foot Ankle Surg* 2015;21 (03):202-205