



# Prevalence of Anatomical Variations in Patients with Carpal Tunnel Syndrome Undergoing Classical Open Carpal Tunnel Release

## *Prevalência de variações anatômicas encontradas em pacientes com síndrome do túnel do carpo submetidos a liberação cirúrgica por via aberta clássica*

Victor Spirandelli Pimentel<sup>1</sup> Bruna Borsari Artoni<sup>2</sup> Flavio Faloppa<sup>3</sup> João Carlos Belloti<sup>3</sup>  
Marcel Jun Sugawara Tamaoki<sup>3</sup> Benedito Felipe Rabay Pimentel<sup>1,4,5</sup>

<sup>1</sup> Faculdade de Medicina, Universidade de Taubaté (UNITAU), Taubaté, SP, Brazil

<sup>2</sup> Medicine Course, Faculdade de Medicina, Universidade Cidade de São Paulo (UNICID), São Paulo, SP, Brazil

<sup>3</sup> Orthopedics and Traumatology Department, Hand and Upper Limb Surgery Subject, Universidade Federal de São Paulo (UNIFESP), São Paulo, SP, Brazil

<sup>4</sup> Orthopedics and Traumatology Service, Hospital Municipal Universitário de Taubaté (H-MUT), Taubaté, SP, Brazil

<sup>5</sup> Orthopedics and Traumatology Service, Hospital Regional do Vale do Paraíba (HRVP), Complexo Hospitalar do Vale do Paraíba, Taubaté, SP, Brazil

Address for correspondence Benedito Felipe Rabay Pimentel, Rua Francisco de Barros, 239, Centro, Taubaté, SP, 12020 230, Brazil (e-mail: befecil@gmail.com).

Rev Bras Ortop 2022;57(4):636–641.

### Abstract

**Objective** To evaluate the prevalence of anatomical variations encountered in patients with carpal tunnel syndrome who underwent carpal tunnel classical open release.

**Methods** A total of 115 patients with a high probability of clinical diagnosis for carpal tunnel syndrome and indication for surgical treatment were included. These patients underwent electroneuromyography and ultrasound for diagnostic confirmation. They underwent surgical treatment by carpal tunnel classical open release, in which a complete inventory of the surgical wound was performed in the search and visualization of anatomical variations intra- and extra-carpal tunnel.

**Results** The total prevalence of anatomical variations intra- and extra-carpal tunnel found in this study was 63.5% (95% confidence interval [CI]: 54.5–72.4). The prevalence

### Keywords

- ▶ carpal tunnel syndrome
- ▶ median nerve
- ▶ surgical procedures
- ▶ prevalence

*Study performed at Hospital Regional do Vale do Paraíba (HRVP), Complexo Hospitalar do Vale do Paraíba, Faculdade de Medicina, Universidade de Taubaté (UNITAU), Taubaté, SP, Brazil.*

received  
October 18, 2020  
accepted  
January 8, 2021  
published online  
October 1, 2021

DOI <https://doi.org/10.1055/s-0041-1731361>.  
ISSN 0102-3616.

© 2021. Sociedade Brasileira de Ortopedia e Traumatologia. All rights reserved.

This is an open access article published by Thieme under the terms of the Creative Commons Attribution-NonDerivative-NonCommercial-License, permitting copying and reproduction so long as the original work is given appropriate credit. Contents may not be used for commercial purposes, or adapted, remixed, transformed or built upon. (<https://creativecommons.org/licenses/by-nc-nd/4.0/>)

Thieme Revinter Publicações Ltda., Rua do Matoso 170, Rio de Janeiro, RJ, CEP 20270-135, Brazil

of the carpal transverse muscle was 57.4% (95% CI: 47.8–66.6%), of the bifid median nerve associated with the persistent median artery was 1.7% (95% CI: 0.0–4.2%), and the median bifid nerve associated with the persistent median artery and the transverse carpal muscle was 1.7% (95% CI: 0.0–4.2%).

**Conclusion** The most prevalent extra-carpal tunnel anatomical variation was carpal transverse muscle. The most prevalent intra-carpal tunnel anatomical variation was median bifid nerve associated with the persistent median artery. The surgical finding of an extra-carpal tunnel anatomical variation, such as the transverse carpal muscle, may indicate the presence of other associated carpal intra tunnel anatomical variations, such as the bifid median nerve, persistent median artery, and anatomical variations of the recurrent median nerve branch.

## Resumo

**Objetivo** Avaliar a prevalência de variações anatômicas encontradas em pacientes com síndrome do túnel do carpo submetidos a liberação cirúrgica por via aberta clássica.

**Métodos** Foram incluídos um total de 115 pacientes com alta probabilidade de diagnóstico clínico de síndrome do túnel do carpo, com indicação para o tratamento cirúrgico. Estes pacientes realizaram eletroneuromiografia e ultrassonografia para confirmação diagnóstica. Foram submetidos ao tratamento cirúrgico por via aberta clássica, no qual foi realizado um inventário completo da ferida operatória na busca e visualização de variações anatômicas intra e extra túnel do carpo.

**Resultados** A prevalência total das variações anatômicas intra e extra túnel do carpo encontradas neste estudo foi de 63,5% (intervalo de confiança [IC]95%: 54,5–72,4%). A prevalência do músculo transverso do carpo foi de 57,4% (IC95%: 47,8–66,6%), do nervo mediano bífido associado à artéria mediana persistente foi de 1,7% (IC95%: 0,0–4,2%) e do nervo mediano bífido associado à artéria mediana persistente e ao músculo transverso do carpo foi de 1,7% (IC95%: 0,0–4,2%).

**Conclusão** A variação anatômica extra túnel do carpo mais prevalente foi o músculo transverso do carpo e a variação anatômica intra túnel do carpo mais prevalente foi o nervo mediano bífido associado à artéria mediana persistente. O achado cirúrgico de uma variação anatômica extra túnel do carpo, como o músculo transverso do carpo, pode nos indicar a presença de outras variações anatômicas intra túnel do carpo associadas, como nervo mediano bífido, artéria mediana persistente e variações anatômicas do ramo recorrente do nervo mediano.

## Palavras-chave

- ▶ síndrome do túnel do carpo
- ▶ nervo mediano
- ▶ procedimento cirúrgico
- ▶ prevalência

## Introduction

Carpal tunnel syndrome (CTS) is characterized by median nerve compression at the wrist level. It is the most common compressive neuropathy of the upper limb.<sup>1</sup> Surgical treatment with the classical open carpal tunnel release (OCTR) is one of the elective procedures most performed in hand surgery.<sup>1,2</sup> Proper preoperative planning, a reliable anatomical knowledge, and an understanding of unexpected anatomical differences are indispensable requirements to prevent negative surgical outcomes. This is especially true in a region with frequent intra- and extra-carpal tunnel anatomical variations, with widely varying prevalence values according to the study design.<sup>3,4</sup> In addition, combination of these anatomical variations and their relationship with CTS remain inconsistently and poorly described by the literature. Well-designed primary studies with good methodological quality on the prevalence of anatomical variations

in patients with CTS are uncommon.<sup>3,4</sup> As such, a study design was proposed based on the routine clinical practice of CTS experts in an attempt to evaluate the prevalence of anatomical variations in patients undergoing classical OCTR.

## Materials and Methods

This is a primary, single-center, transversal prevalence study approved by the ethics and research committee of our institution under the number 11/19. A total of 115 patients were included (n = 115), all females aged from 40 to 80 years old who presented unilateral or bilateral involvement. All subjects agreed to participate in the present study and signed the informed consent form. The patients underwent a previous conservative treatment with no effective clinical improvement and presented a probable CTS clinical diagnosis equal to or greater than 12 points, according to the list of six clinical criteria for the diagnosis of CTS (CTS-6) of Graham

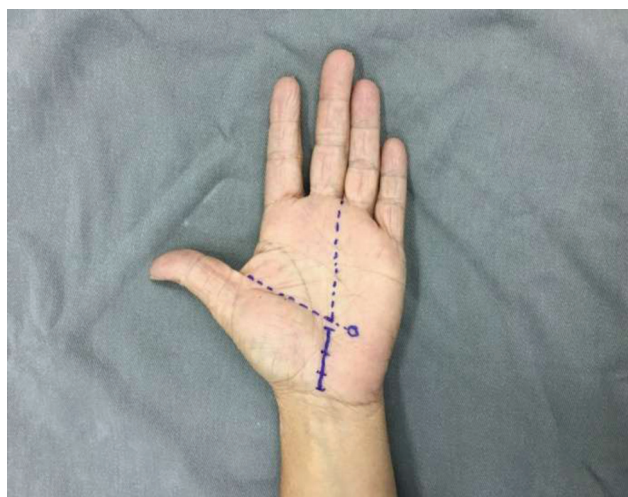
et al.<sup>5</sup> The CTS-6 was used to clinically evaluate potentially eligible patients, and their respective scores were the following: paresthesia (3.5), nocturnal paresthesia (4.0), thenar muscles hypotrophy and/or atrophy (5.0), Tinel test (4.0), Phalen test (5.0), and 2-point discrimination static test (5.0). Subjects with cervical radiculopathy, other compressive syndromes of the upper limbs, polyneuropathy, history of previous surgical carpal tunnel release, and sequelae from wrist fracture were excluded.

After clinical evaluation, the eligible patients were referred for further tests. A cross-sectional area  $\geq 10.0 \text{ mm}^2$  at the proximal anatomical limit of the carpal tunnel, directly measured using wrist ultrasound, and a median nerve sensory conduction rate lower than 50 m/s with a median nerve distal motor latency of 4.2 milliseconds or more at upper limb electroneuromyography confirmed CTS diagnosis.<sup>6-11</sup> Next, the patients were referred and submitted to surgical treatment at an outpatient facility. The procedure was performed consecutively at the operating room by the same hand surgeon. At the operating room, the patients were placed on the table in horizontal supine position with

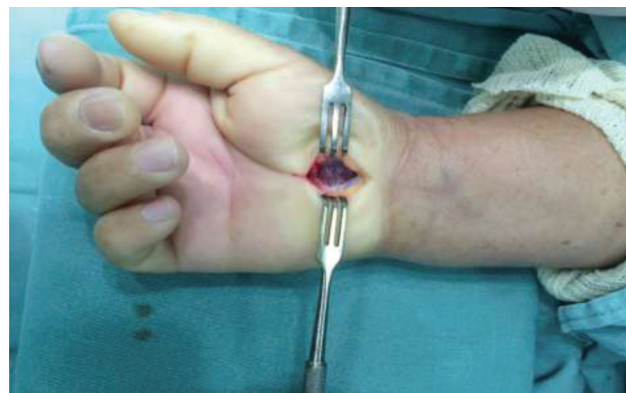the hand and wrist supported by an auxiliary table.<sup>12</sup> The Bier intravenous regional anesthesia technique was performed on the affected limb.<sup>13</sup> The surgical technique, classical OCTR, started with a palmar longitudinal incision of about 2 cm in length, which was aligned with the third interdigital space of the hand but with no proximal extension beyond the distal flexion fold of the wrist or distal extension beyond the Kaplan line (**►Figure 1**). The surgical approach was performed by anatomical planes: skin, subcutaneous tissue, palmar fascia, and transverse carpal ligament, which was opened completely distally and proximally to the carpal tunnel, largely releasing the median nerve (**►Figure 2**).<sup>12-14</sup>

During surgery, a complete inventory of the surgical wound was performed to detect intra- and extra-carpal tunnel anatomical variations (**►Figures 3 and 4**).

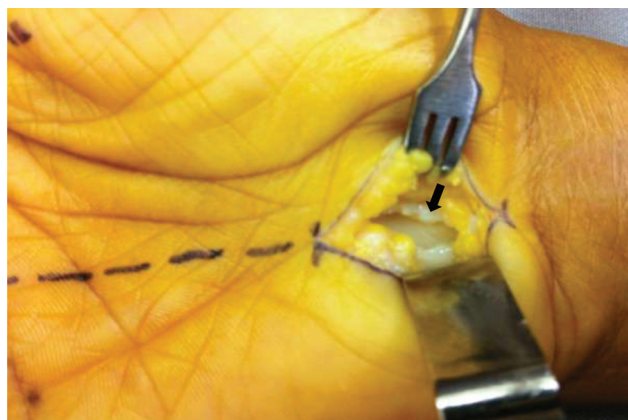
After surgical treatment, the patients were discharged on the same day and followed up at an outpatient facility for 6 months. The total number of recruited eligible patients was 10% more than the required amount to cover possible losses or exclusions during the study. **►Figure 5** shows each step of the study.



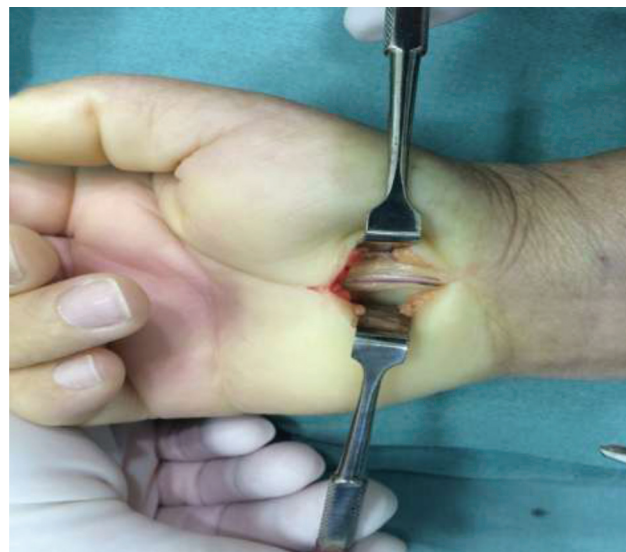
**Fig. 1** Surgical incision planning using the classical open carpal tunnel release technique.



**Fig. 3** Surgical finding of the transverse carpal muscle.



**Fig. 2** Surgical approach showing the transverse carpal ligament (arrow) completely open.



**Fig. 4** Surgical finding of the bifid median nerve associated to a persistent median artery.

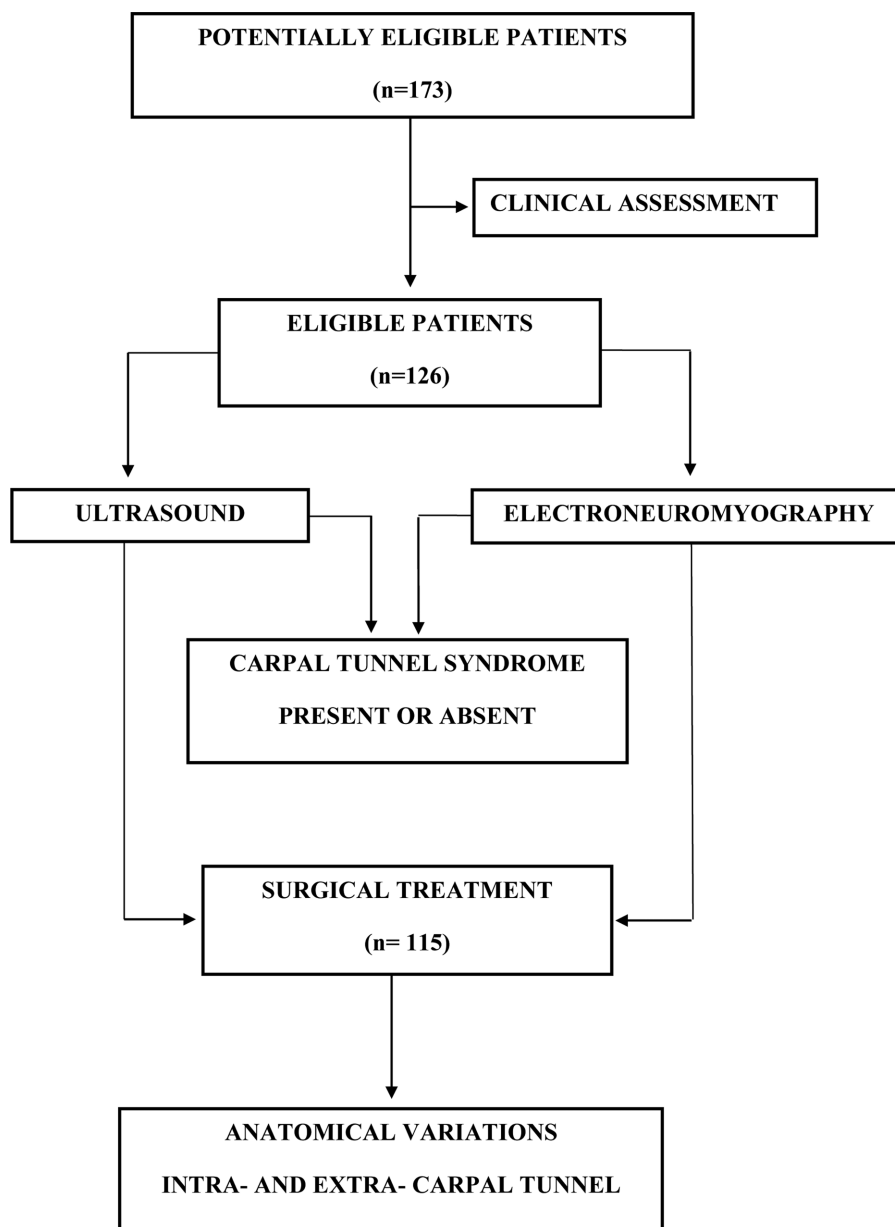


Fig. 5 Study flowchart.

### Statistical Analysis

Categorical variables were presented as relative and absolute frequencies, whereas numerical variables were shown as summary measures.<sup>15</sup> The prevalence of intra- and extra-carpal tunnel anatomical variations was presented as relative and absolute frequencies, as well as their respective 95% confidence intervals, which were calculated using the statistical software STATA 12 (Stata Corp. LLC, College Station, TX, USA).

## Results

### Patients Features

A total of 115 patients were evaluated. Their mean age was 52.9 years old (standard deviation, 9.1 years), ranging from 40 to 79 years old. Median age was 52 years old. Mean disease

duration was 4.0 years (standard deviation, 3.2 years), ranging from 1 year to 20 years. Median disease duration was 3 years. As for laterality, 109 patients (90.8%) had bilateral CTS and 6 patients (5.2%) had unilateral CTS. The right side was affected in 59 patients (51.3%), and the left side was affected in 56 patients (48.7%). Of the 73 patients (63.5%) with intra- and extra-carpal tunnel anatomical variations, 38 patients (52.0%) were operated on the right hand, and 35 patients (48.0%) were operated on the left hand. Sixty-five subjects (89.0%) were right-handed, whereas 8 patients (11.0%) were left-handed.

### Prevalence of Anatomical Variations

The total prevalence of anatomical variations in patients from this study was 63.5% (95% confidence interval [CI], 54.5–72.4%). Regarding extra-carpal tunnel anatomical



**Table 1** Prevalence of anatomical variations in patients with carpal tunnel syndrome undergoing classical open carpal tunnel release surgery

Anatomical variations	N (%)	95% CI (%)
TCM	66 (57.4)	47.8–66.6
BMN + PMA	2 (1.7)	0.0–4.2
BMN + PMA + TCM	2 (1.7)	0.0–4.2
TCM + TRB	1 (0.9)	0.0–2.6
TCM + MB	1 (0.9)	0.0–2.6
SRB	1 (0.9)	0.0–2.6
<b>TOTAL</b>	<b>73 (63.5)</b>	<b>54.5–72.4</b>

Abbreviations: PMA, persistent median artery; 95% CI, 95% confidence interval for proportions; TCM, transverse carpal muscle; BMN, bifid median nerve; SRB, subligamentous recurrent branch of the median nerve; TRB, transligamentous recurrent branch of the median nerve; MB, muscular belly of the flexor and longus digitorum superficialis tendon.  
n = 115.

Results are presented as total percentage values.

variations, the prevalence of a transverse carpal muscle was 57.4% (95% CI, 47.8–66.6%). As for intra-carpal tunnel anatomical variations, the prevalence of bifid median nerve with a persistent median artery was 1.7% (95% CI, 0.0–4.2%). Regarding combined intra- and extra-carpal tunnel variations, the prevalence of a bifid median nerve associated with a persistent median artery and transverse carpal muscle was 1.7% (95% CI, 0.0–4.2%). Other observed anatomical variations were a transverse carpal muscle associated with a transligamentous recurrent branch of the medial nerve, a transverse carpal muscle associated with the muscular belly of the flexor and longus digitorum superficialis tendon and a subligamentous recurrent branch of the median nerve, each with a 0.9% prevalence (95% CI, 0.0–2.6%). ▶ **Table 1** summarizes the results from this study.

## Discussion

This study follows the research line on CTS from our institution and originated from a clinical accuracy trial based on ultrasound and nerve conduction studies effectiveness for CTS diagnosis.<sup>16</sup> Carpal tunnel anatomical variations were classified by Singer and Asworth<sup>17</sup> as type I, intrinsic, or intra-carpal tunnel, when found inside the carpal tunnel, and type II, extrinsic, or extra-carpal tunnel, when lying over the transverse carpal ligament. In our study, both intra- and extra-carpal tunnel anatomy, whether associated or not, were directly related to a probable clinical diagnosis of CTS.<sup>18,19</sup> According to Green and Morgan,<sup>20</sup> in the presence of an extra-carpal tunnel anatomical variation, such as a transverse carpal muscle, there is a greater than 90% probability that the recurrent branch of the median nerve is anomalous, like the transligamentous branch found in our study. The younger age group and the dominant hand of CTS patients from our study were not determining factors correlated to a higher prevalence of intra- and extra-carpal tunnel

anatomical variations as reported by Singer and Asworth.<sup>17</sup> The bifid median nerve is an intra-carpal tunnel anatomical variation represented by a high bifurcation at the median nerve, proximal to the carpal tunnel.<sup>21,22</sup> This anatomical variation can coexist with a persistent median artery in 45% of the cases.<sup>19,22,23</sup> The prevalence of a bifid median nerve associated with a persistent median artery and the total prevalence of intra-carpal tunnel anatomical variations found in our study were similar to those reported by Lindley and Kleinert in their surgical study.<sup>3</sup> The transverse carpal muscle is an extra-carpal tunnel anatomical variation described by Rangoowansi et al.<sup>24</sup> as transverse muscle fibers that cover the transverse carpal ligament or interfere with it. In our study, the prevalence of the transverse carpal muscle was higher than expected, especially when compared with the prevalence reported by the surgical literature.<sup>20,21,24–27</sup> Tuncalli et al.<sup>26</sup> warned us about it, stating that the transverse carpal muscle was described in a similar way in most studies, but it was interpreted differently by several authors. Tuncalli believed that the frequency of the transverse carpal muscle was underestimated in the literature, with a higher prevalence than previously thought, because when it was found during OCTR it was erroneously interpreted as a hypertrophic thenar muscles, as a short palmar muscle or it was not aligned with the third interdigital space of the hand due to a more radial surgical incision, not complying with the surgical technique.<sup>26</sup> The main limitation of this study was the absence of a study group in cadavers of the intra- and extra-carpal tunnel anatomical variations found in our surgical study. The strength of this study was its design and consistency using a sample of patients with a high probability of CTS diagnosis and who underwent a good preoperative planning for a universal, reproducible surgical technique. As a future perspective, it would be interesting to conduct a study on how clinical and complementary findings in CTS patients behave in the presence of these intra- and extra-carpal tunnel anatomical variations.

## Conclusions

In patients with carpal tunnel syndrome who underwent classical OCTR, the most prevalent extra-carpal tunnel anatomical variation was the transverse carpal muscle, whereas the most prevalent intra-carpal tunnel anatomical variation was the bifid median nerve associated with a persistent median artery.

The surgical finding of an extra-carpal tunnel anatomical variation, such as a transverse carpal muscle, may reveal other intra-carpal tunnel anatomical variations, including bifid median nerve, persistent median artery, and anatomical differences at the recurrent branch of the median nerve.

### Financial Support

There was no financial support from public, commercial, or non-profit sources.

### Conflict of Interests

The authors declare that there is no conflict of interests.

## References

- 1 Bickel KD. Carpal tunnel syndrome. *J Hand Surg Am* 2010;35(01):147–152
- 2 Afshar A, Nasiri B, Mousavi SA, Hesarikia H, Navaeifar N, Taleb H. Anatomic Anomalies Encountered in 467 Open Carpal Tunnel Surgeries. *Arch Iran Med* 2016;19(04):285–287
- 3 Lindley SG, Kleinert JM. Prevalence of anatomic variations encountered in elective carpal tunnel release. *J Hand Surg Am* 2003;28(05):849–855
- 4 Walker FO, Cartwright MS, Blocker JN, et al. Prevalence of bifid median nerves and persistent median arteries and their association with carpal tunnel syndrome in a sample of Latino poultry processors and other manual workers [published correction appears in *Muscle Nerve*. 2014 Feb;49(2):297. Schultz, Mark R [corrected to Schulz, Mark R]]. *Muscle Nerve* 2013;48(04):539–544
- 5 Graham B, Regehr G, Naglie G, Wright JG. Development and validation of diagnostic criteria for carpal tunnel syndrome. *J Hand Surg Am* 2006;31(06):919–924
- 6 Trachani E, Rigopoulou A, Veltsista D, Gavanozi E, Chrysanthopoulou A, Chroni E. Occurrence of bifid median nerve in healthy and carpal tunnel syndrome patients. *J Electromyogr Kinesiol* 2018;39:77–80
- 7 Pimentel BF, Abicalaf CA, Braga L, et al. Cross-sectional area of the median nerve characterized by ultrasound in patients with carpal tunnel syndrome before and after the release of the transverse carpal ligament. *J Diagn Med Sonogr* 2013;29(03):116–121
- 8 Granata G, Caliendo P, Pazzaglia C, et al. Prevalence of bifid median nerve at wrist assessed through ultrasound. *Neurol Sci* 2011;32(04):615–618
- 9 Duncan I, Sullivan P, Lomas F. Sonography in the diagnosis of carpal tunnel syndrome. *AJR Am J Roentgenol* 1999;173(03):681–684
- 10 Ntani G, Palmer KT, Linaker C, et al. Symptoms, signs and nerve conduction velocities in patients with suspected carpal tunnel syndrome. *BMC Musculoskelet Disord* 2013;14:242
- 11 Jablecki CK, Andary MT, So YT, Wilkins DE, Williams F. F. H. A. A. E. M. Quality Assurance Committee. Literature review of the usefulness of nerve conduction studies and electromyography for the evaluation of patients with carpal tunnel syndrome. *Muscle Nerve* 1993;16(12):1392–1414
- 12 Louie D, Earp B, Blazar P. Long-term outcomes of carpal tunnel release: a critical review of the literature. *Hand (N Y)* 2012;7(03):242–246
- 13 Brill S, Middleton W, Brill G, Fisher A. Bier's block; 100 years old and still going strong!. *Acta Anaesthesiol Scand* 2004;48(01):117–122
- 14 Rodner CM, Katarinic J. Open carpal tunnel release. *Tech Orthop* 2006;21(01):3–11
- 15 Machin D, Campbell MJ, Tan SB, Tan SH. *Sample Size Tables for Clinical Studies*. 3rd ed. United Kingdom: Willey-Blackwell; 2009
- 16 Pimentel BFR, Faloppa F, Tamaoki MJS, Belloti JC. Effectiveness of ultrasonography and nerve conduction studies in the diagnosing of carpal tunnel syndrome: clinical trial on accuracy. *BMC Musculoskelet Disord* 2018;19(01):115
- 17 Singer G, Ashworth CR. Anatomic variations and carpal tunnel syndrome: 10-year clinical experience. *Clin Orthop Relat Res* 2001;(392):330–340
- 18 Prime MS, Palmer J, Khan WS, Goddard NJ. Is there Light at the End of the Tunnel? Controversies in the Diagnosis and Management of Carpal Tunnel Syndrome. *Hand (N Y)* 2010;5(04):354–360
- 19 Bayrak IK, Bayrak AO, Kale M, Turker H, Diren B. Bifid median nerve in patients with carpal tunnel syndrome. *J Ultrasound Med* 2008;27(08):1129–1136
- 20 Green DP, Morgan JP. Correlation between muscle morphology of the transverse carpal ligament and branching pattern of the motor branch of median nerve. *J Hand Surg Am* 2008;33(09):1505–1511
- 21 Caetano EB, Caetano MF, Fregona LR, Neri IDO, Nunes RPS, Campos DLP. Variações do nervo mediano no túnel do carpo. *Rev Bras Ortop* 2005;40(10):608–613
- 21 Lanz U. Anatomical variations of the median nerve in the carpal tunnel. *J Hand Surg Am* 1977;2(01):44–53
- 23 Tountas CP, Bihrlle DM, MacDonald CJ, Bergman RA. Variations of the median nerve in the carpal canal. *J Hand Surg Am* 1987;12(5 Pt 1):708–712
- 24 Ragoowansi R, Adeniran A, Moss AL. Anomalous muscle of the wrist. *Clin Anat* 2002;15(05):363–365
- 25 Hollevoet N, Barbaix E, D'herde K, Vanhove W, Verdonk R. Muscle fibres crossing the line of incision used in carpal tunnel decompression. *J Hand Surg Eur Vol* 2010;35(02):115–119
- 26 Tuncali D, Barutcu AY, Terzioglu A, Aslan G. Transverse carpal muscle in association with carpal tunnel syndrome: report of three cases. *Clin Anat* 2005;18(04):308–312
- 27 Henry BM, Zwinczewska H, Roy J, et al. The Prevalence of Anatomical Variations of the Median Nerve in the Carpal Tunnel: A Systematic Review and Meta-Analysis. *PLoS One* 2015;10(08):e0136477 Erratum in: *PLoS One* 2015;10(9):e0138300