

## Hepatobiliary Cancer

# Transarterial Radioembolization (TARE) with <sup>131</sup>Iodine-Lipiodol for Unresectable Primary Hepatocellular Carcinoma: Experience from a Tertiary Care Center in India

Aakash Patel<sup>1</sup> Indusekhara Subbanna<sup>1</sup> Vidya Bhargavi<sup>1</sup> Shivakumar Swamy<sup>1</sup>  
Kumarswamy G. Kallur<sup>2</sup> Shekhar Patil<sup>3</sup>

<sup>1</sup>Department of Interventional Radiology, HCG Hospital, Bangalore, Karnataka, India

<sup>2</sup>Department of Nuclear Medicine, HCG Hospital, Bangalore, Karnataka, India

<sup>3</sup>Department of Medical Oncology, HCG Hospital, Bangalore, Karnataka, India

**Address for correspondence** Aakash Patel, MBBS, DNB, Department of Interventional Radiology, Health Care Global (HCG) Hospital, P. Kalinga Rao Road, Bangalore 560027, Karnataka, India (e-mail: aakashpt19@gmail.com).

South Asian J Cancer 2021;10:81–86.

## Abstract



Aakash Patel

**Purpose** This article presents our experience regarding survival benefits in inoperable intermediate stage hepatocellular carcinoma (HCC) and advanced stage HCC treated with <sup>131</sup>I-lipiodol.

**Materials and Methods** This is a retrospective study of intermediate stage HCC (Barcelona Clinic Liver Cancer [BCLC] stage B) not responding to prior treatment and/or advanced stage HCC (BCLC stage C) treated with <sup>131</sup>I-lipiodol. <sup>131</sup>I-lipiodol was injected into the hepatic artery through transfemoral route. Postprocedure, the patient was isolated for 5 to 7 days. All patients underwent tumor response evaluation after 4 weeks. Survival of patients was calculated up to either death or conclusion of the study.

**Results** A total of 55 patients (52 males [94.5%], 3 females [5.4%]) were given intra-arterial <sup>131</sup>I-lipiodol therapy. The median overall survival after transarterial radioembolization (TARE) was 172 ± 47 days (95% confidence limit, 79–264 days). The overall survival at 3, 6, 9, and 12 months was 69, 47, 32, and 29%, respectively. A multivariate Cox regression analysis showed the presence of treatment prior to TARE to most significantly influence survival ( $B = 2.161$ ,  $p \leq 0.001$ ). This was followed by size of the lesion which was second in line ( $B = 0.536$ ,  $p = 0.034$ ). Among 45 patients, 14 patients (31.1%) showed a partial response, 11 patients (24.4%) showed stable disease, and 20 patients (44.4%) showed progressive diseases.

**Conclusion** TARE with <sup>131</sup>I-lipiodol can be a safe and effective palliative treatment in advanced stage HCC and in patients with poor response to prior treatments like transarterial chemoembolization.

## Keywords

- ▶ HCC
- ▶ hepatocellular carcinoma
- ▶ iodine-131-lipiodol
- ▶ neoplasm
- ▶ transarterial radioembolization

DOI <https://doi.org/10.1055/s-0041-1731600> ISSN 2278-330X

**How to cite this article:** Patel A, Subbanna I, Bhargavi V, Swamy S, Kallur K. G, Patil S. Transarterial Radioembolization (TARE) with <sup>131</sup>Iodine-Lipiodol for Unresectable Primary Hepatocellular Carcinoma: Experience from a Tertiary Care Center in India South Asian J Cancer 2021;10(2):81–86.

© 2021. MedIntel Services Pvt Ltd.

This is an open access article published by Thieme under the terms of the Creative Commons Attribution-NonDerivative-NonCommercial-License, permitting copying and reproduction so long as the original work is given appropriate credit. Contents may not be used for commercial purposes, or adapted, remixed, transformed or built upon. (<https://creativecommons.org/licenses/by-nc-nd/4.0/>).

Thieme Medical and Scientific Publishers Private Ltd A-12, Second Floor, Sector -2, NOIDA -201301, India

## Introduction

The purpose of this study is to present our experience regarding survival benefits in inoperable intermediate stage hepatocellular carcinoma (HCC) and advanced stage HCC treated with <sup>131</sup>I-lipiodol in 55 consecutive patients.

## Materials and Methods

Approval was taken from the institutional ethics committee and written informed consent was obtained from all patients. This is a retrospective study in HCC patients who underwent transarterial radioembolization (TARE) between January 2014 and March 2017 at our institute. Patients with intermediate stage HCC (Barcelona Clinic Liver Cancer [BCLC] stage B) not responding to prior treatment and/or advanced stage HCC (patients with portal vein thrombosis [PVT]) (BCLC stage C) treated with <sup>131</sup>I-lipiodol were included in the study. For diagnosis of HCC the modified European Association for Study of Liver (EASL) criteria was followed.<sup>1</sup> For all patients, baseline laboratory workup and imaging (computed tomography/positron emission tomography [CT/PET]-CT/magnetic resonance imaging [MRI]) were performed. The presence of PVT was recorded. The Child–Pugh and BCLC scores were calculated.

**Patient selection:** Intra-arterial <sup>131</sup>I-lipiodol therapy was given to BCLC stage B/C patients with Child–Pugh class A/B cirrhosis having PVT evident on cross-sectional imaging (CT/PET-CT/MRI) or patients without PVT not responding to prior treatment. Patients with Child–Pugh class A and BCLC stage B, not suitable for curative procedure were considered for intra-arterial <sup>131</sup>I-lipiodol therapy. Patients with BCLC stage D, Child–Pugh class C cirrhosis, demonstrable arteriovenous or arteriportal shunting on CT or digital subtraction angiography (DSA), uncorrectable coagulopathy, and renal failure were excluded.

**Technique:** Intra-arterial <sup>131</sup>I-lipiodol therapy was performed under local anesthesia through transfemoral approach. Introducer sheath (5F) (Terumo, Europe N.V.) was used to access the femoral artery. Celiac artery and superior mesenteric artery were catheterized using 4F Yashiro catheter (Terumo, Europe N.V.) or 4F Renal curve catheter (Terumo, Europe N.V.) and angiogram obtained to delineate vascular anatomy and identify vessels supplying the tumor. Routine DSA was performed in all patients and if there was arteriovenous or arteriportal shunting the procedure was abandoned. The vessel supplying the tumor bed were super selectively catheterized using 4F Yashiro catheter (Terumo, Europe N.V.) or 4F Renal curve catheter (Terumo, Europe N.V.) or 2.7F microcatheter (Progreat, Terumo, Europe N.V.) depending on the vascular anatomy. Doxorubicin (20 mg) was injected as a radiosensitizer which was followed by slow injection of 7 to 10 mL <sup>131</sup>I-lipiodol (~50 mCi) under fluoroscopic control with adequate radiation protection. In cases with extensive bilateral disease, infusion was started with catheter tip in hepatic artery proper, distal to the gastroduodenal artery (GDA) origin to prevent reflux into GDA. The injection was stopped when the lesion showed adequate lipiodol fixation or if there was reflux into the normal branches. The puncture site was

closed using a closure device (Star closure device, Abbott Vascular, Illinois, United States) and all radioactive lines were disposed as per radiation safety rules. Postprocedure, the patient was isolated for 5 to 7 days and discharged after confirming the emitted gamma radiation levels to be below 5 mR per hour. A scintigraphy scan was obtained 4 days after therapy to confirm tumor uptake of <sup>131</sup>I-lipiodol.

Patients did not receive any additional therapy after TARE for 6 to 8 weeks. All patients underwent clinical, biochemical (serum alpha-fetoprotein [S.AFP]), and radiological examination to evaluate tumor response after 4 weeks. Tumor response was graded according to the EASL response criteria.<sup>1</sup>

Survival of patients was calculated up to either death or conclusion of the study. Survival in patients who did not come for follow-up was calculated on the basis of information provided by patient's kin through telephonic calls.

**Statistical analysis:** Data were analyzed using a statistical analysis package (Social sciences, version 15.0 for Windows; SPSS Inc.). Survival data were plotted using Kaplan–Meier survival curves.

## Results

A total of 55 patients (52 males [94.5%], 3 females [5.4%]) were given intra-arterial <sup>131</sup>I-lipiodol therapy with a mean age of 63.9 ± 11.7 years (age range: 29–82 years). Thirty-six patients (65.4%) belonged to Child–Pugh class A and 19 patients (34.5%) belonged to class B. Nineteen patients (34.5%) belonged to BCLC stage B and 36 patients (65.4%) belonged to BCLC stage C. Twenty-seven patients (49%) had PVT out of which 12 patients had branch PVT and 15 had main PVT. In 28 patients (50.9%) PVT was absent. Twenty-four patients (43.6%) had extrahepatic spread on imaging (regional lymph node enlargement) while 31 patients (56.3%) had a localized disease. Mean tumor size was 10.1 cm (range: 1.7–21.7 cm). For multifocal disease, the size of the largest lesion was taken into consideration. Six patients (10.9%) had tumor of size < 5 cm, 20 patients (36.3%) had tumor of size 5 to 10 cm, and 29 patients (52.7%) had tumor of size > 10 cm. Twenty patients (36.3%) had solitary lesion while 35 patients (63.6%) had multifocal diseases at the time of treatment. Total 16 patients (29%) having a history of prior treatment were treated with <sup>131</sup>I-lipiodol in our study. All patients with prior treatment had prior cycle/s of transarterial chemoembolization (TACE). Out of these 16 patients, 5 had additional treatment with tablet sorafenib, 2 patients had additional treatment with radiofrequency (RF) ablation, and 2 patients had prior partial hepatectomy with recurrent disease. Twenty-nine patients (52.7%) had elevated S.AFP values (> 300 ng/mL) and 26 patients (47.2%) had normal S.AFP values at the time of treatment. Fifteen patients (27.2%) were hepatitis B positive and 4 patients (7.2%) were hepatitis C positive.

Overall, the procedure was well tolerated by all our patients with mild intra-/postprocedural toxicities ranging from pain, fever, nausea, vomiting, and loss of appetite occurring in 43.6% of our patients. Only one patient in our study had severe postprocedural complication in the form

of hepatic abscess formation which was effectively managed by parenteral antibiotics. This patient had a metallic biliary stent placement prior to treatment to treat obstructive jaundice secondary caused by HCC.

### Survival Data

At the end of follow-up period (January 2014–March 2017) 46 of 55 patients had died with 9 patients alive.

#### Survival after TARE

The median overall survival after TARE was 172 ± 47 days (95% confidence limit, 79–264 days). The overall survival at 3, 6, 9, and 12 months was 69, 47, 32, and 29%, respectively. We did not have any 30-day mortality.

The median survival in days after TARE in various groups is summarized in **Table 1**. Percentage survival at 6 and 12 months after TARE in various groups is summarized in **Table 2**.

Child–Pugh class A patients with solitary lesion showed median survival of 322 days ± 138 days (95% confidence limit, 50–593 days) and those with multiple lesions showed median survival of 217 days ± 55 days (95% confidence limit, 108–325 days). Child–Pugh class B patients with solitary lesion showed median survival of 134 days ± 20 days (95% confidence limit, 93–174 days) and those with multiple lesions showed median survival of 114 days ± 40 days (95% confidence limit, 34–193 days) (log rank chi-square = 0.033, *p* = 0.856).

#### Survival after Diagnosis

The overall median survival after TARE was 253 ± 73 days (95% confidence limit, 108–397 days). The survival at 3, 6, 9, and 12 months were 85, 65, 47, and 40%, respectively.

The median survival in days after diagnosis in various groups is summarized in **Table 1**. Percentage survival at 6 and 12 months after diagnosis in various groups is summarized in **Table 2**.

**Table 1** Summary of median survival in days

Summary of median survival in days	Survival since treatment			Survival since diagnosis		
	Median	95% confidence limit	<i>p</i> -Value	Median	95% confidence limit	<i>p</i> -Value
Overall	172	79–264		253	108–397	
Child–Pugh class						
Class A	217	108–325	0.715	253	97–408	0.729
Class B	133	104–161		222	0–521	
BCLC stage						
Stage B	134	42–225	0.703	338	147–528	0.283
Stage C	172	77–266		238	57–418	
PVT						
Present	169	122–215	0.319	194	124–263	0.05
Absent	184	0–444		397	274–519	
Extrahepatic spread						
Present	169	54–283	0.702	253	0–505	0.614
Absent	172	51–292		281	128–433	
Prior treatment						
With	427	334–519	0.034	750	515–984	< 0.001
Without	134	81–186		176	144–207	
Size of lesion						
< 5 cm	809 (mean)	543–1,075	0.005	1,824 (mean)	1,109–2,539	0.014
5–10 cm	217	96–337		253	74–431	
> 10 cm	133	93–172		185	104–265	
Number of lesion						
Solitary	172	0–405	0.983	386	129–642	0.961
Multifocal	169	60–277		238	154–321	

Abbreviations: BCLC, Barcelona Clinic Liver Cancer; PVT, portal vein thrombosis.

**Table 2** Summary of percentage survival at 6 and 12 months

Percentage (%) survival	Survival since treatment		Survival since diagnosis	
	6 mo	12 mo	6 mo	12 mo
Child–Pugh class				
Class A	55	33	66	38
Class B	31	21	63	42
BCLC stage				
Stage B	47	26	68	63
Stage C	47	30	63	36
PVT				
Present	40	18	59	22
Absent	53	39	71	57
Extrahepatic spread				
Present	50	29	58	37
Absent	45	29	70	42
Prior treatment				
With	68	56	100	87
Without	38	18	51	20
Number of lesion				
Solitary	45	30	65	45
Multifocal	48.5	31.4	65.7	37.1

Abbreviations: BCLC, Barcelona Clinic Liver Cancer; PVT, portal vein thrombosis.

## Factors Associated with Survival after Treatment

A multivariate Cox regression analysis with Child–Pugh class, BCLC stage, PVT, extrahepatic spread, prior treatment, size of the lesion, and number of lesions as predictors for overall survival showed the presence of prior treatment to most significantly influence survival ( $B = 2.161$ ,  $p \leq 0.001$ ) followed by size of the lesion which was second in line ( $B = 0.536$ ,  $p = 0.034$ ).

## Response Evaluation

Response evaluation could not be done in 10 patients as they did not undergo follow-up imaging. In the rest of the 45 patients, 14 patients (31.1%) showed a partial response (–Figs. 1 and 2), 11 patients (24.4%) showed stable disease, and 20 patients (44.4%) showed progressive diseases. All patients with partial response showed reduction in S.AFP levels.

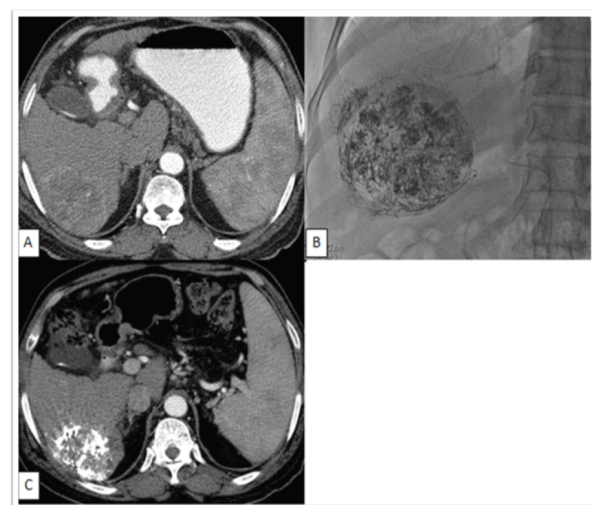
On follow-up, 9 patients were given additional treatment with TACE and 5 patients were started on systemic therapy with tablet sorafenib. In one of these patients, severe toxicity necessitated stoppage of sorafenib therapy within 1 month.

## Discussion

The Indian National Association for Study of the Liver modified BCLC staging system is recommended for prognostic prediction and treatment allocation.<sup>2,3</sup> Curative treatment options in the form of liver resections, ablations, and liver

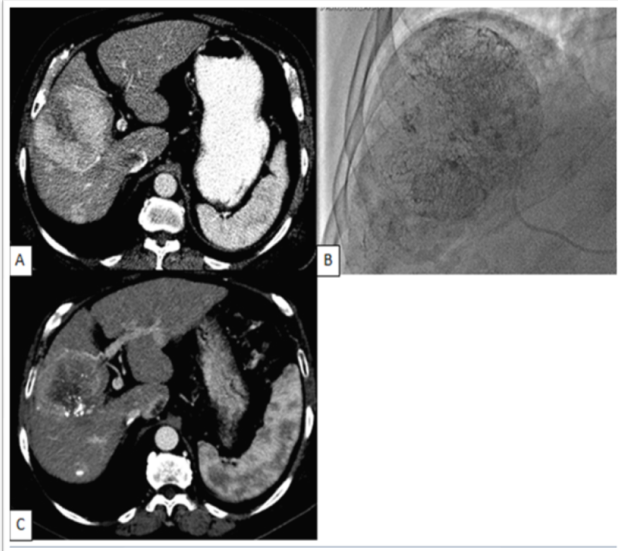
transplant are recommended for BCLC stage 0 and stage A patients. Resection of liver tumors still play an important role and can be performed with acceptable mortality and morbidity as R0 resection can be achieved in as many as 91.9% of patients in early stages.<sup>4</sup>

The treatment options for inoperable intermediate stage HCC include TACE, TARE, and stereotactic body radiation



**Fig. 1** (A) Contrast-enhanced computerized tomography (CECT) demonstrates hypervascular lesion in segment 6 of liver. (B) Lipiodol deposition after transarterial radioembolization (TARE) with  $^{131}\text{I}$ -lipiodol within the hypervascular lesion. (C) CECT after 1 month demonstrates lipiodol deposition with reduction in the enhancing areas within the tumor. Patient was considered to have partial response.





**Fig. 2** (A) Contrast-enhanced computerized tomography (CECT) demonstrates two hypervascular lesions in right lobe of liver. (B) Lipiodol deposition after transarterial radioembolization (TARE) with  $^{131}\text{I}$ -lipiodol within the hypervascular lesion. (C) CECT of the patient after 1 month demonstrates lipiodol deposition with reduction in the enhancing areas within the tumor. Patient was considered to have partial response.

therapy (SBRT). Systemic therapy is reserved for advanced stage HCC (2, 3 - Puri I and II).

TACE is the most widely used treatment option in patient with HCC who are unsuitable candidates for curative management.<sup>5</sup> Efficacy of TACE for palliation of unresectable HCC has been demonstrated in several studies, with overall survival rate at 1, 2, and 3 years being 66, 47, and 36.4%, respectively.<sup>6</sup> TACE can also be combined with modalities like RF ablation and SBRT.

SBRT is an important addition in the treatment armamentarium in patients with inoperable intermediate stage HCC.<sup>7</sup> Culleton et al<sup>8</sup> published a prospective study on 29 patients with HCC with Child–Pugh class B 7 and above. They reported that patients with Child–Pugh class B 7 have a significantly higher median overall survival of 9.9 months versus 2.8 months in Child–Pugh class B 8 and above patients ( $p = 0.011$ ). They also suggested Child–Pugh class B 8 and above and AFP level of  $> 4,491$  ng/mL were poor prognostic factors. All these suggested that patients with Child–Pugh class B 8 and above should not be treated with SBRT as it may not improve outcome.

TARE can successfully be used in all patients in whom TACE is indicated; however, superiority of TARE over TACE has not been documented in literature. In a meta-analysis that compared clinical outcomes of TACE versus TARE in unresectable HCC, there was no statistically significant difference in survival for up to 4 years between the two groups.<sup>9</sup> TARE is probably more suitable in patient where TACE is contraindicated like patients with PVT. Multiple radioactive substances have been tested which includes  $^{131}\text{I}$ -lipiodol, rhenium-188, and glass-based and resin-based  $^{90}\text{Y}$  microspheres.  $^{131}\text{I}$ -lipiodol therapy is safe and effective palliative treatment for unresectable HCC.<sup>10</sup>

Very limited recent data are available regarding effectiveness of  $^{131}\text{I}$ -lipiodol therapy. One of the studies showed the overall survival benefits of  $^{131}\text{I}$ -lipiodol of approximately 69, 38, 22, and 14% at 6 months, 1, 2, and 3 years, respectively.<sup>11</sup> Recent studies regarding  $^{131}\text{I}$ -lipiodol treatment in unresectable HCC reported median survival ranging between 7 and 27 months. The heterogeneous survival results can be explained by the selection of patients for treatment. A study by Boucher et al<sup>12</sup> showed median survival of 27 months. In this study, a significant proportion of patients were in the early stage of disease with a Cancer of the Liver Italian Program score of 0 to 1, underwent two treatments, and had one or two tumors. Study by Kanhere et al<sup>13</sup> showed median survival of 15 months and study by Borbath et al<sup>14</sup> showed median survival of 7 months. The poorer survival outcome in the study by Borbath et al was likely attributed to the finding that a third of patients in that group had evidence of PVT. In our study, the overall median survival was  $172 \pm 47$  days (95% confidence limit, 79–264 days). The survival at 3, 6, 9, and 12 months were 69, 47, 32, and 29%, respectively, with the majority of patients (65.4%) having an advanced stage of disease and 49% having PVT.

Our study showed patients having a history of prior treatment benefited more with  $^{131}\text{I}$  lipiodol as compared with those treated upfront with  $^{131}\text{I}$ -lipiodol. The reason for this could be selection of patients with more advanced disease for upfront treatment with  $^{131}\text{I}$ -lipiodol as compared with patients having prior treatment with TACE. Also, the initial size of the tumor at the time of treatment influenced survival significantly, which is of grave importance in developing countries where the majority of patients present with large size of the tumor at the time of diagnosis. For better treatment outcome, it is important to implement screening programs for HCC in high-risk patients like in developed countries, which enable early detection and early treatment.

Other radionuclide therapies including  $^{90}\text{Y}$  have also been reported to be effective therapies for HCC.  $^{90}\text{Y}$  embedded microspheres tend to cost up to 10 times more than  $^{131}\text{I}$ -lipiodol making it a significant limiting factor in population of developing countries. Moreover, treatment with  $^{90}\text{Y}$  embedded microspheres is a multistaged treatment process requiring two separate treatment sessions for bilobar disease unlike in treatment with  $^{131}\text{I}$ -lipiodol where a single injection in the hepatic artery proper will result in tumor uptake in both lobes. In our study, advanced stage HCC patients showed median survival of 172 days as compared with reported median overall survivals ranging from 6 to 10 months in patients with advanced stage HCC treated by  $^{90}\text{Y}$  embedded microspheres.<sup>15</sup> Another study showed a median survival of 8.4 months in patients treated with TheraSphere as compared with 7.8 months in patients treated with SIR-Sphere.<sup>16</sup> To our knowledge no randomized control trials exists comparing treatment with  $^{131}\text{I}$ -lipiodol and  $^{90}\text{Y}$  embedded microspheres in patients with unresectable HCC. In future treatment with  $^{131}\text{I}$ -lipiodol and  $^{90}\text{Y}$  embedded microspheres in patients with unresectable HCC should be evaluated in a randomized control trial.

## Conclusion

TARE with <sup>131</sup>I-lipiodol can be a safe and effective palliative treatment in advanced stage HCC and in patients with poor response to prior treatments like TACE. TARE with <sup>131</sup>I-lipiodol is a cheaper alternative compared with TARE with <sup>90</sup>Y embedded microspheres in developing countries like India.

### Source(s) of Support

None.

### Conflicting Interest

None declared.

## References

- 1 Bruix J, Sherman M, Llovet JM, et al. EASL panel of experts on HCC: clinical management of hepatocellular carcinoma. Conclusions of the Barcelona EASL conference. European Association for the Study of Liver. *J Hepatol* 2001;35:421–430
- 2 Kumar A, Acharya SK, Singh SP, et al. (The INASL Task-Force on Hepatocellular Carcinoma). The Indian National Association for Study of the Liver (INASL) consensus on prevention, diagnosis and management of hepatocellular carcinoma in India: the Puri recommendations. *J Clin Exp Hepatol* 2014;4(Suppl 3):S3–S26
- 3 Kumar A, Acharya SK, Singh SP, et al. INASL Task-Force on Hepatocellular Carcinoma. 2019 update of Indian National Association for Study of the Liver consensus on prevention, diagnosis, and management of hepatocellular carcinoma in India: the Puri II recommendations. *J Clin Exp Hepatol* 2020;10(1):43–80
- 4 Khobragade K, Kanetkar A, Kurunkar S, Patkar S, Goel M. Five hundred oncological liver resections: single centre experience from Tata Memorial Hospital, Mumbai. *HPB (Oxford)* 2018;20:S387
- 5 Llovet JM, Burroughs A, Bruix J. Hepatocellular carcinoma. *Lancet* 2003;362(9399):1907–1917
- 6 Paul SB, Gamanagatti S, Sreenivas V, et al. Trans-arterial chemoembolization (TACE) in patients with unresectable Hepatocellular carcinoma: experience from a tertiary care centre in India. *Indian J Radiol Imaging* 2011;21(2):113–120
- 7 Saini G. Stereotactic body radiation therapy in hepatocellular carcinoma. *Indian J Med Paediatr Oncol* 2020;41:488–491
- 8 Culleton S, Jiang H, Haddad CR, et al. Outcomes following definitive stereotactic body radiotherapy for patients with Child-Pugh B or C hepatocellular carcinoma. *Radiother Oncol* 2014;111(3):412–417
- 9 Lobo L, Yakoub D, Picado O, et al. Unresectable hepatocellular carcinoma: radioembolization versus chemoembolization: a systematic review and meta-analysis. *Cardiovasc Intervent Radiol* 2016;39(11):1580–1588
- 10 Paul SB, Manjunatha YC, Acharya SK. Palliative treatment in advanced hepatocellular carcinoma: has it made any difference? *Trop Gastroenterol* 2009;30(3):125–134
- 11 Lau WY. Radiotherapy with emphasis on radioembolization for liver tumors. In: Blumgart LH, Fong Y, eds. *Surgery of the Liver and Biliary Tract*. 2nd ed. London: W. B. Saunders London; 2000 1545–1564
- 12 Boucher E, Garin E, Guyligomarc'h A, Ollivié D, Boudjema K, Raoul J-L. Intra-arterial injection of iodine-131-labeled lipiodol for treatment of hepatocellular carcinoma. *Radiother Oncol* 2007;82(1):76–82
- 13 Kanhere HA, Leopardi LN, Fischer L, Kitchener MI, Maddern GJ. Treatment of unresectable hepatocellular carcinoma with radiolabelled lipiodol. *ANZ J Surg* 2008;78(5):371–376
- 14 Borbath I, Lhommel R, Bittich L, et al. <sup>131</sup>I-Labelled-iodized oil for palliative treatment of hepatocellular carcinoma. *Eur J Gastroenterol Hepatol* 2005;17(9):905–910
- 15 Salem R, Lewandowski RJ, Mulcahy MF, et al. Radioembolization for hepatocellular carcinoma using Yttrium-90 microspheres: a comprehensive report of long-term outcomes. *Gastroenterology* 2010;138(1):52–64
- 16 Bhangoo MS, Karnani DR, Hein PN, et al. Radioembolization with Yttrium-90 microspheres for patients with unresectable hepatocellular carcinoma. *J Gastrointest Oncol* 2015;6(5):469–478