



# Optional Management of Achalasia in 2021: Dilatation or Myotomy

Zaheer Nabi<sup>1</sup>, Mohan Ramchandani<sup>1</sup>, D. Nageshwar Reddy<sup>1</sup>

<sup>1</sup>Asian Institute of Gastroenterology, Hyderabad, Telangana, India

**Address for correspondence** Zaheer Nabi, MD, DNB, Consultant Gastroenterologist, 6-3-661, Asian Institute of Gastroenterology, Hyderabad, Telangana 500082, India (e-mail: zaheernabi1978@gmail.com).

J Digest Endosc 2021;12:93–102.

## Abstract

Achalasia cardia is a primary motility disorder of the esophagus, defined by lack of normal esophageal peristalsis along with inadequate relaxation of lower esophageal sphincter. The mainstay of management in achalasia includes pneumatic dilatation, Heller's myotomy and peroral endoscopic myotomy (POEM). Pneumatic dilatation and Heller's myotomy have gained maturity over several decades. The current best practice with regard to pneumatic dilatation is graded and on-demand dilatation in appropriately selected cases with type I and II achalasia. Laparoscopic Heller's myotomy plus partial fundoplication is minimally invasive with reduced postoperative reflux and has virtually replaced open Heller's myotomy with or without fundoplication. The subtyping of achalasia using high-resolution manometry bears prognostic significance and may help in choosing appropriate therapeutic modality in these patients. Since all the three modalities are effective for type I and II achalasia, the choice among these depends on the availability, expertise, and patient's preferences. On the other hand, POEM is more effective than pneumatic dilatation and Heller's myotomy and, therefore, preferred in type III achalasia. Although POEM is effective across the spectrum of esophageal motility disorders, the incidence of gastroesophageal reflux is high and needs to be considered while choosing among various options in these patients. In cases with failed POEM, redo POEM appears to be effective in alleviating symptoms.

## Keywords

- ▶ esophagus
- ▶ achalasia
- ▶ endoscopy
- ▶ treatment
- ▶ Heller's myotomy
- ▶ per-oral endoscopic myotomy

## Introduction

Achalasia cardia, although rare, is the most common primary motility disorder of the esophagus. It is characterized by the lack of normal esophageal peristalsis and deficient relaxation of lower esophageal sphincter (LES). The rising incidence of achalasia indicates better awareness as well as increased utilization of improved diagnostic modalities, especially high-resolution manometry (HRM), which is more sensitive in detecting esophageal motility disorders.<sup>1,2</sup>

The pathophysiology of achalasia is complex and incompletely understood. Irrespective of the underlying triggering factors, the end result is the progressive, immune-mediated destruction of myenteric plexus neurons.<sup>3</sup> Since none of the currently available treatment modalities halt the degeneration of neurons, it may not be unreasonable to accept that achalasia cardia cannot be cured, although the palliation of symptoms can be achieved in the vast majority of the affected patients. The dominant modalities for the treatment

published online  
April 1, 2021

DOI <https://doi.org/10.1055/s-0041-1731626>  
ISSN 0976-5042

© 2021. Society of Gastrointestinal Endoscopy of India. This is an open access article published by Thieme under the terms of the Creative Commons Attribution-NonDerivative-NonCommercial-License, permitting copying and reproduction so long as the original work is given appropriate credit. Contents may not be used for commercial purposes, or adapted, remixed, transformed or built upon. (<https://creativecommons.org/licenses/by-nc-nd/4.0/>). Thieme Medical and Scientific Publishers Pvt. Ltd. A-12, 2nd Floor, Sector 2, Noida-201301 UP, India

of achalasia include pneumatic dilatation (PD), peroral endoscopic myotomy (POEM), and laparoscopic Heller's myotomy (LHM).

In the following sections, we discuss the role of various modalities for the management of achalasia in the current era.

## Classification of Esophageal Motility Disorders

Esophageal motility disorders are broadly divided into disorders of gastroesophageal junction (GEJ) outflow obstruction and disorders of peristalsis.<sup>4</sup> Disorders of GEJ outflow obstruction include achalasia cardia and esophagogastric junction outflow obstruction (EGJOO), whereas peristaltic disorders without impairment of GEJ outflow are constituted by hypercontractile esophagus and distal esophageal spasm. This subdivision of esophageal motility disorders bears prognostic and therapeutic relevance. Therapeutic modalities like dilatation are mainly directed at GEJ and, therefore, relatively ineffective in spastic esophageal motility disorders, where spasms involving variable length of esophagus are involved in the genesis of symptoms. On the other hand, myotomy (especially endoscopic) can address the spastic segments of esophagus and is preferred in this subgroup. Therefore, the classification of esophageal motility disorders using HRM is crucial before choosing the modality of treatment in these patients.

Endoluminal functional lumen imaging probe (EndoFLIP) is emerging as a useful modality in establishing a diagnosis in cases with equivocal findings on high-resolution esophageal manometry.<sup>5,6</sup> These cases include those with clinical and radiological findings compatible with achalasia but normal-appearing relaxation on manometry (integrated relaxation pressure < 15 mm Hg) and those with a manometric diagnosis of EGJOO.

## Endoscopic Management Options

The endoscopic management of achalasia include botulinum toxin injection, PD, and POEM. Of these, botulinum toxin injection is reserved for elderly and frail patients, unsuitable for other durable treatment modalities like PD or myotomy.<sup>7</sup>

## Pneumatic Dilatation

PD has been the mainstay of endoscopic management for several decades now. With the availability of low-compliance pneumatic balloons and the graded protocol for dilatation, the outcomes of PD have improved substantially (► Fig. 1). Although the technique of PD with regard to the inflation pressure and duration of inflation has not been standardized, it does not seem to influence the results of dilatation.<sup>8</sup> Nevertheless, accurate positioning of the balloon and disappearance of the waist are important during dilatation for optimal outcomes.

More recently, a hydraulic balloon dilation device (EsoFLIP Croston Ltd) has been utilized in cases with idiopathic

achalasia.<sup>9,10</sup> Using this system, dilation is achieved by injecting saline, assisted by electrohydraulic pump. This allows stepwise and controlled dilation. Since the catheter is connected to the EndoFLIP system, the diameter as well as cross-sectional area can be measured during dilatation. Although the results from initial studies appear encouraging, comparative studies are required with pneumatic dilatation before recommending hydraulic dilatation in routine practice.

## Outcomes

The outcomes of PD are largely dependent on the protocol used, that is, single versus graded versus graded and on-demand dilatation (► Fig. 1). There is ample data to suggest that single dilatation does not provide durable response and majority (~ 70%) will require retreatment at 5 to 6 years follow-up.<sup>11</sup> The current best practice is graded dilatation using larger balloons (30 mm, 35 mm, and 40 mm balloons). The most robust evidence regarding the efficacy of graded and on-demand dilatation was provided by the landmark European achalasia trial.<sup>12</sup> In this randomized trial, graded dilatation was performed initially using 30 mm and 35 mm balloons in all the patients, followed by 40 mm in symptomatic patients. Subsequently, on-demand dilatation using 35- and 40-mm balloons was allowed in those with recurrence of symptoms. With this protocol, clinical success was achieved in 90% and 86% at 1 and 2-years follow-up, respectively.<sup>12</sup> Although effective, nearly one-third of patients will experience symptom recurrence after initial series of graded dilatation during follow-up. In these cases, long-term remission can be achieved in approximately 70 to 90% of cases with repeated and on-demand dilatations.<sup>13-16</sup>

## Predictors of Outcomes

The preprocedure predictors for poor response to PD include young age ( $\leq 40$  years), male gender, high-baseline LES pressure ( $> 50$  mm Hg), dilated esophagus ( $> 3$  cm) and type III achalasia.<sup>17,18</sup> Postdilatation predictive factors for relapse after PD include incomplete barium emptying ( $< 50\%$ ) and postdilatation LES pressure  $> 10$  mm Hg or  $< 50\%$  reduction in the LES pressure.<sup>18</sup> Of these, young age ( $< 40$  years) and

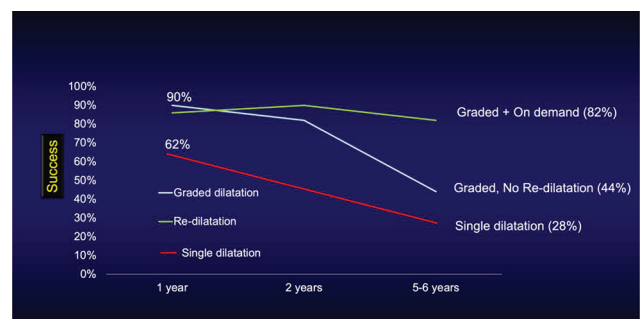


Fig. 1 Outcome of pneumatic dilatation according to the protocol (single vs graded vs graded plus on-demand dilatation).<sup>11,12,14</sup>

type III achalasia have been shown to consistently affect the response to PD.<sup>19,20</sup> Besides these, EndoFLIP is emerging as a novel tool in predicting the immediate outcomes of PD. An increase in EGJ-distensibility index of 1.8 mm<sup>2</sup>/mm Hg after a single PD predicts an immediate response with an accuracy of 87%.<sup>21</sup>

## Adverse Events

Perforation (1–3%) is the most dreaded complication of PD. Conservative management is suffice in a substantial proportion of cases, suggesting that the requirement for surgery is not universal.<sup>22,23</sup> The most important risk factor for perforation is initial dilatation with a 35-mm balloon.<sup>8</sup> In a systematic review (including 10 studies, 643 patients), the rate of perforations was higher when 35-mm balloon was used for initial dilatations (9.3% vs. 0.97%,  $p = 0.0017$ ).<sup>8</sup> In addition, the risk may be higher in elderly cases (> 65 years).<sup>22</sup> Therefore, initial dilatations should be performed using a 30-mm balloon, especially in elderly patients. The guidelines by European Society of Gastroenterology (ESGE) recommend dilatation with a 30-mm, followed by a 35-mm balloon at a planned interval of 2 to 4 weeks, with a subsequent 40-mm dilation when there is insufficient relief.<sup>7</sup>

## Myotomy: Heller's and Endoscopic

### Laparoscopic Heller's Myotomy

Heller's myotomy was introduced by Sir Ernst Heller in 1914. Initially, Heller's myotomy was performed via laparotomy and not accompanied by a fundoplication wrap. Over a century old, the procedure of Heller's myotomy has undergone several modifications. As of now, the procedure is performed laparoscopically and combined with anterior (Dor) or posterior (Toupet) fundoplication. In the current form, Heller's myotomy is not only less invasive but also associated with less postoperative reflux.<sup>24</sup>

### Outcomes

The safety and efficacy of Heller's myotomy has been established in multiple studies. The short- to midterm clinical success with Heller's myotomy ranges from 80 to 90% at a follow-up of  $\leq 5$  years, whereas symptom remission beyond 10 to 15 years is seen in 70 to 80% of patients.<sup>25–27</sup> The notable reasons of failure or symptom relapse after Heller's myotomy include incomplete myotomy, reflux, fibrosis, fundoplication failure, and progression of the disease. Majority of the failures occur within 12 months of surgery, presumably due to incomplete myotomy.<sup>28</sup> The management options in these cases include relaparoscopic myotomy, PD, and POEM with success rates of 64 to 79%, 57 to 89%, and 80 to 95%, respectively.<sup>29</sup> However, complications may be higher in re-Heller's myotomy than in primary surgery of achalasia, with a conversion rate to open surgery of 6%.<sup>29</sup>

### Predictors of Outcomes

The predictors for early dysphagia after Heller's myotomy include preoperative dilatation, fundoplication, and

botulinum toxin injection.<sup>30</sup> Other reported predictors for negative outcomes after surgical myotomy include presence of chest pain, severe preoperative dysphagia, sigmoid esophagus, baseline LES pressure < 30 mm Hg, and type III achalasia.<sup>20,28,31–33</sup> The predictors for good response include manometric type II achalasia, high-baseline LES pressure (> 30 mm Hg), and extended myotomy toward gastric side (3 cm).<sup>28,32,34</sup>

### Adverse Events

The most important intraoperative complication of Heller's myotomy is esophageal or gastric perforation with a cumulative incidence of approximately 7%.<sup>35</sup> Majority of the perforations are recognized and repaired intraoperatively with minimal postoperative consequences. GERD is the most frequent delayed adverse event and occurs in about one-third of patients after LHM without fundoplication.<sup>35</sup> With the addition of partial fundoplication procedure (Dor or Toupet), GERD is noticed in 8 to 10% of patients during short-term follow-up.<sup>24,35</sup> However, there is some evidence that the incidence of GERD increases with increasing follow-up, highlighting the need for regular objective assessment in these patients.<sup>25,26</sup>

### Peroral Endoscopic Myotomy

POEM is the most recent addition to the treatment modalities for achalasia cardia. The seminal works by Sumiyama and Pasricha in animal models are credited for the introduction of POEM and other procedures, listed under the umbrella of third space endoscopy.<sup>36,37</sup>

### Outcomes

Since its introduction nearly a decade ago, multiple studies have established the safety and efficacy of POEM in achalasia. In major studies, the efficacy of POEM is > 90% at 1 to 2 years follow-up.<sup>38–40</sup> Emerging data suggests that the response to POEM may be durable at midterm follow-up. Clinical success at  $\geq 4$  years follow-up has been recorded in 80 to 95% patients.<sup>41–46</sup> POEM has also shown to be effective in cases with symptom relapse after PD and Heller's myotomy.<sup>47</sup> The response rate ranges from 80 to 95% in cases with prior Heller's myotomy at a follow-up ranging from 8.5 to 28 months.<sup>48–50</sup> In a recent systematic review (9 studies, 272 patients), the pooled clinical success after POEM was 90% (95% CI 83.1–96.8%).<sup>51</sup> Considering its excellent safety and efficacy, recent guidelines published by prominent gastrointestinal (GI) societies have included POEM in the management protocol for achalasia.<sup>52–55</sup>

The management in cases with relapse of symptoms after POEM has not been studied well. Limited data suggests that re-POEM may provide the best outcomes in these cases.<sup>56–58</sup> A recent multicenter study evaluated the response to various treatments in 99 patients who experienced recurrence of symptoms after POEM.<sup>58</sup> Clinical success was highest in cases who underwent re-POEM (76%), followed by PD (60%) and Heller's myotomy (29%). In contrast, the response to PD was particularly poor (0–20%) as compared with POEM (63%) and Heller's myotomy (45%) in this setting in another study.<sup>57</sup>

### Predictors of Outcomes

There is paucity of studies evaluating the risk factors for poor response after POEM. The available data suggests that the probability of clinical failure is higher in those with pretreatment Eckardt score  $\geq 9$ , previous treatment, intraprocedural mucosal injury, reflux, and esophageal dilatation ( $\geq$  grade II or  $\geq 3.5$  cm).<sup>59-61</sup> The Eckardt score is a symptom-based score and comprises four distinct symptoms including dysphagia (0-3), regurgitation (0-3), chest pain (0-3) and weight loss (0-3), whereas esophageal dilatation is graded as grade I ( $< 3.5$  cm), grade II ( $\geq 3.5-6$  cm) and grade III ( $> 6$  cm).<sup>60</sup> In two recent studies, risk-scoring systems were devised using these risk factors to predict clinical failure after POEM.<sup>60,61</sup> These scoring systems need to be validated in future studies to confirm their utility in routine clinical practice.

EndoFLIP is a novel tool that uses impedance planimetry to assess the dynamics of GEJ, including diameter, volume and pressure changes.<sup>62</sup> The information provided by EndoFLIP can be used to aid in the diagnosis of achalasia as well as to determine the adequacy of myotomy and predict outcomes after treatment. Intraoperative FLIP during POEM has been shown to correlate with treatment outcomes as well as postoperative reflux. In this regard, intraoperative EGJ-cross-sectional area and distensibility index appear to be useful parameters in assessing the response to POEM.<sup>62-65</sup>

### Adverse Events

Major adverse events are uncommon with POEM and occur in 1 to 3% patients.<sup>66</sup> Insufflation-related events like subcutaneous emphysema and pneumoperitoneum are common but rarely clinically significant. Mucosal injuries and delayed mucosal barrier failure are the most important clinically relevant group of adverse events. Consequently, oral contrast studies are commonly performed before initiating oral feeds

after POEM, although their utility remains questionable in this setting.<sup>67</sup>

Gastroesophageal reflux disease (GERD) is the most common delayed adverse event after POEM. Nearly half of the patients have evidence of GERD on 24-hour pH study, and reflux esophagitis is noticed in 20 to 40% of patients at 3 to 12 months after POEM.<sup>68-70</sup> However, majority of the patients are asymptomatic for GERD, develop mild esophagitis (Los Angeles grade A or B) and respond well to proton-pump inhibitor (PPI) therapy.<sup>70</sup> There are no predictive factors consistently shown to influence the rate of GERD after POEM. Low-integrated relaxation pressure after POEM, female gender, division of oblique fibers during posterior myotomy, excess myotomy along gastric side ( $> 2-2.5$  cm), presence of hiatus hernia, and full thickness myotomy have been shown to be associated with an increased incidence of GERD after POEM in few studies.<sup>69,71-73</sup> It is important to note that the literature is heterogenous with regard to the predisposing factors for GERD after POEM. Therefore, quality studies are required to confirm and validate the conclusions drawn by these studies.

Several modifications in the technique of POEM have been proposed to reduce the incidence of GERD after POEM. These include preservation of oblique fibers during posterior POEM, addition of fundoplication during anterior POEM, and avoiding excess gastric myotomy ( $> 3$  cm).<sup>69,72-74</sup> However, in the absence of quality data, it may be premature to conclude the efficacy of these strategies.

### Pneumatic Dilatation versus Myotomy (POEM and Heller's)

Graded PD, Heller's myotomy and, more recently, POEM constitute the mainstay of management in achalasia cardia. PD and Heller's myotomy have been compared in multiple quality randomized trials (**► Table 1**). Overall, the results suggest

**Table 1** Outcomes of pneumatic dilatation versus myotomy (endoscopic or surgical) in achalasia cardia

Study	Type of study	N	Clinical success	Adverse events	Follow-up (years)	Reflux esophagitis
Boeckxstaens et al <sup>12</sup>	RCT	PD 95 LHM 106	86% 90%	4% 12%	2	19% 21%
Moonen et al <sup>14</sup>	RCT	PD 96 LHM 105	82% 84%	5% 11%	$\geq 5$	14% 18%
Meng et al <sup>76</sup>	R	PD 40 POEM 32	60% 93%	No major AE	3	NR
Zheng et al <sup>78</sup>	R	PD 26 POEM 40	57.5% 92.3%	No major AE	1	NR
Ponds et al <sup>79</sup>	RCT	PD 66 POEM 64	54% 92%	3% 0%	2	7% 41%
Kim et al <sup>77</sup>	R	PD 177 PD 66	68% 91.8%	1.7% 3.1%	2	0.6% 6.3%
Harvey et al <sup>75</sup>	R	PD 4748 HM 2190	86.2% 81.9%	3.8% <sup>a</sup> 2.6% <sup>a</sup>	10	NR

Abbreviations: LHM, laparoscopic Heller's myotomy; NR, not reported; P, prospective; PD, pneumatic dilatation; POEM, per-oral endoscopic myotomy; R, retrospective; RCT, randomized controlled trial.

<sup>a</sup> 30-day emergency readmission

**Table 2** Outcomes of endoscopic versus surgical myotomy in achalasia cardia

Study	Type of study	N	Clinical success	Adverse events	Follow-up	Reflux esophagitis
Bhayani et al <sup>81</sup>	P	HM 64 POEM 37	Dysphagia to solids 29% vs 0%	17.1% 10.8% (mucosal injuries)	6 m	NR
Kumagai <sup>82</sup>	P	HM 41 POEM 42	NR 90%	4.9% 2.4%	12 m	NR
Kumbhari et al <sup>90</sup>	R	LHM 26 POEM 49	80.8% 98%	27% 6%	8.6 m 21.5 m	NR
Chan et al <sup>83</sup>	R	LHM 23 POEM 33	13% <sup>a</sup> (1%) 0% <sup>a</sup>	NR	60 m 6 m	NR
Schneider et al <sup>84</sup>	R	LHM 25 POEM 25	84% 91%	3 <sup>b</sup> 7 <sup>b</sup>	158 weeks 36 weeks	31.6% 53.4%
Hanna et al <sup>86</sup>	R	LHM 54 POEM 42	59% 74%	No major AE in both groups	37 m 22 m	15% 22%
Shea et al <sup>87</sup>	P	HM 97 POEM 44	65% 73.3%	NR	45 m 18.2 m	NR
Wirsching et al <sup>88</sup>	P	LHM 28 POEM 23	13.6% <sup>a</sup> 11.1% <sup>a</sup>	14.2% 8.8%	102 d 83 d	NR
Werner et al <sup>80</sup>	RCT	LHM 109 POEM 112	81.7% 83%	7.3% 2.7%	24 m	29% 44%
Constantini et al <sup>101</sup>	R	LHM POEM	97.7% 99.3%	2.1% 5%	31 m 24 m	15.2% 37.4%
Podboy et al <sup>89</sup>	R	LHM 43 POEM 55	65.1% 72.7%	20.9% 12.7%	5.4 years 3.9 years	4.7% 1.8%

Abbreviations: LHM, laparoscopic Heller's myotomy; NR, not reported; P, prospective; POEM, peroral endoscopic myotomy; R, retrospective; RCT, randomized controlled trial.

<sup>a</sup> Recurrent dysphagia.

<sup>b</sup> Mucosal injuries (actual numbers).

**Table 3** Comparison of the currently available endoscopic modalities for achalasia cardia

	Pneumatic dilatation (multiple sessions)	Peroral endoscopic myotomy	Heller's myotomy
Efficacy: short term	90% (1-year) 54–86% (2 years)	> 90% (1–3 years)	93% (1-year) 90% (2-year)
Efficacy: long-term	78–93% (≥ 4–5years)	80–95% (≥ 4 years)	84% (5 years) 70–80% (≥ 10 years)
Predictors of poor outcomes	Young age (≤ 40 years), type III achalasia, high LES pressure > 50 mm Hg	Prior treatment, mucosal injury, reflux, sigmoid esophagus, dilated esophagus (≥ 3.5 cm), high base-line Eckardt score	Presence of chest pain, severe preoperative dysphagia, sigmoid esophagus, resting LES pressure < 30 mm Hg, type III achalasia
Complications	Perforation (1–3%), bleeding (2%), GERD (9%)	Mucosal injuries (2–4%), delayed bleeding (< 1%)	Perforation (7%)
Indications	Type I and II achalasia preferably > 40 years, relapse after POEM or Heller's myotomy	All subtypes of achalasia especially type III achalasia, relapse of symptoms after PD or Heller's myotomy	All subtypes of achalasia, relapse after PD or POEM
Advantages	Effective in type I and II achalasia, widely available, cost effective	Durable response, effective in all subtypes of achalasia, more effective than PD and HM in type III achalasia	Durable response, effective in all subtypes of achalasia, less postoperative GERD compared with POEM
Disadvantages	Multiple interventions required, relatively ineffective in young (≤ 40 years) and those with type III achalasia	High incidence of GERD, need of expertise	Probably inferior to POEM in type III achalasia, GERD increases with follow-up

Abbreviations: GERD, gastroesophageal reflux disease; HM, Heller's myotomy; LES, lower esophageal sphincter; PD, pneumatic dilatation.



that these two modalities are comparable with respect to short- and long-term outcomes.<sup>12,14</sup> On the other hand, a single series of dilatation may not provide durable response and, therefore, regarded as inferior to Heller's myotomy. The protocol of dilatation utilized in the landmark European achalasia trial, that is, graded and on-demand, has been widely accepted as the standard of care in cases undergoing PD. With this protocol, the clinical success at 2 years (86 vs. 90%) and  $\geq 5$  years (84% vs. 82%) were comparable in PD and Heller's myotomy groups, respectively.<sup>12</sup> The results of this study were further substantiated by a large nationwide cohort study, including 6938 subjects, where PD and Heller's myotomy had similar efficacy over 10-years follow-up (86% vs. 82%).<sup>75</sup>

POEM has been compared with PD in several cohort studies majority of which conclude that POEM is superior to PD (►Table 1).<sup>76-78</sup> However, the important shortcomings of these trials include retrospective design, suboptimal protocol of PD, and difference in the duration of follow-up. More recently, two high quality randomized trials compared POEM to PD and Heller's myotomy.<sup>79,80</sup> In the multicenter

randomized trial by Ponds et al, clinical success with POEM was superior to PD at 2-years follow-up (92% vs. 54%,  $p < 0.001$ ).<sup>79</sup> However, GERD (reflux esophagitis) was more in the POEM group (41% vs. 7%;  $p = 0.002$ ).

Endoscopic and surgical myotomy appear comparable with regard to efficacy at least in short-term follow-up (►Table 2).<sup>80-89</sup> In the randomized study by Werner and colleagues, POEM was noninferior to laparoscopic Heller's myotomy with Dor's fundoplication at 2 years (83% vs. 81.7%). However, the downside of POEM was a higher incidence of reflux esophagitis (44% vs. 29%).<sup>80</sup>

POEM may be superior to Heller's myotomy in cases with type III achalasia and other nonachalasia spastic esophageal motility disorders like hypercontractile esophagus and distal esophageal spasm.<sup>89,90</sup> In a retrospective cohort study, the clinical success after POEM was significantly better than Heller's myotomy in selected cases with type III achalasia.<sup>90</sup> Subsequent studies have also confirmed excellent outcomes with POEM in spastic motility disorders of esophagus.<sup>91-99</sup> The ability to perform long esophageal

**Table 4** Guidelines and recommendations for the endoscopic management of achalasia cardia

	ESGE <sup>53</sup>	ASGE <sup>54</sup>	ACG <sup>55</sup>
Botulinum toxin inj.	<ul style="list-style-type: none"> <li>• Safe and effective</li> <li>• Indicated in patients unfit for more invasive treatments, or in whom a more definite treatment needs to be deferred<sup>d</sup></li> </ul>	<ul style="list-style-type: none"> <li>• Should be avoided as definitive therapy for achalasia patients<sup>a</sup></li> <li>• Should be reserved for patients who are not candidates for other definitive therapies<sup>a</sup></li> </ul>	<ul style="list-style-type: none"> <li>• First-line therapy for patients with achalasia that are unfit for definitive therapies<sup>b</sup></li> <li>• BTX injection does not significantly affect performance and outcomes of myotomy<sup>c</sup></li> </ul>
Pneumatic dilatation	Graded PD is safe and efficacious treatment for achalasia <sup>d</sup>	<ul style="list-style-type: none"> <li>• PD is an effective modality for achalasia<sup>d</sup></li> <li>• PD is preferred over BTX injection for patients with achalasia<sup>d</sup></li> <li>• PD and LHM are comparable for type I and II achalasia<sup>a</sup></li> </ul>	<ul style="list-style-type: none"> <li>• PD is superior to medical therapy in relieving symptoms and physiologic parameters of esophageal emptying<sup>b</sup></li> <li>• PD is superior to medical therapy in relieving symptoms and physiologic parameters of esophageal emptying<sup>b</sup></li> </ul>
Laparoscopic Heller's myotomy	<ul style="list-style-type: none"> <li>• LHM combined with an antireflux procedure is an effective and relatively safe therapy for achalasia<sup>a</sup></li> <li>• LHM, graded repetitive pneumatic dilation, and POEM have comparable efficacy<sup>a</sup></li> <li>• Recurrent or persistent dysphagia after LHM should be managed with PD, POEM or redo surgery<sup>b</sup></li> </ul>	<ul style="list-style-type: none"> <li>• LHM, PD and POEM are effective and comparable therapeutic modalities for patients with type I and II achalasia<sup>a</sup></li> </ul>	<ul style="list-style-type: none"> <li>• Myotomy with fundoplication is superior to myotomy without fundoplication in controlling distal esophageal acid exposure<sup>a</sup></li> <li>• Dor or Toupet fundoplication is recommended to control esophageal acid exposure<sup>a</sup></li> </ul>
Peroral endoscopic myotomy	POEM is a safe and efficacious treatment for achalasia <sup>d</sup>	<ul style="list-style-type: none"> <li>• POEM is an effective modality for achalasia<sup>d</sup></li> <li>• POEM should be preferred in type III achalasia<sup>b</sup></li> <li>• POEM and LHM are comparable for type I and II achalasia<sup>c</sup></li> </ul>	<ul style="list-style-type: none"> <li>• Tailored POEM or LHM preferred over dilatation for type III achalasia<sup>a</sup></li> <li>• POEM would be a better treatment option in those with type III achalasia.</li> <li>• POEM is associated with a higher incidence of GERD as compared with LHM with fundoplication and PD<sup>a</sup></li> <li>• POEM, PD and LHM are comparable in type I and II achalasia<sup>c</sup></li> </ul>

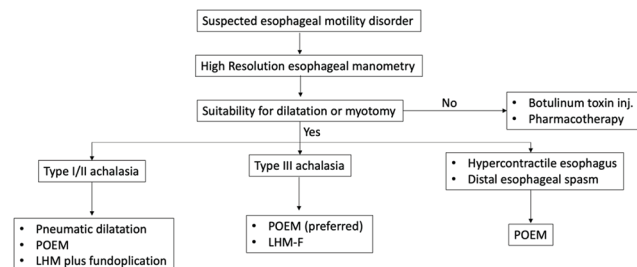
Abbreviations: BTX, botulinum toxin; LHM, laparoscopic Heller's myotomy; PD, pneumatic dilatation; POEM, peroral endoscopic myotomy.

<sup>b</sup> very low evidence.

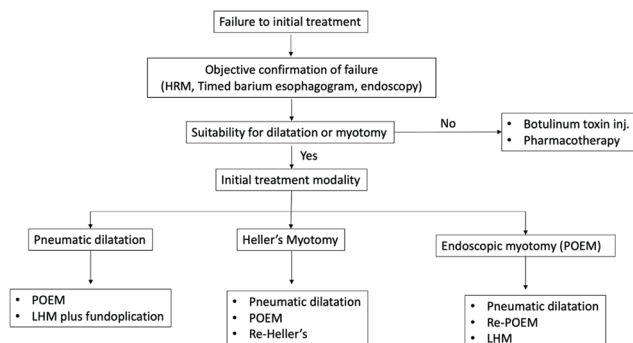
<sup>c</sup> low evidence.

<sup>a</sup> moderate evidence.

<sup>d</sup> high evidence.



**Fig. 2** Approach to esophageal motility disorders in treatment naïve cases.



**Fig. 3** Approach to esophageal motility disorders in prior treatment failed cases.

myotomies explains the superior response with POEM in these cases. A recent meta-analysis described the clinical outcomes after Heller's myotomy and POEM for achalasia based on manometric subtypes.<sup>100</sup> POEM was superior to Heller's myotomy for type I (95% vs. 81%) and III (93% vs. 71%) achalasia. The recent guidelines by the American Society for Gastrointestinal Endoscopy (ASGE) and the American College of Gastroenterology (ACG) recommend POEM for type III achalasia (very low quality evidence).<sup>54,55</sup> Other reported advantages of POEM over Heller's myotomy include shorter procedure time, less postoperative pain, and shorter hospitalization.<sup>81,83,85</sup>

### Individualized Management of Achalasia: Putting it all Together

Currently, there are three effective modalities available for the management of achalasia, including PD, POEM, and Heller's myotomy (►Table 3). The choice among these modalities is based on several factors which include availability and expertise, presence of risk factors of poor response with a particular modality, and patient's preferences (►Fig. 2). The major gastroenterology societies have published the updated guidelines regarding the management of achalasia and allied disorders.<sup>52-55</sup> The salient features of these guidelines have been summarized in ►Table 4.

The pros and cons of each procedure should be detailed to the patients for a shared decision-making. PD is widely available, safe, cost-effective and provides durable response in appropriately selected patients. The patients should be aware regarding the requirement of repeated interventions and a small risk of perforation associated with PD. In cases

with presumed poor response to PD (age < 40 years, type III achalasia, high LES pressure > 50 mm Hg), endoscopic or surgical myotomy is preferable. Endoscopic and surgical myotomy are similarly effective across all age groups and subtypes of achalasia, except in cases with type III achalasia, where POEM may be more effective than Heller's myotomy. The important limitations with endoscopic myotomy are lack of data on long-term efficacy, that is, beyond 10 years and high incidence of postoperative GERD. Therefore, the long-term need for antireflux medications should be explained. In cases with relapse of symptoms after myotomy (POEM or Heller's), PD may be a reasonable first-line treatment with acceptable results, especially after failed Heller's myotomy. Alternatively, remyotomy, especially POEM, may be performed with superior outcomes as compared with re-Heller's myotomy, although the data is limited (►Fig. 3).

### Abbreviations

POEM per-oral endoscopic myotomy

ACG American College of Gastroenterology

ASGE American Society of Gastrointestinal Endoscopy

ESGE European Society of Gastrointestinal Endoscopy

GEJ gastroesophageal junction

GERD gastroesophageal reflux disease

HRM high resolution manometry

LES lower esophageal sphincter

PD pneumatic dilatation

### Funding

The authors (Z.N., M.R., D.N.R) received no funding or support for this manuscript.

### Conflict of Interest

All the authors declare no conflict of interest.

### Acknowledgments

None.

### References

- Roman S, Huot L, Zerbib F, et al. High-resolution manometry improves the diagnosis of esophageal motility disorders in patients with dysphagia: a randomized multicenter study. *Am J Gastroenterol* 2016;111(3):372-380
- Samo S, Carlson DA, Gregory DL, Gawel SH, Pandolfino JE, Kahrilas PJ. Incidence and prevalence of achalasia in Central Chicago, 2004-2014, since the widespread use of high-resolution manometry. *Clin Gastroenterol Hepatol* 2017;15(3):366-373
- Rieder E, Fernandez-Becker NQ, Sarosiek J, Guillaume A, Azagury DE, Clarke JO. Achalasia: physiology and diagnosis. *Ann N Y Acad Sci* 2020;1482(1):85-94
- Yadlapati R, Kahrilas PJ, Fox MR, et al. Esophageal motility disorders on high-resolution manometry: Chicago classification version 4.0©. *Neurogastroenterol Motil* 2021;33(1):e14058
- Carlson DA, Kahrilas PJ, Lin Z, et al. Evaluation of esophageal motility utilizing the functional lumen imaging probe. *Am J Gastroenterol* 2016;111(12):1726-1735
- Ponds FA, Bredenoord AJ, Kessing BF, Smout AJ. Esophagogastric junction distensibility identifies achalasia subgroup with manometrically normal esophagogastric junction relaxation. *Neurogastroenterol Motil* 2017;29(1):29

- 7 Weusten BLAM, Barret M, Bredenoord AJ, et al. Endoscopic management of gastrointestinal motility disorders - part 1: European Society of Gastrointestinal Endoscopy (ESGE) Guideline. *Endoscopy* 2020;52(6):498–515
- 8 van Hoeij FB, Prins LI, Smout AJPM, Bredenoord AJ. Efficacy and safety of pneumatic dilation in achalasia: A systematic review and meta-analysis. *Neurogastroenterol Motil* 2019;31(7):e13548
- 9 Schnurre L, Murray FR, Schindler V, et al. Short-term outcome after singular hydraulic EsoFLIP dilation in patients with achalasia: a feasibility study. *Neurogastroenterol Motil* 2020;32(9):e13864
- 10 Kappelle WF, Bogte A, Siersema PD. Hydraulic dilation with a shape-measuring balloon in idiopathic achalasia: a feasibility study. *Endoscopy* 2015;47(11):1028–1034
- 11 Vela MF, Richter JE, Khandwala F, et al. The long-term efficacy of pneumatic dilatation and Heller myotomy for the treatment of achalasia. *Clin Gastroenterol Hepatol* 2006;4(5):580–587
- 12 Boeckxstaens GE, Annese V, des Varannes SB, et al. European Achalasia Trial Investigators. Pneumatic dilation versus laparoscopic Heller's myotomy for idiopathic achalasia. *N Engl J Med* 2011;364(19):1807–1816
- 13 Hulselmans M, Vanuytsel T, Degreef T, et al. Long-term outcome of pneumatic dilation in the treatment of achalasia. *Clin Gastroenterol Hepatol* 2010;8(1):30–35
- 14 Moonen A, Annese V, Belmans A, et al. Long-term results of the European achalasia trial: a multicentre randomised controlled trial comparing pneumatic dilation versus laparoscopic Heller myotomy. *Gut* 2016;65(5):732–739
- 15 Zerbib F, Th  tiot V, Richey F, Benajah DA, Message L, Lamouliatte H. Repeated pneumatic dilations as long-term maintenance therapy for esophageal achalasia. *Am J Gastroenterol* 2006;101(4):692–697
- 16 Bravi I, Nicita MT, Duca P, et al. A pneumatic dilation strategy in achalasia: prospective outcome and effects on oesophageal motor function in the long term. *Aliment Pharmacol Ther* 2010;31(6):658–665
- 17 M  ller M, Keck C, Eckardt AJ, et al. Outcomes of pneumatic dilation in achalasia: Extended follow-up of more than 25 years with a focus on manometric subtypes. *J Gastroenterol Hepatol* 2018;33(5):1067–1074
- 18 Felix VN. Results of pneumatic dilation in treating achalasia: predictive factors. *Ann N Y Acad Sci* 2018;1434(1):124–131
- 19 Pratap N, Kalapala R, Darisetty S, et al. Achalasia cardia subtyping by high-resolution manometry predicts the therapeutic outcome of pneumatic balloon dilatation. *J Neurogastroenterol Motil* 2011;17(1):48–53
- 20 Pandolfino JE, Kwiatek MA, Nealis T, Bulsiewicz W, Post J, Kahrilas PJ. Achalasia: a new clinically relevant classification by high-resolution manometry. *Gastroenterology* 2008;135(5):1526–1533
- 21 Wu PI, Szczesniak MM, Craig PI, et al. Novel intra-procedural distensibility measurement accurately predicts immediate outcome of pneumatic dilatation for idiopathic achalasia. *Am J Gastroenterol* 2018;113(2):205–212
- 22 Vanuytsel T, Lerut T, Coosemans W, et al. Conservative management of esophageal perforations during pneumatic dilation for idiopathic esophageal achalasia. *Clin Gastroenterol Hepatol* 2012;10(2):142–149
- 23 Ghoshal UC, Karyampudi A, Verma A, et al. Perforation following pneumatic dilation of achalasia cardia in a university hospital in northern India: A two-decade experience. *Indian J Gastroenterol* 2018;37(4):347–352
- 24 Richards WO, Torquati A, Holzman MD, et al. Heller myotomy versus Heller myotomy with Dor fundoplication for achalasia: a prospective randomized double-blind clinical trial. *Ann Surg* 2004;240(3):405–412, discussion 412–415
- 25 Csendes A, Braghetto I, Burdiles P, Korn O, Csendes P, Henr  quez A. Very late results of esophagomyotomy for patients with achalasia: clinical, endoscopic, histologic, manometric, and acid reflux studies in 67 patients for a mean follow-up of 190 months. *Ann Surg* 2006;243(2):196–203
- 26 Ortiz A, de Haro LF, Parrilla P, et al. Very long-term objective evaluation of heller myotomy plus posterior partial fundoplication in patients with achalasia of the cardia. *Ann Surg* 2008;247(2):258–264
- 27 Csendes A, Orellana O, Figueroa M, Lanzarini E, Panza B. Long-term (17 years) subjective and objective evaluation of the durability of laparoscopic Heller esophagomyotomy in patients with achalasia of the esophagus (90% of follow-up): a real challenge to POEM. *Surg Endosc* 2021;(e-pub ahead of print). doi:10.1007/s00464-020-08273-1
- 28 Zaninotto G, Costantini M, Rizzetto C, et al. Four hundred laparoscopic myotomies for esophageal achalasia: a single centre experience. *Ann Surg* 2008;248(6):986–993
- 29 Fernandez-Ananin S, Fern  ndez AF, Balagu   C, Sacoto D, Targarona EM. What to do when Heller's myotomy fails? Pneumatic dilatation, laparoscopic remyotomy or peroral endoscopic myotomy: A systematic review. *J Minim Access Surg* 2018;14(3):177–184
- 30 Finley CJ, Kondra J, Clifton J, Yee J, Finley R. Factors associated with postoperative symptoms after laparoscopic Heller myotomy. *Ann Thorac Surg* 2010;89(2):392–396
- 31 Salvador R, Costantini M, Zaninotto G, et al. The preoperative manometric pattern predicts the outcome of surgical treatment for esophageal achalasia. *J Gastrointest Surg* 2010;14(11):1635–1645
- 32 Torquati A, Richards WO, Holzman MD, Sharp KW. Laparoscopic myotomy for achalasia: predictors of successful outcome after 200 cases. *Ann Surg* 2006;243(5):587–591, discussion 591–593
- 33 Khajanchee YS, Kanneganti S, Leatherwood AE, Hansen PD, Swanstr  m LL. Laparoscopic Heller myotomy with Toupet fundoplication: outcomes predictors in 121 consecutive patients. *Arch Surg* 2005;140(9):827–833, discussion 833–834
- 34 Oelschlager BK, Chang L, Pellegrini CA. Improved outcome after extended gastric myotomy for achalasia. *Arch Surg* 2003;138(5):490–495, discussion 495–497
- 35 Campos GM, Vittinghoff E, Rabl C, et al. Endoscopic and surgical treatments for achalasia: a systematic review and meta-analysis. *Ann Surg* 2009;249(1):45–57
- 36 Sumiyama K, Gostout CJ, Rajan E, Bakken TA, Knipschild MA, Marler RJ. Submucosal endoscopy with mucosal flap safety valve. *Gastrointest Endosc* 2007;65(4):688–694
- 37 Pasricha PJ, Hawari R, Ahmed I, et al. Submucosal endoscopic esophageal myotomy: a novel experimental approach for the treatment of achalasia. *Endoscopy* 2007;39(9):761–764
- 38 Ramchandani M, Nageshwar Reddy D, Darisetty S, et al. Peroral endoscopic myotomy for achalasia cardia: treatment analysis and follow up of over 200 consecutive patients at a single center. *Dig Endosc* 2016;28(1):19–26
- 39 Shiwaku H, Inoue H, Onimaru M, et al. Multicenter collaborative retrospective evaluation of peroral endoscopic myotomy for esophageal achalasia: analysis of data from more than 1300 patients at eight facilities in Japan. *Surg Endosc* 2020;34(1):464–468
- 40 Shiwaku H, Inoue H, Sato H, et al. Peroral endoscopic myotomy for achalasia: a prospective multicenter study in Japan. *Gastrointest Endosc* 2020;91(5):1037–1044.e2, e2
- 41 Guo H, Yang H, Zhang X, et al. Long-term outcomes of peroral endoscopic myotomy for patients with achalasia: a retrospective single-center study. *Dis Esophagus* 2017;30(5):1–6
- 42 Li QL, Wu QN, Zhang XC, et al. Outcomes of per-oral endoscopic myotomy for treatment of esophageal achalasia with a median



- follow-up of 49 months. *Gastrointest Endosc* 2018;87(6):1405–1412.e3, e3
- 43 Teitelbaum EN, Dunst CM, Reavis KM, et al. Clinical outcomes five years after POEM for treatment of primary esophageal motility disorders. *Surg Endosc* 2018;32(1):421–427
  - 44 He C, Li M, Lu B, et al. Long-term efficacy of peroral endoscopic myotomy for patients with achalasia: outcomes with a median follow-up of 36 months. *Dig Dis Sci* 2019;64(3):803–810
  - 45 Brewer Gutierrez OI, Moran RA, Familiari P, et al. Long-term outcomes of per-oral endoscopic myotomy in achalasia patients with a minimum follow-up of 4 years: a multicenter study. *Endosc Int Open* 2020;8(5):E650–E655
  - 46 McKay SC, Dunst CM, Sharata AM, et al. POEM: clinical outcomes beyond 5 years. *Surg Endosc* 2021;(e-pub ahead of print). doi:10.1007/s00464-020-08031-3
  - 47 Nabi Z, Ramchandani M, Chavan R, et al. Peroral endoscopic myotomy in treatment-naïve achalasia patients versus prior treatment failure cases. *Endoscopy* 2018;50(4):358–370
  - 48 Ngamruengphong S, Inoue H, Ujiki MB, et al. Efficacy and safety of peroral endoscopic myotomy for treatment of achalasia after failed Heller myotomy. *Clin Gastroenterol Hepatol* 2017;15(10):1531–1537.e3, e3
  - 49 Tyberg A, Sharaiha RZ, Familiari P, et al. Peroral endoscopic myotomy as salvation technique post-Heller: International experience. *Dig Endosc* 2018;30(1):52–56
  - 50 Zhang X, Modayil RJ, Friedel D, et al. Per-oral endoscopic myotomy in patients with or without prior Heller's myotomy: comparing long-term outcomes in a large U.S. single-center cohort (with videos) *Gastrointest Endosc* 2018;87(4):972–985
  - 51 Huang Z, Cui Y, Li Y, Chen M, Xing X. Peroral endoscopic myotomy for patients with achalasia with previous Heller myotomy: a systematic review and meta-analysis. *Gastrointest Endosc* 2021;93(1):47–56.e5, e5
  - 52 Jung HK, Hong SJ, Lee OY, et al. Korean Society of Neurogastroenterology and Motility. 2019 Seoul Consensus on Esophageal Achalasia Guidelines. *J Neurogastroenterol Motil* 2020;26(2):180–203
  - 53 Oude Nijhuis RAB, Zaninotto G, Roman S, et al. European guidelines on achalasia: United European Gastroenterology and European Society of Neurogastroenterology and Motility recommendations. *United European Gastroenterol J* 2020;8(1):13–33
  - 54 Khashab MA, Vela MF, Thosani N, et al. ASGE guideline on the management of achalasia. *Gastrointest Endosc* 2020;91(2):213–227.e6, e6
  - 55 Vaezi MF, Pandolfino JE, Yadlapati RH, Greer KB, Kavitt RT. ACG Clinical Guidelines: Diagnosis and Management of Achalasia. *Am J Gastroenterol* 2020;115(9):1393–1411
  - 56 Tyberg A, Seewald S, Sharaiha RZ, et al. A multicenter international registry of redo per-oral endoscopic myotomy (POEM) after failed POEM. *Gastrointest Endosc* 2017;85(6):1208–1211
  - 57 van Hoeij FB, Ponds FA, Werner Y, et al. Management of recurrent symptoms after per-oral endoscopic myotomy in achalasia. *Gastrointest Endosc* 2018;87(1):95–101
  - 58 Ichkhanian Y, Assis D, Familiari P, et al. Management of patients after failed peroral endoscopic myotomy: a multicenter study. *Endoscopy* 2020;(e-pub ahead of print). doi: /a-1312-049
  - 59 Ren Y, Tang X, Chen Y, et al. Pre-treatment Eckardt score is a simple factor for predicting one-year peroral endoscopic myotomy failure in patients with achalasia. *Surg Endosc* 2017;31(8):3234–3241
  - 60 Urakami S, Abe H, Tanaka S, et al. Development of a preoperative risk-scoring system for predicting poor responders to peroral endoscopic myotomy. *Gastrointest Endosc* 2021;93(2):398–405
  - 61 Liu XY, Cheng J, Chen WF, et al. A risk-scoring system to predict clinical failure for patients with achalasia after peroral endoscopic myotomy. *Gastrointest Endosc* 2020;91(1):33–40.e1, e1
  - 62 Hirano I, Pandolfino JE, Boeckxstaens GE. Functional Lumen Imaging Probe for the Management of Esophageal Disorders: Expert Review From the Clinical Practice Updates Committee of the AGA Institute. *Clin Gastroenterol Hepatol* 2017;15(3):325–334
  - 63 Donnan EN, Pandolfino JE. Applying the functional luminal imaging probe to esophageal disorders. *Curr Gastroenterol Rep* 2020;22(3):10
  - 64 Su B, Callahan ZM, Novak S, Kuchta K, Ujiki MB. Using impedance planimetry (EndoFLIP) to evaluate myotomy and predict outcomes after surgery for achalasia. *J Gastrointest Surg* 2020;24(4):964–971
  - 65 Attaar M, Su B, Wong HJ, et al. Intraoperative impedance planimetry (EndoFLIP) results and development of esophagitis in patients undergoing peroral endoscopic myotomy (POEM) *Surg Endosc* 2020;(e-pub ahead of print). doi:10.1007/s00464-020-07876-y
  - 66 Nabi Z, Reddy DN, Ramchandani M. Adverse events during and after per-oral endoscopic myotomy: prevention, diagnosis, and management. *Gastrointest Endosc* 2018;87(1):4–17
  - 67 Reddy CA, Tavakkoli A, Abdul-Hussein M, et al. The clinical impact of routine esophagram after peroral endoscopic myotomy. *Gastrointest Endosc* 2020;93(1):102–106
  - 68 Kumbhari V, Familiari P, Bjerregaard NC, et al. Gastroesophageal reflux after peroral endoscopic myotomy: a multicenter case-control study. *Endoscopy* 2017;49(7):634–642
  - 69 Nabi Z, Ramchandani M, Reddy DN. Per-oral endoscopic myotomy and gastroesophageal reflux: Where do we stand after a decade of "POETRY"? *Indian J Gastroenterol* 2019;38(4):287–294
  - 70 Nabi Z, Ramchandani M, Kotla R, et al. Gastroesophageal reflux disease after peroral endoscopic myotomy is unpredictable, but responsive to proton pump inhibitor therapy: a large, single-center study. *Endoscopy* 2020;52(8):643–651
  - 71 Ramirez M, Zubieta C, Ciotola F, et al. Per oral endoscopic myotomy vs. laparoscopic Heller myotomy, does gastric extension length matter? *Surg Endosc* 2018;32(1):282–288
  - 72 Grimes KL, Bechara R, Shimamura Y, et al. Gastric myotomy length affects severity but not rate of post-procedure reflux: 3-year follow-up of a prospective randomized controlled trial of double-scope per-oral endoscopic myotomy (POEM) for esophageal achalasia. *Surg Endosc* 2020;34(7):2963–2968
  - 73 Tanaka S, Toyonaga T, Kawara F, et al. Novel per-oral endoscopic myotomy method preserving oblique muscle using two penetrating vessels as anatomic landmarks reduces postoperative gastroesophageal reflux. *J Gastroenterol Hepatol* 2019;34(12):2158–2163
  - 74 Inoue H, Shiwaku H, Kobayashi Y, et al. Statement for gastroesophageal reflux disease after peroral endoscopic myotomy from an international multicenter experience. *Esophagus* 2020;17(1):3–10
  - 75 Harvey PR, Coupland B, Mytton J, Evison F, Patel P, Trudgill NJ. Outcomes of pneumatic dilatation and Heller's myotomy for achalasia in England between 2005 and 2016. *Gut* 2019;68(7):1146–1151
  - 76 Meng F, Li P, Wang Y, et al. Peroral endoscopic myotomy compared with pneumatic dilation for newly diagnosed achalasia. *Surg Endosc* 2017;31(11):4665–4672
  - 77 Kim GH, Jung KW, Jung HY, et al. Superior clinical outcomes of peroral endoscopic myotomy compared with balloon dilation in all achalasia subtypes. *J Gastroenterol Hepatol* 2019;34(4):659–665
  - 78 Zheng Z, Zhao C, Su S, et al. Peroral endoscopic myotomy versus pneumatic dilation - result from a retrospective study with 1-year follow-up. *Z Gastroenterol* 2019;57(3):304–311
  - 79 Ponds FA, Fockens P, Lei A, et al. Effect of peroral endoscopic myotomy vs pneumatic dilation on symptom severity and treatment outcomes among treatment-naïve

- patients with achalasia: a randomized clinical trial. *JAMA* 2019;322(2):134–144
- 80 Werner YB, Hakanson B, Martinek J, et al. Endoscopic or surgical myotomy in patients with idiopathic achalasia. *N Engl J Med* 2019;381(23):2219–2229
  - 81 Bhayani NH, Kurian AA, Dunst CM, Sharata AM, Rieder E, Swanstrom LL. A comparative study on comprehensive, objective outcomes of laparoscopic Heller myotomy with per-oral endoscopic myotomy (POEM) for achalasia. *Ann Surg* 2014;259(6):1098–1103
  - 82 Kumagai K, Tsai JA, Thorell A, Lundell L, Håkanson B. Per-oral endoscopic myotomy for achalasia. Are results comparable to laparoscopic Heller myotomy? *Scand J Gastroenterol* 2015;50(5):505–512
  - 83 Chan SM, Wu JC, Teoh AY, et al. Comparison of early outcomes and quality of life after laparoscopic Heller's cardiomyotomy to peroral endoscopic myotomy for treatment of achalasia. *Dig Endosc* 2016;28(1):27–32
  - 84 Schneider AM, Louie BE, Warren HF, Farivar AS, Schembre DB, Aye RW. A Matched comparison of per oral endoscopic myotomy to laparoscopic Heller myotomy in the treatment of achalasia. *J Gastrointest Surg* 2016;20(11):1789–1796
  - 85 Docimo S, Jr, Mathew A, Shope AJ, Winder JS, Haluck RS, Pauli EM. Reduced postoperative pain scores and narcotic use favor per-oral endoscopic myotomy over laparoscopic Heller myotomy. *Surg Endosc* 2017;31(2):795–800
  - 86 Hanna AN, Datta J, Ginzberg S, Dasher K, Ginsberg GG, Dempsey DT. Laparoscopic Heller myotomy vs per oral endoscopic myotomy: patient-reported outcomes at a single institution. *J Am Coll Surg* 2018;226(4):465–472.e1, e1
  - 87 Shea GE, Johnson MK, Venkatesh M, et al. Long-term dysphagia resolution following POEM versus Heller myotomy for achalasia patients. *Surg Endosc* 2020;34(4):1704–1711
  - 88 Wirsching A, Boshier PR, Klevebro F, et al. Comparison of costs and short-term clinical outcomes of per-oral endoscopic myotomy and laparoscopic Heller myotomy. *Am J Surg* 2019;218(4):706–711
  - 89 Podboy AJ, Hwang JH, Rivas H, et al. Long-term outcomes of per-oral endoscopic myotomy compared to laparoscopic Heller myotomy for achalasia: a single-center experience. *Surg Endosc* 2021;35(2):792–801
  - 90 Kumbhari V, Tieu AH, Onimaru M, et al. Peroral endoscopic myotomy (POEM) vs laparoscopic Heller myotomy (LHM) for the treatment of Type III achalasia in 75 patients: a multicenter comparative study. *Endosc Int Open* 2015;3(3):E195–E201
  - 91 Khan MA, Kumbhari V, Ngamruengphong S, et al. Is POEM the answer for management of spastic esophageal disorders? A systematic review and meta-analysis. *Dig Dis Sci* 2017;62(1):35–44
  - 92 Zhang W, Linghu EQ. Peroral endoscopic myotomy for type III achalasia of Chicago Classification: outcomes with a minimum follow-up of 24 months. *J Gastrointest Surg* 2017;21(5):785–791
  - 93 Albers D, Frieling T, Dakkak D, et al. Peroral endoscopic myotomy (POEM) is effective in treatment of noncardiac chest pain caused by hypercontractile esophageal motility disorders: results of the POEM-HYPE-Study. *Z Gastroenterol* 2018;56(11):1337–1342
  - 94 Khashab MA, Familiari P, Draganov PV, et al. Peroral endoscopic myotomy is effective and safe in non-achalasia esophageal motility disorders: an international multicenter study. *Endosc Int Open* 2018;6(8):E1031–E1036
  - 95 Chandan S, Mohan BP, Chandan OC, et al. Clinical efficacy of per-oral endoscopic myotomy (POEM) for spastic esophageal disorders: a systematic review and meta-analysis. *Surg Endosc* 2019;34(2):707–718
  - 96 Filicori F, Dunst CM, Sharata A, et al. Long-term outcomes following POEM for non-achalasia motility disorders of the esophagus. *Surg Endosc* 2019;33(5):1632–1639
  - 97 Kane ED, Budhreja V, Desilets DJ, Romanelli JR. Myotomy length informed by high-resolution esophageal manometry (HREM) results in improved per-oral endoscopic myotomy (POEM) outcomes for type III achalasia. *Surg Endosc* 2019;33(3):886–894
  - 98 Bernardot L, Roman S, Barret M, et al. Efficacy of per-oral endoscopic myotomy for the treatment of non-achalasia esophageal motor disorders. *Surg Endosc* 2020;34(12):5508–5515
  - 99 Nabi Z, Chavan R, Ramchandani M, et al. Long-term outcomes of per-oral endoscopic myotomy in spastic esophageal motility disorders: a large, single-center study. *J Clin Gastroenterol* 2020
  - 100 Andolfi C, Fisichella PM. Meta-analysis of clinical outcome after treatment for achalasia based on manometric subtypes. *Br J Surg* 2019;106(4):332–341
  - 101 Costantini A, Familiari P, Costantini M, et al. Poem versus laparoscopic Heller myotomy in the treatment of esophageal achalasia: a case-control study from two high volume centers using the propensity score. *J Gastrointest Surg* 2020;24(3):505–515