



Bilobed Flap in Hand Clinodactyly Reconstruction: Technique Description and Result Appraisal

Retalho bilobado na reconstrução das clinodactilias da mão: Descrição da técnica e avaliação do resultado

Ricardo Kaempf¹ João Pedro Farina Brunelli² Márcio Aurelio Aita³ Pedro J. Delgado⁴
Francisco Soldado⁵ Enrique Vergara⁶

¹ Department of Hand Surgery, Hospital Santa Casa de Misericórdia, Porto Alegre, RS, Brazil

² Department of Hand Surgery at Santa Casa de Misericórdia, São Paulo, SP, Brazil

³ Department of Hand Surgery, Faculdade de Medicina do ABC, Santo André, SP, Brazil

⁴ Department of Hand Surgery, Hospital Universitario Madrid Montepíncipe, Universidad San Pablo CEU, Boadilla del Monte, Madrid, Spain

⁵ Department of Hand Surgery, Universitat de Barcelona, Barcelona, Spain

⁶ Department of Orthopedics and Traumatology, Universidad Nacional de Colombia, Bogotá, Colombia

Address for correspondence Ricardo Kaempf, MD, Department of Hand Surgery, Santa Casa de Misericórdia Hospital, Rua Leopoldo Bier, 825 / 301, 90620-100, Porto Alegre, RS, Brazil (e-mail: ricardokaempf@gmail.com).

Rev Bras Ortop 2022;57(4):642–648.

Abstract

Keywords

- ▶ clinodactyly
- ▶ fingers/abnormalities
- ▶ surgical flaps
- ▶ osteotomy

Objective Clinodactyly is a congenital hand deformity that is characterized by coronal angular deviation and may occur in thumbs or fingers. Surgical treatment is indicated for severe angulations. Among the described techniques, one of the options consists of bone alignment by wedge-shaped addition osteotomy of the anomalous phalanx. Such alignment maneuver creates a problem in skin cover, along with soft-tissue tension at the concave aspect of the deformity. Hence, some sort of skin flap is required for the adequate operative wound closure. We aim to demonstrate the aforementioned technique and to assess the results of bilobed flap in the treatment of hand clinodactyly.

Methods Retrospective study conducted between January 2008 and January 2015. Five patients were included in the study, including nine operated digits. Surgical indication consisted of angular deviations $> 30^\circ$. Neither patients with thumb deformities nor those with deformities associated to syndromes were excluded from the study. We assessed the functional and cosmetic outcomes of the technique, as well as complications and the satisfaction rates of the family.

Work developed at the Hospital Santa Casa de Porto Alegre, Porto Alegre, RS, Brazil.

received
November 30, 2020
accepted
February 11, 2021
published online
October 1, 2021

DOI <https://doi.org/10.1055/s-0041-1731797>.
ISSN 0102-3616.

© 2021. Sociedade Brasileira de Ortopedia e Traumatologia. All rights reserved.

This is an open access article published by Thieme under the terms of the Creative Commons Attribution-NonDerivative-NonCommercial-License, permitting copying and reproduction so long as the original work is given appropriate credit. Contents may not be used for commercial purposes, or adapted, remixed, transformed or built upon. (<https://creativecommons.org/licenses/by-nc-nd/4.0/>)

Thieme Revinter Publicações Ltda., Rua do Matoso 170, Rio de Janeiro, RJ, CEP 20270-135, Brazil

Results All patients had satisfactory functional and cosmetic results, with a mean skin healing of 18.6 days. Among nine operated digits, only one of the patients presented vascular compromise at the distal portion of the first flap lobe, albeit without necrosis or the need for any additional procedure. Patients were followed up on a minimum of 12-month interval. No deformity recurred during the observation period.

Conclusion Bilobed flap for the treatment of hand clinodactyly is a good option for skin cover after the osteotomy.

Resumo

Objetivo A clinodactilia é uma deformidade congênita da mão, caracterizada por desvio angular coronal, podendo ocorrer em polegares ou dedos. O tratamento cirúrgico é indicado para angulações severas. Dentre as técnicas descritas, uma das opções consiste no alinhamento ósseo, através de osteotomia em cunha de adição da falange anômala. Essa manobra de alinhamento gera uma dificuldade de cobertura cutânea, juntamente com a tensão das partes moles no lado côncavo da deformidade. Sendo assim, algum tipo de retalho cutâneo é necessário para o fechamento adequado da ferida cirúrgica. Objetivamos demonstrar a técnica citada e avaliar os resultados do retalho bilobado no tratamento das clinodactilias da mão.

Métodos Estudo retrospectivo entre janeiro de 2008 e janeiro de 2015. Foram incluídos cinco pacientes no estudo, nove dedos foram submetidos à cirurgia. Tiveram indicação cirúrgica os pacientes com desvios angulares nos dedos acima de 30 graus. Não foram excluídos do estudo os pacientes com deformidades no polegar, nem aqueles com deformidades associadas a síndromes. Foram avaliados os resultados funcionais e estéticos com o uso desta técnica, assim como as complicações e o grau de satisfação dos familiares.

Resultados Todos os pacientes apresentaram resultados funcionais e estéticos satisfatórios, com cicatrização cutânea média de 18,6 dias. Entre os nove dedos submetidos à cirurgia, apenas um dos pacientes apresentou comprometimento vascular na porção distal do primeiro lobo do retalho, porém sem necrose ou necessidade de qualquer procedimento adicional. Os pacientes foram acompanhados durante um intervalo mínimo de 12 meses. Nenhuma deformidade ocorreu durante o período de observação.

Conclusão O uso do retalho bilobado no tratamento das clinodactilias da mão é uma boa opção para cobertura cutânea após a realização de osteotomia.

Palavras-chave

- ▶ clinodactilia
- ▶ dedos/anormalidades
- ▶ retalhos cirúrgicos
- ▶ osteotomia

Introduction

Clinodactyly is a congenital hand deformity that is characterized by coronal angular deviation and may occur in thumbs or fingers; little finger deformity is frequent and often mild, as an isolated deformity. Angulations in excess of 20° create functional changes with digit overlapping during flexion.¹⁻⁴ The thumb deformities are more often severe and can be associated with syndromes, such as Rubstein-Taybi, Pfeiffer, Apert, and Patau, among others.¹⁻⁴ In most cases, there is a radial deviation; such deformities are also called “hitchhiker’s thumb.”⁵

Severe angulations commonly show the replacement of a normal phalanx for another with an abnormal format, which can be triangular or trapezoid-shaped. Surgical treatment is indicated for those patients; one of the options consists of bone alignment by means of an addition wedge osteotomy of the abnormal phalanx and K-wire fixation.⁶ Such alignment maneuver creates a problem in skin cover

and soft-tissue tension at the concave aspect of the deformity. Thus, some sort of skin flap is needed for adequate closure of the operative wound.⁷

The use of a bilobed flap, as described by Esser,⁸ and further modifications⁹ allow skin redistribution, taking the redundant skin of the convex aspect to the concave aspect of the deformity. Such technique allows digit alignment without the need of either skin grafting or distant flaps.

The present study aims to detail the technique for the bilobed flap in the surgical treatment of clinodactyly, as described by Cerqueiro-Mosquera and Fleming⁵ in 2000, and to assess the results of a series comprising 9 digits and 5 patients.

Material and Methods

The project was submitted to the institution’s Research Ethics Committee, with the number CAAE 87964217.4.0000.5335.

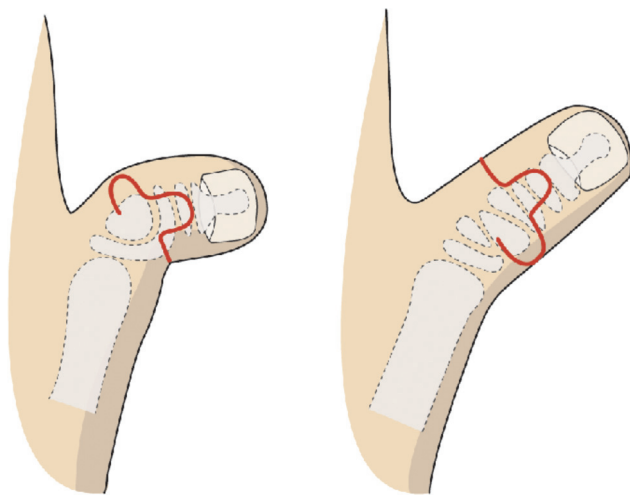


Fig. 1 Schematic of surgical treatment for clinodactyly using bilobed flap. It starts with a transverse line at the digit concave border, which is the point of maximum deformity. The dorsal lobe shall be the size of the space created at the concave border with the digit aligned. The secondary lobe should be performed toward the palm on the convex side of deformity and must have a similar height to that of the first lobe, although not as wide.

We retrospectively assessed all patients surgically treated at our service for clinodactyly with bilobed flap between January 2008 and January 2015. Five patients, comprising nine digits operated, were included in this study.

The surgical technique was indicated only for digit angular deviations $> 30^\circ$. Patients with thumb deformities, as well as those with deformities associated with syndromes, were not excluded from the study. Orthopedic abnormalities associated with other digits, such as syndactyly, were not excluded either.

The procedure was performed under general anesthesia, with the application of an upper limb pneumatic tourniquet. Regarding the surgical technique employed, it started with the incision design, which should be routinely performed to attain a safer primary closure. The incision creation starts with a transverse line at the point of maximum deformity at the digit concave aspect and aligned with the interphalangeal extension crease. Such incision starts at the junction between the dorsal skin and the glabrous skin (hairless) going toward the flap's dorsal lobe. The width of the dorsal lobe should fill the size of the space that will be created at the concave aspect upon digit alignment. The dorsal lobe extends distally from the interphalangeal extension crease to two-thirds of the nail crease distance. The secondary lobe must be performed toward the palm, at the convex side of the deformity, and shall have a height similar to that of the same lobe, although not as wide (► Fig. 1).

Care must be taken during dorsal dissection to keep the tenosynovial tissue of the extensor apparatus intact, along with main dorsal veins. Flap lobes include skin and subcutaneous tissue, and care must be exercised at the convex aspect of the secondary lobe to keep the neurovascular bundle untouched in its position.

The incision that is created for the bilobed flap is wide enough so that the anomalous delta or trapezoidal phalanx is visualized through both sides of the extensor tendon, thus facilitating the osteotomy. The osteotomy is transversely performed at the phalanx, so that the deformity correction creates an opening wedge at the deformity concave aspect. After the osteotomy, the phalanx is fixated with one or two K-wires. Bone grafting was not employed in our series.

Flap lobes are rotated in 90° for closure, so that the dorsal lobe closes the defect on the concave aspect, and the secondary convex lobe covers the dorsal defect. The convex aspect is primarily closed, with no tension or need for skin grafting. Before flaps closure, the pneumatic tourniquet is deflated for hemostasis. The patient is initially immobilized with a long-arm plaster that includes the operated digit, which, after the first week, is replaced by an aluminum finger splint. K-wires are removed after 8 weeks. Home mobilization exercises are prescribed after and are usually enough for mobility recovery. Cosmetic and functional outcomes with this technique are excellent, and do not give rise to complications.

Results

Among the five patients included in our series, one had Apert syndrome; one had Pfeiffer syndrome (► Fig. 2); two had Rubinstein-Taybi syndrome—they were homozygous twins; and one had an isolated clinodactyly (► Figs. 3 and 4). All patients were male and had a mean age of 4 years and 1 month (ranging from 2 years and 5 months to 7 years and 4 months) at the time of the operation. Overall, nine digits were operated, including eight thumbs and one index finger. All patients displayed radial deviation, and the mean angle was 67.2° (ranging from 60° – 80°). Patients were clinically followed at a mean of 18.6 months (range: 12–24 months). Being a pediatric patient sample, no dominance was determined at the time of the surgery (► Table 1).

There were no severe perioperative or early postoperative complications as regard to the technique. The procedure conveyed the primary closure of all operated digits. All nine digits had the flap healed at 18.6 days (ranging from 14–28 days). All flaps endured, and only one patient showed a distal compromise of part of the first lobe. In this case, a crust formed, followed by second-intention healing.

Three patients with bilateral deformity had both hands operated on the same day. Only one patient with bilateral thumb deformity was operated in two steps due to third- and fourth-digit syndactyly, which was conjointly approached with the thumb clinodactyly. No patient required a second procedure. All patients presented good or excellent cosmesis, and no deformity relapses were seen at a minimum of 12-months follow-up. Upon subjective assessment, all patients and families reported to be satisfied with the surgical outcome.

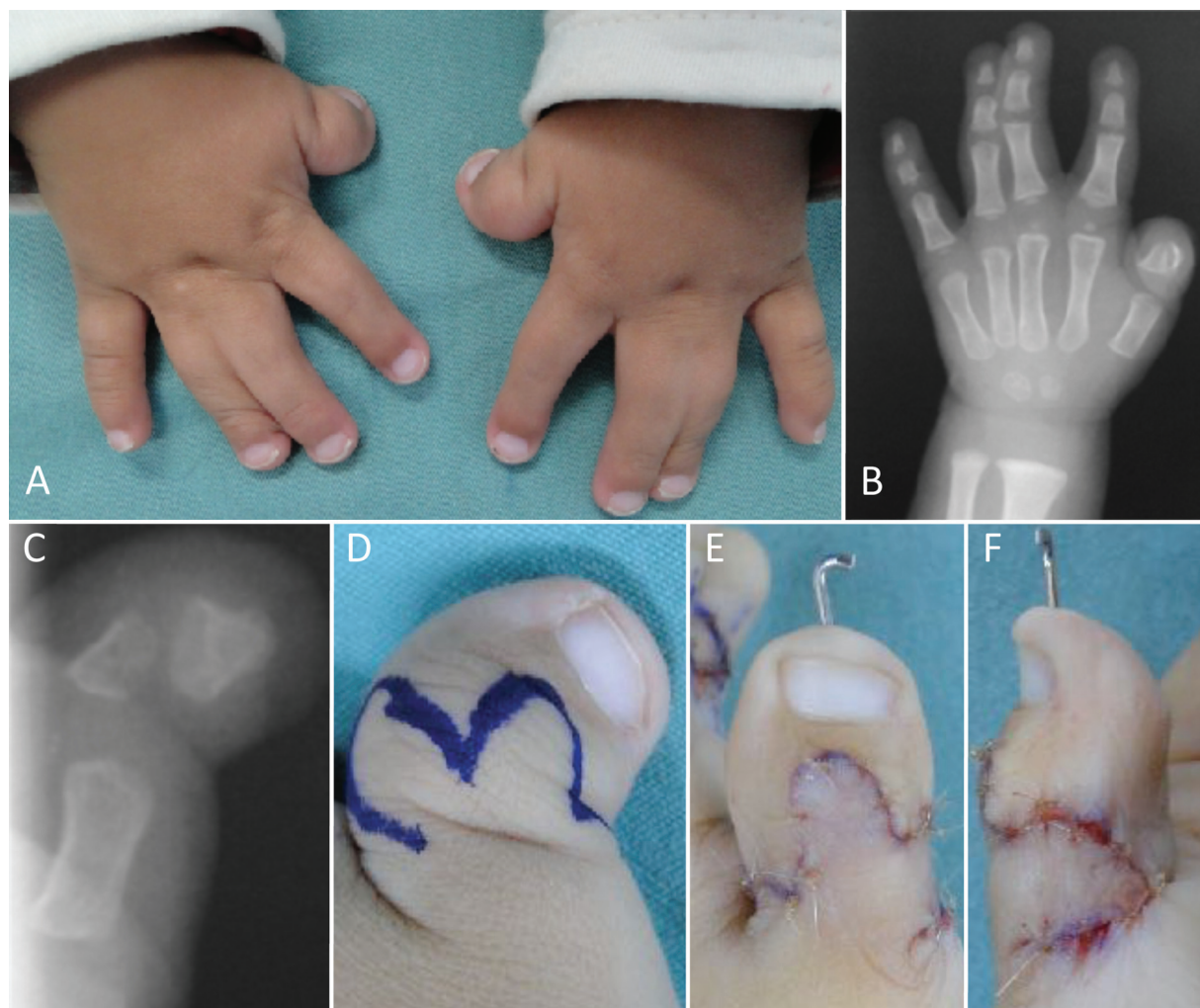


Fig. 2 Patient with Pfeiffer syndrome presenting bilateral hand changes, with the typical hitchhiker thumb deformity associated with third- and fourth-digit syndactyly (A). Radiograph showing a delta proximal phalanx of the thumb, and hypoplasia of middle phalanges of long fingers (B). Thumb radiograph details clinodactyly and delta phalanx (C). Surgical planning with bilobed skin flap (D). Elevation and rotation of bilobed flap with complete skin cover (E and F).

Discussion

Clinodactyly is a congenital anomaly featured by an excessive lateral deviation of a digit. In long fingers, that usually occurs due to abnormal medium phalanx development, leading to distal interphalangeal joint deformity, and, exceptionally, it can lead to proximal interphalangeal joint deviation due to a proximal phalanx abnormality.¹⁻⁴ It is most frequently caused by a delta phalanx, which is defined by its triangular shape, with a longitudinal epiphysis instead of a transverse one, located on the shorter side of the phalanx. The abnormal epiphysis disturbs the bone growth, thus causing a staple-like effect. Delta phalanges display a circle- or D-format on radiographs. A progressive, lateral deviation of the finger occurs with growth.^{2,6}

The most frequent site is the fifth digit with a radial-sided deformity, and, most commonly, there is bilateral compromise. Those cases usually show a positive familial history due to a variable expressivity, autosomal dominant trait. The second most-frequent location is the index finger, showing ulnar or

radial deviation. Surgical procedures are indicated for severe angulations and functional changes, causing finger overlapping during flexion, which usually happens with angulations > 30°.^{2,3,10}

The treatment for hitchhiker's thumb is the same used for the delta phalanx.¹¹ Few studies have assessed the result of surgical treatment of thumb clinodactyly, and mostly have reported a deformity recurrence in excess of 30% of the patients.¹¹

Our series thus included patients with Apert Syndrome, whose thumbs are always short and radially deviated; Pfeiffer Syndrome, whose hands are affected in almost 80% of cases, and changes are quite variable. Only 20% of patients with this syndrome display the hitchhiker thumb typical deformity. The other syndrome found in our series was the Rubinstein-Taybi Syndrome, a rare dysmorphic pathology described in 1963.^{12,13} The hand shows an enlarged and radially-deviated thumb, due to the presence of a delta proximal phalanx, thus creating the hitchhiker thumb.

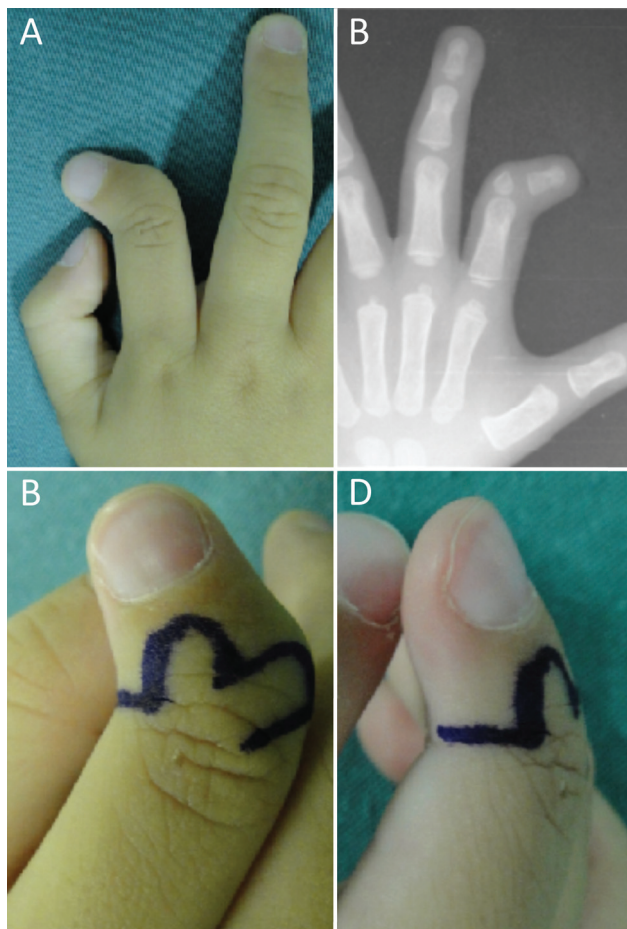


Fig. 3 Patient with index finger clinodactyly. An isolated deformity not associated to any syndrome (A). Radiograph proves the abnormal development of middle phalanx. Delta phalanx (B). Surgical planning with bilobed skin flap (C and D).

Clinodactyly has been classified by Burke and Flatt.¹⁴ Ali et al.⁴ have classified in accordance to deformity severity.

No matter the cause, the corrective surgery for clinodactyly aims to improve function and cosmesis. Different surgical procedures have been described, and the choice of technique depends on the underlying pathology, deformity degree, soft-tissue contracture, age, and surgeon preference. The procedure shall address bone alignment, soft-tissue lengthening, and skin cover.^{1,7}

Different bone procedures have been proposed. Burke and Flatt¹⁴ described resection, or closing-wedge osteotomy, a simpler procedure that carries the pitfall of the creation of a shortening on an already shortened digit. Carstam and Theander¹⁵ advocate an inversion-wedge osteotomy, in which a wedge is removed from one side of the phalanx and placed on the other side. Vickers⁷ proposes a physal opening through a mediolateral incision at the deformity apex, and fat interposition for the early treatment of clinodactyly. The deformity is, thus, not corrected during the surgery, but during longitudinal bone growth. It is not indicated for patients > 10 years of age and those with thumb deformities. Jain et al.¹⁶ have employed a dome-shaped osteotomy in 8 of 13 patients operated and reported angular

deformity recurrence in 5 patients. Jones¹⁷ described an addition- or opening-wedge osteotomy, with the advantage of creating a larger digit, together with bone and soft-tissue lengthening, along with skin cover by means of a z-plasty or full-thickness bone graft. Al Qattan¹⁸ points the use of Vickers' procedure for early treatment, and addition-wedge osteotomy for older patients and more severe deformities. Other techniques described, such as simple fixation with K-wires, primary arthrodesis, and isolated capsulotomy have all been abandoned due to poor results.

The alignment of a digit severe angular deformity requires a concurrent care with skin cover, especially in cases of addition-wedge osteotomy. The need of soft-tissue release at the concave side of deformity may appear during the procedure. Collateral ligaments and joint capsule may be released or lengthened, thus allowing the correct digit positioning.⁶ Several different flaps have been described, and the aim is the rapid healing with good-quality skin, minimum scarring, and the lack of need for a distant skin graft or flap rotation.⁴ Z-plasties may produce a satisfactory skin cover for cases of resection-wedge osteotomy.¹³

The bilobed flap was originally described by Esser in 1918,⁸ and, due to its versatility, it has been employed for defect reconstruction in different anatomic regions. The use on the correction of radial tilt hand deformity¹² and skin cover for distal interphalangeal joint mucous cyst postcorrection^{19,20} has been described. The angle between flap lobes was originally described as of 90°; however, several authors have created use and shape variations, thus allowing the possibility of angle variation between 45 and 180°, depending on the application.^{20,21} Our series has followed the technique as proposed by Cerqueira-Mosqueira and Fleming,⁵ using the bilobed flap to aid in clinodactyly reconstructions. This flap is obtained in a simple, safe fashion, and takes advantage of the redundant skin from one given region, adding quality skin cover on another region. The geometric design is straightforward and reproducible, thus minimizing the learning curve. The cosmetic result of the scar was excellent, as the flap allows skin closure with no tension.

The bilobed flap has clear advantages over other techniques for skin redistribution in angular defects. Due to creation simplicity and potential use of local redundant skin. It is a safe procedure, allowing adequate skin cover during surgery, with no tension onto the suture, thus avoiding the need of skin grafting or second-intention healing. Its simple geometric shape conveys reliability, allowing a rapid, unique, and definitive procedure. The final cosmetic result was excellent, expediting the healing process.^{5,20} It is hard to find a surgeon with at least reasonable experience in the treatment of hand clinodactyly, for its rareness. We have performed the bilobed flap in patients with different syndromes with good results, especially in diseases prone to develop keloid scarring.¹³ Patients showed good or excellent cosmetic evolution. There was no deformity recurrence within a follow-up of at least 12 months. We regard this follow-up time as too short to define whether there will be any residual deformity; however, such type of assessment was the chosen option, because the emphasis of this study is on the skin flap technique.

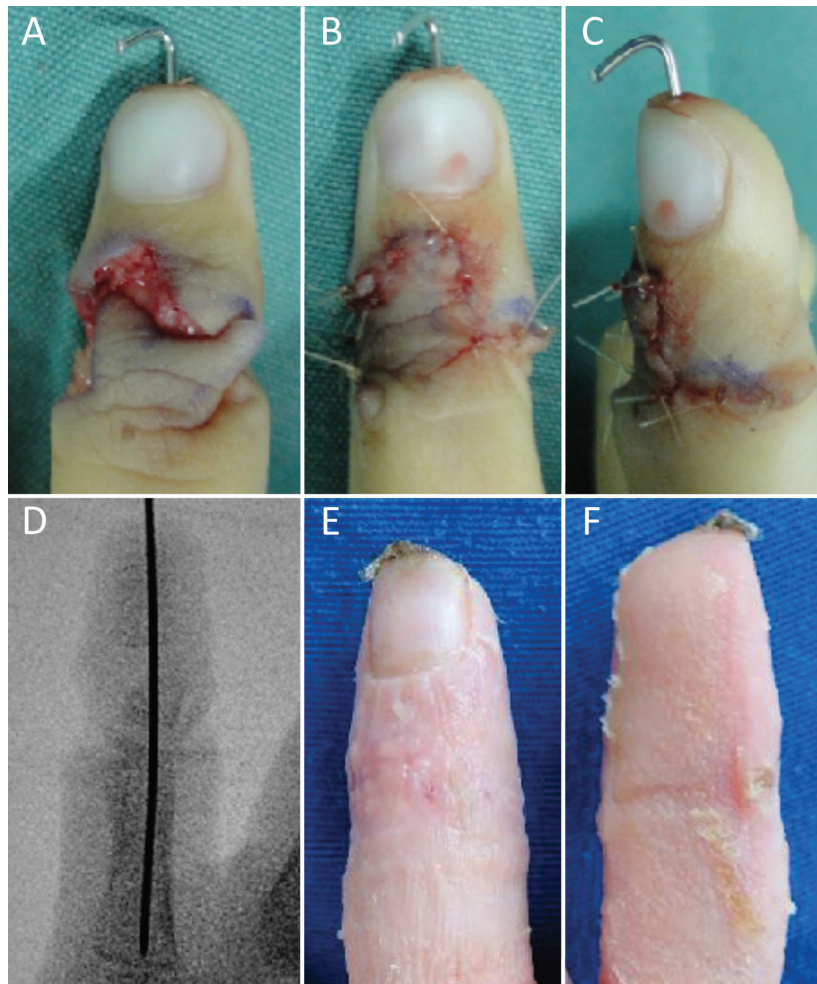


Fig. 4 Same patient of the previous figure. Elevation and rotation of bilobed flap, with complete skin cover (A, B, and C). Delta phalanx osteotomy and K-wire fixation (D). Skin healing after 2 weeks postoperatively (E and F).

Table 1 General data of clinodactyly patients operated with bilobed flap

Patient	Age	Sex	Side	Diagnosis	Site	Associated hand lesion	Initial angulation	Healing	Cosmesis	Complication
1	7y 4 mos	M	R	Apert syndrome	Thumb	Syndactyly 2/3/4/5 digits	60	3 weeks	Good	No
1	7y 4 mos	M	L	Apert syndrome	Thumb	Syndactyly 2/3/4/5 digits	50	3 weeks	Good	No
2	2y 10 mos	M	R	Pfeiffer syndrome	Thumb	Syndactyly 2/3/4/5 digits	80	2 weeks	Good	Flap vascular compromise
2	3y 11 mos	M	L	Pfeiffer syndrome	Thumb	Syndactyly 2/3/4/5 digits	75	4 weeks	Excellent	No
3	2y 11 mos	M	R	Rubinstein-Taybi syndrome	Thumb	No	75	2 weeks	Good	No
3	2y 11 mos	M	L	Rubinstein-Taybi syndrome	Thumb	No	65	2 weeks	Excellent	No
4	2y 5 mos	M	L	Isolated lesion	Index finger	No	70	2 weeks	Excellent	No
5	3y 10 mos	M	R	Rubinstein-Taybi syndrome	Thumb	No	70	3 weeks	Good	No
5	3y 10 mos	M	L	Rubinstein-Taybi syndrome	Thumb	No	60	3 weeks	Good	No

Abbreviations: L, left; mos, months; R, right; y, years.

Financial Support

There was no financial support from public, commercial, or non-profit sources.

Conflict of Interests

The authors declare that they have no conflict of interests.

References

- 1 Goldfarb CA, Wall LB. Osteotomy for clinodactyly. *J Hand Surg Am* 2015;40(06):1220–1224
- 2 Piper SL, Goldfarb CA, Wall LB. Outcomes of opening wedge osteotomy to correct angular deformity in little finger clinodactyly. *J Hand Surg Am* 2015;40(05):908–13.e1
- 3 Medina JA, Lorea P, Elliot D, Foucher G. Correction of Clinodactyly by Early Physiolyis: 6-Year Results. *J Hand Surg Am* 2016;41(06):e123–e127
- 4 Ali M, Jackson T, Rayan GM. Closing wedge osteotomy of abnormal middle phalanx for clinodactyly. *J Hand Surg Am* 2009;34(05):914–918
- 5 Cerqueiro-Mosquera J, Fleming AN. The bilobed flap: a new application in the reconstruction of congenital thumb deviation. *J Hand Surg Br* 2000;25(03):262–265
- 6 Strauss NL, Goldfarb CA. Surgical correction of clinodactyly: two straightforward techniques. *Tech Hand Up Extrem Surg* 2010;14(01):54–57
- 7 Vickers D. Clinodactyly of the little finger: a simple operative technique for reversal of the growth abnormality. *J Hand Surg Br* 1987;12(03):335–342
- 8 Esser JF. Gestielte lokale nasenplastik mit zweizipigen lappen, deckung des sekundären defektes vom ersten zipfel durch den zweiten. *Deutsche Zeitschrift für Chirurgie* 1918;143:385–390
- 9 Evans DM, Gateley DR, Lewis JS. The use of a bilobed flap in the correction of radial club hand. *J Hand Surg Br* 1995;20(03):333–337
- 10 Bednar MS, Bindra RR, Light TR. Epiphyseal bar resection and fat interposition for clinodactyly. *J Hand Surg Am* 2010;35(05):834–837
- 11 Anderson PJ, Hall CM, Smith PJ, et al. The hands in the Pfeiffer syndrome. *J Hand Surg Br* 1997;22:537–540
- 12 Wood VE, Rubinstein JH. Surgical treatment of the thumb in the Rubinstein-Taybi syndrome. *J Hand Surg Br* 1987;12(02):166–172
- 13 Varela Ares E, Yáñez J, Irisarri C. El tratamiento de la falange delta en el síndrome de Rubinstein-Taybi. A propósito de un caso. *Acta Ortop Gallega* 2012;8(02):65–67
- 14 Burke F, Flatt A. Clinodactyly. A review of a series of cases. *Hand* 1979;11(03):269–280
- 15 Carstam N, Theander G. Surgical treatment of clinodactyly caused by longitudinally bracketed diaphysis (“delta phalanx”). *Scand J Plast Reconstr Surg* 1975;9(03):199–202
- 16 Jain A, Rehman S, Smith G. Long-term results following osteotomy of the thumb delta phalanx in Rubinstein-Taybi Syndrome. *J Hand Surg Eur Vol* 2010;35(04):296–301
- 17 Jones GB. Delta Phalanx. *J Bone Joint Surg Br* 1964;46:226–228
- 18 Al-Qattan MM. Congenital sporadic clinodactyly of the index finger. *Ann Plast Surg* 2007;59(06):682–687
- 19 Young KA, Campbell AC. The bilobed flap in treatment of mucous cysts of the distal interphalangeal joint. *J Hand Surg Br* 1999;24(02):238–240
- 20 Jager T, Vogels J, Dautel G. The Zitelli design for bilobed flap applied on skin defects after digital mucous cyst excision. A review of 9 cases. *Tech Hand Up Extrem Surg* 2012;16(03):124–126
- 21 Zitelli JA. The bilobed flap for nasal reconstruction. *Arch Dermatol* 1989;125(07):957–959