



Stabilization of Talocalcaneal Luxation with a Dorsal 1.0 mm Compression Plate in Four Cats

Matthew Smith¹ Nicholas Macdonald¹

¹Northwest Veterinary Specialists, Runcorn, Cheshire, United Kingdom of Great Britain and Northern Ireland

VCOT Open 2021;4:e72–e78.

Address for correspondence Matthew Smith, BVetMed, Northwest Veterinary Specialists, Delamere House Ashville Point Sutton Weaver, Runcorn, Cheshire WA7 3FW, United Kingdom of Great Britain and Northern Ireland (e-mail: matt.smith@nwspecialists.com).

Abstract

The objective of this case series was to report the surgical technique, complications, and long-term outcome of feline talocalcaneal luxation stabilized with a dorsally applied two-hole, 1.0 mm compression plate. It is a retrospective study of four cats that underwent surgical stabilization of talocalcaneal luxation with a dorsally applied two-hole, 1.0 mm compression plate between 2013 and 2019. Medical history and diagnostic imaging (radiographs ± computed tomography scans) were reviewed. The owners of three of the four cats were contacted with a follow-up questionnaire based on the Feline Musculoskeletal Pain Index to assess long-term outcome. No intraoperative or postoperative complications were encountered. All three owner questionnaires were returned and Feline Musculoskeletal Pain Index scores of 0, 1, and 4 were recorded out of a maximum score of 83 (normal cat range is –18 to 4; cats with degenerative joint disease range from 11 to 66). Quality of life was rated by the owners as excellent ($\frac{2}{3}$) or good ($\frac{1}{3}$). All cats returned to full activity. Stabilization of feline talocalcaneal luxation with a dorsally applied two-hole, 1.0 mm compression plate was technically straightforward, easily accessible, and a relatively low-cost treatment option which carries a low risk of complications and an excellent prognosis.

Keywords

- ▶ talocalcaneal luxation
- ▶ 1.0 mm compression plate
- ▶ feline

Introduction

Talocalcaneal luxation is an uncommon injury in cats and is thought to be the result of trauma causing hyperextension and axial compression of the tarsus.^{1,2} Dorsal luxation of the head of the talus is the most common presentation of talocalcaneal luxation with plantar luxation reported rarely.² In order for the head of the talus to luxate dorsally, there must be disruption of the talocalcaneal and talocentral ligaments.³ Dorsal luxation of the head of the talus causes severe lameness due to the loss of the weight bearing axis between the talus and the central tarsal bone.² Reduction restores the integrity of the tarsus and the normal weight bearing axis. Conservative treatment with external coaptation may be considered for cases where closed reduction can be successfully maintained. Internal stabilization should be

considered for cases where closed reduction cannot be performed or where relaxation occurs following closed reduction. Four internal stabilization techniques have been described across two reference texts. Dorsally placed two-hole 2.0 mm locking plate with screws in the talus and central tarsal bone, 1.3 or 1.5 mm mini-plates spanning the talocentral, centrodistal and tarsometatarsal joints, tension band wire repair around 1.5 mm screws placed in the talus and central tarsal bone and a 2.0 mm positional screw placed between the talus and calcaneus.^{1,2,4} A good to excellent prognosis has been reported in three cats following internal stabilization of talocalcaneal luxation using 2.0 mm ComPact Unilock plating system.⁴

The aim of this case series was to report the technical aspects and outcomes of internal stabilization of talocalcaneal

received
November 23, 2020
accepted after revision
May 22, 2021

DOI <https://doi.org/10.1055/s-0041-1732302>.
ISSN 2625-2325.

© 2021. The Author(s).

This is an open access article published by Thieme under the terms of the Creative Commons Attribution License, permitting unrestricted use, distribution, and reproduction so long as the original work is properly cited. (<https://creativecommons.org/licenses/by/4.0/>)
Georg Thieme Verlag KG, Rüdigerstraße 14, 70469 Stuttgart, Germany

luxation in cats using a two-hole, 1.0 mm compression plate with two bicortical 1.0 mm cortical bone screws.

Methods and Materials

The medical records and diagnostic imaging (radiographs ± computed tomography [CT] images) of four cats treated for unilateral talocalcaneal luxation between 2013 and 2019 were reviewed. All cases were managed by a Board-certified surgeon or surgical resident working under supervision. Orthopaedic re-examinations were initially planned as part of the long-term follow-up; however, these could not be performed. The owners of each cat were contacted with a follow-up questionnaire using the Feline Musculoskeletal Pain Index (FMPI), a previously verified owner assessment of degenerative joint disease (DJD) associated pain in cats.⁵ The FMPI contains 21 multiple-choice questions to assess activity, pain intensity and overall quality of life. A score is attributed to each multiple-choice option with a maximum total score of 83.

Ethical approval for the study was provided by the Royal College of Veterinary Surgeons Ethics Review Panel.

Case 1

A six-year-11-month-old, female neutered, domestic long hair cat presented with a 10/10 left pelvic limb lameness of 24 hours. Examination revealed pain and swelling just distal to the left tarsocrural joint. Orthogonal radiographs of the tarsi revealed left talocalcaneal luxation. A CT scan was performed to exclude other tarsal injuries (→ Fig. 1). No other abnormalities were reported. Closed reduction in the luxation was performed and a modified Robert Jones bandage applied but re-luxation occurred within 4 days. Surgery was performed 5 days after initial presentation.

Case 2

A twelve-year-old, male neutered (MN), domestic short hair (DSH) was presented with a 10/10 right pelvic limb lameness

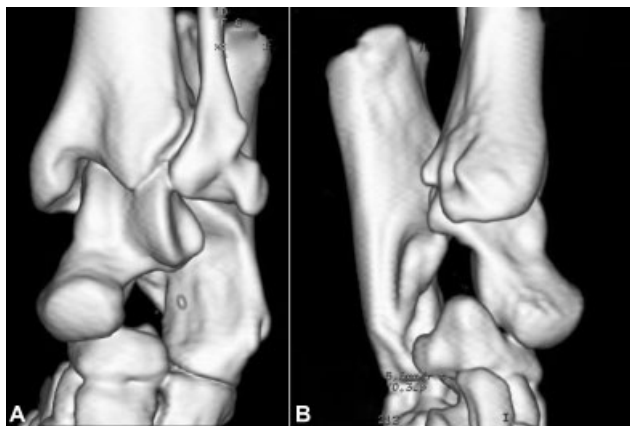


Fig. 1 Three-dimensional computed tomography reconstructions of left tarsal joint from case 1. Dorsolateral-plantomedial oblique view (A) and mediolateral view (B) revealing talocalcaneal luxation. Note the dorsal displacement of the head of the talus.

having been missing for 2 days. Examination revealed pain and swelling associated with the right tarsus. Orthogonal radiographs of the tarsi revealed right talocalcaneal luxation (→ Fig. 2). A CT scan was performed to exclude other tarsal injuries. No other abnormalities were reported. Closed reduction in the luxation was performed; however, re-luxation occurred immediately.

Case 3

A one-year-9-month-old, MN, DSH was presented with a 9-day history of 9 to 10/10 right pelvic limb lameness. Swelling was palpable around the right tarsus with pain on manipulation and a firm protrusion palpable dorsal to the level of the proximal intertarsal joint. No other abnormalities were detected. Orthogonal radiographs of the right tarsus revealed a talocalcaneal luxation. Closed reduction in the luxation was performed but re-luxation occurred immediately.

Case 4

A six-year-3-month-old, MN, DSH was presented with a 5-day history of 8/10 left pelvic limb lameness following a low-speed road traffic accident. Pain was detected on manipulation of the left tarsus and a firm protrusion was palpable dorsal to the proximal intertarsal joint. No other abnormalities were detected. Orthogonal radiographs of the left tarsus revealed a talocalcaneal luxation. Closed reduction in the luxation was possible but spontaneous re-luxation occurred immediately.

Surgical Technique

Premedication with methadone (Comfortan 10 mg/mL; Dechra) 0.1 to 0.2 mg/kg intravenously (IV) and either acepromazine (ACP 2 mg/mL; Novartis) 0.02 mg/kg or medetomidine (Domitor 1 mg/mL; Zoetis) 5 µg/kg IV was performed prior to induction of general anaesthesia with propofol (Propofol 10 mg/mL; Abbott) IV given to effect. After tracheal intubation, general anaesthesia was maintained with isoflurane in oxygen (Isoflo; Zoetis). Cefuroxime (Zinacef; GlaxoSmithKline) 15 to 20 mg/kg IV was given 30 minutes prior to skin incision. Cases 3 and 4 received sciatic and saphenous nerve blocks with bupivacaine (Marcain Polyamp 0.25%; Aspen). Each cat was positioned for surgery in dorsal recumbency with a hanging limb preparation.

All cases were treated via an identical approach. A 1.0 to 1.5 cm skin incision was made centred over the palpable dorsally displaced head of the talus. Sharp dissection was continued down on the talus and central tarsal bone. Subcutaneous tissue, dorsal fascia and extensor tendons were retracted with Gelpi retractors. The articular surfaces of the talus and central tarsal bone were inspected prior to reduction in the luxation. Appropriate positioning of a two-hole 1.0 mm compression plate (Veterinary Instrumentation) over the dorsal aspect of the head of the talus and the central tarsal bone was confirmed. Care was taken to ensure that the proposed position of the distal screw in the centre of the central tarsal

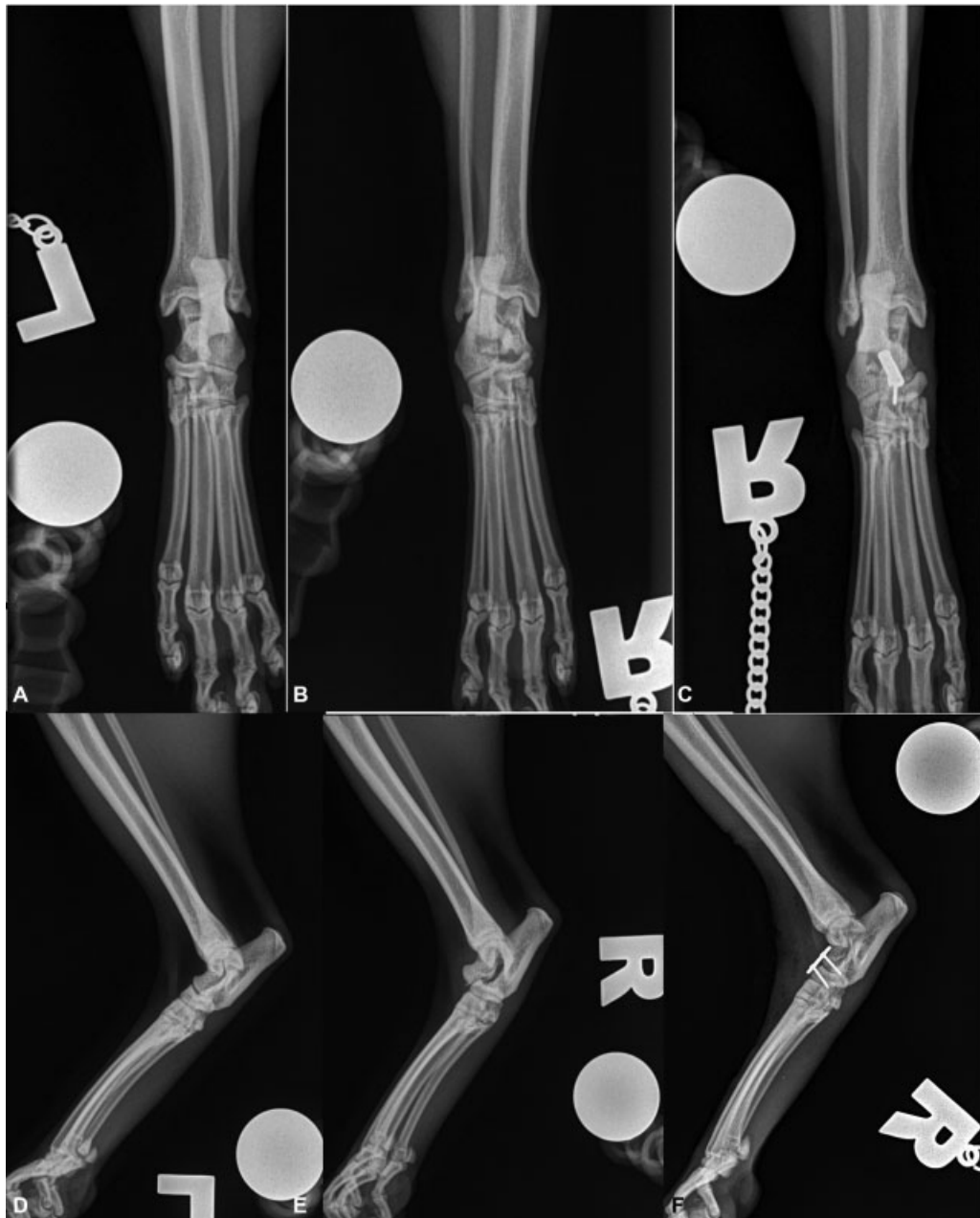


Fig. 2 Radiographs of tarsi from case 2. Dorsoplantar (A) and mediolateral (D) views of normal left tarsal joint. Preoperative dorsoplantar (B) and mediolateral (E) views of the right tarsal joint revealing talocalcaneal luxation. Postoperative dorsoplantar (C) and mediolateral (F) views of the right tarsal joint confirming talocalcaneal luxation reduction and good implant positioning.

bone would permit appropriate placement of the proximal screw in the head of the talus. A 0.7 mm pilot hole was drilled in the centre of the dorsal aspect of the central tarsal bone. A self-tapping 1.0 mm cortical bone screw was inserted through the distal plate hole. The pilot hole for the proximal screw was drilled into the head of the talus through the plate and a self-tapping 1.0 mm cortical bone screw inserted (►Fig. 3). The plate was placed as a neutralization plate. Dorsal crural fascia was closed with 4-0 polydioxanone (PDS, Ethicon). Subcutaneous layer closure and intradermal skin apposition was achieved with 4-0 poliglecaprone 25 (Monocryl, Ethicon). Postoperative orthogonal radiographs confirmed correct anatomical reduction and good implant positioning in each

case (►Fig. 2). No intraoperative complications were encountered.

The limb was bandaged for 24 to 72 hours postoperatively, depending on patient compliance. All cases were discharged from the hospital within 48 hours of surgery. Cage rest was advised for 3 weeks followed by small room restriction for 3 weeks progressing to house rest for a further 4 weeks. Cats were discharged with meloxicam (Metacam 0.5 mg/mL oral suspension for cats, Boehringer Ingelheim) 0.05 mg/kg q 24 hours per os for 7 to 10 days. Cases 3 and 4 received gabapentin (gabapentin 25mg tablets; Summit Veterinary Pharmaceuticals) 25mg q 8 to 12 hours per os for 5 days. No complications were encountered during surgery.

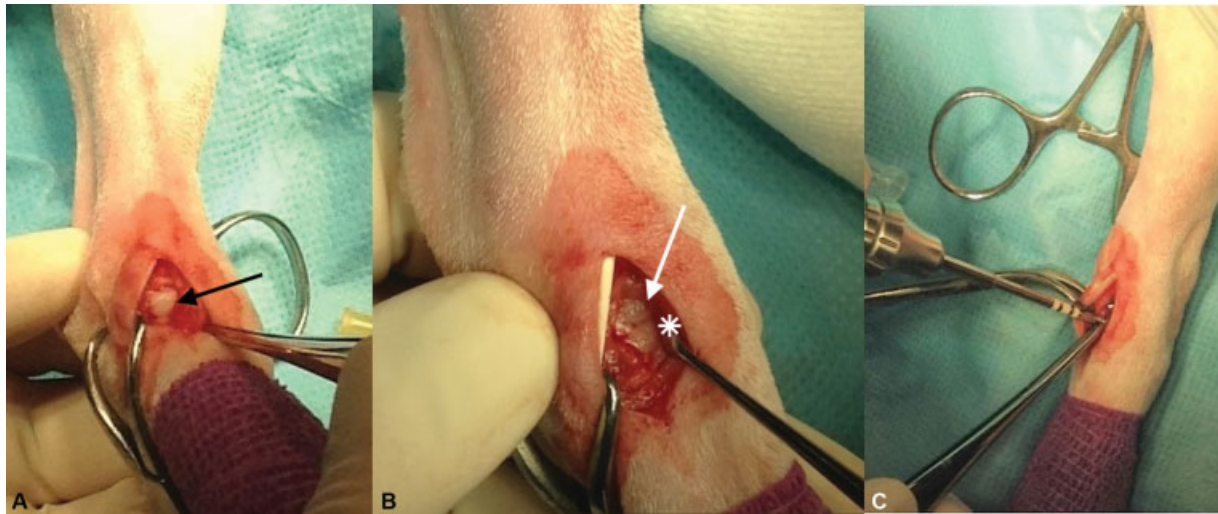


Fig. 3 Intraoperative photographs of talocalcaneal luxation. Pre-reduction photograph (A) (black arrow) indicates dorsally displaced head of the talus. Post-reduction photograph (B) (white arrow) indicates reduced head of talus and white asterisk indicates central tarsal bone. Application of two-hole 1.0 mm compression plate (C) to maintain reduction in talocalcaneal luxation.

Outcomes

All cats made good recoveries from surgery and no complications were reported. No lameness was reported in case 1 at 6 weeks follow-up examination. Orthogonal radiographs revealed mild osteophytosis of the centrodistal joint space but there were no concerns regarding talocalcaneal reduction or the implants. Case 2 was using the limb with no problems reported at follow-up examination 9 days postoperatively. The cat did not return for further follow-up examination or radiographs. Case 3 did not return for follow-up assessment or radiographs. Case 4 returned for re-examination 7 weeks postoperatively at which stage mild (2/10) left pelvic limb lameness was observed. The tarsus had a normal range of movement and no pain was detected on examination. Orthogonal radiographs revealed no evidence of re-luxation or implant concerns.

Owner questionnaire results of cases 2 to 4 are reported in ►Table 1. Case 1 was re-homed 19 months post-surgery following death of the owner and the cat could not be traced. Routine examination by the referring veterinary surgeon had been performed at 4 and 16 months postoperatively. Limb use was reported as good with no lameness concerns or complications documented on both occasions. The owner of case 2 reported that the cat made a full recovery with no lameness or pain up until his death 6 years later due to unrelated reasons. The FMPI score for case 2 was 1/83 and quality of life was rated as excellent with a follow-up time of 6 years. The owner of case 3 reported that the cat made a good recovery from surgery and had resumed normal activity. Right pelvic limb stiffness was reported following periods of rest; however, this resolved once the cat was active and required no analgesia. The FMPI score for case 3 was 4/83 and quality of life was rated as good with a follow-up time of 15 months. The owner of case 4 reported that the cat made a complete recovery from surgery and resumed full activity.

The FMPI score for case 4 was 0/83 and quality of life was rated as excellent with a follow-up of 10 months.

Discussion

The results of this case series suggest that surgical stabilization of talocalcaneal luxation with a two-hole 1.0 mm compression plate carries an excellent prognosis. Benito and colleagues reported a control group of cats (no evidence of DJD) scored a median FMPI total score of 0 (range: -18 to 4). Cats with evidence of DJD scored a median FMPI total score of 25 to 29 (measured on 2 occasions, range: 11-66).⁵ Case 3 had the highest FMPI score of 4 which was within the range reported for cats unaffected by DJD and the cat returned to full activity when compared with pre-injury level.

The surgical technique employed was technically straightforward. No difficulties were encountered when performing the limited approach, reducing the luxation or placing the implants. Preoperative measurements from the radiographs or CT scans of either the contralateral limb or the affected limb with the luxation temporarily reduced revealed the distance between the base of the trochlea of the talus and the craniodistal margin of the central tarsal bone to be 10 to 12 mm (►Fig. 4). The optimal distance between screw placement was approximately 6 mm (►Fig. 4). The two-hole 1.0 mm compression plate was 10 mm long and permitted screw placement 6 mm apart, whereas the minimum plate lengths for the 1.5 mm dynamic compression plate (DCP) and 2.0 mm locking compression plate (LCP) were four-hole, 20 and 27 mm long plates respectively; thus at least double the required length. The LCP combination hole was significantly larger than the hole for a standard DCP which resulted in reduced screw hole density. Cutting a four-hole LCP down to a two-hole plate would not permit optimal screw position and may cause interference with the trochlea of the talus and the talocrural joint. A two-node 2.0 mm string of pearls plate

Table 1 Results of FMPI-based owner questionnaire from cases 2 to 4.

Category	Case 2	Case 3	Case 4
Walking	Normal—0	Not quite normal—1	Normal—0
Running	Normal—0	Not quite normal—1	Normal—0
Jumping up	Normal—0	Normal—0	Normal—0
Jumping up to kitchen counter height	Normal—0	Normal—0	Normal—0
Jumping down	Normal—0	Normal—0	Normal—0
Climbing upstairs	Normal—0	Normal—0	Normal—0
Climbing downstairs	Normal—0	Normal—0	Normal—0
Playing with / chasing toys	Normal—0	Normal—0	Normal—0
Playing / interacting with other pets	Normal—0	Normal—0	Normal—0
Getting up from a resting position	Normal—0	Normal—0	Normal—0
Lying down or sitting	Normal—0	Normal—0	Normal—0
Stretching	Normal—0	Normal—0	Normal—0
Grooming	Normal—0	Normal—0	Normal—0
Interacting with owner	Normal—0	Normal—0	Normal—0
Being touched or handled	Not quite normal when touching affected paw—1	Normal—0	Normal—0
Eating	Normal—0	Normal—0	Normal—0
Using litter box	Normal—0	Normal—0	Normal—0
Overall activity	Normal—0	Normal—0	Normal—0
Pain over last week	No pain—0	Little Pain—1	No pain—0
Pain over last 24 hours	No pain—0	No pain—0	No pain—0
Quality of life	Excellent—0	Good—1	Excellent—0
Total Score (Max Score 83)	1	4	0

Abbreviation: FMPI, Feline Musculoskeletal Pain Index.

Note: Questions 1–18 ‘How has treatment of your cat’s injury affected the following [Category]?’ Owners selected one of the following options (score for each answer in brackets); Above normal (–1), Normal (0), Not quite normal (1), Somewhat worse than normal (2), Barely/with great difficulty (3), Not at all (4), Not applicable (N/A). Questions 19 and 20 ‘How would you grade your cat’s pain level?’ Options: No pain (0), Little pain (1), Mild pain (2), Moderate pain (3), and Severe pain (4). Question 21: ‘How would you grade your cat’s quality of life?’ Options: Excellent (0), Good (1), Fair (2), and Poor (3).

was not considered appropriate due to the profile of the plate, resulting in limited soft tissue coverage and concerns for increased wound tension. The length of a two node 2.0 mm string of pearls plate was 17 mm which would likely have resulted in interference of the talocrural joint. In addition, internode spacing of 8 mm may have made optimal screw position in the central tarsal bone challenging. Other small locking plate systems (e.g. 1.5 mm LCP) may have provided suitable alternative options; however, they were not without limitations. The smallest 1.5 mm LCP available was a four-hole plate, measuring 23 mm in length. Cutting the plate to two holes may have provided an appropriate length; however, this may have exceeded the 10 to 12 mm preoperative measurement, potentially compromising optimum screw position or interference with the trochlea. The two-hole 1.0 mm compression plate and 1.0 mm cortical bone screws were readily available in the UK and required no alteration. The cost of these implants along with the

0.7 mm drill bit was approximately 24% that of a four-hole 1.5 mm LCP, locking screws and instrumentation. While locking plate technology may provide greater stability,⁶ our results indicate that this is not required and that a two-hole 1.0 mm compression plate with two bi-cortical 1.0 mm cortical bone screws provided adequate stability for good clinical outcomes in four cats with talocalcaneal luxation.

Previous work has shown that stability of the talocalcaneal joint is maintained by two ligaments (proximal and distal talocalcaneal ligaments) that traverse the tarsal sinus.³ The four cases reported all demonstrated dorsal luxation of the head of the talus but no clear displacement of the proximal aspect of the talocalcaneal joint. We suggest that this may reflect disruption of only the distal talocalcaneal ligament (along with the talocentral ligament) which could result in dorsal rotation of the head of the talus. Previously published radiographs of canine talocalcaneal luxation revealed marked

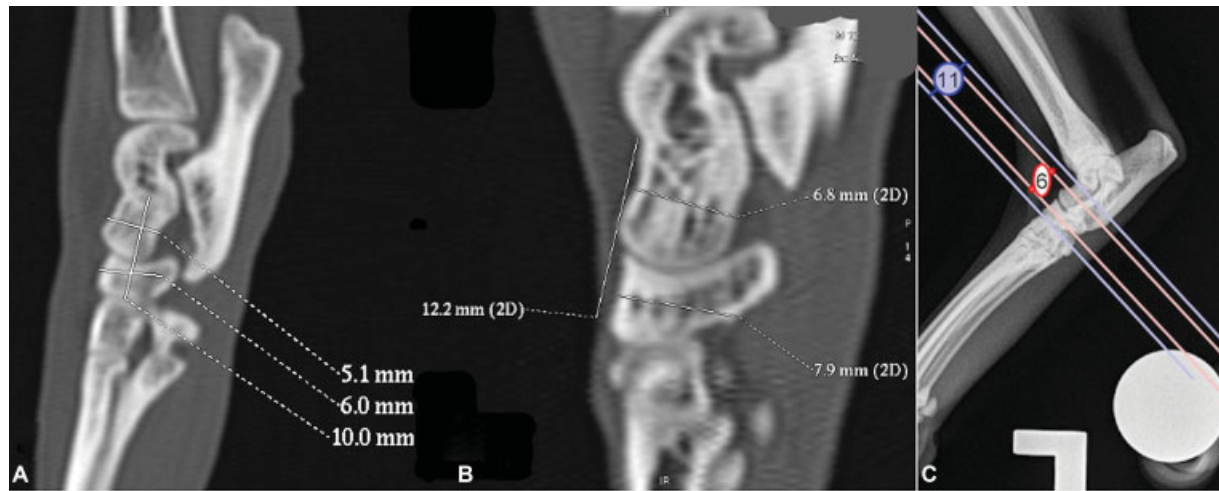


Fig. 4 Preoperative measurements from base of the trochlear of the talus to the distal margin of the central tarsal bone. (A) Sagittal view of computed tomography (CT) scan from left tarsus of case 1 with temporary reduction in the talocalcaneal luxation. (B) Sagittal view of the CT scan of the left tarsus from case 2 (contralateral limb). (C) Mediolateral radiograph of left tarsus of case 3 (contralateral limb); the blue lines indicate the distance between the base of the trochlear and the distal margin of the central tarsal bone. The red lines indicate the optimum position of each screw with a distance of 6 mm between the screws.

displacement of the proximal aspect of the talocalcaneal joint in addition to dorsal displacement of the head of the talus which may represent rupture of both talocalcaneal ligaments.³ In this scenario in cats, it is possible that dorsal internal stabilization with a 1.0 mm compression plate may not provide adequate stability. An alternate technique is placement of a positional screw between the talus and calcaneus.^{3,7} The talocalcaneal joint in dogs has been classified as a low motion rather than no motion joint with approximately 1 mm of diagonal movement between the talus and calcaneus.³ A concern with the talocalcaneal screw technique is the risk of screw breakage due to residual motion within the talocalcaneal joint resulting in cyclic metal fatigue.^{3,7} In cases of rupture of both talocalcaneal ligaments and displacement of the entire talocalcaneal joint, talocalcaneal screw placement with or without placement of a dorsal 1.0 mm compression plate may be required to provide adequate stability.

The dorsal aspect of the tarsus is the compression surface of the joint when weight bearing.⁸ The talocentral joint is considered a low motion joint also in cats and may play only a minor role during ambulation.⁴ The aim of internal stabilization in these cases was to provide adequate stability for fibrous healing of the distal talocalcaneal and dorsal talocentral ligaments to restore normal function. Removal of the implants may be advantageous to maximize return to normal function; however, our results suggest that excellent long-term function can be obtained without implant removal. Radiographic follow-up was limited to two of the four cats; however, no implant-related concerns were identified in these two cases. Screw loosening or breakage due to cyclic fatigue remained a possibility, especially if talocentral joint movement persisted.⁴ Arthrodesis of the talocentral joint could be considered in these cases; however, this would require more extensive dissection to accommodate more robust internal

fixation, prolonged surgical time, potential autogenous bone graft morbidity, extended postoperative restrictions and the possible need for postoperative external coaptation.

This case series is limited by the small number of cats and the inherent limitation of a retrospective study. A multi-centre study assessing the long-term outcome, complications, and success of this technique compared with alternate plating systems and talocalcaneal positional screw placement could be useful.

The results presented in this case series give veterinary surgeons a technically straightforward, easily accessible, and a relatively low-cost treatment option for feline talocalcaneal luxation which carries a low risk of complications and an excellent prognosis.

Conflict of Interest

None declared.

References

- 1 Scott H, McLaughlin R. Fractures and disorders of the hindlimb - Part 6: Tarsal, metatarsal and phalangeal injuries. In: Scott H, McLaughlin R, eds. *Feline Orthopedics*. Florida: Manson Publishing; 2006:249–250
- 2 Voss K, Langley-Hobbs SJ, Montavon PM. Tarsal joint. In: Montavon PM, Voss K, Langley-Hobbs SJ, eds. *Feline Orthopedic Surgery and Musculoskeletal Disease*. Philadelphia: Saunders Elsevier; 2009:515–519
- 3 Gorse MJ, Purinton PT, Penwick RC, Aron DN, Roberts RE. Talocalcaneal luxation: an anatomic and clinical study. *Vet Surg* 1990; 19(06):429–434
- 4 Voss K, Keller M, Montavon PM. Internal splinting of dorsal inter tarsal and tarsometatarsal instabilities in dogs and cats with the Compact Unilock 2.0/2.4™ System. *Vet Comp Orthop Traumatol* 2004;17:125–130
- 5 Benito J, Depuy V, Hardie E, et al. Reliability and discriminatory testing of a client-based metrology instrument, feline musculoskeletal pain

- index (FMPI) for the evaluation of degenerative joint disease-associated pain in cats. *Vet J* 2013;196(03):368–373
- 6 Sikes JW Jr, Smith BR, Mukherjee DP, Coward KA. Comparison of fixation strengths of locking head and conventional screws, in fracture and reconstruction models. *J Oral Maxillofac Surg* 1998; 56(04):468–473
- 7 Campbell JR, Bennett D, Lee R. Intertarsal and tarso-metatarsal subluxation in the dog. *J Small Anim Pract* 1976;17(07): 427–442
- 8 Welch JA. The tarsus and metatarsus. In: Slatter D, ed. *Textbook of Small Animal Surgery*. Third edition Philadelphia: Saunders Elsevier; 2003:2158–2169