



# Treatment of Irreparable Rotator Cuff Tears: Superior Capsular Reconstruction with Fascia Lata Allograft

## *Tratamento das rupturas irreparáveis do manguito rotador: Reconstrução capsular superior com aloenxerto de fáschia lata*

Rodrigo Alves Beraldo<sup>1</sup> Mauro Emilio Conforto Gracitelli<sup>1</sup> Eduardo Angeli Malavolta<sup>1</sup>   
 Jorge Henrique Assunção<sup>1</sup> Fernando Brandão de Andrade e Silva<sup>1</sup> Arnaldo Amado Ferreira Neto<sup>1</sup>

<sup>1</sup>Orthopedist and Traumatologist, Shoulder and Elbow Specialist, Institute of Orthopedics and Traumatology, Hospital das Clínicas, Faculty of Medicine, University of Sao Paulo, Sao Paulo, SP, Brazil

Address for correspondence Rodrigo Alves Beraldo, MD, MSc, University of Sao Paulo, Rua Dr. Ovídio Pires de Campos, 333, 3rd floor, Cerqueira Cesar, São Paulo, SP, 05403-010, Brazil (e-mail: beraldo.ortop@gmail.com).

Rev Bras Ortop 2022;57(5):876–883.

### Abstract

**Objective** The objective of the present study was to evaluate the efficacy and safety of superior capsular reconstruction (SCR) using fascia lata allograft.

**Methods** A prospective case series of 15 patients with irreparable supraspinatus tear who underwent SCR using fascia lata allograft. The American Shoulder and Elbow Surgeons (ASES) scale at 12 months after surgery was the primary outcome. The University of California Los Angeles (UCLA), Constant-Murley, and Single Assessment Numeric Evaluation (SANE) scales, in addition to the range of motion, were secondary outcomes. Radiological parameters were also evaluated by simple radiographs and magnetic resonance imaging (MRI).

**Results** Fifteen patients completed 12 months of postoperative follow-up. The ASES score increased from 34.0 to 73.0 ( $p = 0.005$ ). The UCLA, Constant-Murley, and SANE scales also showed statistically significant differences ( $p = 0.001$ ;  $p = 0.005$ ; and  $p = 0.046$ ). In the evaluation of range of motion, there was improvement in elevation and in external rotation ( $95$  to  $140^\circ$ ,  $p = 0.003$ ;  $30$  to  $60^\circ$ ,  $p = 0.007$ ). Six patients (40%) had complete graft healing. The clinical outcomes were significantly higher in the patients who presented graft healing.

**Conclusions** Superior capsular reconstruction using a fascia lata allograft is a safe and effective procedure in short follow-up. Level of Evidence IV; Therapeutic Study; Case Series.

### Keywords

- ▶ rotator cuff injuries/surgery
- ▶ shoulder joint
- ▶ joint capsule
- ▶ fascia lata/transplantation
- ▶ treatment outcome

\* Work developed in the Shoulder and Elbow Group of the Institute of Orthopedics and Traumatology, Hospital das Clínicas, Faculty of Medicine, University of São Paulo, São Paulo, SP, Brazil.

received  
October 21, 2020  
accepted  
February 11, 2021  
published online  
November 11, 2021

DOI <https://doi.org/10.1055/s-0041-1732389>  
ISSN 0102-3616.

© 2021. Sociedade Brasileira de Ortopedia e Traumatologia. All rights reserved.

This is an open access article published by Thieme under the terms of the Creative Commons Attribution-NonDerivative-NonCommercial-License, permitting copying and reproduction so long as the original work is given appropriate credit. Contents may not be used for commercial purposes, or adapted, remixed, transformed or built upon. (<https://creativecommons.org/licenses/by-nc-nd/4.0/>)

Thieme Revinter Publicações Ltda., Rua do Matoso 170, Rio de Janeiro, RJ, CEP 20270-135, Brazil

## Resumo

**Objetivo** O objetivo do presente estudo foi avaliar a eficácia e a segurança da reconstrução capsular superior (RCS) com a utilização do aloenxerto de fásia lata.

**Métodos** Uma série de casos prospectivos de 15 pacientes com ruptura irreparável do supraespinhal foi submetida a RCS com aloenxerto de fásia lata, sendo adotada como desfecho primário a escala American Shoulder and Elbow Surgeons (ASES, na sigla em inglês) aos 12 meses do pós-operatório. Como desfechos secundários, foram adotadas as escalas da University of California Los Angeles (UCLA, na sigla em inglês), Constant-Murley, e Single Assessment Numeric Evaluation (SANE, na sigla em inglês), além da amplitude de movimento. Os parâmetros radiológicos também foram avaliados por radiografias simples e ressonância magnética (RM).

**Resultados** Quinze pacientes completaram 12 meses de acompanhamento pós-operatório. O escore ASES aumentou de 34,0 para 73,0 ( $p=0,005$ ). As escalas UCLA, Constant-Murley e SANE também apresentaram diferenças estatisticamente significativas ( $p=0,001$ ;  $p=0,005$ ; e  $p=0,046$ ). Na avaliação da amplitude de movimento, houve melhora na elevação e rotação externa ( $95$  a  $140^\circ$ ,  $p=0,003$ ;  $30$  a  $60^\circ$ ,  $p=0,007$ ). Seis pacientes (40%) tiveram cicatrização completa do enxerto. Os desfechos clínicos foram significativamente maiores nos pacientes que apresentaram cicatrização do enxerto.

**Conclusões** A RCS com aloenxerto de fásia lata é um procedimento seguro e eficaz com um curto acompanhamento de tempo. Nível de evidência IV; Estudo Terapêutico; Série de casos.

### Palavras-chave

- ▶ lesões do manguito rotador/cirurgia
- ▶ articulação do ombro
- ▶ cápsula articular
- ▶ fásia lata/transplante
- ▶ resultado do tratamento

## Introduction

Rotator cuff tear is a common condition, affecting  $\sim 20\%$  of the population.<sup>1</sup> The surgical treatment for this lesion usually has significant clinical improvement.<sup>2</sup> However, healing failures are frequent, with retears in 27% of the cases.<sup>3</sup> The treatment of massive rotator cuff tears is particularly challenging, because the repair and its consequent healing are hampered by tendon retraction, muscle atrophy, and fatty degeneration.<sup>3</sup> There is still no consensus for the treatment of irreparable supraspinatus tears, especially in young patients.

Mihata et al.<sup>4,5</sup> described a procedure for superior capsular reconstruction (SCR) in patients with massive supraspinatus tears that aimed at restoring the upper stability of the glenohumeral joint and, thus, re-establishing the function of the remaining rotator cuff. Originally, the technique used autologous fascia lata for the graft.<sup>4</sup> To reduce patient morbidity and surgical time, decellularized human dermis has gained popularity in SCR surgeries.<sup>6</sup> To date, no clinical study has used the fascia lata allograft for SCR. Using this graft would have some advantages, including decreased patient morbidity, shorter surgical time, and adequate graft resistance.<sup>7</sup>

The aim of the present study is to evaluate the clinical results and healing of SCR. Our hypothesis is that SCR with fascia lata allograft has good clinical results, especially when there is graft healing.

## Materials and Methods

### Study Design and Population Studied

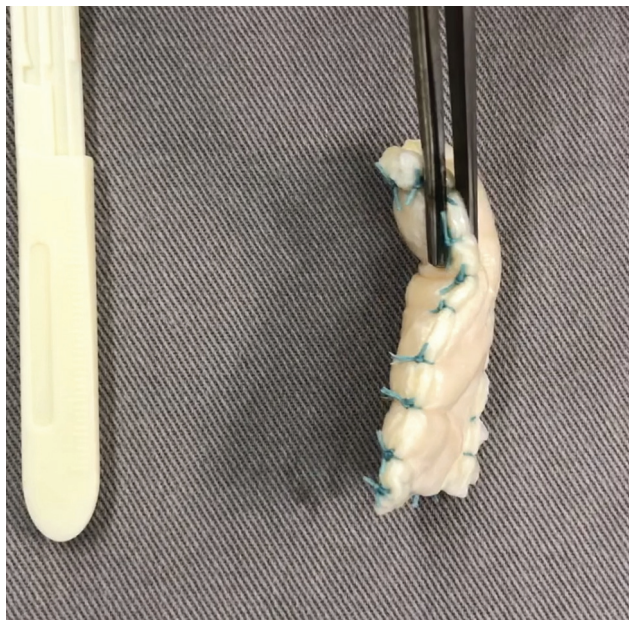
Fifteen patients underwent SCR in a prospective cohort study. All patients were treated in the same institution and agreed to sign the informed consent form (CAAE-62105616.4.0000.0068).

We included patients with symptoms of pain or functional deficit and with a diagnosis of massive tear of the supraspinatus tendon, classified as grade 2, 3 or 4 of fatty degeneration, according to Goutallier et al.<sup>8</sup> In addition, all patients had active external rotation  $> 0^\circ$ .

Patients with full-thickness subscapularis tear with type 3 or 4 fatty degeneration, patients with rotator cuff arthropathy classified as Hamada et al.<sup>9</sup> grade 5, and patients with previous shoulder injuries, such as brachial plexus injuries, proximal fractures of the humerus, and treated for active infection, were not included. Cases in which repair of the supraspinatus tendon was possible or cases in which repair of the subscapularis tendon was not possible were excluded.

### Intervention

The surgeries were performed by the same shoulder and elbow surgeon with 11 years of experience [blinded]. Fascia lata allografts from the tissue bank were used, according to the standard collection protocol of the institution.



**Fig. 1** Fascia lata allograft 8 mm in thickness.

The procedure followed the steps described by Mihata et al.,<sup>4,10</sup> but with a single-row fixation technique, previously described by the authors [blinded]. All cases were operated using an arthroscopic technique with the patient positioned in lateral decubitus with the arm abducted at 30°. Biceps tenotomy, bursectomy and acromioplasty were done in all cases. Subscapular tears were repaired when there was any partial or complete tear. Patients in whom the supraspinatus tendon was repairable were excluded from the study.

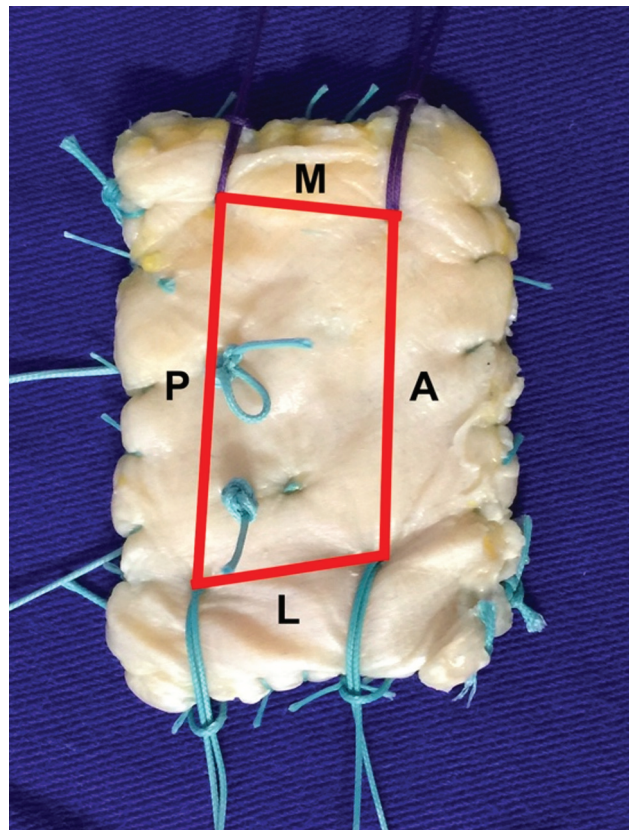
The first step of the SCR consisted of preparing the upper region of the glenoid and greater tuberosity and creating the accessory portals. Two portals, anterosuperior and posterolateral, were made for the insertion of the anchors into the greater tuberosity. The Neviaser portal, which allows the insertion of the posterior anchor into the glenoid and permits graft traction via a double pulley system, was also made. The anterior anchor of the glenoid was introduced through the anterior portal. All the anchors used were 5 mm, metallic, and double-loaded.

Next, a graft of the appropriate size was prepared, having to be folded 3 to 4 times to reach a thickness of 6 to 8 mm (►Fig. 1). The distances between the anchors were used to determine the location of the graft stitches (►Fig. 2).

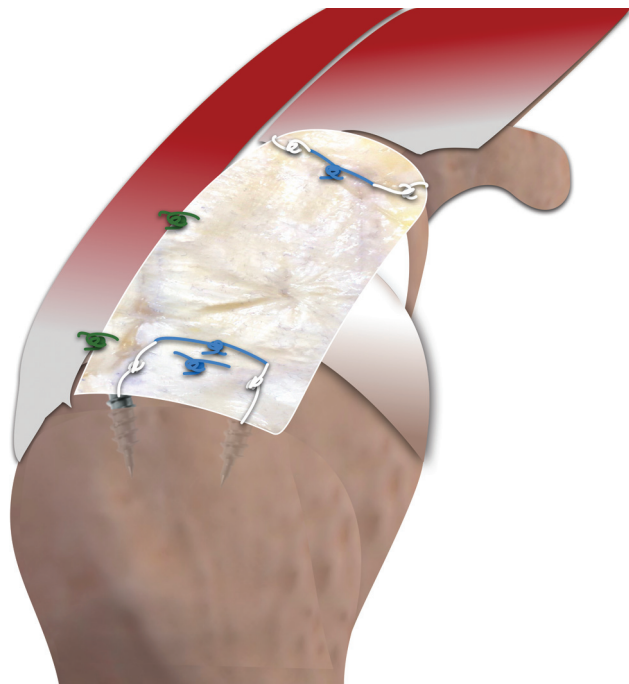
The subsequent step consisted of fixation of the graft to the glenoid by performing an outside-in double pulley suture, in which the graft was pulled by the anchor threads through the medial Neviaser portal. After medial and lateral fixation of the graft, simple sutures were performed between the graft and the infraspinatus tendon<sup>11</sup> (►Fig. 3).

### Postoperative Follow-up

Rehabilitation followed the same protocol as that of rotator cuff repair. Patients were instructed to use an abduction



**Fig. 2** Fascia lata allograft with temporary sutures according to the measurements taken arthroscopically.



**Fig. 3** Final aspect of the superior capsular reconstruction with fascia lata allograft.

pillow sling for 6 weeks. After 4 weeks, the patients underwent passive movement therapy, and active movement

therapy was started after the 6<sup>th</sup> week. Twelve weeks after surgery, exercises to strengthen the rotator cuff and the stabilizing musculature of the scapula were started.

### Outcomes

The ASES scale applied 12 months after surgery was adopted as the primary outcome. The secondary outcomes adopted were the Constant-Murley, UCLA, and SANE scales; active range of motion was assessed with the patient in the standing position. Elevation, external, and internal rotation were evaluated. All measurements were performed with a goniometer, except internal rotation, which was assessed according to the position of the hand of the patient in relation to the vertebral spinous processes and subsequently converted to continuous numbers using a scale from 1 to 19 (T1 to T12 = 1 to 12; L1 to L5 = 13 to 17; sacrum = 18; and greater trochanter = 19). The distance between the acromion and the head of the humerus was evaluated by the Ellman<sup>12</sup> method; assessment of the healing of the graft was performed through MRI 6 months after the procedure; as well as complications and reoperations. The graft was considered “unhealed” when it showed signs of discontinuity in two or more T1- and T2 continuous oblique coronal cuts. The scales and range of motion were assessed by an independent evaluator, and the MRIs were evaluated by a musculoskeletal radiologist.

### Statistical Analysis

We subjected the continuous variables to the evaluation of normality through the Kolmogorov-Smirnov test and of homogeneity through the Levene test. The continuous data were expressed as mean, median, standard deviation (SD) and interquartile range. The categorical variables were expressed as absolute value and percentage. The comparison between the different variables before and after treatment was performed using the chi-squared or the Fisher exact test for categorical variables and the Wilcoxon test for continuous variables. We used IBM SPSS Statistics for Windows version 21.0 (IBM Corp., Armonk, NY, USA) for data analysis, with a significance level of 5%.

### Results

Twenty patients were initially included for SCR using fascia lata allograft between March 2017 and February 2018. During surgery, 5 patients were excluded from the study after complete rotator cuff repair. No patients were lost to follow-up. Thus, 15 patients received the surgical treatment proposed. The general characteristics of the sample are shown in ► **Table 1**.

The median for the ASES scale increased from a preoperative value of 34.0 to 73.0 at 12 months ( $p = 0.005$ ). The UCLA scale increase from 11.0 to 27.0, the Constant-Murley from 41.0 to 73.0, and the SANE from 50.0 to 70.0 ( $p = 0.001$ ,  $p = 0.005$ , and  $p = 0.046$ , respectively). The values are shown in ► **Table 2**.

The patients presented a statistically significant difference for active range of motion in both elevation ( $p = 0.003$ )

**Table 1** Distribution of the absolute and relative frequencies of the variables intrinsic to the patient

	Cases
Gender, n (%)	
Male	8 (53.3)
Female	7 (46.7)
Age (years old)	
Mean (SD)	60.6 (8.56)
Smoker, n (%)	
Yes	1 (6.7)
Ex-smoker	4 (26.7)
No	11 (66.6)
Diabetes, n (%)	
Yes	4 (26.7)
No	11 (73.3)
Side affected, n (%)	
Right	13 (86.7)
Left	2 (13.3)
Dominant side affected, n (%)	
Yes	15 (100)
No	0 (0)
Previous surgery, n (%)	
Yes	3 (20)
No	12 (80)

Abbreviations: n: number of patients; SD, standard deviation.

**Table 2** Clinical evaluation results according to the ASES, UCLA, Constant-Murley, and SANE scales

	Median	<i>p</i> -value
ASES		
Initial	34	
6 months	72	0.008
12 months	73	0.005
UCLA		
Initial	11	
6 months	24	0.005
12 months	27	0.001
Constant-Murley		
Initial	41	
6 months	66	0.017
12 months	73	0.005
SANE		
Initial	50	
6 months	60	0.231
12 months	70	0.046

Abbreviations: ASES, American Shoulder and Elbow Surgeons; SANE, Single Assessment Numeric Evaluation; UCLA, University of California, Los Angeles.

**Table 3** Active range of motion evaluation

	Median	<i>p</i> -value
Elevation		
Initial	95.0	
6 months	140.0	0.044
12 months	140.0	0.003
External rotation		
Initial	30.0	
6 months	40.0	0.076
12 months	60.0	0.007
Internal rotation		
Initial	10.0	
6 months	10.0	0.398
12 months	10.0	0.624

*p*-value: significance level; \*Internal rotation was converted to continuous numbers. T1 to T12 were equated to values of 1 to 12, L1 to L5 to values of 13 to 17, the sacrum was equated to 18, and the greater trochanter to 19.

and external rotation ( $p=0.007$ ). The values are shown in **Table 3**.

There was an increase in the average acromioclavicular distance from 3.62 mm (SD = 1.4) to 7.04 mm (SD = 1.6).

**Table 4** Relationship between graft healing and Hamada classification<sup>16</sup>

	Not healed		Healed	
	<i>n</i>	%	<i>n</i>	%
HAMADA				
1 + 2	3	37.5	5	62.5
3	2	66.7	1	33.3
4	4	100.0	0	0.0

Abbreviation: *n*, number of patients.

Graft healing occurred in 6 patients (40%) at the 6-month postoperative MRI. Among the patients without healing, there was predominance of Hamada 3 and 4 (66.7%), while among those with healing, there was a predominance of Hamada 1 and 2 (83.3%). **Table 4** shows the distribution of the patients comparing the preoperative Hamada classification and graft healing.

The subgroup analysis comparing cases with and without graft healing showed that cases with healing presented better functional results according to the ASES, UCLA and Constant-Murley scales, and the highest active elevation and internal rotation. The values are presented in **Table 5** and **Table 6**.

No superficial or deep infections, neurological lesions, hematomas, or joint stiffness were reported.

**Table 5** Subgroup analysis for ASES, UCLA, Constant-Murley, and SANE scales according to graft healing

Healing	NO		YES		<i>p</i> -value
	Mean	Median	Mean	Median	
ASES					
Initial	36.1	37.0	39.0	31.5	0.906
6 months	48.1	43.0	86.5	90.0	0.003
12 months	58.0	55.0	87.3	90.0	0.013
UCLA					
Initial	10.5	10.0	13.8	14.5	0.238
6 months	16.1	15.0	29.3	30.0	0.011
12 months	19.7	25.0	30.6	30.0	0.013
Constant-Murley					
Initial	38.0	38.0	54.3	60.5	0.195
6 months	44.7	37.0	74.8	80.0	0.007
12 months	53.3	65.0	75.1	78.5	0.011
SANE					
Initial	57.7	50.0	38.3	35.0	0.210
6 months	53.3	50.0	80.0	80.0	0.023
12 months	66.6	70.0	81.6	85.0	0.188

Abbreviations: ASES, American Shoulder and Elbow Surgeons; SANE, Single Assessment Numeric Evaluation; UCLA, University of California, Los Angeles.

**Table 6** Active range of motion evaluation according to graft healing

	Not healed	Healed	<i>p</i> -value
<b>Elevation (median °)</b>			
Initial	90	148	0.288
12 months	133	175	0.020
<b>External rotation (median °)</b>			
Initial	20	47.5	0.121
12 months	60	67.5	0.159
<b>Internal rotation (median °)</b>			
Initial	12	8.5	0.184
12 months	13	7	0.001

## Discussion

Regarding the clinical outcomes, there was a statistically significant improvement in the ASES scale, with a median preoperative score of 34.0 and a 12-month score of 73.0 ( $p = 0.003$ ). Although all studies show statistically significant improvements, there are some differences in the ASES scale values when compared with the others. Mihata et al.,<sup>4</sup> using autografts, obtained excellent results with the mean ASES scale score increasing from 23.5 to 92.9 in their first published clinical study. In addition, the same authors reported similar results in other subsequently published studies.<sup>13,14</sup> However, Pennington et al.<sup>15</sup> and Burkhart et al.<sup>16</sup> published promising results using decellularized human dermis, but without achieving a mean ASES scale score > 90 points (82 and 89, respectively). Similarly to our study, both Denard et al.<sup>17</sup> and Hirahara et al.<sup>18</sup> achieved statistically significant results with ASES scale values < 80 points (77.5 and 70.7, respectively) using dermal grafts. Improvement in all clinical scores corroborates the results presented in four recently published literature reviews.<sup>19–22</sup>

In the active range of motion assessment, there were improvements both in elevation, which increased from 95 to 140° ( $p = 0.003$ ), and in external rotation, which increased from 30 to 60° ( $p = 0.007$ ). Our results are in line with what has already been published regarding range of motion after SCR, both in studies that used autografts<sup>4,13,23</sup> and in studies that used decellularized human dermis grafts.<sup>15–18</sup>

Regarding the acromiohumeral distance, we observed a mean of 3.62 mm preoperatively and of 7.04 mm postoperatively. This finding is similar to that demonstrated in previous publications with gains that range from 2.6 to 5 mm after surgery.<sup>4,15,18</sup>

In the evaluation of graft healing after 6 months of follow-up, 6 patients (40%) presented complete healing, and 9

patients (60%) showed signs of non-healing. Similarly, in 2018, Denard et al.<sup>17</sup> published a 45% healing rate, while AlRamadhan et al.<sup>24</sup> and Lee et al.<sup>25</sup> reported rates of 69.3 and 63.8%, respectively. However, Mihata et al.<sup>4,13</sup> observed higher rates following SCR, with levels of 83.3 and 93% in studies published in 2013 and 2015. After a systematic review that evaluated a total of 350 cases, Catapano et al.<sup>19</sup> reported a graft healing rate of 87.5%, a finding similar to the rate of 85.8% published by Sochacki et al.,<sup>20</sup> also in a systematic review.

When we correlated the graft healing rate with the preoperative Hamada classification, we observed that of the 9 non-healing patients, 6 (66.7%) were classified as Hamada 3 or 4, while 83.3% of the healing patients were classified as Hamada 1 or 2. Although our sample was small, which diminishes the power of the results, our data corroborate with Denard et al.,<sup>17</sup> who published a healing rate of 75% in Hamada 1 and 2 patients and of only 44% in patients classified as Hamada 3 or 4. These data may help us understand the high healing rates published by Mihata et al. (83.3%),<sup>4</sup> given that only 2 patients in his series of 24 cases were classified as Hamada 3 or 4.

When we evaluated the clinical scores by “healing” and “non-healing” subgroups, we observed that they did not present any preoperative statistical difference. However, at the 12-month follow-up, all scores were statistically higher in the healing group, except for the SANE scale. Similar to the findings described by Denard et al.,<sup>17</sup> who published an ASES mean score of 90.0 in patients with graft healing versus 66.5 in non-healing cases ( $p = 0.027$ ). We also observed a statistically significant difference in the evaluation of active elevation, with a median of 175° in the healed subgroup versus 133° in the unhealed subgroup ( $p = 0.020$ ), a finding similar to that published by Mihata et al.<sup>13</sup> These data suggest that the preoperative Hamada classification may assist in the prognosis and indication of the SCR procedure. Frank et al.,<sup>26</sup> in a literature review, suggested that only patients classified as Hamada 1 and 2 are candidates for SCR, and our study corroborates this suggestion.

As limitations, we can highlight the fact that the present study was noncomparative, with a relatively small sample and short follow-up. However, the sample size is within the average range of the other studies,<sup>4,16,18</sup> and the follow-up time was similar to that published in earlier studies.<sup>15–18,24</sup> In addition, another limitation was the lateral fixation of the graft performed with the single-row technique. However, good results were achieved with the single-row technique, especially in patients with Hamada classification 1 or 2.<sup>24,25</sup>

Even though it has shown satisfactory initial results, SCR is a relatively recent procedure. Further clinical studies are needed to confirm its long-term effectiveness and define the type of patient for this surgery. In addition, the ideal graft and its fixation method also need to be defined.

## Conclusion

Superior capsular reconstruction with allograft fascia lata is a safe procedure that provides clinical improvement to patients. Better results are shown in cases where complete healing of the graft occurs.

### Author's Contributions

Each author contributed individually and significantly to the development of the present article:

RAB: wrote the article; performed the surgeries; data collection; approved the final version.

MECG: wrote the article; performed the surgeries; follow-up of the patients; approved the final version.

EAM: statistical analysis; bibliographic review; approved the final version.

JHA: interpreted the results of the study; bibliographic review; clinical examination; approved the final version.

FBAS: data collection; survey of medical records; follow-up of the patients; approved the final version.

AAFN: participated in the review process; clinical examination; approved the final version.

### Financial Support

There was no financial support from public, commercial, or non-profit sources.

### Conflict of Interests

The authors have no conflict of interests to declare.

## References

- 1 Yamamoto A, Takagishi K, Osawa T, et al. Prevalence and risk factors of a rotator cuff tear in the general population. *J Shoulder Elbow Surg* 2010;19(01):116–120
- 2 Burks RT, Crim J, Brown N, Fink B, Greis PE. A prospective randomized clinical trial comparing arthroscopic single- and double-row rotator cuff repair: magnetic resonance imaging and early clinical evaluation. *Am J Sports Med* 2009;37(04):674–682
- 3 McElvany MD, McGoldrick E, Gee AO, Neradilek MB, Matsen FA 3rd. Rotator cuff repair: published evidence on factors associated with repair integrity and clinical outcome. *Am J Sports Med* 2015;43(02):491–500
- 4 Mihata T, Lee TQ, Watanabe C, et al. Clinical results of arthroscopic superior capsule reconstruction for irreparable rotator cuff tears. *Arthroscopy* 2013;29(03):459–470
- 5 Mihata T, McGarry MH, Pirolo JM, Kinoshita M, Lee TQ. Superior capsule reconstruction to restore superior stability in irreparable rotator cuff tears: a biomechanical cadaveric study. *Am J Sports Med* 2012;40(10):2248–2255
- 6 Tokish JM, Beicker C. Superior capsule reconstruction technique using an acellular dermal allograft. *Arthrosc Tech* 2015;4(06):e833–e839
- 7 Mihata T, Bui CNH, Akeda M, et al. A biomechanical cadaveric study comparing superior capsule reconstruction using fascia lata allograft with human dermal allograft for irreparable rotator cuff tear. *J Shoulder Elbow Surg* 2017;26(12):2158–2166
- 8 Goutallier D, Postel JM, Bernageau J, Lavau L, Voisin MC. Fatty muscle degeneration in cuff ruptures. Pre- and postoperative evaluation by CT scan. *Clin Orthop Relat Res* 1994; (304):78–83
- 9 Hamada K, Fukuda H, Mikasa M, Kobayashi Y. Roentgenographic findings in massive rotator cuff tears. A long-term observation. *Clin Orthop Relat Res* 1990;(254):92–96
- 10 Mihata T, McGarry MH, Kahn T, Goldberg I, Neo M, Lee TQ. Biomechanical Effects of Acromioplasty on Superior Capsule Reconstruction for Irreparable Supraspinatus Tendon Tears. *Am J Sports Med* 2016;44(01):191–197
- 11 Gracitelli MEC, Beraldo RA, Malavolta EA, Assunção JH, Oliveira DRO, Ferreira Neto AA. Superior capsular reconstruction with fascia lata allograft for irreparable supraspinatus tendon tears. *Rev Bras Ortop (Sao Paulo)* 2019;54(05):591–596
- 12 Ellman H, Hunker G, Bayer M. Repair of the rotator cuff. End-result study of factors influencing reconstruction. *J Bone Joint Surg Am* 1986;68(08):1136–1144
- 13 Mihata T, Lee TQ. Clinical Outcomes of Superior Capsule Reconstruction for Irreparable Rotator Cuff Tears without Osteoarthritis in the Glenohumeral Joint. *Journal of Shoulder and Elbow Surgery* 2015;24(04):e107–e109
- 14 Mihata T, Lee TQ, Fukunishi K, et al. Return to sports and physical work after arthroscopic superior capsule reconstruction among patients with irreparable rotator cuff tears. *Am J Sports Med* 2018;46(05):1077–1083
- 15 Pennington WT, Bartz BA, Pauli JM, Walker CE, Schmidt W. Arthroscopic superior capsular reconstruction with acellular dermal allograft for the treatment of massive irreparable rotator cuff tears: short-term clinical outcomes and the radiographic parameter of superior capsular distance. *Arthroscopy* 2018;34(06):1764–1773
- 16 Burkhart SS, Hartzler RU. Superior capsular reconstruction reverses profound pseudoparalysis in patients with irreparable rotator cuff tears and minimal or no glenohumeral arthritis. *Arthroscopy* 2019;35(01):22–28
- 17 Denard PJ, Brady PC, Adams CR, Tokish JM, Burkhart SS. Preliminary results of arthroscopic superior capsule reconstruction with dermal allograft. *Arthroscopy* 2018;34(01):93–99
- 18 Hirahara AM, Andersen WJ, Panero AJ. Superior capsular reconstruction: clinical outcomes after minimum 2-year follow-up. *Am J Orthop (Belle Mead NJ)* 2017;46(06):266–278
- 19 Catapano M, de Sa D, Ekhtiari S, Lin A, Bedi A, Lesniak BP. Arthroscopic superior capsular reconstruction for massive, irreparable rotator cuff tears: a systematic review of modern literature. *Arthroscopy* 2019;35(04):1243–1253
- 20 Sochacki KR, McCulloch PC, Lintner DM, Harris JD. Superior capsular reconstruction for massive rotator cuff tear leads to significant improvement in range of motion and clinical outcomes: a systematic review. *Arthroscopy* 2019;35(04):1269–1277
- 21 Ekhtiari S, Adili AF, Memon M, et al. Sources, quality, and reported outcomes of superior capsular reconstruction: a systematic review. *Curr Rev Musculoskelet Med* 2019;12(02):173–180
- 22 Galvin JW, Kenney R, Curry EJ, et al. Superior capsular reconstruction for massive rotator cuff tears: a critical analysis review. *JBJS Rev* 2019;7(06):e1;1–11
- 23 Mihata T, Lee TQ, Hasegawa A, et al. Arthroscopic superior capsule reconstruction can eliminate pseudoparalysis in patients with irreparable rotator cuff tears. *Am J Sports Med* 2018;46(11):2707–2716

- 24 Al Ramadhan H, Sungjoon L, In-Ho J. Early MRI findings of arthroscopic superior capsule reconstruction (ASCR): how to prevent early failure. *Arthroscopy* 2017;33(06 Suppl):e21
- 25 Lee SJ, Min YK. Can inadequate acromiohumeral distance improvement and poor posterior remnant tissue be the predictive factors of re-tear? Preliminary outcomes of arthroscopic superior capsular reconstruction. *Knee Surg Sports Traumatol Arthrosc* 2018;26(07):2205-2213
- 26 Frank RM, Cvetanovich G, Savin D, Romeo AA. Superior capsular reconstruction: indications, techniques, and clinical outcomes. *JBJS Rev* 2018;6(07):e10; 1-8