



Hepatic Liquoric Cyst as a Complication of Ventriculoperitoneal Shunt Insertion: A Case Report

Lívio Pereira de Macêdo¹ Arlindo Ugulino Netto¹ Kauê Franke¹ Pierre Vansant Oliveira Eugenio²
 Lucas Ribeiro de Moraes Freitas² Davi Coutinho Marcelino Guerra Leone²
 Diego Pereira de Melo Oliveira³ Eduardo Vieira de Carvalho Júnior¹ Igor Vilela Faquini¹
 Nivaldo S. Almeida¹ Hildo Rocha Cirne Azevedo-Filho¹

¹Department of Neurosurgery, Hospital da Restauração, Recife, PE, Brazil

²Centro de Ciências Médicas, Universidade Federal da Paraíba, João Pessoa, PB, Brazil

³Faculdade de Ciências Médicas da Paraíba, João Pessoa, PB, Brazil

Address for correspondence Lívio Pereira de Macêdo, MD, Departamento de Neurocirurgia, Hospital da Restauração, Rua João Fernandes Vieira, 544, Boa Vista, Recife, PE 50050-200, Brasil (e-mail: livio21@gmail.com).

Arq Bras Neurocir 2021;40(4):e408–e411.

Abstract

Background The ventriculoperitoneal shunt (VPS) procedure is still the most used technique for management of hydrocephalus. This article reports a case of hepatic cerebrospinal fluid (CSF) pseudocyst as a rare, but important, complication of the VPS insertion.

Case Description An 18-year-old male presented to the hospital complaining of temporal headache and visual turbidity for approximately 3 months with a history of VPS insertion for treatment of hydrocephalus and revision of the valve in adolescence. The diagnosis was based on abdominal imaging, demonstrating an extra-axial hepatic CSF pseudocyst free from infection. Following the diagnosis, the management of the case consisted in the removal and repositioning of the catheter on the opposite site of the peritoneum.

Conclusion The hepatic CSF pseudocyst is an infrequent complication of VPS procedure, but it needs to be considered when performing the first evaluation of the patient. Several techniques are considered efficient for the management of this condition, the choice must be made based on the variables of each individual case.

Keywords

- ▶ ventriculoperitoneal shunt
- ▶ cerebrospinal fluid pseudocyst
- ▶ hepatic cyst

Resumo

Palavras-chave

- ▶ derivação ventriculoperitoneal
- ▶ pseudocisto de líquido cefalorraquidiano
- ▶ cisto hepático

Introdução O procedimento de derivação ventriculoperitoneal (DVP) ainda é a técnica mais utilizada para o tratamento da hidrocefalia. Este artigo relata um caso de pseudocisto de líquido cefalorraquidiano (LCR) hepático como uma complicação rara, mas importante, da inserção do shunt ventriculoperitoneal (VP).

Descrição do Caso Um homem de 18 anos deu entrada no hospital com queixa de cefaleia temporal e turvação visual há aproximadamente 3 meses, com histórico de inserção da DVP para tratamento de hidrocefalia e revisão da válvula na adolescência. O diagnóstico foi baseado em exames de imagem abdominais, demonstrando um

received
October 14, 2020
accepted
March 9, 2021
published online
August 30, 2021

DOI <https://doi.org/10.1055/s-0041-1732441>.
ISSN 0103-5355.

© 2021. Sociedade Brasileira de Neurocirurgia. All rights reserved. This is an open access article published by Thieme under the terms of the Creative Commons Attribution-NonDerivative-NonCommercial-License, permitting copying and reproduction so long as the original work is given appropriate credit. Contents may not be used for commercial purposes, or adapted, remixed, transformed or built upon. (<https://creativecommons.org/licenses/by-nc-nd/4.0/>)
Thieme Revinter Publicações Ltda., Rua do Matoso 170, Rio de Janeiro, RJ, CEP 20270-135, Brazil

pseudocisto hepático extraaxial de LCR, livre de infecção. Após o diagnóstico, o manejo do paciente se baseou na retirada e reposicionamento do cateter no sítio oposto do peritônio.

Conclusão O pseudocisto hepático de LCR é uma complicação infrequente do procedimento de DVP, mas deve ser considerado na primeira avaliação do paciente. Diversas técnicas são consideradas eficientes para o manejo desta condição, a escolha deve ser feita com base nas variáveis de cada caso individual.

Introduction

Ventriculoperitoneal (VP) shunt remains the most used technique for the treatment of hydrocephalus.¹ With the increased survival of patients undergoing the procedure, we can identify some complications, such as abdominal cysts of cerebrospinal fluid (CSF). These are rare complications of VP shunt, accounting for only 0.25% of all cases with abdominal disorders.^{2,3}

This article aims to report a case of hepatic CSF pseudocyst, an even more unusual example of abdominal complications after a VPS procedure, in which there was perforation of a massive organ. The literature review performed was based on PubMed, using the keywords and Boolean operators *VP shunt complications* OR *ventriculoperitoneal shunt* AND *hepatic pseudocyst* OR *CSF pseudocyst* OR *intrahepatic cyst*, restricting the search to articles in the English language. No other limitations were included, and less than 50 cases reporting this condition in the past 20 years were found.

Case Report

TJC, male, 18 years old, with VPS since childhood due to hydrocephalus of idiopathic etiology, with history of revision of the valve in adolescence, presented to the neurology service of Hospital da Restauração, in Recife, Brazil, in August 2020. The patient complained of severe temporal headache associated with visual turbidity for approximately 3 months. He brought a recent brain computed tomography (CT) scan with no abnormalities. Despite this, the examination of the eye fundus already showed papilledema, with visual acuity of 20/20 bilaterally.

In a detailed investigation, it was evidenced that the patient had visual turbidity associated with abdominal pain. Therefore, a new brain CT scan without contrast was requested, which did not show lesions or signs of hydrocephalus and, additionally, a brain magnetic resonance imaging (MRI) was performed, which showed no signs of aqueduct stenosis (►Fig. 1). For better investigation, the patient underwent abdominal CT and evaluation by the ophthalmology and general surgery teams. On the abdominal CT scan, the presence of an intrahepatic abdominal catheter was observed, forming a hepatic pseudocyst of intracapsular CSF, due to the probable entry of the distal VPS catheter through the hepatic capsule (►Fig. 2).

The surgical management of the patient was performed with removal of the catheter from the liver capsule and repositioning of the catheter, intraperitoneally, in another

site at the same surgical time, due to the absence of signs of infection in surgery. Venous antibiotic therapy (vancomycin and ceftriaxone) was performed for 14 days. The patient evolved with stability and a positive prognosis. Control abdominal CT was performed 8 days after the surgery, showing resorption of more than 70% of the hepatic cyst without need for further interventions (►Fig. 3). The patient stayed in the hospital for 20 days, and was dismissed without any complications.

Discussion

The set of abdominal cysts are a well-recognized but uncommon complications of the VPS procedure.⁴ However, the hepatic CSF pseudocyst is an even less frequent condition classified into intraaxial or extraaxial cases. Intraaxial cysts happen when the tip of the shunt is lodged in the liver and causes the cyst to grow within the organ parenchyma.⁵ Similar to the case reported, extraaxial cysts develop when there is a migration of the distal catheter through the Glisson capsule, resulting in the subcapsular accumulation of CSF.⁶ In addition, a case report described a cyst whose smaller part

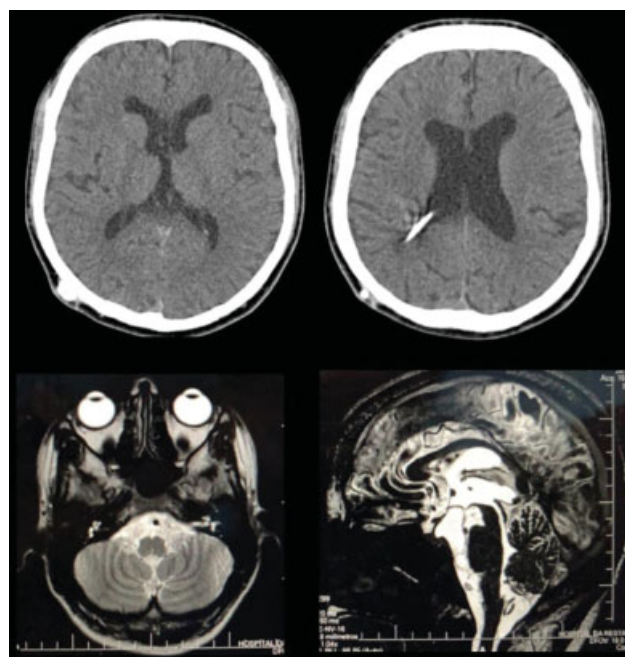


Fig. 1 Brain computed tomography scan without contrast showing no lesions or signs of hydrocephalus (upper). Brain magnetic resonance imaging showing no fossa posterior.

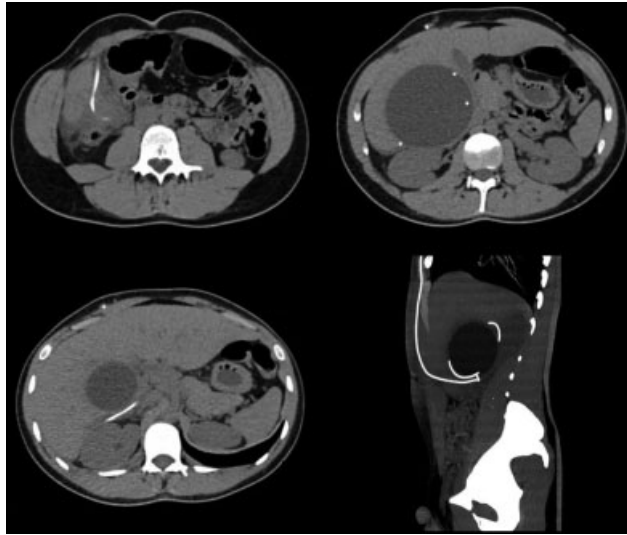


Fig. 2 Abdominal computed tomography scan showing an hepatic pseudocyst of intracapsular cerebrospinal fluid, due to the probable entry of the distal ventriculoperitoneal shunt catheter through the hepatic capsule

was inside the parenchyma and the largest part outside, configuring a case of juxtahepatic CSF cyst.⁷

There are several etiologies for the development of hepatic CSF pseudocysts. Among the possible etiologies, sterile or infected inflammatory processes, such as peritonitis, reactions against foreign bodies, and irritation of the peritoneum due to continuous exposure to CSF,⁸ were considered the most common phenomena that could cause this condition by destabilizing the capsular structure of the liver.⁹ Furthermore, intraperitoneal fibrosis has a great role in the perforation process as it promotes the fixation of the tip of the distal catheter and the continued mechanical irritation of the organ's periphery. Among other causes, multiple revisions of the shunt in the abdomen as well as prior surgeries in that location, CSF malabsorption, and history of intracranial tumor are factors that predispose the formation of abdominal and hepatic pseudocysts.^{10,11}

Image findings are essential for the diagnosis of this condition. Ultrasound examination, because it is simple, economical, and provides satisfactory diagnosis results, is the most advisable method for the first evaluation in most cases. In contrast, abdominal CT ensures an accurate diagnosis, especially when the CSF cyst grows to the point of deforming the normal internal configuration of the abdomen^{12,13} or its growth is extraaxial, in which the liver tissue cannot be identified in the periphery of the cyst. With the CT exam, it is possible to make differential diagnoses of conditions that mimic the hepatic CSF pseudocyst symptoms (to exemplify, appendicitis, diverticulitis, volvulus, among others). Finally, it is emphasized that the efficient interpretation of the neurological deficits presented by the patient is indispensable.

Various types of treatment approaches have been reported in the analyzed literature; however, only one case has experienced recurrence.⁸ Due to the scarcity of cases and the fact that the treatment depends on the patient's particular characteristics as well as on the surgeon's experience and

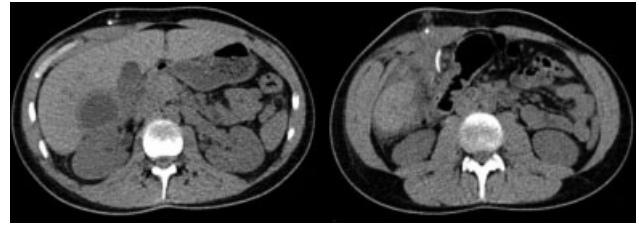


Fig. 3 Control abdominal computed tomography scan showing resorption of more than 70% of the hepatic cyst

findings during the procedure, there is no consensus in the treatment of the hepatic CSF pseudocyst. After the possible infection is treated,¹⁴ the most common procedures include 6 main categories (1) removal of the primary shunt, placement of external ventricular shunt (EVD) followed by VP shunt insertion^{15,16}; (2) removal of the primary shunt, placement of the EVD, followed by the insertion of a ventriculoatrial shunt (VAS)^{17,18}; (3) removal of the primary shunt and conversion to VAS¹⁹; (4) repositioning of the distal catheter to the opposite side of the peritoneum^{18,20}; (5) exploratory laparotomy, removal of the primary shunt, EVD followed by VAS or VPS^{17,21}; (6) other treatment modalities, such as aspiration, paracentesis or excision of the pseudocyst.²²⁻²⁴ In the case demonstrated in this report, due to the absence of infection and spontaneous resorption of > 70% of the CSF pseudocyst, the management was repositioning the distal catheter on the opposite site of the peritoneum.

Conclusion

The present case report describes a rare complication of the VPS technique. Hepatic CSF pseudocysts should be suspected in patients with a history of surgery for shunt placement for hydrocephalus treatment, and the diagnostic approach should be based on ultrasound and abdominal CT scans. In the reported case, after confirming the absence of infection and the natural resorption of the cyst, the surgical procedure chosen was to reposition the catheter on the opposite side of the peritoneum.

Conflict of Interests

The authors report no conflict of interests.

References

- 1 Limbrick DD Jr, Baird LC, Klimo P Jr, Riva-Cambrin J, Flannery AMPediatric Hydrocephalus Systematic Review and Evidence-Based Guidelines Task Force. Pediatric hydrocephalus: systematic literature review and evidence-based guidelines. Part 4: Cerebrospinal fluid shunt or endoscopic third ventriculostomy for the treatment of hydrocephalus in children. *J Neurosurg Pediatr* 2014;14(Suppl 1):30-34. Doi: 10.3171/2014.7.PEDS14324
- 2 Lortat-Jacob S, Pierre-Kahn A, Renier D, Hirsch JF, Martelli H, Pellerin D. [Abdominal complications of ventriculo-peritoneal shunts in children. 65 cases]. *Chir Pediatr* 1984;25(01):17-21
- 3 Dabdoub CB, Fontoura EA, Santos EA, Romero PC, Diniz CA. Hepatic cerebrospinal fluid pseudocyst: A rare complication of ventriculoperitoneal shunt. *Surg Neurol Int* 2013;4:162

- 4 Anderson CM, Sorrells DL, Kerby JD. Intraabdominal pseudocysts as a complication of ventriculoperitoneal shunts. *J Am Coll Surg* 2003;196(02):297–300
- 5 Chitkara N, Gupta R, Singla SL, Sharma NK. Lower end of ventriculoperitoneal shunt embedding in liver parenchyma. *Neurol India* 2004;52(03):405
- 6 Wang F, Miller JH. Cerebrospinal fluid pseudocyst presenting as a hepatic mass: a complication of ventriculoperitoneal shunt. *Pediatr Radiol* 1989;19(05):326–327
- 7 Verma A, Mohan S, Gupta A. Ventriculo-peritoneal shunts can cause liver injury, juxta and intrahepatic pseudocysts: imaging findings and review of literature. *Clin Neurol Neurosurg* 2012;114(04):389–391
- 8 Berkmann S, Schreiber V, Khamis A. Recurrent intrahepatic dislocation of ventriculoperitoneal shunt. *Minim Invasive Neurosurg* 2011;54(02):83–86
- 9 de Aquino HB, Carelli EF, Borges Neto AG, Pereira CU. Nonfunctional abdominal complications of the distal catheter on the treatment of hydrocephalus: an inflammatory hypothesis? Experience with six cases. *Childs Nerv Syst* 2006;22(10):1225–1230
- 10 Mobley LW III, Doran SE, Hellbusch LC. Abdominal pseudocyst: predisposing factors and treatment algorithm. *Pediatr Neurosurg* 2005;41(02):77–83. Doi: 10.1159/000085160
- 11 Kaplan M, Ozel SK, Akgun B, Kazez A, Kaplan S. Hepatic pseudocyst as a result of ventriculoperitoneal shunts: case report and review of the literature. *Pediatr Neurosurg* 2007;43(06):501–503
- 12 Faraj W, Ahmad HH, Mukherji D, Khalife M. Hepatic cerebrospinal fluid pseudocyst mimicking hydatid liver disease: a case report. *J Med Case Reports* 2011;5:475
- 13 Hsieh CT, Pai CC, Tsai TH, Chiang YH, Su YH. Hepatic cerebrospinal fluid pseudocyst: a case report and review of the literature. *Neurol India* 2006;54(01):86–88
- 14 Arsanious D, Sribnick E. Intrahepatic Cerebrospinal Fluid Pseudocyst: A Case Report and Systematic Review. *World Neurosurg* 2019;125:111–116. Doi: 10.1016/j.wneu.2019.01.150
- 15 Fischer EG, Shillito J Jr. Large abdominal cysts: a complication of peritoneal shunts. Report of three cases. *J Neurosurg* 1969;31(04):441–444
- 16 Gaskill SJ, Marlin AE. Pseudocysts of the abdomen associated with ventriculoperitoneal shunts: a report of twelve cases and a review of the literature. *Pediatr Neurosci* 1989;15(01):23–26, discussion 26–27
- 17 Gutierrez FA, Raimondi AJ. Peritoneal cysts: a complication of ventriculoperitoneal shunts. *Surgery* 1976;79(02):188–192
- 18 Hahn YS, Engelhard H, McLone DG. Abdominal CSF pseudocyst. Clinical features and surgical management. *Pediatr Neurosci* 1985-1986;12(02):75–79
- 19 Burchianti M, Cantini R. Peritoneal cerebrospinal fluid pseudocysts: a complication of ventriculoperitoneal shunts. *Childs Nerv Syst* 1988;4(05):286–290. Doi: 10.1007/BF00271925
- 20 Egelhoff J, Babcock DS, McLaurin R. Cerebrospinal fluid pseudocysts: sonographic appearance and clinical management. *Pediatr Neurosci* 1985-1986;12(02):80–86. Doi: 10.1159/000120224
- 21 Grosfeld JL, Cooney DR, Smith J, Campbell RL. Intra-abdominal complications following ventriculoperitoneal shunt procedures. *Pediatrics* 1974;54(06):791–796
- 22 Davidson RI, Lingley JF. Intraperitoneal pseudocyst: treatment by aspiration. *Surg Neurol* 1975;4(01):33–36
- 23 Gebarski KS, Gebarski SS, McGillicuddy JE. Cerebrospinal fluid abdominal cyst. Computed tomographic resolution of a sonographic dilemma. *Surg Neurol* 1984;21(04):414–416. Doi: 10.1016/0090-3019(84)90123-x
- 24 Norfray JF, Henry HM, Givens JD, Sparberg MS. Abdominal complications from peritoneal shunts. *Gastroenterology* 1979;77(02):337–340