


# Magnetic Resonance Arthrography of the Wrist: The Impact on Operative Management of Wrist Injuries

Glenn E. Lee, MD<sup>1,2</sup>  Grace L. Forster, BS<sup>3</sup> Aaron M. Freilich, MD<sup>1,2</sup> Brent R. DeGeorge Jr., MD, PhD<sup>1,2</sup>

<sup>1</sup> Department of Plastic Surgery, University of Virginia, Charlottesville, Virginia

<sup>2</sup> Department of Orthopaedic Surgery, University of Virginia, Charlottesville, Virginia

<sup>3</sup> University of Virginia School of Medicine, Charlottesville, Virginia

**Address for correspondence** Glenn E. Lee, MD, Department of Orthopaedic Surgery, Virginia Commonwealth University Health, 1200 E Broad St, 9th Floor, Box 980153, Richmond, VA 23298 (e-mail: glenn.lee@vcuhealth.org).

J Wrist Surg 2022;11:120–126.

## Abstract

**Background** There is no consensus on the utility of arthrography in the evaluation of wrist injuries. This study evaluates ordering trends of different types of magnetic resonance imaging (MRI) of the wrist and compares rates of surgery following these imaging modalities.

**Methods** A national claims-based database was used to identify patients who underwent MRI within 90 days of a first-instance diagnosis of wrist injury from 2010 to 2018. The utilization of MRI without intravenous (IV) contrast, MRI with IV contrast, and MRI with arthrogram was investigated. The instances of operative procedures of the wrist within 1 year of MRI study were recorded. Patient demographics, comorbidities, type of operative procedure, and ordering physician specialty were obtained. Logistic regression analysis was used to evaluate the utilization of MRI and subsequent 1-year operative intervention rates as well as association of patient-related factors.

**Results** Magnetic resonance arthrography use was associated with higher rates of subsequent operative treatment. Surgeons were more likely to order an arthrogram at the time of MRI. Younger patients were more likely to undergo MRI-based advanced imaging.

**Conclusion** Surgeons may perceive MRA of the wrist to play an important role in operative decision-making following wrist injury.

**Level of Evidence** This is a Level III, retrospective cohort study.

## Keywords

- ▶ Magnetic Resonance Imaging
- ▶ arthrography
- ▶ arthroscopy
- ▶ wrist

The prevalence of wrist pain has been reported to be up to 4.2% in the general population and even higher in athletes and manual laborers.<sup>1</sup> Despite its relatively high prevalence, diagnosing the etiology of wrist pain can be challenging to the clinician, and often times, advanced imaging is obtained to supplement patient evaluation and aid in diagnosis. Wrist arthroscopy is the gold standard in the diagnosis of wrist ligament pathologies.<sup>2–5</sup> Nonetheless, magnetic resonance imaging (MRI) is more widely utilized, as it is significantly

less invasive than surgery and can be ordered by surgeons and nonsurgeons alike.

Previous studies have demonstrated that magnetic resonance arthrography (MRA) has higher sensitivity and specificity over conventional MRI in the diagnosis of soft-tissue injuries of the wrist.<sup>4,6–8</sup> Pahwa et al demonstrated that MRA has 100% sensitivity, specificity, positive predictive value, negative predictive value, and accuracy in detecting triangular fibrocartilage complex (TFCC), scapholunate interosseous

received

May 22, 2021

accepted after revision

July 27, 2021

published online

October 5, 2021

© 2021, Thieme. All rights reserved.  
Thieme Medical Publishers, Inc.,  
333 Seventh Avenue, 18th Floor,  
New York, NY 10001, USA

DOI <https://doi.org/10.1055/s-0041-1735305>  
ISSN 2163-3916.

ligament (SLIL), and lunotriquetral interosseous ligament (LTIL) injuries when compared to diagnostic arthroscopy as the reference standard.<sup>9</sup> However, these findings are not universally accepted among other studies.<sup>3,10</sup>

Despite the presence of evidence to suggest that MRA offers improved diagnostic accuracy over conventional MRI, it remains unclear if its use results in findings that ultimately guide treatment—specifically, the decision to proceed with operative management. To this end, we queried a large, national insurance claims database to identify trends in the utilization of MRI with and without contrast or MR arthrogram in patients following wrist injury, and investigated the rates of subsequent open or arthroscopic wrist procedures. We sought to examine national trends of ordering wrist MRI with and without contrast and arthrography, patient-related factors that may influence obtaining one study over the other, differences between surgeons and non-surgeons in the types of studies ordered, and whether use of contrast or arthrography correlates to higher rates of surgical treatment. We hypothesized that surgeons were more likely to utilize MR arthrography and that obtaining an MR arthrogram would be associated with higher rates of operative intervention when compared to conventional MRI.

## Methods

A commercially available, proprietary, national insurance claims-based database, PearlDiver Patients Records Database ([www.pearldiverinc.com](http://www.pearldiverinc.com); PearlDiver Inc., Colorado Springs, CO) was queried to identify patients who received an MRI study after and within 90 days of a first-instance diagnosis of a wrist injury from 2010 and 2018. This database contains patient records, which are deidentified, anonymous, and compliant with the privacy rules of the Health Information Portability and Accountability Act, and were therefore exempted from approval by an institutional review board.

The database contains patient demographics, comorbidities, and diagnoses and procedural coding, among numerous other data. This database may be queried via International Classification of Diseases, 9th Revision (ICD-9) and 10th Revision (ICD-10) and procedures or Current Procedural Terminology (CPT) codes. The database includes over 122 million distinct United States patients insured from 2010 to 2018, and patients can be tracked across all locations (inpatient, outpatient, etc.) throughout the database years. The database includes both commercial and government-funded insurance types.

CPT codes were used to identify patients who underwent MRI without contrast, MRI with contrast, or MRI with contrast and a documented injection procedure for an arthrogram (–Table 1). Patients were excluded for absence of valid age or gender information, or absence of a documented MRI after or within 90 days from wrist injury. Patients were excluded if they were not active in the database for 1 year after the MRI study was obtained.

Primary endpoints of the study were the utilization of MRI with or without contrast and with or without an arthrogram following a diagnosed wrist injury and whether this differed between different specialties. Secondary endpoints of the study included the rates of subsequent open or arthroscopic wrist procedures within 1 year of the MRI study. Demographic data on age, gender, comorbidities, procedures, and ordering physician specialty were reported (–Table 2).

R Project for Statistical Computing software (<https://www.r-project.org/>), available through the PearlDiver database, was used for all statistical analyses. Epidemiologic data was analyzed to report descriptive statistics, as appropriate. Logistic regression analysis was utilized to evaluate the association of patient-related risk factors, including demographic variables and comorbidities, with the utilization of MRI and subsequent 1-year operative intervention rates. Odds ratios (OR) were calculated from the regression

**Table 1** Definitions

	CPT or ICD-9/ICD-10 codes
Magnetic resonance imaging	
without contrast	CPT-73221
with contrast	CPT-73222
wrist arthrogram injection	CPT-25246
Condition	
Wrist injury	ICD-9-D-84200: ICD-9-D-84209, ICD-10-D-S63501A: ICD-10-D-S6392XS
Procedures	
Wrist arthroscopy	CPT-29840, CPT-29843, CPT-29844, CPT-29845, CPT-29846, CPT-29847
Open wrist procedures	CPT-25085, CPT-25100, CPT-25101, CPT-5105, CPT-25107, CPT-25210, CPT-25215, CPT-25230, CPT-25240, CPT-25230, CPT-25332, CPT-25337, CPT-25360, CPT-25390, CPT-25441, CPT-25442, CPT-25446, CPT-25447, CPT-25800, CPT-25805, CPT-25810, CPT-25820, CPT-25825, CPT-25830

Abbreviations: CPT, Current Procedural Terminology; ICD-9, International Classification of Diseases, Ninth Revision; ICD-10, International Classification of Diseases, Tenth Revision.

analysis, and a corresponding 95% confidence interval (CI) and *p*-value was also calculated for each patient-related risk factor. For all statistical calculations, *p* < .05 was considered statistically significant.

## Results

A total of 215,683 patients were identified with a wrist injury, and of these patients, 7331 (3.9%) underwent MRI without contrast, 1172 (0.5%) underwent MRI with contrast, and 941 (0.4%) underwent MRI with contrast and a

documented arthrogram (► **Table 2**). Among patients who had an MRI without contrast, 5.36% (393/7331) and 4.73% (347/7331) underwent open and arthroscopic wrist surgery, respectively. The OR for undergoing subsequent open wrist surgery was 1.0 (95% CI 0.7–1.41) (*p* = .997) and arthroscopic surgery was 0.05 (95% CI 0–0.71) (*p* = 0.031) (► **Tables 3 and 5**).

Among patients who had an MRI with contrast, 9.73% (114/1172) and 14.68% (172/1172) underwent open and arthroscopic wrist surgery, respectively. The OR for undergoing subsequent open wrist surgery was 1.01 (95% CI 0.23–

**Table 2** Demographics and patient factors

	MRI without contrast	MRI with contrast	MRI with arthrogram
Patients	7331	1172	941
Age			
< 40	2441	456	359
40–49	1383	250	208
50–59	1840	283	232
60–69	1095	138	110
70–79	572	45	32
Gender			
Male	2409	453	358
Female	4922	719	583
Year			
2010	827	122	98
2011	985	125	97
2012	1040	179	136
2013	1095	169	139
2014	1182	205	162
2015	1110	171	147
2016	942	160	132
2017	665	123	93
Comorbidities			
Asthma	1202	179	146
Congestive heart failure	268	39	32
Coronary artery disease	895	114	89
Chronic kidney disease	476	51	42
Chronic obstructive pulmonary disease	2064	262	198
Diabetes mellitus	2168	266	214
Hypertension	3500	479	388
Obesity	2402	367	299
Osteoarthritis	3176	462	363
Rheumatoid arthritis	360	36	26
Tobacco use	1800	246	201
Charlson comorbidity index	0.89 ± 1.65	0.67 ± 1.35	0.66 ± 1.35

**Table 3** Operative procedures within 1 year following MRI of wrist

	MRI without contrast	MRI with contrast	MRI with arthrogram
Patients	7331	1172	941
Total procedures	740	286	245
Arthroscopic wrist surgery	347	172	148
Open wrist surgery	393	114	97

**Table 4** OR of MRI following wrist injury

	MRI without contrast		MRI with contrast		MRI with contrast and arthrogram	
	OR (95% CI)	p-Value	OR (95% CI)	p-Value	OR (95% CI)	p-Value
Gender						
Male	1.2 (1.17–1.24)	< 0.001	1.41 (1.32–1.51)	< 0.001	1.22 (1.11–1.34)	< 0.001
Age						
< 30	0.83 (0.77–0.89)	< 0.001	1.04 (0.9–1.21)	0.592	0.84 (0.67–1.05)	0.926
< 40	1.1 (1.04–1.17)	0.001	1.44 (1.27–1.64)	< 0.001	1.59 (1.33–1.9)	0.134
< 50	1.45 (1.37–1.54)	< 0.001	2.09 (1.83–2.39)	< 0.001	1.9 (1.57–2.29)	< 0.001
> 65	0.33 (0.31–0.35)	< 0.001	0.23 (0.19–0.28)	< 0.001	0.18 (0.14–0.23)	< 0.001
Comorbidities						
CCI < 1	0.97 (0.93–1.01)	0.129	1.02 (0.93–1.11)	0.703	1 (0.88–1.15)	< 0.001
CCI > 1	0.99 (0.94–1.05)	0.845	0.99 (0.86–1.14)	0.897	1.04 (0.85–1.28)	0.963
CCI > 3	0.99 (0.91–1.09)	0.906	0.63 (0.45–0.85)	0.004	0.68 (0.42–1.05)	0.672
CCI > 5	0.95 (0.84–1.07)	0.378	1.44 (0.96–2.17)	0.080	1.36 (0.75–2.45)	0.097
Procedure						
Arthroscopic wrist surgery	1.03 (0.73–1.45)	0.874	1.57 (1.01–2.42)	0.044	1.27 (0.75–2.1)	0.005
Open wrist surgery	0.87 (0.69–1.09)	0.223	0.74 (0.55–0.99)	0.043	0.65 (0.46–0.9)	0.367
Consultant						
Hand surgery	3.16 (3.02–3.32)	< 0.001	3.11 (2.83–3.41)	< 0.001	4.57 (4.05–5.15)	< 0.001
Orthopedic surgery	2.47 (2.38–2.57)	< 0.001	2.31 (2.13–2.5)	< 0.001	3.15 (2.82–3.51)	< 0.001

Abbreviations: CCI, Charlson comorbidity index; CI, confidence interval; OR, odds ratio.

Note: Bold values are statistically significant at  $p < 0.05$ .

3.15) ( $p = .992$ ) and arthroscopic surgery was 0.94 (95% CI 0.34–2.17) ( $p = 0.887$ ) (► **Tables 3** and **5**).

Among patients who had an MRA, 10.31% (97/941) and 15.73% (148/941) underwent open and arthroscopic wrist surgery, respectively. The OR for undergoing subsequent open wrist surgery was 0.6 (95% CI 0.17–2.87) ( $p = 0.468$ ) and arthroscopic surgery was 9.88 (95% CI 1.3–49.24) ( $p = 0.010$ ) (► **Tables 3** and **5**).

Patients less than 50 years of age had an OR of 1.45 (95% CI 1.37–2.09) ( $p < 0.001$ ) for getting an MRI without contrast, 2.09 (95% CI 1.83–2.39) ( $p < 0.001$ ) for MRI with contrast, and 1.9 (95% CI 1.57–2.29) ( $p < 0.001$ ) for MRA. Patients greater than 65 years of age had an OR of 0.33 (95% CI 0.31–0.35) ( $p < 0.001$ ) for getting an MRI without contrast, 0.23 (95% CI 0.19–0.28) ( $p < 0.001$ ) for MRI with contrast, and 0.18 (95% CI 0.14–0.23) ( $p < 0.001$ ) for MRA. Mean Charlson comorbidity index (CCI) was  $0.89 \pm 1.65$  for patients who received MRI

without contrast,  $0.67 \pm 1.35$  for MRI with contrast, and  $0.66 \pm 1.35$  for MRA (► **Table 4**).

Approximately 60% of the studies obtained had available information regarding specialty of the ordering physician. Within this subset of data, surgeons (orthopaedic surgery, hand surgery, sports medicine) accounted for 76.01% (3395/4466) of MRI without contrast, 87.02% (610/701) of MRI with contrast, and 87.74% (494/563) of MRA orders. Primary care physicians (family medicine, internal medicine) accounted for 23.98% (1071/4466) of MRI without contrast, 12.98% (91/701) of MRI with contrast, and 12.26% (69/563) of MRA orders (► **Table 6**).

## Discussion

We investigated the utilization of MRI, specifically the use of MR arthrography, in a large, national insurance claims

**Table 5** OR of operative procedures following MRI of wrist

	Open wrist surgery		Arthroscopic wrist surgery	
	OR (95% CI)	p-Value	OR (95% CI)	p-Value
MRI without contrast	1 (0.7–1.41)	0.997	0.05 (0-0.71)	<b>0.031</b>
MRI with contrast	1.01 (0.23–3.15)	0.992	0.94 (0.34-2.17)	0.887
MRI with arthrogram	0.6 (0.17–2.87)	0.468	9.88 (1.3-49.24)	<b>0.010</b>

Abbreviations: CI, confidence interval; OR, odds ratio.  
Note: Bold values are statistically significant at  $p < 0.05$ .

**Table 6** MRI type ordered by specialty

	MRI without contrast	MRI with contrast	MRI with arthrogram
Total studies	7331	1172	941
Studies with specialty info available	4466	701	563
Surgeon	3395	610	494
Orthopaedic surgery	2075	311	246
Hand surgery	1079	221	186
Sports medicine	241	78	62
Primary care	1071	91	69
Family medicine	765	69	52
Internal medicine	306	22	17

database of over 215 683 patients with wrist injuries. We have identified that despite higher utilization rates of non-contrasted MRI following wrist injury, the rates of operative management following MR arthrogram are greater. As anticipated, contrasted MRI was more commonly requested by surgical subspecialists compared to primary care providers. These trends may reflect surgeon preferences for MR arthrography for the diagnosis of specific radiocarpal or intercarpal wrist pathologies.

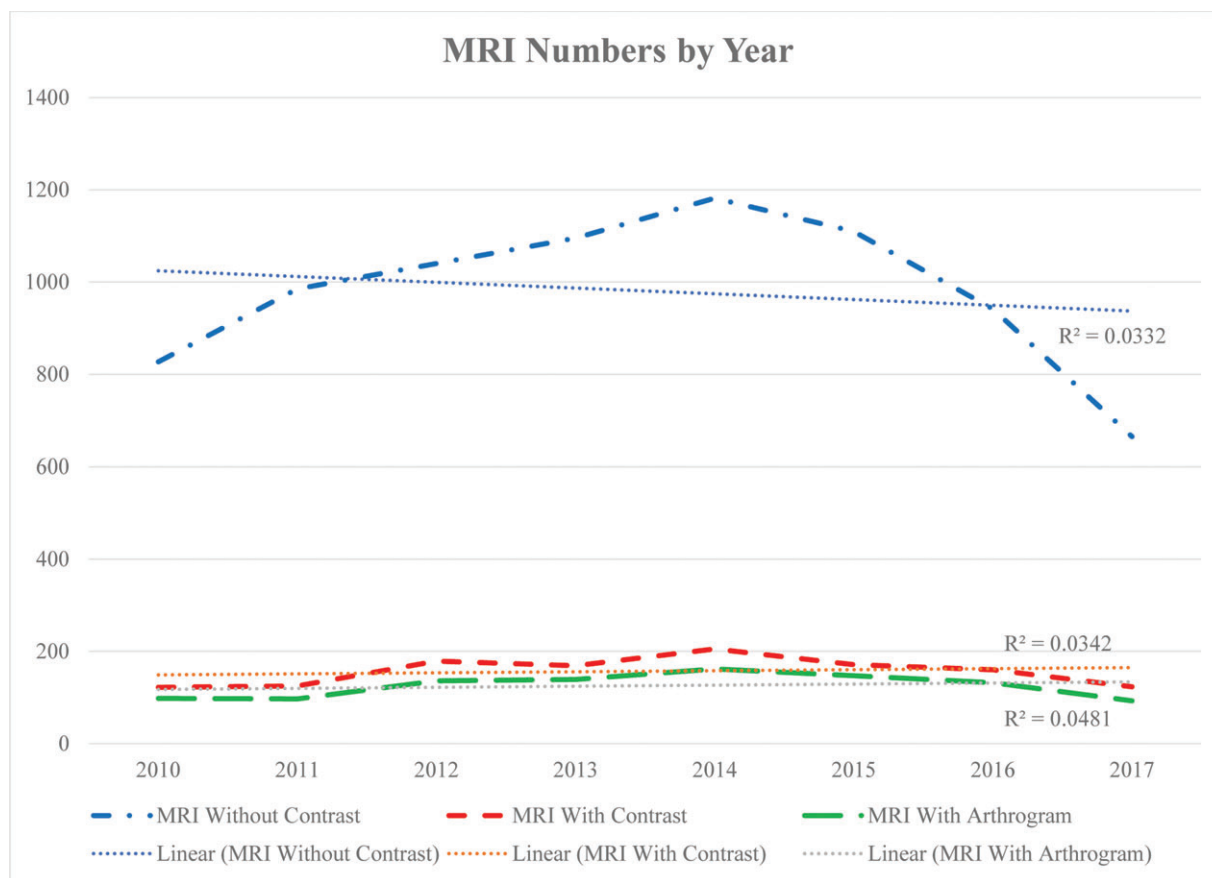
Recent advances in technology including higher resolution images and specific coils have increased the accuracy of conventional MRI.<sup>8</sup> MRA may be more accurate than 1.5-T MRI, but 3-T MRI may be equivalent to 3-T MRA in detecting wrist soft-tissue injuries.<sup>2,7,11</sup> However, some argue that 1.5-T MRI with wrist coils are equivalent to 3-T MRI without dedicated surface coils.<sup>5</sup> There is also a concern for non-pathological microperforations in wrist ligaments, which may yield false positive results with MRA.<sup>7,12</sup> Arthrography also contributes increased risks for patients undergoing the procedure. There have been reports of infection, chemical synovitis, worsening pain, and vasovagal attacks after arthrography.<sup>5</sup>

Smith et al conducted a meta-analysis and systematic review of the diagnostic accuracy of MRI versus MRA for detecting full-thickness TFCC tears. They concluded that while MRA has marginally higher accuracy, the difference in testing performance may not have clinical relevance in influencing decision-making.<sup>8</sup> Boer et al corroborated these results in a more recent study.<sup>4</sup> In contrast, some studies suggest that physical examination and specialized X-ray views have high enough sensitivities and specificities to

diagnose TFCC and SLIL injuries.<sup>3,13</sup> Without a clear-cut consensus in the literature, both MRI and MRA are still broadly utilized in the evaluation of wrist pain.

Even though there are numerous studies comparing the accuracy of MRI versus MRA, there is a paucity of literature assessing whether these studies lead to different rates of surgical intervention. Our study aimed to examine 1) national trends of ordering wrist MRI with and without contrast and arthrography, 2) patient demographics that may impact preference for type of study obtained, 3) differences in the ordering rates of contrasted studies between surgeons and nonsurgeons, 4) and ultimately whether use of contrast or arthrography correlates to higher rates of surgery.

Our study demonstrated that the incidence of obtaining all three types of studies remained relatively stable during the observed time period (►Fig. 1). This follows the trend published by Kanasa-Thanan et al in which the overall utilization of nonspine joint MRI was stable from 2007 to 2015.<sup>14</sup> The type of MRI study, however, did correlate to different rates of surgery within a 1-year time period. Patients who underwent MRA were almost 10 times more likely to have arthroscopic surgery, while those who underwent MRI without contrast were 20 times less likely to have arthroscopic surgery. In Magee's study of 300 patients, 4.67% of patients who had MRI without contrast underwent wrist arthroscopy, compared to 11.67% who had MRA.<sup>7</sup> Similarly, 4.74% of our MRI without contrast group had arthroscopic surgery, compared to 15.73% of our MRA group. The discrepancy between the imaging modalities could be attributed to the higher sensitivity of detecting ligamentous injuries with the addition of arthrography. The addition of intra-articular



**Fig. 1** Number of MRI by type performed between 2010 and 2017.

contrast may reveal findings that warrant surgical treatment and that are not apparent in noncontrast MRI. This may also explain why there were no statistically significant differences in the odds of undergoing open wrist surgery in all three groups. Unlike injuries to the intercarpal ligaments or the TFCC when arthroscopic surgery is frequently utilized, in pathologies for which open surgery is generally performed, such as scaphoid fractures or Kienbock's disease, contrast would not necessarily lead to higher rates of abnormal MRI findings. It is important to consider the distinction between MRI with contrast and MRA in our data set. In many institutions, including ours, it is standard practice to code MRA as a combination of two separate codes: MRI with contrast plus wrist arthrogram. MRI with intravenous (IV) contrast is frequently used in the evaluation of tumors and infections. These conditions are less commonplace than TFCC, SLIL, or LTIL injuries. It is certainly possible that 16% of our patient population underwent MRI with IV contrast. However, on account of the nature of how our data was reported and gathered, it is more likely that the incidence of MRA is underestimated due to wrist arthrogram not being coded or billed for in some of these instances. We speculate that the majority of the MRI with contrast cohort also underwent arthrogram, but we do not currently have the supportive data to confirm that hypothesis. Thus, to prevent the introduction of bias, we did not combine the MRI with contrast and MRA groups for analysis.

Ordering rates of all three types of MRI studies differed between surgical and nonsurgical specialties. Orthopedic surgeons and hand surgeons were more than 2 to 3 times more likely to obtain MRI with and without contrast, and more than 3 to 4 times likely to obtain an MRA. This may be due to referral patterns, where primary care physicians treat wrist pain conservatively and then consult a specialist when symptoms are refractory to nonoperative measures. This phenomenon may be beneficial to patients and the health care system as a whole, because MRI studies ordered by orthopedic surgeons are more likely to be cost-effective and positively influence their ultimate treatment plans.<sup>15</sup> Better knowledge of wrist anatomy and pertinent physical examination findings may also explain the higher utilization of arthrograms among orthopedic and hand surgeons. Surgeons are more inclined to use MRI to confirm a specific injury than to use it as a screening tool for wrist pain,<sup>15</sup> and an arthrogram may better help the surgeon delineate whether a patient requires operative treatment. Additionally, negative results on a highly sensitive test such as an MRA may be helpful in avoiding unnecessary operations.

Patient age also seems to correlate to how often MRIs are obtained during wrist pain workup. Patients less than 50 years of age are almost 1.5 times more likely to undergo MRI without contrast, and twice as likely to get an MRI with contrast or MRA. In contrast, patients greater than 65 years of age are 3 times less likely to undergo MRI without contrast, and 4 times less likely to get an MRI with contrast or MRA.



Surgeons may be dissuaded from obtaining MRIs on older patients to avoid unindicated surgeries, as there is a high prevalence of asymptomatic TFCC tears in patients greater than 50 years of age.<sup>10</sup> In addition, older patients may be more likely to have evidence of degenerative or posttraumatic arthritis on plain radiographs that may preclude further workup with advanced imaging. Even though older patients are more likely to have more comorbid conditions, age as an independent factor seems to play a bigger role than CCI. Overall, the CCI of our patient population was low, probably because the majority of the patients were under 50 years. There were no statistically significant trends on MRI ordering patterns based on CCI.

The primary limitation of our study is that it is retrospective and any correlation cannot be interpreted as causality. Additionally, because the data was gathered from a database, we cannot determine the rationale of why any particular type of MRI was obtained or the choice of nonoperative versus surgical management. We also do not have access to operative reports that could be used to compare imaging and arthroscopic findings. As previously stated, due to uncertainty in billing practices, the number of patients who underwent MRA may be underestimated and many of the MRI with contrast cohort may actually have received an arthrogram as well. The database also relies upon accurate reporting of ICD-9/10 and CPT codes. The Centers for Medicare & Medicaid Services, however, identified only a 1.0% to 1.6% rate of coding errors during our study years.<sup>16</sup> The incidence of coding errors among privately insured patients is unknown. Despite these limitations, the volume and homogeneity of patients in our study population allows us to highlight the potential value of arthrography.

MRI continues to be a widely employed tool in the armamentarium of clinicians in the evaluation and management of wrist pain. Although there is conflicting evidence in the literature on the utility of MR arthrography, higher rates of arthroscopic surgery after MRA in our study suggest that it may play a key role in medical decision-making, at least, for ligamentous injuries. The high percentage of MRAs ordered by surgical subspecialists highlights its perceived importance in diagnosis and ultimate operative management of wrist pathologies.

The database utilized in this study contains deidentified and anonymous patient information, and is compliant with the privacy rules of the Health Information Portability and Accountability Act. Thus, this study was exempted from approval by an institutional review board.

#### Funding

None.

#### Conflict of Interest

None declared.

#### Acknowledgements

The authors would like to thank Marieke Jones, Research Data Specialist at the Claude Moore Health Systems

Library at the University of Virginia for her help with the statistical analysis.

#### References

- 1 Ferguson R, Riley ND, Wijendra A, Thurley N, Carr AJ, Bif D. Wrist pain: a systematic review of prevalence and risk factors- what is the role of occupation and activity? *BMC Musculoskelet Disord* 2019;20(01):542
- 2 Anderson ML, Skinner JA, Felmlee JP, Berger RA, Amrami KK. Diagnostic comparison of 1.5 Tesla and 3.0Tesla preoperative MRI of the wrist in patients with ulnar-sided wrist pain. *J Hand Surg Am* 2008;33(07):1153-1159
- 3 Ruston J, Konan S, Rubinraut E, Sorene E. Diagnostic accuracy of clinical examination and magnetic resonance imaging for common articular wrist pathology. *Acta Orthop Belg* 2013;79(04):375-380
- 4 Boer BC, Vestering M, van Raak SM, van Kooten EO, Huis In 't Veld R, Vochteloo AJH. MR arthrography is slightly more accurate than conventional MRI in detecting TFCC lesions of the wrist. *Eur J Orthop Surg Traumatol* 2018;28(08):1549-1553
- 5 Cherian BS, Bhat AK, Rajagopal KV, Maddukuri SB, Paul D, Mathai NJ. Comparison of MRI & direct MR arthrography with arthroscopy in diagnosing ligament injuries of wrist. *J Orthop* 2019;19:203-207
- 6 Lee RKL, Ng AWH, Tong CSL, et al. Intrinsic ligament and triangular fibrocartilage complex tears of the wrist: comparison of MDCT arthrography, conventional 3-T MRI, and MR arthrography. *Skeletal Radiol* 2013;42(09):1277-1285
- 7 Magee T. Comparison of 3-T MRI and arthroscopy of intrinsic wrist ligament and TFCC tears. *AJR Am J Roentgenol* 2009;192(01):80-85
- 8 Smith TO, Drew B, Toms AP, Jerosch-Herold C, Chojnowski AJ. Diagnostic accuracy of magnetic resonance imaging and magnetic resonance arthrography for triangular fibrocartilaginous complex injury: a systematic review and meta-analysis. *J Bone Joint Surg Am* 2012;94(09):824-832
- 9 Pahwa S, Srivastava DN, Sharma R, Gamanagatti S, Kotwal PP, Sharma V. Comparison of conventional MRI and MR arthrography in the evaluation wrist ligament tears: A preliminary experience. *Indian J Radiol Imaging* 2014;24(03):259-267
- 10 Iordache SD, Rowan R, Garvin GJ, Osman S, Grewal R, Faber KJ. Prevalence of triangular fibrocartilage complex abnormalities on MRI scans of asymptomatic wrists. *J Hand Surg Am* 2012;37(01):98-103
- 11 Ochman S, Wieskötter B, Langer M, Vieth V, Raschke MJ, Stehling C. High-resolution MRI (3T-MRI) in diagnosis of wrist pain: is diagnostic arthroscopy still necessary? *Arch Orthop Trauma Surg* 2017;137(10):1443-1450
- 12 Sutherland JK, Nozaki T, Kaneko Y, et al. Initial experience with 3D isotropic high-resolution 3 T MR arthrography of the wrist. *BMC Musculoskelet Disord* 2016;17(01):30
- 13 Dornberger JE, Rademacher G, Mutze S, Eisenschenk A, Stengel D. Accuracy of simple plain radiographic signs and measures to diagnose acute scapholunate ligament injuries of the wrist. *Eur Radiol* 2015;25(12):3488-3498
- 14 Kanasa-Thanan RM, Nazarian LN, Parker L, Rao VM, Levin DC. Comparative trends in utilization of mri and ultrasound to evaluate nonspine joint disease 2003 to 2015. *J Am Coll Radiol* 2018;15(3 Pt A):402-407
- 15 Michelotti BF, Mathews A, Chung KC. Appropriateness of the use of magnetic resonance imaging in the diagnosis and treatment of wrist soft tissue injury. *Plast Reconstr Surg* 2018;141(02):410-419
- 16 Centers for Medicare & Medicaid Services. 2018 Medicare Fee-for-Service Supplemental Improper Payment Data. 2018