



# Internal Carotid Injury during Transsphenoidal Resection of Pituitary Macroadenoma Managed with Neurointervention Technique

Mohammad Sarwar<sup>1,✉</sup> Laxminarayan Tripathy<sup>1,✉</sup> Sukalyan Purkayastha<sup>2,✉</sup> Gobinda Pramanick<sup>3</sup>

<sup>1</sup>Medica Institute of Neurological Diseases, Medica Superspecialty Hospital, Kolkata, West Bengal, India

<sup>2</sup>Department of Neuroradiology, Institute of Neurosciences, Kolkata, West Bengal, India

<sup>3</sup>Department of Neuroradiology, Apollo Gleneagles Hospital, Kolkata, West Bengal, India

**Address for correspondence** Mohammad Sarwar, MBBS, MS, 6A/1, Ghulam Jilani Khan Road, 3rd floor, Kolkata-700039, West Bengal, India (e-mail: drsarwar262@gmail.com).

Indian J Neurosurg 2021;00:1–3

## Abstract

### Keywords

- ▶ internal carotid artery injuries
- ▶ transsphenoidal surgery
- ▶ pituitary macroadenoma

Iatrogenic internal carotid artery (ICA) injuries during transsphenoidal pituitary tumor surgery are extremely rare but are associated with potentially disabling or life-threatening complications. Management options of ICA injuries are sacrifice, embolization, and endoluminal reconstruction. We report a case of ICA injury during transsphenoidal pituitary macroadenoma surgery, which was managed with endovascular covered stent placement for left carotid-ophthalmic pseudoaneurysm.

Iatrogenic internal carotid artery (ICA) injuries during transsphenoidal pituitary tumor surgery are extremely rare but are associated with potentially disabling or life-threatening complications. Management options of ICA injuries are sacrifice, embolization, and endoluminal reconstruction. We report a case of ICA injury during transsphenoidal pituitary macroadenoma surgery, which was managed with endovascular covered stent placement for left carotid-ophthalmic pseudoaneurysm.

A 28-year-old male patient presented with progressive diminution of vision of both eyes over past 18 months and recent history of dull headache over last 3 months. Magnetic resonance imaging (MRI) was suggestive of a pituitary macroadenoma (size: 2.3 x 2.5 x 2.7 cm) and it was a nonfunctioning one on hormonal screening. MRI showed sellar space occupying lesion with parasellar and suprasellar extension causing compression of optic chiasm and bilateral internal carotid involvement with tortuosity of both ICA. Computed tomography paranasal sinus showed an oblique septum of

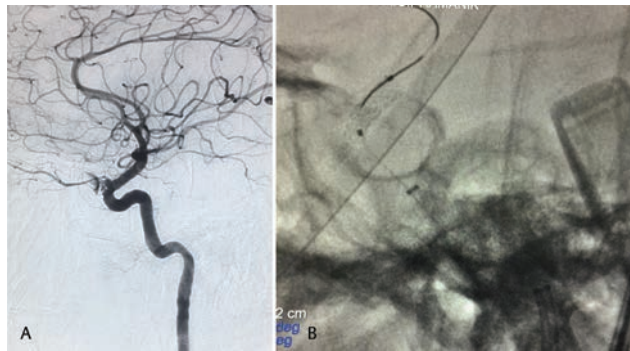
sphenoid sinus to the left of midline. A transnasal transsphenoidal microscopic approach was undertaken after informed consent. At surgery, sellar dura was identified and seen bulging into sphenoid sinus. While enlarging the sella floor and removing the sphenoid septum with 1 mm Kerrison punch, there was sudden profuse arterial bleeding. Bleeding was controlled with muscle, fascia, fat, Surgicel, and Tisseel. Nasal packing was done with Surgicel, Gelfoam, and ribbon gauze. Adequate blood transfusion was given. Surgery was abandoned and patient was transferred to the Cath lab. The left carotid angiogram detected a pseudoaneurysm and there was active leak of contrast from carotid artery into it (▶Fig. 1A). A covered stent was placed across the defect (▶Fig. 1B), which got thrombosed (▶Fig. 2A), in spite of antiplatelet loading with tablet Brilinta (ticagrelor) 90 mg through nasogastric tube 30 minutes before intervention. However, left vertebral artery angiogram revealed filling of left supraclinoid ICA, left middle cerebral artery, and both anterior cerebral arteries. At the end of the procedure, there was nonvisualization of

DOI <https://doi.org/10.1055/s-0041-1735351>  
ISSN 2277-954X

© 2021. Neurological Surgeons' Society of India.

This is an open access article published by Thieme under the terms of the Creative Commons Attribution-NonDerivative-NonCommercial-License, permitting copying and reproduction so long as the original work is given appropriate credit. Contents may not be used for commercial purposes, or adapted, remixed, transformed or built upon. (<https://creativecommons.org/licenses/by-nc-nd/4.0/>).

Thieme Medical and Scientific Publishers Pvt. Ltd. A-12, 2nd Floor, Sector 2, Noida-201301 UP, India



**Fig. 1** (A) Left carotid angiogram showing active leak and pseudoaneurysm from internal carotid artery proximal to the origin of ophthalmic artery. Part (B) showing stent in situ.

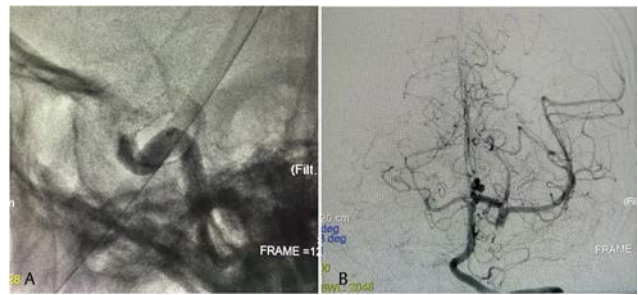
the aneurysmal segment of the left ICA (► **Fig. 2B**). He developed transient right hemiparesis and was dysphasic. He was improving at discharge on the 10th postoperative day.

Hemorrhagic complications during transsphenoidal surgery (TSS) are rare. The reported incidence is 1.1%.<sup>1</sup> On a survey, 20% surgeons experienced a carotid artery injury.<sup>2</sup> The largest single study was reported in 1997 by Raymond et al, who retrospectively identified ICA injuries in 17 (0.9%) of 1800 TSS for pituitary adenoma.<sup>3</sup>

ICA injuries more frequently occurred during TSS for large invasive adenomas.<sup>4,5</sup> The anatomy of the sellar floor is extremely variable, as emphasized by Renn and Rhoton.<sup>6</sup> The variants considered disadvantageous to the transsphenoidal approach and relevant to ICA injury were large anterior intercavernous sinuses extending anterior to the gland just posterior to the anterior sellar wall in 10%, a thin diaphragm in 62%, or a diaphragm with a large opening in 56%, carotid arteries exposed in the sphenoid sinus with no bone over them in 4%, and carotid arteries that approach within 4 mm of midline within the sella in 10%. Hemorrhagic complications are also common in repeat TSS or previously radiated sella. These complications arise due to higher risk of deviation from the midline because of distorted anatomy, more difficult dissection caused by fibrosis after radiation, or prolonged bromocriptine therapy, or may simply reflect an aggressive attempt at complete resection of the lesions invading the cavernous sinus. Anatomic variations of sphenoid sinus such as a honeycomb appearance or absence of pneumatization are well-known pitfalls of TSS. Thus, a strict midline tract is essential to minimize the risk of carotid injuries.<sup>7</sup>

In most of the patients, intraoperative bleeding is initially controlled by vigorous packing, followed by cerebral angiography and subsequent definitive interventional treatment. Packing may be difficult when all bony structures are destroyed by giant invasive grade IV lesions. Overpacking can cause complete ICA occlusion, stenosis, or basilar artery compression that can cause postoperative ophthalmoplegia and optic nerve injury.<sup>5</sup> Fatal delayed epistaxis can occur even after 2 to 10 years of surgery.

Various known complications following iatrogenic ICA injuries are carotid-cavernous fistulas (CCF), carotid stenosis,



**Fig. 2** Part (A) showing stent thrombosis. (B) Left vertebral artery angiogram revealed filling of left supraclinoid internal carotid artery (ICA), left middle cerebral artery, and both anterior cerebral artery from posterior communicating artery and nonvisualization of the aneurysmal segment of the left ICA.

and pseudoaneurysm. Raymond et al<sup>3</sup> recommend balloon occlusion of the carotid artery for CCF, stenosis, and pseudoaneurysm. If a patient fails occlusion test, either by clinical examination or angiography, he has to undergo more aggressive surgical bypass.

Angiography and neurointervention techniques are now universally accepted for iatrogenic ICA injury. Neurointervention techniques are ICA sacrifice by coil placement, lesion embolization by coil or stent-assisted coil placement, or endoluminal reconstruction by flow diverter and/or covered stent.<sup>8,9</sup> Use of Doppler probe for carotid localization and micro-hook blades for lateral dural opening can be used to prevent the devastating complication.<sup>10</sup>

#### Funding

None.

#### Conflict of Interest

None declared.

#### References

- 1 Ciric I, Ragin A, Baumgartner C, Pierce D. Complications of transsphenoidal surgery: results of a national survey, review of the literature, and personal experience. *Neurosurgery* 1997;40(2):225–236, discussion 236–237
- 2 Rowan NR, Turner MT, Valappil B, et al. Injury of the carotid artery during endoscopic endonasal surgery: surveys of skull base surgeons. *J Neurol Surg B Skull Base* 2018;79(3):302–308
- 3 Raymond J, Hardy J, Czepko R, Roy D. Arterial injuries in transsphenoidal surgery for pituitary adenoma; the role of angiography and endovascular treatment. *AJNR Am J Neuroradiol* 1997;18(4):655–665
- 4 Zervas NT, Surgical results for pituitary adenomas: results of an international survey. In: Black PMcL, Zervas NT, Ridgway EC Jr, et al., eds. *Secretary Tumors of the Pituitary Gland*. New York: Raven Press; 1984 377–385
- 5 Laws ER Jr. Vascular complications of transsphenoidal surgery. *Pituitary* 1999;2(2):163–170
- 6 Renn WH, Rhoton AL Jr. Microsurgical anatomy of the sellar region. *J Neurosurg* 1975;43(3):288–298
- 7 Hardy J, McCutcheon IE, Pituitary microadenomas. In: Apuzzo MLJ, ed. *Brain Surgery: Complication Avoidance and Management*. New York, NY: Churchill Livingstone; 1992 276–295

- 8 Sylvester PT, Moran CJ, Derdeyn CP, et al. Endovascular management of internal carotid artery injuries secondary to endonasal surgery: case series and review of the literature. *J Neurosurg* 2016;125(5):1256–1276
- 9 Giorgianni A, Pozzi F, Pellegrino C, et al. Emergency placement of a flow diverter stent for an iatrogenic internal carotid artery injury during endoscopic pituitary surgery. *World Neurosurg* 2019;122:376–379
- 10 Dusick JR, Esposito F, Malkasian D, Kelly DF. Avoidance of carotid artery injuries in transsphenoidal surgery with the Doppler probe and micro-hookblades. *Neurosurgery* 2007;60(4(Suppl2)):ONS322–ONS-328, discussion 328–329