




# Expanding the Spectrum of EEG Periodic Discharges in Subacute Sclerosing Panencephalitis: A Case Report

Iliyana Aleksandrova<sup>1,2</sup>  Asya Asenova<sup>1,2</sup> Daniela Deneva<sup>1,2</sup> Veneta Bojinova<sup>1</sup>

<sup>1</sup> Clinic of Child Neurology, MHATNP "St. Naum," Sofia, Bulgaria

<sup>2</sup> Department of Neurology, Medical University - Sofia, Sofia, Bulgaria

**Address for correspondence** Iliyana Aleksandrova, MD, PhD,  
Department of Neurology, Clinic of Child Neurology, Medical

University of Sofia, University Hospital for Active Treatment of  
Neurology and Psychiatry "St Naum," 1, Ljuben Roussev Street, 1113  
Sofia, Bulgaria (e-mail: iliyana\_@abv.bg).

J Child Sci 2021;11:e245–e249.

## Abstract

**Background** Atypical electroencephalogram (EEG) abnormalities emerge in patients with subacute sclerosing panencephalitis (SSPE), especially in cases with an atypical clinical presentation that can lead to diagnostic difficulties.

**Case Report** In this article, we presented a case of SSPE with an atypical onset with epileptic seizures and Parkinson's features. The neurological examination during the initial evaluation of the patient showed extrapyramidal syndrome, hyperreflexia, intention tremor, and dysmetria. Cranial magnetic resonance imaging was normal. Video EEGs were performed in wakefulness and sleep. In wakefulness, multiple brief seizures (1–1.5 seconds) were recorded, consisting of gradual bending of the body forward and to the right that lacked the sudden characteristic of myoclonia. During those episodes, we recorded generalized epileptiform activity of 4 or 5 sharp waves, with higher amplitude in the anterior regions, in some of the paroxysms superimposed on a slow wave or followed by a high amplitude slow wave. The paroxysms appeared periodically every 15 to 30 seconds. However, 2 months later, the EEG showed typical periodic generalized activity of biphasic/triphasic slow waves (Radermecker complexes), accompanied by myoclonias.

**Conclusion** We reported a peculiar EEG pattern in a patient with SSPE that consists of periodic generalized activity of sharp waves. Atypical EEG patterns can appear when the disease progresses, but initially too, before typical periodic complexes and can complicate the diagnostic process.

## Keywords

- ▶ EEG periodic discharges
- ▶ subacute sclerosing panencephalitis
- ▶ measles

## Introduction

EEG is one of the main tests that leads to the diagnosis of subacute sclerosing panencephalitis (SSPE). The typical EEG pattern consists of bilaterally synchronous and symmetrical diphasic or triphasic high amplitude slow wave 1 to 3 Hz, which appear periodically.<sup>1,2</sup> Many atypical EEG abnormalities emerge,<sup>3,4</sup> especially in cases with an

atypical clinical presentation that can lead to diagnostic difficulties.

## Case Presentation

We presented the case of a 11 years old girl with a normal motor and neuropsychological development, without a history of measles infection, who was vaccinated with measles,

received

May 11, 2021

accepted after revision

July 25, 2021

DOI <https://doi.org/>

10.1055/s-0041-1735536.

ISSN 2474-5871.

© 2021. The Author(s).

This is an open access article published by Thieme under the terms of the Creative Commons Attribution License, permitting unrestricted use, distribution, and reproduction so long as the original work is properly cited. (<https://creativecommons.org/licenses/by/4.0/>)

Georg Thieme Verlag KG, Rüdigerstraße 14, 70469 Stuttgart, Germany

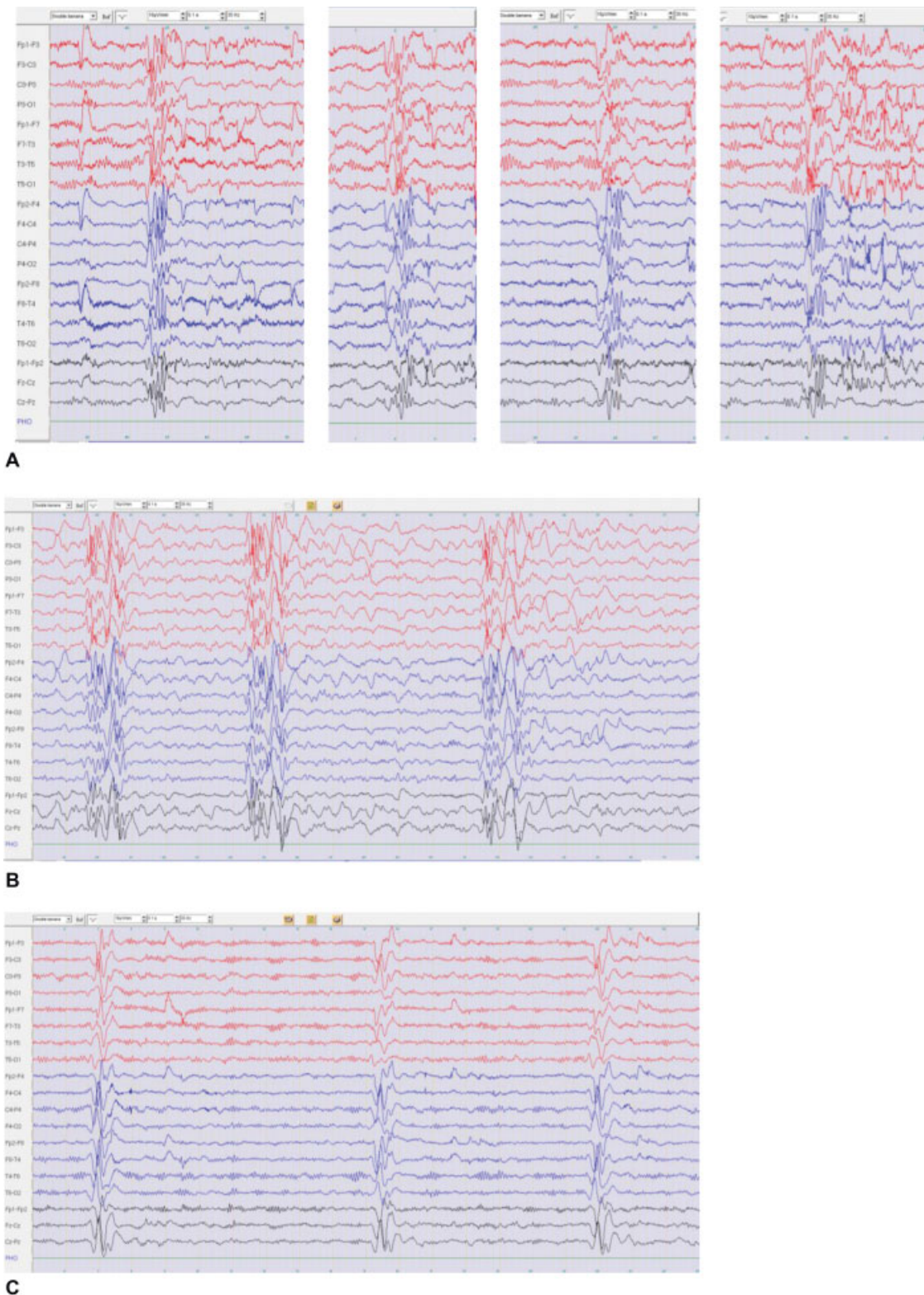
mumps and rubella vaccine when 13 months old, according to the anamnestic data provided by the parents. When 10 years old, she started to experience episodes described as gradual bending of the body and the head forward without falling. Several weeks later, the parents observed behavioral changes: the girl became agitated, cried, and often screamed without reason. Memory and language problems emerged, there was a change of gait and sleep inversion. Overall, 4 months later, because of further deterioration, she was admitted to Child Neurology Clinic. The neurological examination showed an extrapyramidal syndrome with rigidity and cogwheel phenomenon, hyperreflexia, positive Babinski sign, intention tremor, and dysmetria. The patient was able to walk only with assistance, slightly dragging her right leg. There was no physiological synkinesis. The neuropsychological evaluation confirmed severe cognitive decline. Cranial MRI was normal. Video EEGs were performed in wakefulness and sleep. When awake multiple brief seizures (1–1.5 seconds) were observed, consisting of gradual bending of the body forward and to the right. We recorded generalized epileptiform activity of 4 or 5 sharp waves during those episodes, with higher amplitude in the anterior regions, in some of the paroxysms superimposed on a slow wave or followed by a high amplitude slow wave. The paroxysms appeared periodically every 15 to 30 seconds. The background activity consisted of  $\alpha$  rhythm, more prominent, with higher amplitude and unreactive to any stimulus on the left. When falling asleep, the frequency of the generalized paroxysms increased, they appeared with a period of 5 to 8 seconds and each paroxysm was followed by a slight suppression of the activity, a pattern that in some places looked like burst suppression. The slow-wave component of the paroxysms was more pronounced, and there were groups of theta and delta waves in the frontal areas (**►Fig. 1**). No seizures during sleep were recorded. The cerebrospinal fluid analysis showed elevated proteins 0.64 g/L (<0.45 g/L – normal), oligoclonal bands, and positive antimeasles IgG antibody titer – R=4.7 (R>1.1–positive) that confirmed the diagnosis of SSPE. About 2 months later, the parents reported worsening: a tremor of the body, head and limbs, and myoclonic jerks appeared. The EEG showed typical periodic generalized activity of biphasic/triphasic slow waves (Radermecker complexes), accompanied by myoclonias (**►Fig. 1A–C**).

## Discussion

We present a case of SSPE with an atypical onset with epileptic seizures, Parkinson features, and pyramidal syndrome. Parkinson features as an initial clinical manifestation of SSPE is an uncommon finding but not so rare at the advanced stages of the disease.<sup>5,6</sup> Bozlu et al described a 12-year-old boy with an initial clinical picture that led to the diagnosis of juvenile Parkinson disease.<sup>5</sup> The diagnosis of SSPE was suspected after myoclonus appearance and confirmed with the identification of measles antibodies in cerebrospinal fluid. In another two cases reported by Misra et al, Parkinsonism was the presenting syndrome, which followed by myoclonus appearance,

behavioral changes, and intellectual deterioration.<sup>6</sup> Epilepsy, as an initial clinical manifestation of SSPE, has been described in 18 to 32% of the reported cases.<sup>7</sup> Focal seizures are the most common initial seizures, whereas atypical absences, myoclonic-astatic, and atonic seizures and epileptic spasms are rarely reported.<sup>7</sup> Dimova and Bojinova described a case of a 10-year-old boy with atypical absences and myoclonic-astatic seizures as an initial clinical manifestation, which followed by chorioretinitis and a rapid deterioration with the development of severe cognitive deficits.<sup>8</sup> A 2-year-old boy with SSPE initially experienced flexor spasms, followed by myoclonus.<sup>7</sup> Epilepsy in the course of SSPE has been reported in 52 to 76% of the cases.<sup>7</sup> Focal and generalized tonic-clonic seizures in the first year of the disease occurred in one-third of the patients of Kissani et al<sup>9</sup> and in two-thirds of the cases of Jovic et al.<sup>7</sup>

The initial EEG pattern, observed in our patient, is not typical for SSPE as it consists of periodic paroxysmal generalized activity of sharp waves, in some of the paroxysms superimposed on a slow wave or followed by a slow wave. The abundance of sharp waves, according to Demir et al<sup>1</sup>, is more typical when epilepsy is presented, as in our case. Ekmekci et al<sup>3</sup> reported atypical patterns that look like our periodic complexes (PCs) of four to five sharp waves every 2 seconds and prolonged discharges of sharp and slow waves for 4 to 7 seconds followed by suppression. Authors agree that the integrity of the cortex is needed for the appearance of the typical PCs in SSPE and that the progression of the disease leads to gradual waning in the amplitude of the complexes and eventually to their disappearance and isoelectric record in the terminal stages.<sup>2–4</sup> According to Ekmekci,<sup>3</sup> the atypical EEG pattern in their patient was due to the progression of the disease and more severe brain involvement. Unlike their observation, the PCs of several sharp waves in our patient were observed 2 months before the classical PCs appeared. Several other atypical EEG findings in SSPE have been reported: PCs amplitude asymmetry, delta activity in the anterior areas following PCs, focal epileptic discharges, and single cases with periodic lateralized epileptiform discharges (PLEDs).<sup>1–4,10–19</sup> Delta activity, most prominent in the anterior regions, is one of the most common atypical EEG finding<sup>1,4,10,11</sup> and is interpreted as a sign of a diffuse underlying encephalopathic process.<sup>1</sup> Focal epileptiform abnormalities are usually described in the frontal and temporal areas.<sup>1,3,4,10,11</sup> To the best of our knowledge, there is only one report of bioccipital spikes, followed by PCs.<sup>12</sup> The appearance of the focal epileptiform activity is discussed as a sign of cortical involvement.<sup>1</sup> The symmetry of the MRI findings does not seem to affect the symmetry of the PCs as in asymmetric PCs MRI showed both symmetric and asymmetric brain lesions.<sup>1</sup> The appearance of PLEDs<sup>1,4,13,14</sup> usually suggests extensive brain involvement and preferential involvement of one hemisphere.<sup>1</sup> Demir et al<sup>1</sup> described some peculiar findings mimicking hypsarhythmia, the slow spike-and-wave activity seen in Lennox–Gastaut syndrome and low-voltage fast discharges typical for tonic seizures. The atypical EEG finding,<sup>1–4,10–19</sup> described by some of the authors, are summarized in **►Table 1**.



**Fig. 1** Periodic electroencephalogram discharges in a patient with subacute sclerosing panencephalitis. (A) EEG in wakefulness - generalised epileptiform activity of 4 of 5 sharp waves, more prominent in the anterior regions and in some of the paroxysms superimposed on a slow wave of followed by a slow wave. The paroxysms appear periodically every 15 to 30 s. (B) EEG during sleep – lack of normal sleep elements, slow theta and delta waves in the anterior regions and vertex, generalised activity of sharp waves, followed by slow wave that appear every 5 to 8 s. (C) EEG 2 months later - periodic generalised activity of biphasic/triphasic slow waves (Radermecker complexes), fast activity (treatment with clonazepam).

**Table 1** Atypical electroencephalogram findings in patients with subacute sclerosing panencephalitis

No.	Atypical EEG findings in SSPE	Reference
1	<ul style="list-style-type: none"> <li>• Asymmetric PCs</li> <li>• PCs with spikes (focal, bifocal, unilateral, or bilateral)</li> <li>• Periods of short-lasting (1–4 s) suppression following PCs</li> <li>• Rhythmic delta activity between PCs most prominent in frontal regions</li> <li>• Delta activity with posterior localization between the PCs</li> <li>• Focal epileptiform activity mostly in frontal regions</li> <li>• PLED or bilateral periodic lateralized discharges</li> <li>• Electrical activity similar to hypsarrhythmia</li> <li>• Diffuse intermittent or continuous slow spike-and-wave activity as in Lennox–Gastaut or CSWS syndromes</li> <li>• Bilateral paroxysmal discharges, composed of fast activity within 10 to 20 Hz, common for epilepsies with tonic seizures</li> </ul>	Demir et al (2013)
2	<ul style="list-style-type: none"> <li>• Asynchronous and asymmetric PCs</li> <li>• Sharp waves, sharp and slow wave complexes in every 1–2 s</li> <li>• Periodic complexes of four or five sharp waves every 2 s</li> <li>• Prolonged discharges of sharp waves, slow waves for 4–7 s followed by suppression for 1–4 s</li> <li>• Sharp waves, sharp and slow wave complexes at 1–2 Hz in frontal regions</li> </ul>	Ekmekci et al (2005)
3	<ul style="list-style-type: none"> <li>• PLEDs at 1.5–2 Hz frequency intermixed with high amplitude delta activity</li> </ul>	Cherian et al (2009)
4	<ul style="list-style-type: none"> <li>• Focal epileptiform discharges, most frequently in frontal, central and temporal regions, seen prior to PCs or during the intervals between PCs</li> <li>• Delta activity in the anterior regions</li> <li>• Asymmetric and asynchronous PCs</li> <li>• PLEDs</li> </ul>	Gurses et al (2000)
5	<ul style="list-style-type: none"> <li>• Asymmetry PCs</li> <li>• Rhythmic delta activity during the intervals between PCs</li> <li>• Electrodecremental period following PCs</li> <li>• Focal abnormalities over frontal and temporal areas disappearance of the focal abnormalities and typical PCs occurrence after diazepam injection</li> <li>• Diffuse sharp wave and sharp-and-slow-wave complexes prominent in frontal areas</li> <li>• High amplitude generalized rhythmic sharp wave activity following PCs that disappeared after intravenous injection of diazepam</li> </ul>	Dogulu et al (1995)
6	<ul style="list-style-type: none"> <li>• Focal paroxysmal abnormality and PLEDs</li> </ul>	Silva et al (1995)
7	<ul style="list-style-type: none"> <li>• Bisynchronous occipital spikes preceding PCs</li> </ul>	Tung et al (1997)
8	<ul style="list-style-type: none"> <li>• PCs with spikes as an initial component</li> <li>• Spikes, sharp waves or triphasic waves over the frontal areas</li> <li>• Asymmetry in PCs or focal PCs</li> <li>• Electrodecremental period following PCs</li> <li>• Rhythmic delta activity during intervals between PCs most prominent in the frontal areas</li> </ul>	Markand and Panszi (1975)
9	<ul style="list-style-type: none"> <li>• Inverse relationship of the PCs frequency to the body temperature</li> </ul>	Farrel et al (1971)
10	<ul style="list-style-type: none"> <li>• Multifocal paroxysmal high amplitude slow waves during the presymptomatic stage</li> </ul>	Gimenez-Roldan et al (1981)
11	<ul style="list-style-type: none"> <li>• Periodic generalized bursts of fast waves</li> </ul>	Martinovic et al (1986)
12	<ul style="list-style-type: none"> <li>• Diffuse <math>\alpha</math> waves during sleep</li> </ul>	Yoshikawa et al (1990)
13	<ul style="list-style-type: none"> <li>• Three types of PCs: type I - periodic giant delta waves; type II - periodic giant delta waves intermixed with spikes or fast activity; type III - long spike-wave discharges interrupted by giant delta waves</li> </ul>	Yakub (1996)

Abbreviations: CSWS, continuous spikes and waves during slow sleep; EEG, electroencephalogram; PC, periodic complexes; PLED, periodic lateralized discharges; SSPE, subacute sclerosing panencephalitis.

## Conclusion

We reported a peculiar EEG pattern in a patient with SSPE that consists of periodic generalized activity of sharp waves. Atypical EEG patterns can appear when the disease progresses, but initially too, before typical PCs, and can complicate the diagnostic process. Therefore, expanding the

spectrum of unusual EEG features in SSPE will shorten the time to resolve the cases and prevent misdiagnosis.

## Authors' Contributions

I.A. and V.B. involved in study conception and design. I.A. and A.A. supported in data collection. I.A. and D.D. dedicated to analysis of the EEG and supervised the

manuscript preparation. All authors reviewed the results and approved the final version of the manuscript.

**Funding**  
None.

**Conflict of Interest**  
None declared.

## References

- Demir N, Cokar O, Bolukbasi F, et al. A close look at EEG in subacute sclerosing panencephalitis. *J Clin Neurophysiol* 2013;30(04):348–356
- Gutierrez J, Issacson RS, Koppel BS. Subacute sclerosing panencephalitis: an update. *Dev Med Child Neurol* 2010;52(10):901–907
- Ekmekci O, Karasoy H, Gökçay A, Ulkü A. Atypical EEG findings in subacute sclerosing panencephalitis. *Clin Neurophysiol* 2005;116(08):1762–1767
- Gürses C, Oztürk A, Baykan B, et al. Correlation between clinical stages and EEG findings of subacute sclerosing panencephalitis. *Clin Electroencephalogr* 2000;31(04):201–206
- Bozlu G, Cobanogullari Direk M, Okuyaz C. Subacute sclerosing panencephalitis with parkinsonian features in a child: a case report. *Brain Dev* 2015;37(09):901–903
- Misra AK, Roy A, Das SK. Parkinsonian presentation of SSPE: report of two case. *Neurol Asia* 2008;13:117–120
- Jović NJ. Epilepsy in children with subacute sclerosing panencephalitis. *Srp Arh Celok Lek* 2013;141(7-8):434–440
- Dimova PS, Bojinova VS. Case of subacute sclerosing panencephalitis with atypical absences and myoclonic-atonic seizures as a first symptom. *J Child Neurol* 2004;19(07):548–552
- Kissani N, Ouazzani R, Belaidi H, Ouahabi H, Chkili T. [Epileptic seizures and epilepsy in subacute sclerosing panencephalitis (report of 30 cases)]. *Neurophysiol Clin* 2001;31(06):398–405
- Dogulu CF, Ciger A, Saygi S, Renda Y, Yalaz K. Atypical EEG findings in subacute sclerosing panencephalitis. *Clin Electroencephalogr* 1995;26(04):193–199
- Markand ON, Panszi JG. The electroencephalogram in subacute sclerosing panencephalitis. *Arch Neurol* 1975;32(11):719–726
- Tung SL, Yen DJ, Yiu CH, Chen SJ, Su MS. Unusual electroencephalographic findings in subacute sclerosing panencephalitis: a case report. *Brain Dev* 1997;19(03):222–225
- Cherian A, Sreedharan S, Raghavendra S, Nayak D, Radhakrishnan A. Periodic lateralized epileptiform discharges in fulminant form of SSPE. *Can J Neurol Sci* 2009;36(04):524–526
- Silva DF, Lima MM, Anghinah R, Zanoteli E, Lima JG. Atypical clinical and electroencephalographic pattern in a patient with subacute sclerosing panencephalitis. *Arq Neuropsiquiatr* 1995;53(02):278–280
- Farrell DF, Starr A, Freeman JM. The effect of body temperature on the “periodic complexes” of subacute sclerosing leuconencephalitis (SSLE). *Electroencephalogr Clin Neurophysiol* 1971;30(05):415–421
- Martinović Z. Periodic generalized bursts of fast waves in subacute sclerosing panencephalitis. *Electroencephalogr Clin Neurophysiol* 1986;63(03):236–238
- Yaqub BA. Subacute sclerosing panencephalitis (SSPE): early diagnosis, prognostic factors and natural history. *J Neurol Sci* 1996;139(02):227–234
- Yoshikawa H, Takanashi A, Fukushima N, Sakuragawa N, Arima M. [Paradoxical alpha waves seen in the course of subacute sclerosing panencephalitis]. *No To Hattatsu* 1990;22(05):445–450
- Giménez-Roldán S, Martín M, Mateo D, López-Fraile IP. Preclinical EEG abnormalities in subacute sclerosing panencephalitis. *Neurology* 1981;31(06):763–767