



Pulmonary Embolization of Radiolucent Intravenous Cannula: Endovascular Retrieval

Suresh Giragani¹ Manish Kumar Singh¹ Hari kishan Gonuguntla² Swathi Muthyala¹
Surender Alwala³

¹Department of Vascular Interventional Radiology, Yashoda Hospitals, Secunderabad, Telangana, India

²Department of Pulmonology, Yashoda Hospital, Secunderabad, Telangana, India

³Department of Radiology, Yashoda Hospitals, Seunderabad, Telangana, India

Address for correspondence Suresh Giragani, MD, DM, Department of Vascular & Interventional Radiology, Yashoda Hospitals, Alexander Road, Secunderabad, Telangana 500003, India (e-mail: suresh8g@yahoo.com).

Indian J Radiol Imaging 2021;31:1036–1038.

Abstract

Fracture and embolization of peripheral intravenous cannula is very rare. Although endovascular retrieval is the standard of care for most of the embolized intravascular devices, endovascular management of embolized peripheral intravenous cannula is technically difficult due to its radiolucent nature and it is not described previously in the literature. We describe the clinical presentation, imaging findings, and endovascular management in a middle aged male who had fractured peripheral intravenous cannula which was embolized into the pulmonary artery branch. Technical nuances associated with retrieval of this radiolucent little plastic tube have been discussed.

Keywords

- ▶ intravenous cannula
- ▶ pulmonary artery
- ▶ endovascular retrieval

Introduction

The placement of peripheral Intravenous cannula is very common practice in medicine. The risk of fracture of intravenous cannula is a rare occurrence and embolization of fractured fragment is very rare.¹ Endovascular removal of fractured central venous catheters and port devices has been well described.² Previously reported cases of embolized fractured peripheral intravenous cannula were managed by surgical technique.^{3,4} Endovascular retrieval of this particular foreign body is technically challenging and it has not been described in the literature. We present a case of accidental fracture of peripheral intravenous cannula tip with embolism into anterior segmental branch of right descending pulmonary artery and its endovascular management.

Case Report

A 55 years male was admitted with fever and pain abdomen at a local hospital. He was managed conservatively with intravenous medications for 7 days. During the time of discharge, when peripheral intravenous cannula was removed from dorsum of right hand it was accidentally broken and only the hub of the cannula was seen exteriorly (▶ **Fig. 1A**). The cannula tip was not palpable superficially in right upper limb. The patient was referred to our center for localization and removal of fractured peripheral intravenous cannula tip. The patient was clinically asymptomatic.

Chest radiograph was unremarkable. Multidetector computed tomography (CT) scan of thorax was done, which revealed a linear hyperdense foreign body in anterior segmental branch of right descending pulmonary artery

published online
December 13, 2021

DOI <https://doi.org/10.1055/s-0041-1735926>.
ISSN 0971-3026.

© 2021. Indian Radiological Association. All rights reserved.

This is an open access article published by Thieme under the terms of the Creative Commons Attribution-NonDerivative-NonCommercial-License, permitting copying and reproduction so long as the original work is given appropriate credit. Contents may not be used for commercial purposes, or adapted, remixed, transformed or built upon. (<https://creativecommons.org/licenses/by-nc-nd/4.0/>)

Thieme Medical and Scientific Publishers Pvt. Ltd., A-12, 2nd Floor, Sector 2, Noida-201301 UP, India

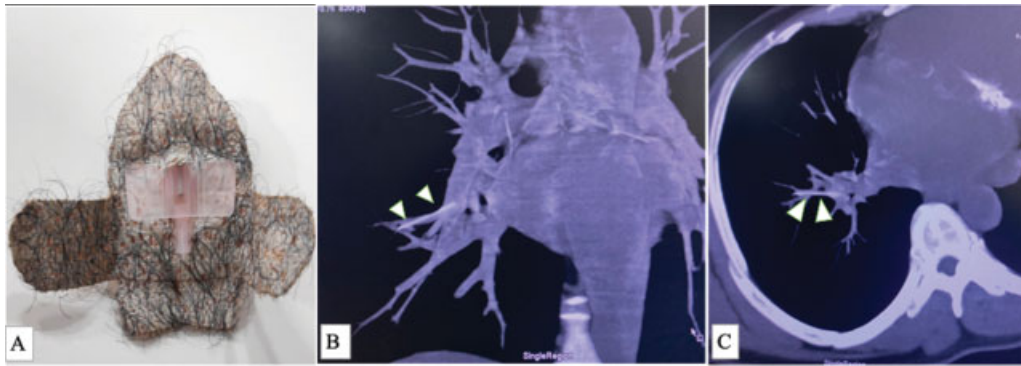


Fig. 1 (A) Proximal residual hub of IV cannula. Maximum intensity projections of the CT thorax in (B) Coronal and (C) axial projections showing a linear hyperdense foreign body embolized into anterior segmental branch of right descending pulmonary artery (arrowheads).

(► **Fig. 1B, C**). After informed consent, patient was taken up for endovascular retrieval of the foreign body.

A right femoral venous access was taken and 8Fr femoral short sheath was placed in right common femoral vein using Seldingers Technique and 3000 IU of unfractionated heparin was administered. Pulmonary angiogram was performed through the right femoral venous access using 5F pigtail catheter. Being radiolucent, localization of plastic cannula tip

was challenging on fluoroscopy. It was localized as a linear radiolucent filling defect (► **Fig. 2A**) in segmental branch during selective angiogram of right descending pulmonary artery. A 15mm Amplatz gooseneck snare (Medtronic peripheral vascular, USA) was introduced through a 5Fr JR-3.5 guiding catheter and the snare loop was positioned across the expected location of the radiolucent foreign body in the right descending pulmonary artery branch (► **Fig. 2B, C**). After couple of

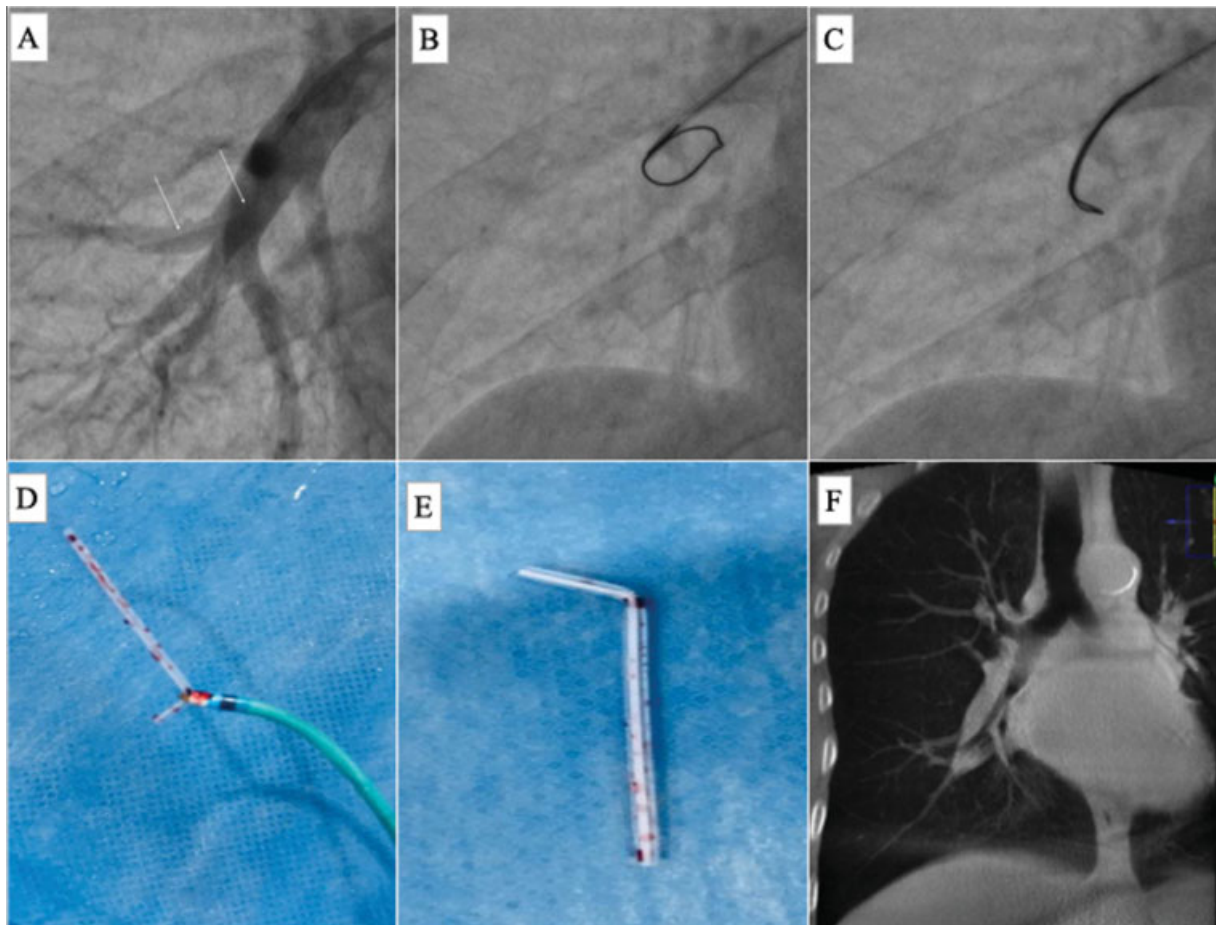


Fig. 2 (A) Pulmonary angiographic spot image in posteroanterior (PA) projection localized the foreign body as a linear filling defect in segmental branch of right descending pulmonary artery (arrowheads) (B) Fluoroscopic spot image showing opened end of Amplatz gooseneck snare before deployment across the radiolucent foreign body (C) Engaged radiolucent cannula tip by the snare in the guiding catheter (D & E) Retrieved foreign body, i.e., fractured peripheral intravenous cannula tip (F) Check cone beam CT coronal reconstruction showing no residual foreign body in corresponding right pulmonary artery branch.

attempts the snare could catch up the foreign body and the snare-guiding catheter assembly was removed en bloc through the femoral sheath (– Fig. 2D, E). Later the femoral sheath was removed and hemostasis was obtained by manual compression. Post retrieval, cone beam CT of the chest revealed no residual foreign body (– Fig. 2F). There were no peri procedural complications. The patient was discharged on the next day of the procedure without any complications.

Discussion

Intravenous therapy is very common practice in medicine, required in almost all hospitalized patients. Primarily, there are two types of venous access- peripheral and central venous access. Peripheral intravenous access is preferred for short term intravenous therapy while central venous access is utilized for long term administration of medications.¹ The risk of fracture of intravenous cannula is a rare occurrence and embolization of fractured fragment is very rare complication. Turner et al, first described the intravascular embolization of the central venous catheter fragment in 1954.³ The incidence of embolization of fractured intravenous catheter fragment varies from 0.2% to 4.2%, and mainly occurs with central venous catheters or implanted port devices with complications like thromboembolism, sepsis, cardiac arrhythmia, pericardial effusion, myocardial lesions and bacterial endocarditis.²

Peripheral intravenous cannula placement is associated with complications like phlebitis, extravasation, hematoma, occlusion.¹ The occurrence of fracture of peripheral intravenous cannula and its embolization is very rare complication. It is unlikely to happen in peripheral intravenous cannulation without a forceful attempt of removal.⁵ The localization of fractured fragment of the cannula is made first by manual palpation along the course of the superficial vein in upper limb, followed by ultrasonography of the upper limb venous system, if intravascular embolization is suspected. If above investigations fail to localize the fractured peripheral intravenous cannula, central embolization is to be suspected. Multidetector 3D computed tomography of thorax is the preferred modality to localize the fractured fragment embolization into central venous system and heart as well as determining embolization related complications. 3D volume rendered and maximum intensity projection (MIP) rendered images provide exact location of fractured fragment into vascular system.⁶

Only few cases have been previously reported regarding fracture of peripheral intravenous cannula and their management. Most of them reported dislodged fractured peripheral intravenous cannula either into superficial vein of the upper limb⁷ or into subcutaneous tissue.⁸ All these cases have been managed by surgical retrieval of the fractured cannula tip. Only one case has been reported previously as fracture of peripheral venous catheter with pulmonary artery embolism,⁹ where they had retrieved the fractured fragment by lateral thoracotomy.

Endovascular retrieval of venous foreign bodies is mostly described in relevance to fracture associated embolization of central venous catheters, peripherally inserted central catheters and port catheters.¹⁰ To best of our knowledge, this is the first

case of fracture of peripheral intravenous cannula with pulmonary artery embolism to be managed by endovascular retrieval. The indications for the removal of these kind of foreign bodies are still debated. Some suggest that the long-term risk of pulmonary artery thrombosis, sepsis and perforation is sufficient to justify extraction¹. So, conservative management of asymptomatic embolus into central branch of pulmonary artery was not considered in the index case. It was preferred to go for elective retrieval of foreign body by endovascular technique, keeping conventional surgical embolectomy option reserved for unsuccessful endovascular retrieval. The challenging part in endovascular retrieval was its localization under fluoroscopy, as the foreign body was a radiolucent thin plastic shaft of peripheral intravenous cannula. Being radiolucent, it was localized as a linear filling defect in the pulmonary angiogram. Fluoroscopic landmarking and intermittent iodinated contrast injections helped in demarcating the radiolucent foreign body and engaging the snare loop around it.

To conclude, fracture and central venous embolization of the peripheral intravenous cannula is very rare. Endovascular snare retrieval of embolized radiolucent venous cannula from pulmonary artery may be feasible and safe.

Funding

This research received no specific grant from any funding agency in the public, commercial, or not-for-profit sectors.

Conflicts of Interest

Authors declare that that there is no conflict of interest.

References

- 1 Surov A, Wienke A, Carter JM, et al. Intravascular embolization of venous catheter—causes, clinical signs, and management: a systematic review. *JPEN J Parenter Enteral Nutr* 2009;33(06):677–685
- 2 Dychter SS, Gold DA, Carson D, Haller M. Intravenous therapy: a review of complications and economic considerations of peripheral access. *J Infus Nurs* 2012;35(02):84–91
- 3 Turner DD, Sommers SC. Accidental passage of a polyethylene catheter from cubital vein to right atrium; report of a fatal case. *N Engl J Med* 1954;251(18):744–745
- 4 Bloom AI, Woolf YG, Cuenca A. Accidental embolization of an intravenous cannula in the upper limb: retrieval following computed tomography localization. *Eur J Emerg Med* 1996;3(02):106–107
- 5 Freiberg DB, Barnes DJ. Fatal sepsis following peripheral intravenous cannula embolus. *Chest* 1992;101(03):865–866
- 6 Weiss CR, Fishman EK. Multidetector 3D CT of pulmonary embolism of a peripheral intravenous line. *Emerg Radiol* 2005;11(04):247–249
- 7 Khoo PJ, Tay KL, Jamaluddin AA, Gunasaker D. Self-inflicted and iatrogenic peripheral intravenous cannula fracture: A case report. *Ann Med Surg (Lond)* 2018;33:44–46
- 8 Khadim MF, Leonard D, Moorehead RA, Hill C. Back to basics: iatrogenic intravenous cannula embolus. *Ann R Coll Surg Engl* 2013;95(07):110–111
- 9 Dell'Amore A, Ammari C, Campisi A, D'Andrea R. Peripheral venous catheter fracture with embolism into the pulmonary artery. *J Thorac Dis* 2016;8(12):E1581–E1584
- 10 Woodhouse JB, Uberoi R. Techniques for intravascular foreign body retrieval. *Cardiovasc Intervent Radiol* 2013;36(04):888–897