

Skin Cancer

Early Experience with Dabrafenib–Trametinib Combination in Patients with BRAF-Mutated Malignant Melanoma—A Single-Center Experience

Sandip Ganguly¹ Joydeep Ghosh¹ Deepak Mishra² Gautam Biswas³ Deepak Dabkara¹
Somanth Roy¹ Bivas Biswas¹

¹Department of Medical Oncology, Tata Medical Center, Kolkata, West Bengal, India

²Department of Molecular Pathology, Tata Medical Center, Kolkata, West Bengal, India

³Department of Plastic Surgery, Tata Medical Center, Kolkata, West Bengal, India

Address for correspondence Bivas Biswas, MD, DM (Med. Onco.), Department of Medical Oncology, Tata Medical Center, 14 MAR (EW) Newtown, Kolkata 700160, West Bengal, India (e-mail: bivasbiswas@gmail.com).

South Asian J Cancer 2021;10:187–189.

Abstract



Bivas Biswas



Sandip Ganguly

Keywords

- ▶ malignant melanoma
- ▶ BRAF mutation
- ▶ dabrafenib
- ▶ trametinib

Background Combination of dabrafenib–trametinib is one of the standard treatments in patients with BRAF-mutated advanced malignant melanoma (MM). Real-world data on the usage of this combination is scarce, especially from India. Here, we are reporting our early experience with the usage of this combination therapy.

Materials and Methods This is a single institutional data assessment of patients with BRAF-mutated MM registered and treated with BRAF–MEK inhibitors in our hospital. Clinico-pathological features and treatment details were reviewed for all patients.

Results A total of seven patients with BRAF-mutated MM treated with this combination therapy with a median age of 66.5 years (range: 49–72 years) and a male:female ratio of 3:4. Six (85.7%) patients had metastatic disease at presentation. In total, 80% of our patient population had two or less than two sites of metastasis at presentation. The initial response rate of the study population was 71%. The drug was well tolerated with fever being the most common side effect which was seen in two (28.5%) of the patients.

Conclusion Combination of dabrafenib–trametinib is effective in patients with BRAF-mutated MM with good tolerability. Further studies are required to look for improvement in outcome in this group of patients.

Introduction

Malignant melanoma (MM) arises from the melanocytes. The incidence of MM has a wide geographical variation with the highest incidence being reported from Australia and the lowest from South-Central Asia.¹ Metastatic MM (MMM)

is associated with a poor response with standard conventional chemotherapy leading to poor outcome. However, recently the advent of newer therapies like immunotherapy and tyrosine kinase inhibitors (TKIs) has improved the response rate and survival outcome compared with historic data.² Targeted therapy is directed toward the dual inhibition

DOI <https://doi.org/10.1055/s-0041-1736032> ISSN 2278-330X

How to cite this article: Ganguly S, Ghosh J, Mishra D, et al. Early Experience with Dabrafenib–Trametinib Combination in Patients with BRAF-Mutated Malignant Melanoma—A Single-Center Experience. South Asian J Cancer 2021;10(3):187–189.

© 2021. MedIntel Services Pvt Ltd.

This is an open access article published by Thieme under the terms of the Creative Commons Attribution-NonDerivative-NonCommercial-License, permitting copying and reproduction so long as the original work is given appropriate credit. Contents may not be used for commercial purposes, or adapted, remixed, transformed or built upon. (<https://creativecommons.org/licenses/by-nc-nd/4.0/>).

Thieme Medical and Scientific Publishers Private Ltd A-12, Second Floor, Sector -2, NOIDA -201301, India

of BRAF and MEK pathway inhibition. The incidence of BRAF mutation is very high in patients with MMM.³ Initially only BRAF inhibition was targeted with BRAF inhibitors like dabrafenib⁴ and vemurafenib⁵ but due to cross-activation of the MAPK pathway, it led to resistance to therapy with a shorter duration of disease control.⁶ Additionally, the activation of the MAPK pathway led to the development of secondary cutaneous malignancies and also reactivation of RAS mutant tumors.⁷ Further research led to the development of MEK inhibitors like trametinib and cobimetinib, and it showed there is improvement in overall survival in patients with BRAF mutant MMM with no paradoxical activation.^{8,9} Combination of these two groups of the drug has synergistic activity leading to improvement in overall survival in patients with MMM in the metastatic setting. Similar improved results have been seen in patients with resected node-positive disease.¹⁰ Real-world data on the usage of this drug is scarce in the available literature especially from a resource-poor country like India. Here we report our early experience with the usage of these inhibitors in patients with advanced MM. Initially, the drug was not available in India and we received the drug from Novartis Pharmaceuticals through a compassionate access program.

Materials and Methods

This is a single institutional data assessment of patients with BRAF-mutated MM registered and treated with BRAF–MEK inhibitors in the Department of Medical Oncology at Tata Medical Center, Kolkata. Clinico-pathological features and treatment details were reviewed for all patients. Ethical clearance was taken from the institutional review board.

Diagnosis and Workup

All patients underwent tissue diagnosis by biopsy with appropriate immunohistochemistry markers (S100, HMB 45, and Melan-A.) Metastatic workup was done with either whole-body 18-fluorodeoxyglucose positron emission tomography-computed tomography (PET-CT) or CT of thorax and abdomen with/without ^{99m}technetium bone scintigraphy whenever indicated. Magnetic resonance imaging of the brain was done in patients with symptomatic neurological symptoms. BRAF mutation was analyzed by next-generation sequencing (NGS) using ion torrent platform with cancer hotspot V2 panel.

Treatment and Response Evaluation

Patients who were found to have BRAF mutation by the NGS technique were given a combination of capsule dabrafenib (150 mg twice daily) and tablet trametinib (2 mg once daily) both in empty stomach with normal organ functions. Toxicities were graded as per the Common Terminology Criteria for Adverse Events version 4.¹¹ Patients were assessed periodically for response assessment. Complete response (CR), partial response (PR), stable disease (SD), and progressive disease (PD) were defined according to the Response Evaluation Criteria in Solid Tumors (RECIST v1.1) criteria wherever applicable.¹² Overall response rate (ORR) was defined as the sum of CR + PR. Clinical benefit rate (CBR) was defined as the sum of CR + PR + SD. Descriptive statistics were used for demographic and clinical characteristics. Progression-free survival (PFS) was calculated from the date of diagnosis to the date of clinical and/or radiological disease progression or death from any cause.

Results

The total number of MMM treated at our department from January 2013 to December 2020 was 122, and out of them, 50 patients underwent BRAF testing. Out of these, eight patients were found to have BRAF mutation on NGS testing and seven patients took treatment. The median age of the study cohort was 66.5 years (range: 49–72 years) with a male:female ratio being 3:4. Among them, six (85.7%) had metastatic disease. Five patients had BRAF V600E mutation while two patients had BRAF V600R mutation. Five patients received upfront systemic therapy with the combination TKI, one received the same in the adjuvant setting (stage III disease), and one received the treatment in second-line setting after the failure of taxane-based chemotherapy. The baseline characteristics of the patients are shown in [Table 1](#).

Response Assessment and Outcome

All six patients with metastatic disease had their initial response assessment. It was CR in 2 (33%), PR in 2 (33%), SD in 1 (17%), and PD in 1 (17%) patient with an ORR of 60% and a CBR of 83%. At a median follow-up of 23 (95% confidence interval [CI]: 6 to NR [not reached]) months, the median PFS was 9.3 (95% CI: 1.3 to not reached) months as shown in [Fig. 1](#).

Table 1 Clinicopathologic characteristics and treatment outcome

Age	Sex	Primary site	Sites of metastases	Which line?	Type of BRAF mutation	Line of treatment	Response assessment
72	Female	Arm	Bone, skin	First	V600R	First	PR
44	Female	Scalp	Lung	First	V600E	First	CR
65	Male	Upper limb	Brain, soft tissue, nodes	First	V600E	First	PD
49	Male	Anal canal	Lung, nodes	Second	V600R	Second	CR
56	Female	Inguinal nodes	Nil	Adjuvant	V600E	Adjuvant	
63	Male	Pericardium	Nodes	First	V600E	First	SD
61	female	Breast	Skin, nodes	First	V600E	First	PR

Abbreviations: CR, complete response; PD, progressive disease; PR, partial response; SD, stable disease.

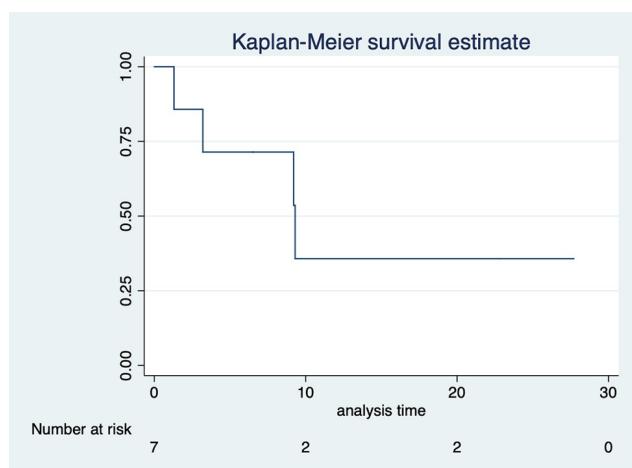


Fig. 1 Kaplan–Meier curve showing the median progression-free survival of patients who were treated with the drug combination.

Discussion

MM is a rare cancer in India constituting 0.3% of all new cases as per the latest GLOBOCAN data.¹³ Very limited literature is available from India.^{14,15} None of the studies does not discuss the outcome with recently approved targeted therapies and this is the first study from India which deals with an early experience of using targeted therapies in patients with MM.

The median age of the study population was 66.5 years, which was higher than that reported in the available literature.^{14–17} In total, 80% of our patient population had two or less than two sites of metastasis in comparison to 52% in the landmark trial.¹⁶ The response rate of our study population was 66%, which was almost similar to 67% in clinical trial settings¹⁶ and 72% from the Japanese study.¹⁷

At a median follow-up of 23 months, the median PFS of the cohort of our patients was 9.3 months. It is almost similar to the updated analysis of the pivotal landmark trial where it was 11.1 months.¹⁸ Pyrexia is the most commonly reported adverse effect of this combination therapy. Only two (33.3%) patients had fever as a side effect, which was easily managed with dose interruption and in some cases, prophylaxis with paracetamol was used.

One of the limitations of our study is that we have not stratified our patients based on the lactate dehydrogenase level and another limitation being the small number of patients in our cohort.

However, our study does have some strong points. This is the first study from India where we are reporting our experience with the usage of dabrafenib and trametinib in patients with MM. Another interesting point is that though the drug has been approved for use in patients with V600E/K mutation only, we have used this therapy in patients with BRAF V600R mutation and they have also responded to the therapy. Further studies are required to see the efficacy of this combination therapy in patients with nonapproved BRAF mutation.

Conflict of Interest

None.

Acknowledgment

We would like to thank Novartis Pharmaceuticals for providing the medicines free of cost through a compassionate access program.

References

- 1 Ali Z, Yousaf N, Larkin J. Melanoma epidemiology, biology and prognosis. *EJC Suppl* 2013;11(2):81–91
- 2 Ugurel S, Röhmel J, Ascierto PA, et al. Survival of patients with advanced metastatic melanoma: the impact of novel therapies-update 2017. *Eur J Cancer* 2017;83:247–257
- 3 Lokhandwala PM, Tseng L-H, Rodriguez E, et al. Clinical mutational profiling and categorization of BRAF mutations in melanomas using next generation sequencing. *BMC Cancer* 2019;19(1):665
- 4 Hauschild A, Grob J-J, Demidov LV, et al. Dabrafenib in BRAF-mutated metastatic melanoma: a multi-centre, open-label, phase 3 randomised controlled trial. *Lancet* 2012;380(9839):358–365
- 5 Chapman PB, Hauschild A, Robert C, et al; BRIM-3 Study Group. Improved survival with vemurafenib in melanoma with BRAF V600E mutation. *N Engl J Med* 2011;364(26):2507–2516
- 6 Carnahan J, Beltran PJ, Babij C, et al. Selective and potent Raf inhibitors paradoxically stimulate normal cell proliferation and tumor growth. *Mol Cancer Ther* 2010;9(8):2399–2410
- 7 Viros A, Milagre C, Trunzer K, et al. RAS mutations in cutaneous squamous-cell carcinomas in patients treated with BRAF inhibitors. *N Engl J Med* 2012; 366:207–215
- 8 Long GV, Stroyakovskiy D, Gogas H, et al. Combined BRAF and MEK inhibition versus BRAF inhibition alone in melanoma. *N Engl J Med* 2014;371(20):1877–1888
- 9 Larkin J, Ascierto PA, Dréno B, et al. Combined vemurafenib and cobimetinib in BRAF-mutated melanoma *N Engl J Med* 2014;371(20):1867–1876
- 10 Long GV, Hauschild A, Santinami M, et al. Adjuvant dabrafenib plus trametinib in stage III BRAF-mutated melanoma. *N Engl J Med* 2017;377(19):1813–1823
- 11 Common Terminology Criteria for Adverse Events (CTCAE) Protocol development CTEP. https://ctep.cancer.gov/protocol-development/electronic_applications/ctc.htm. Accessed on September 6, 2021
- 12 Schwartz LH, Litière S, de Vries E, et al. RECIST 1.1-Update and clarification: from the RECIST committee. *Eur J Cancer* 2016;62:132–137
- 13 IARC. 356-india-fact-sheets.pdf. Available at: <https://gco.iarc.fr/today/data/factsheets/populations/356-india-fact-sheets.pdf>. Assessed May 20, 2021
- 14 Sharma K, Mohanti BK, Rath GK. Malignant melanoma: a retrospective series from a regional cancer center in India. *J Cancer Res Ther* 2009;5(3):173–180
- 15 Radhika K, Prayaga AK, Sundaram C. A clinicopathologic study of malignant melanoma based on cytomorphology. *Indian J Cancer* 2016;53(1):199–203
- 16 Robert C, Karaszewska B, Schachter J, et al. Improved overall survival in melanoma with combined dabrafenib and trametinib. *N Engl J Med* 2015;372(1):30–39
- 17 Takahashi A, Namikawa K, Nakano E, Yamazaki N. Real-world efficacy and safety data for dabrafenib and trametinib combination therapy in Japanese patients with BRAF V600 mutation-positive advanced melanoma. *J Dermatol* 2020;47(3):257–264
- 18 Robert C, Grob JJ, Stroyakovskiy D, et al. Five-year outcomes with dabrafenib plus trametinib in metastatic melanoma. *N Engl J Med* 2019;381(7):626–636