

Improving Projection of the Nasal Tip in Primary Endonasal Rhinoplasty

Norman Pastorek, MD¹ Patrick Cleveland, MD²

¹Facial Plastic Surgery, New York Presbyterian Hospital-Cornell Med Center, New York

²Department of Facial Plastic Surgery, New York University Medical Center, New York

Address for correspondence Norman Pastorek, MD, Facial Plastic Surgery, 1127 Park Avenue, New York, NY 10128 (e-mail: drpastorek@gmail.com).

Facial Plast Surg 2022;38:46–56.

Abstract

Gaining, improving, and maintaining nasal tip projection is one of the most essential elements of successful endonasal rhinoplasty. For years the hallmark of inadequate nasal tip projection following rhinoplasty has been the Polly beak deformity. Early rhinoplasty technique consisted of intracartilaginous excision of the cephalic margin of the lower lateral cartilages, cartilage and bony hump reduction, and osteotomies. Some of these simple rhinoplasties still look good decades later, however, many are conspicuous in their lack of nasal tip projection. The reason for this inconsistency in rhinoplasty results was the surgeon's inattention to the structural integrity and anatomical position of the LLC. The senior author uses a combination of suture, strut, and cartilage grafting techniques to achieve ideal projection in a manner tailored to each patient's unique anatomic needs.

Keywords

- ▶ rhinoplasty
- ▶ endonasal
- ▶ nasal projection
- ▶ nasal tip

During the initial consultation, after the medical history is taken and the patient's desires are clearly understood the rhinoplasty surgeon must learn all that he or she can about the anatomical components of the patient's nose. While the focus of this article is about nasal tip projection it should be understood that all parts of the nose are interconnected and related. For example, the reduction of a large nasal hump can give the impression of a more projected nasal tip.

Once it is determined that the nasal tip must maintain its current projection or that the projection must be increased to satisfy the aesthetic goals of the patient, then a careful analysis of the nasal tip is imperative. An evaluation of the nasal skin is very important, as most rhinoplasty surgeons recognize that there is an inverse ratio of the nasal tip skin thickness and LLC strength. In patients with extremely thick skin, the LLC may have the consistency and strength of a paper towel. Even minor surgical manipulation of such weak lower LLC will lead to further weakness and significant postoperative loss of projection. Dealing with this type of nasal tip will be addressed toward the end of this article.

The strength and position of the LLC and the position of the domes are evaluated by palpation and observation. With finger pressure at the nasal tip is there firmness or does the nasal tip easily compress? Are the domes tightly united or are they widely separated? Do the lateral crura of the LLC angle toward the medial canthus or the lateral canthus?

In primary rhinoplasty, improving nasal tip projection may require suture techniques alone or the possibility of cartilage grafts.^{1,2} It is important to evaluate the potential sources of cartilage should it be needed to support the nasal tip projection. The author does not use allopathic grafts in rhinoplasty surgery. The risks of potential complications of allopathic materials such as infection, rejection, or extrusion are higher in rhinoplasty surgery than in other areas of the face and body. The nasal septum is the most common donor site for cartilage grafts. The surgeon must ascertain that the cartilaginous septum is adequate, is not twisted or fractured, and that a previous septoplasty has not removed the useful portion of the septum. At the time of consultation, following adequate topical anesthesia of the nasal mucosa, a long cotton tip applicator is used to palpate the septum under

published online
October 26, 2021

Issue Theme Why Not Endonasal Rhinoplasty?; Guest Editor: Michael Adelard Carron, MD

© 2021. Thieme. All rights reserved.
Thieme Medical Publishers, Inc.,
333 Seventh Avenue, 18th Floor,
New York, NY 10001, USA

DOI <https://doi.org/10.1055/s-0041-1736391>.
ISSN 0736-6825.

direct magnified lighted observation. If it is determined that the septal cartilage is not available then the ears are examined as potential donor sites for cartilage grafting. A surgical consent will be necessary if there is any possibility that auricular cartilage may be used.³⁻⁶

Surgical Planning

There are multiple considerations when addressing nasal tip projection in a patient. How much increase in projection does the patient desire? Is the patient happy with the current amount of projection? How much increase in projection is possible? How does the patient feel about a supratip break if one has not been present preoperatively? It is the author's feeling that patients whose preoperative lateral view shows the high point to be at the anterior septal angle rarely want a supratip break at rhinoplasty. It is simply too much change. The possible change in projection can be demonstrated with the patient looking in a hand mirror from the side while the surgeon uses his or her fingers and thumb to manipulate the nasal tip. It is surprising how quickly a patient will say "yes, I like that" just as the surgeon has moved then tip forward to their liking (► Fig. 1). Imaging can also be used to approximate the final tip projection. Care must be taken not to "over promise" a final result.

Based on the strength of the LLC, specifically the medial crura and the patient's wishes a decision is made at the time of consultation about the use of sutures alone, sutures with columella strut grafting, or sutures with an extended strut tip columella graft to achieve nasal tip projection. In most cases, the nasal septum is adequate for any needed graft. Permission for the use of auricular cartilage is obtained if there is any doubt.^{3,6-8}

Anesthesia

Until the COVID-19 pandemic of 2020, most rhinoplasties performed by the author were done using local anesthesia

with intravenous monitored analgesia. Until hospital protocol changes, rhinoplasties are done under general anesthesia, usually LMA, with 4 mL of topical 4% cocaine and 3 to 4 mL of 2% xylocaine with 100,000 epinephrine. (A video of the application and infiltration of local anesthesia can be seen online; Rhinoplasty Archive, Dr. Norman Pastorek video, Endonasal Rhinoplasty, pt.1.). If auricular cartilage grafting is anticipated, 2 mL of local anesthesia is injected into the postauricular sulcus.⁹

Surgery

The author uses an endonasal conservation structural technique for rhinoplasty. Initially, the LLC is delivered into the nares via an intercartilaginous and marginal incision. The lower lateral cartilages (LLCs) are examined for integrity. If the LLCs are soft and weak only the minimal amount of cephalic margin is removed. If the LLC are found to be firm and strong then more of the cephalic margin can be removed to reduce the lateral bulk. At least 6 mm of LLC must remain, however, 7 to 8 mm of LLCs are usually left intact.^{7,10}

Once the cephalic trim of the LLC is complete, the remainder of rhinoplasty is performed, i.e., cartilage and bony hump, septoplasty, osteotomies. Other maneuvers may be applied to the LLC besides and in addition to cephalic trimmings, such as a lateral crura turn in flap or a lateral crura extension graft, but these are beyond the scope of this article.^{11,12} The tip projection techniques are the last maneuvers of the rhinoplasty.

The Dome Binding Suture

In cases where the LLC are strong and resilient, the dome binding suture alone will increase projection enough to satisfy both the patient and surgeon. Before suture placement, the vestibular skin must be dissected away from the

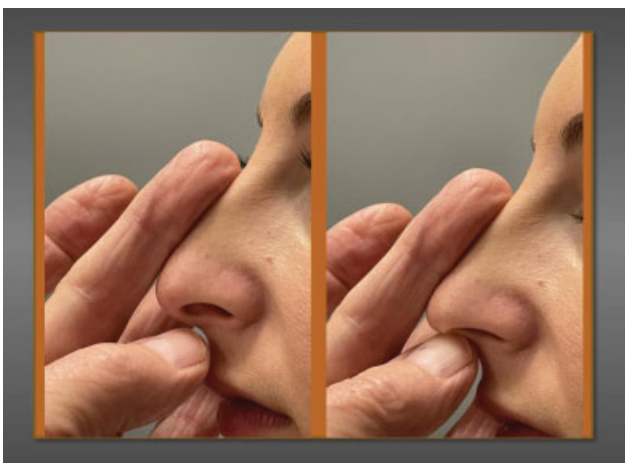


Fig. 1 Both the patient and surgeon can see the aesthetic benefit of increasing projection by moving the thumb back and forth.

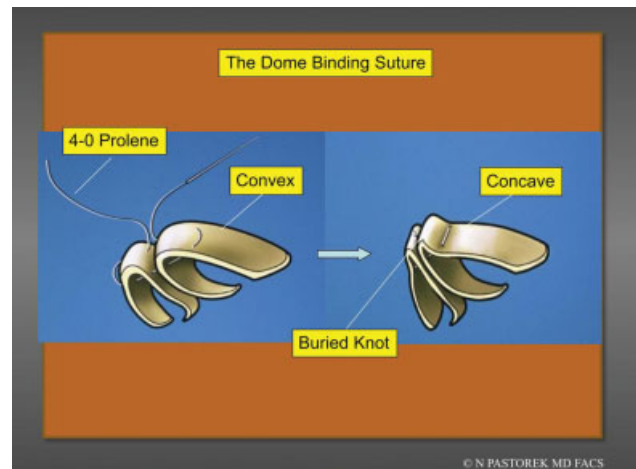


Fig. 2 The effect of the dome-binding suture, showing graphically. The convex arch just beyond the domes is transformed into a gentle concavity.

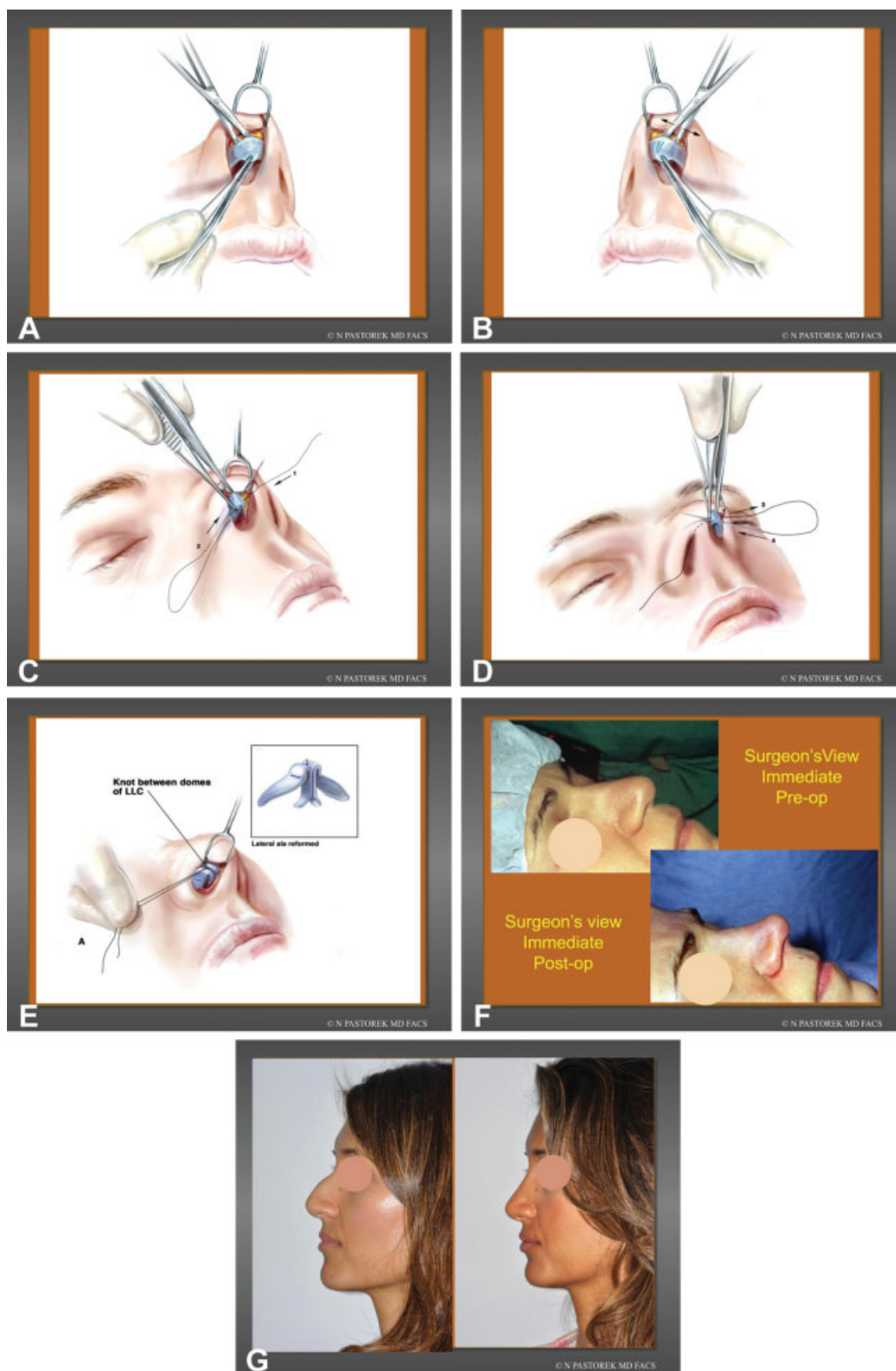


Fig. 3 (A) The right dome is exposed. The LLC is delivered via a bipedicle chondromucosal flap with intercartilaginous incisions between the and ULC and along the inferior margin of the LLC. The mucosa is separated from LLC where the needle will pass. (B) The same procedure on the left side. (C) A 4–0 Prolene mattress suture using a straight needle through the right dome. (D) A mattress suture through the opposite dome. (E) The domes are brought together with a suture knot buried between the domes. (F) Improved nasal tip projection from a dome-binding suture. (G) Maintenance of tip projection with a dome-binding suture. (H) Tip projection improved with a dome-binding suture. LLC, lower lateral cartilage; ULC, upper lateral cartilage.

This document was downloaded for personal use only. Unauthorized distribution is strictly prohibited.

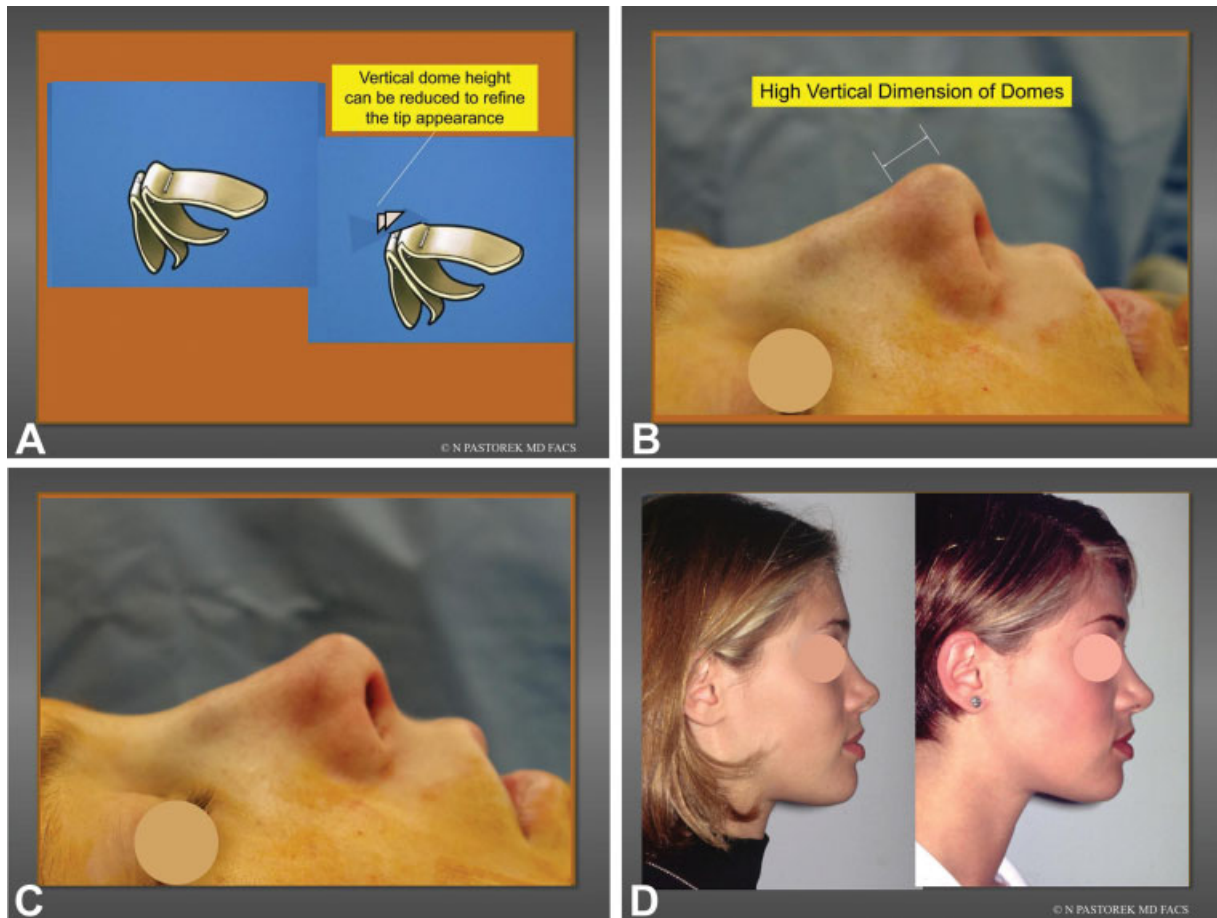


Fig. 4 (A) To reduce the dome height for a more appealing tip appearance, a portion of the superior unified domes can be removed at the completion of the case. (B) The image shows as high vertical height of the domes at the conclusion of the case. (C) The height of the domes has been reduced to 4 mm, giving a more refined appearance to the tip. (D) The patient in the preoperative photo shows excessive vertical height of the domes in the lateral view. The postoperative view shows the result of a dome binding suture and reduction of dome height to 4 mm.

undersurface of the domes to prevent suture exposure in the internal nose. This is best done with a curved iris scissors. The suture recruits some of the lateral LLC and combines the domes into a firm four surface central projection element (► Fig. 2). The author prefers to use a 4-0 Prolene suture on a straight V-47 needle to mattress the domes. The domes may both be brought into the right nares (for a right-handed surgeon) or the needle can be passed back and forth under the tip skin to mattress the domes (► Fig. 3A–D, F). The two domes must be brought together in the exact midline. Care is taken to prevent the suture from touching the patient's lips or teeth. A surgical sponge placed over the patient's mouth is an easy method of assuring sterility of the suture. Before the suture is cut at the knot in its position between the domes, it is bathed in a 10% Povidone-Iodine solution. After the dome binding suture has been placed, the nose is examined from a lateral position. Is there an elevation at the supratip that gives an overall roundness to the tip? If a more chiseled appearance is desired a small additional amount of LLC at the domes can be removed (► Fig. 4A–D). In thin-skinned noses, small morsel grafts are placed, after the rhinoplasty, against

the lateral surface of the domes to assure proper tip width.^{7,10,13}

Dome Binding Suture Plus Trans Columellar Strut

Occasionally, at the very conclusion of the rhinoplasty, the surgeon palpates the nasal tip and feels he or she may have slightly miscalculated the overall strength of the LLC. The weakness in these cases is almost always in the feet of the LLC. At this point in the rhinoplasty, it would be difficult to open the closed incisions and remove the dome binding to insert a columellar strut.

A more reasonable way to ensure adequate projection postoperatively is to place a trans-columellar strut. Ideally, the strut should be septal cartilage from the nasal floor where it is thickest and measures approximately 1.75 cm in length. The ends of the strut should not be square, but instead slightly arrowhead-shaped so that the strut passes easily into a pocket in the columella. An incision is made with a #15 scalpel in the lateral mid columella, through

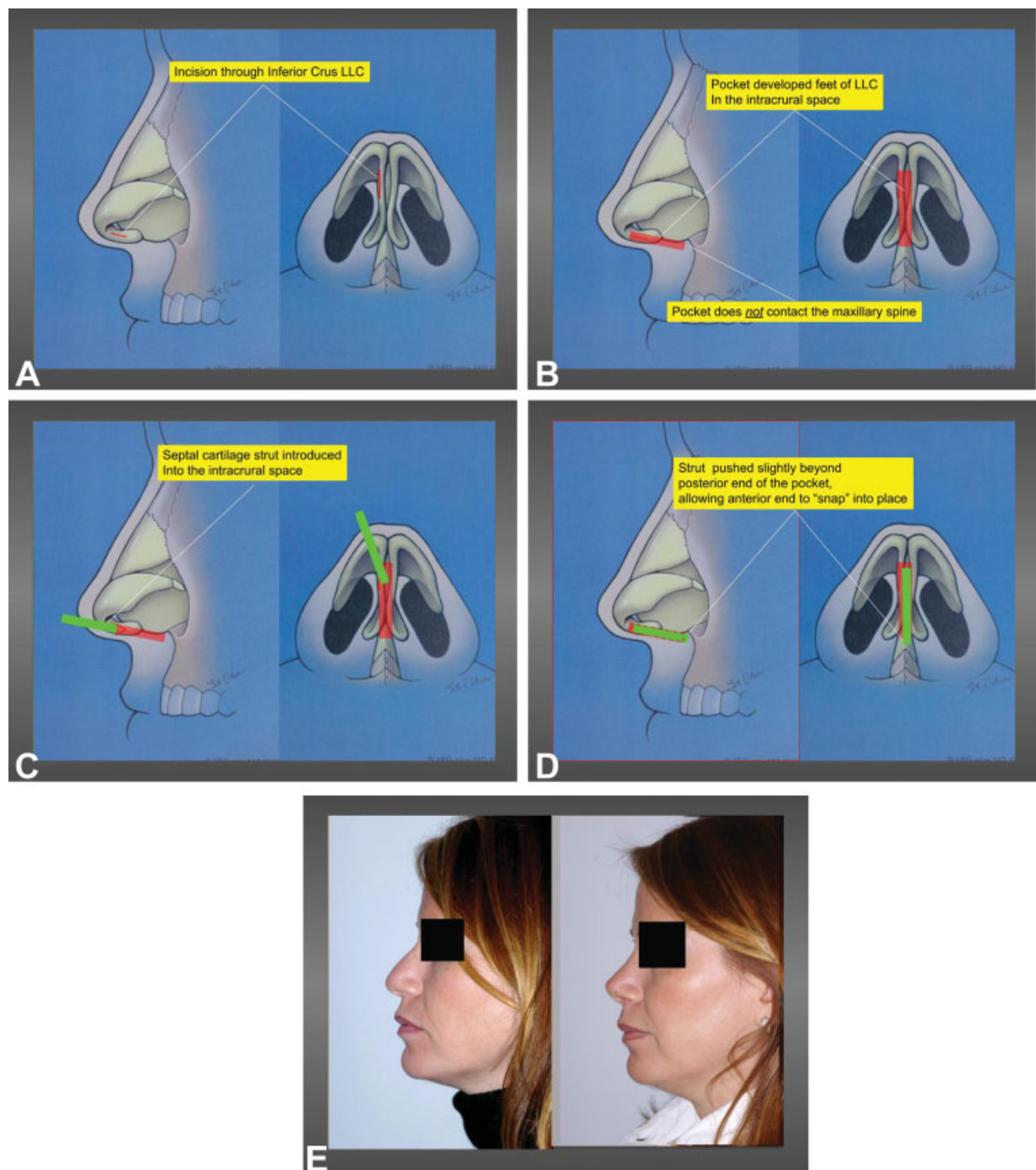


Fig. 5 (A) A 0.5-mm incision is made into the foot of the lower lateral cartilage entering into the intercrural space. (B) A pocket is made between the feet of the lower lateral cartilages with a curved Steven's scissors down toward the maxillary spine. The pocket size is made to accept of cartilage strut measuring 1.75 to 2.0 cm. (C) The strut is introduced into the pocket with a Brown-Adson forceps. (D) The pocket should be just slightly smaller than the strut, so that it "snaps" into place. The pocket is too large and the strut will fail to support the nasal tip. (E) The lateral view of a patient with a trans-columellar strut placement.

the foot of the medial crura. A curved Stevens scissor is used to expand the intercrural space down toward the premaxilla, but not onto the premaxilla. The idea is to make the intercrural space just slightly smaller than the strut. This gives some tension in the columella. A pocket much larger than the strut would make the strut less effective. The strut is inserted with Brown-Adson forceps. A single 4-0 chromic suture is used to close the columella incision (► Fig. 5A-D).^{13,14}

The Interdomal Columellar Strut

When, at the time of consultation, it is determined that the weakness of the LLC is such that a dome binding suture alone will not be adequate to maintain tip projection, following rhinoplasty plans are made to use an interdomal columellar strut. This strut is placed after modification of the LLC, removal of any cartilaginous or bony hump, and osteotomies are completed. Before the dome binding

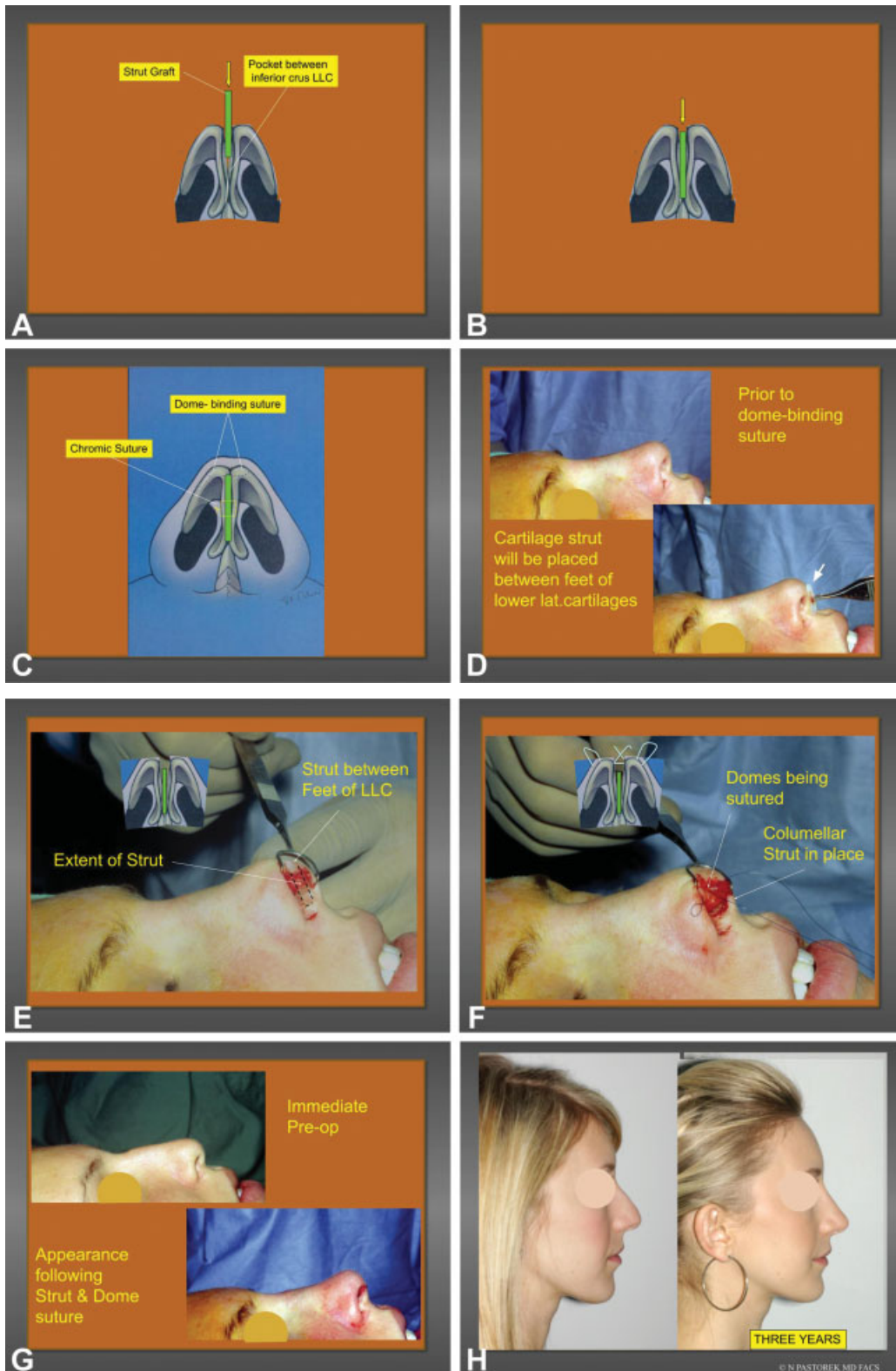


Fig. 6 (A) The interdomal columellar strut is introduced into a pocket made between the domes prior to using the dome binding suture. This strut is between 1.75 and 2.0 cm in length. (B) The interdomal strut should not rest on the maxillary spine and should be far enough below the domes to allow for the dome binding suture. (C) A 4-0 Chromic suture through the feet of the LLC and interdomal strut holds the strut in position and the dome binding suture prevents it from slipping forward. (D) The photo shows the size of the interdomal strut to be used in this patient. (E) The dotted line shows the extent and position of the strut. (F) The dome binding suture placed to give support to the projection of the tip also prevents the strut from moving forward. (G) An immediate preoperative and immediate postoperative view of the result of an interdomal strut placement. (H) Pre and postoperative lateral views of long-term patient with an interdomal strut graft.

This document was downloaded for personal use only. Unauthorized distribution is strictly prohibited.

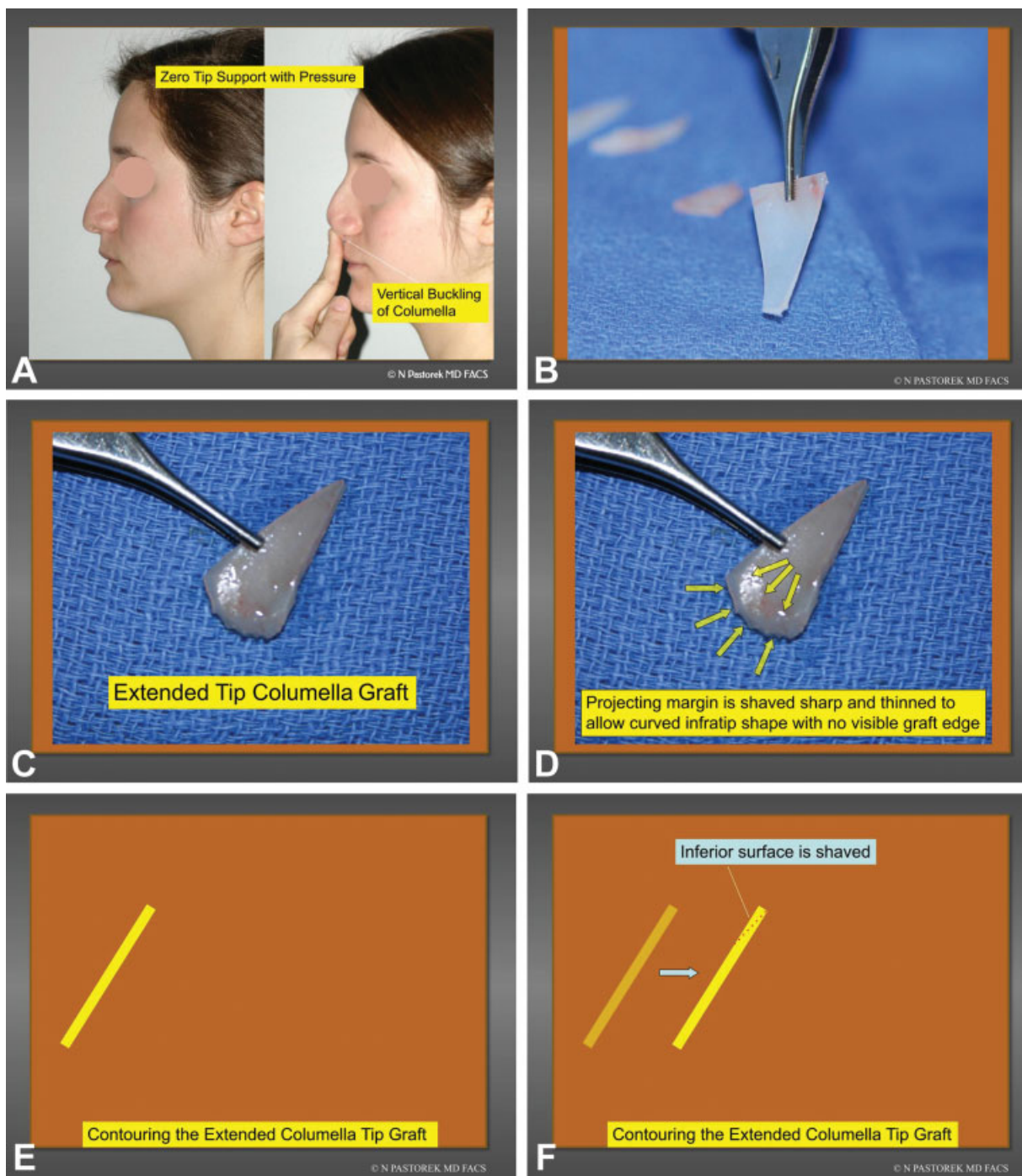


Fig. 7 (A) The severe lack of nasal tip projection is demonstrated with digital pressure to the nasal tip. There is a vertical buckling of the feet of the LLC. (B) The size and shape of the extended tip columella graft. (C) An extended tip columella graft after modification to prevent “show” of the graft edge at the nasal tip. (D) It is important that the leading edge of the extended tip columella graft be tapered. (E) Contouring the extended tip columella graft. (F) Contouring the extended tip columella graft. (G) Contouring the extended tip columella graft. (H) Contouring the extended tip columella graft. (I) Diagrammatic position of the implanted extended tip columella graft. (J) Showing the position of extended tip columella graft. (K) A pocket is developed the graft implantation. (L) The graft is grasped in the middle and via the right marginal incision moved onto the nasal dorsum. The narrow end of the graft is engaged into the intercrural pocket. Then the graft is pushed into the full extent of intercrural pocket. (M) This photo shows the immediate result of implantation of the extended tip columella graft and a diagram of its relationship with the domes of the LLC. (N) Sutures are placed through the mucosa on each side of the graft to keep it centered. LLC, lower lateral cartilage.

This document was downloaded for personal use only. Unauthorized distribution is strictly prohibited.

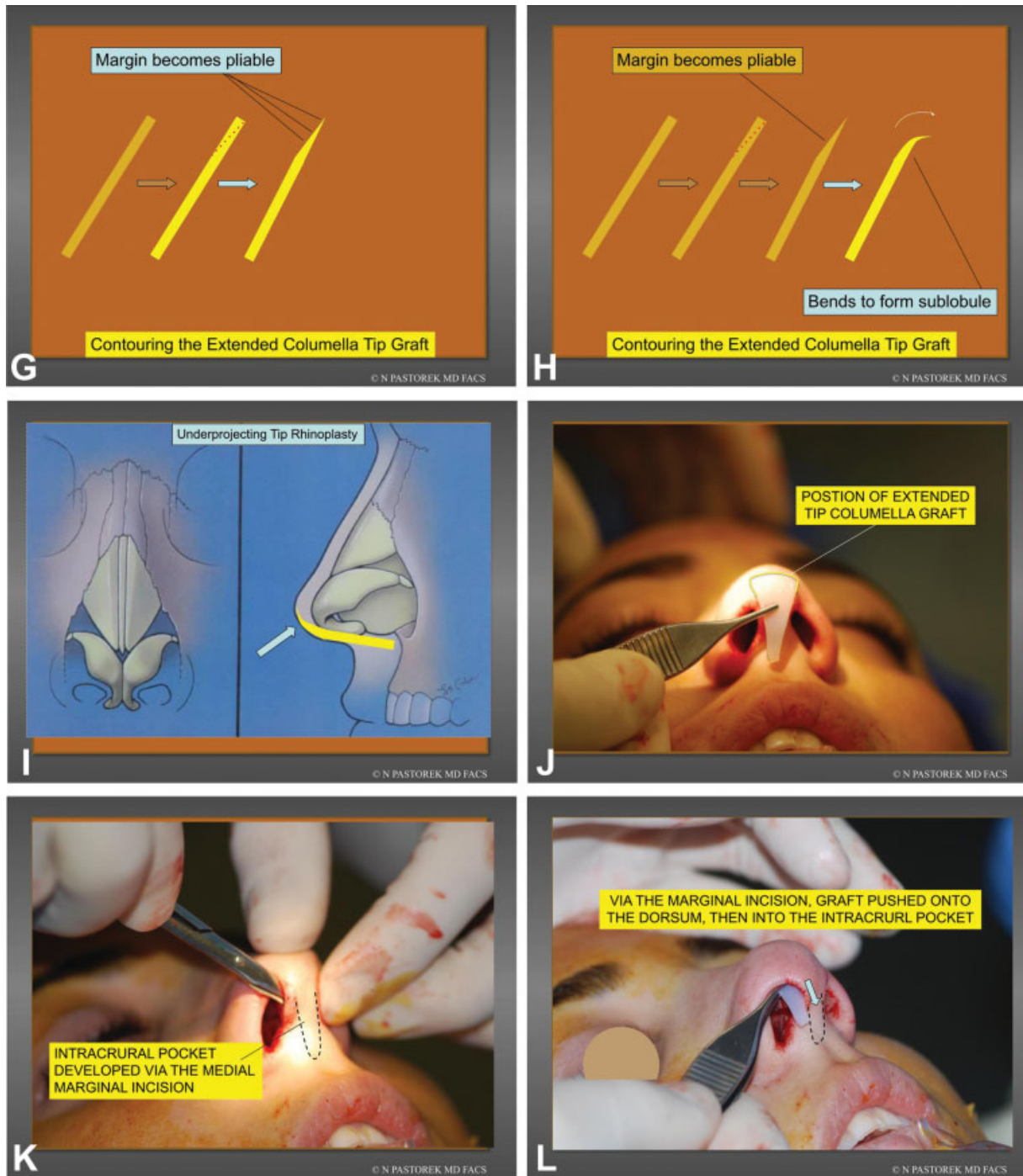


Fig. 7 (G-L) (Continued)

suture, a pocket is made between the feet of the medial crura extending down to, but not onto, the maxillary spine. A cartilaginous strut measuring approximately 1.75 cm in length is obtained from the nasal septum along the floor of the nose where the cartilage is the thickest. The graft is inserted between the domes and anchored in position with a single 4-0 chromic mattress suture through the feet of the medial crura and the strut. The last maneuver is the dome binding suture which projects the

domes and prevents the graft from migrating forward (► Fig. 6A-H).^{13,14}

The Extended Columella Tip Graft

Occasionally, the lack of nasal tip projection is profound. This severe type of LLC weakness is demonstrated by nasal tip digital pressure. When the nasal tip is compressed, the columella buckles vertically (► Fig. 7A). The author

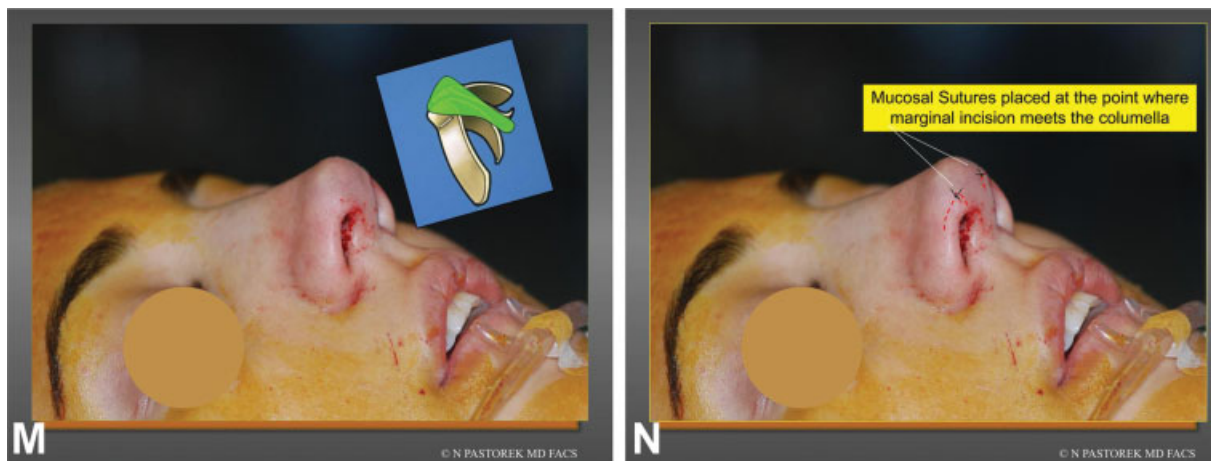


Fig. 7 (M–N) (Continued)

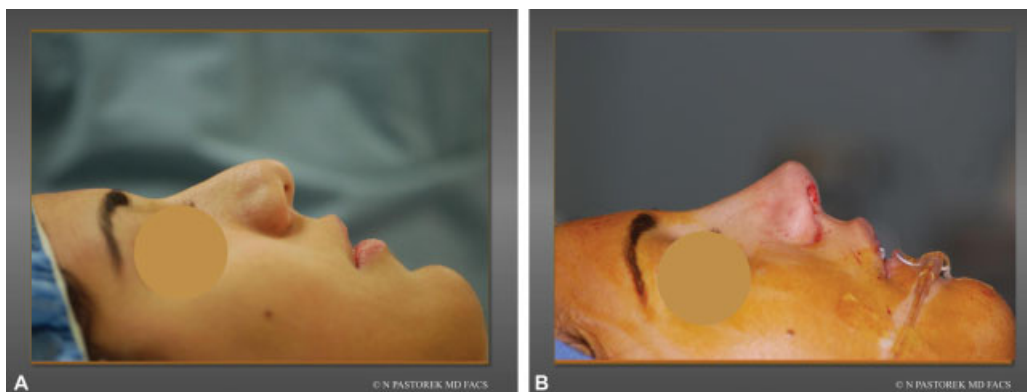


Fig. 8 (A) Preoperative view of a patient with extreme weakness of the LLC. (B) An immediate postoperative view of the patient following placement of the extended tip columella graft. LLC, lower lateral cartilage.

developed a large extended columella tip graft to overcome the marked nasal tip under projection in these cases. The graft was originally used in a secondary rhinoplasty where almost all lateral LLCs including the domes had been removed at the primary rhinoplasty.

A straight portion of nasal septal cartilage is required. In primary cases this is not usually a problem, however, a traumatized or absent cartilaginous septum will necessitate auricular or costal cartilage to fashion an adequate graft. Ideally, the graft starts as an isosceles triangle measuring 3 cm by 1.25 cm (► Fig. 7B). The long sides, but not the tip, are tapered slightly to resemble a thick golf tee. This helps to reduce the width of the columella. The small side of the triangle is shaved on one side so that this end of the graft begins to curve slightly. The surface will be the sublobule of the tip (► Fig. 7C–H). This prevents any “show” of the graft at the nasal tip (► Fig. 7I).

The extended columella tip graft is placed at conclusion of the rhinoplasty after all other maneuvers including the dome binding suture have been placed. All incisions are closed except the marginal incision on the right side (for a right-handed surgeon). A pocket is made with a curved Stevens scissors beginning at the base of the dome and

extending into the intercrural space down toward the premaxilla. The pocket must be wide enough to accept the graft. The extended columella tip graft is then grasped at the midsection with a Brown-Adson forceps. It is then pushed through the marginal incision until it is lying on the nasal dorsum. The graft is then moved downward until the pointed end is engaged in the intercrural pocket. This

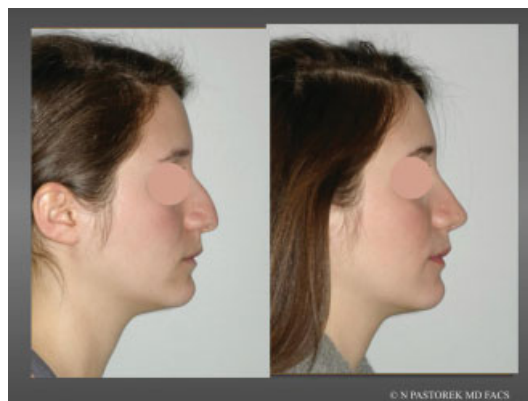

Fig. 9 Preoperative and 1-year postoperative view of a patient with an extended tip columella graft.

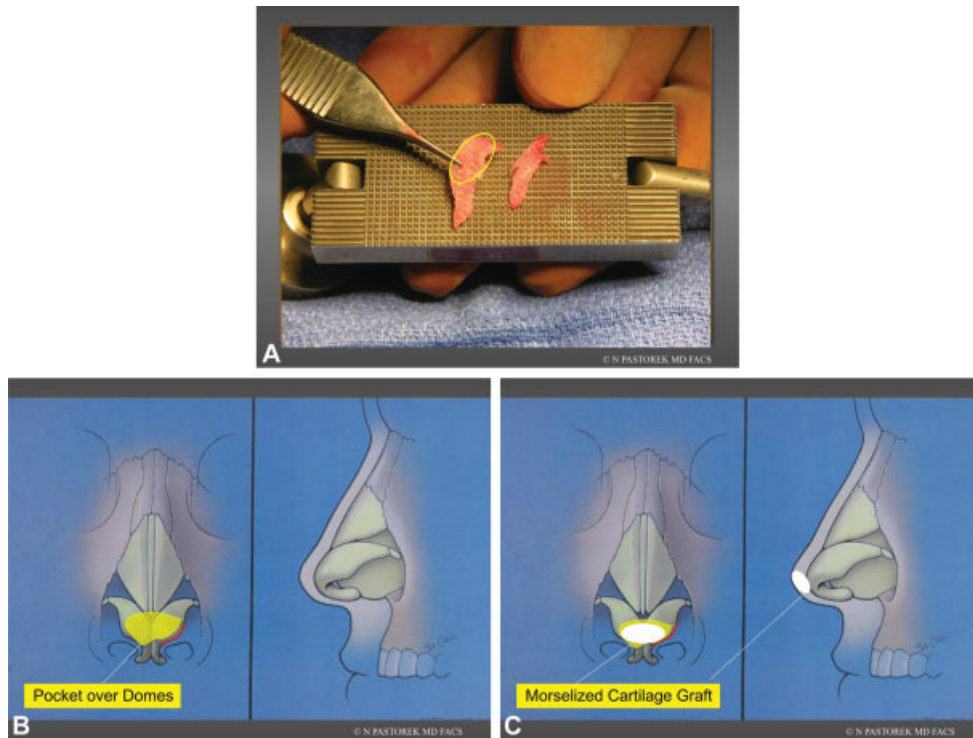


Fig. 10 (A) Morselized septal cartilage for nasal tip projection. (B) Development of a pocket over the domes. (C) Morselized septal cartilage positioned over the domes to give tip projection.

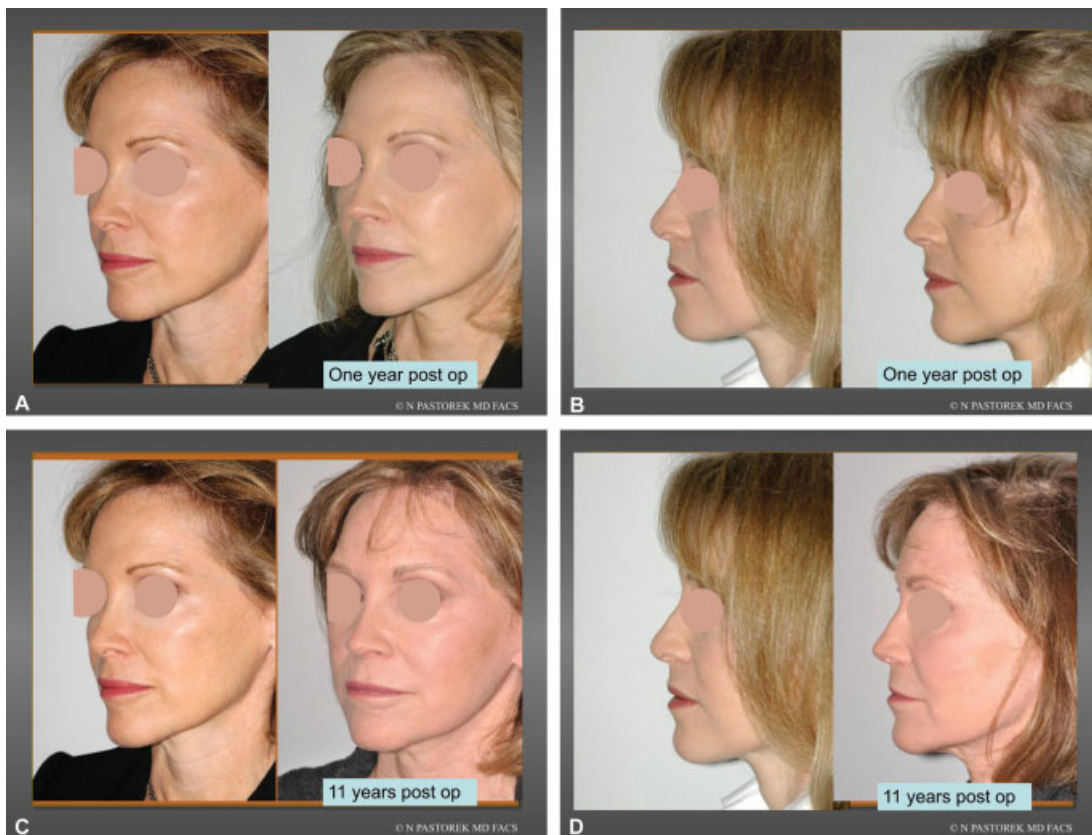

Fig. 11 (A) Oblique view of a patient with a morselized cartilage graft preoperatively and at 1 year. (B) Profile view of a patient with a morselized cartilage graft preoperatively and 1 year postoperatively. (C) Oblique view of a patient with a morselized cartilage graft preoperatively and at 11 years. (D) Profile view of a patient with a morselized cartilage graft preoperatively and 11 years.

downward movement is continued until the graft is completely seated with the broad end anterior to the bound domes. The long portion of the graft seated in the columella gives it stability. A single 4–0 chromic suture is placed at the most anterior end of the marginal incision on both sides to assure that the graft stays centrally positioned (►Fig. 7J–M, ►Fig. 8A, B, and ►Fig. 9).^{13–16}

Morselized Cartilage Tip Plumping Grafts

Occasionally, a rhinoplasty case presents with a history of minimal primary endonasal surgery and a complaint of nasal tip blunting. Upon palpation, the domes of the LLC are fairly unified and just slightly weak.

Years ago, the solution to this problem may have been a minimal procedure involving a firm tip graft in a precise tip pocket over the domes. While such an approach would look good for a while, time inevitably would shrink the precise pocket and show the graft edges in the nasal tip.

A better solution is to develop a pocket over the domes and use morselized septal cartilage to expand the nasal skin over the domes. The texture of the morselized cartilage should be that of a “wet cornflake.” In this manner, the tip is projected with minimal surgical effort and prolonged patient satisfaction (►Fig. 10A–C, 11A–D).¹⁰

Other Nasal Tip Projection Techniques

There are several additional nasal tip projection techniques, i.e., the septal extension graft and the tongue and groove procedure which do work effectively. However, these techniques can cause a distinct stiffness and immobility to the nasal tip. Many patients object to this. The nasal projection procedures discussed above project the nasal tip while leaving it mobile.^{3,12}

Conflict of Interest

None declared.

References

- 1 Constantian MB. The two essential elements for planning tip surgery in primary and secondary rhinoplasty: observations based on review of 100 consecutive patients. *Plast Reconstr Surg* 2004;114(06):1571–1581, discussion 1582–1585
- 2 Anderson JR. A reasoned approach to nasal base surgery. *Arch Otolaryngol* 1984;110(06):349–358
- 3 Williams EF III, Lam SM. A systematic, graduated approach to rhinoplasty. *Facial Plast Surg* 2002;18(04):215–222
- 4 Gunter JP. Anatomical observations of the lower lateral cartilages. *Arch Otolaryngol* 1969;89(04):599–601
- 5 Gunter JP. Tip rhinoplasty: a personal approach. *Facial Plast Surg* 1987;80:161–174
- 6 Bradley DT, Park SS. Preoperative analysis and diagnosis for rhinoplasty. *Facial Plast Surg Clin North Am* 2003;11(03):377–390
- 7 Pastorek N. Technical decisions in rhinoplasty. *Otolaryngol Head Neck Surg* 1995;112(05):
- 8 Anderson JR, Willett M. On planning before rhinoplasty. *Laryngoscope* 1984;94(08):1115–1116
- 9 Pastorek N. The art of local anesthesia surgery. *JAMA Facial Plast Surg* 2015;17(03):226–227
- 10 Pastorek N. Surgical management of the boxy tip. *Aesthet Surg J* 2007;27(03):306–318, quiz 319–321
- 11 Lee MR, Geissler P, Cochran S, Gunter JP, Rohrich RJ. Decreasing nasal tip projection in rhinoplasty. *Plast Reconstr Surg* 2014;134(01):41e–49e
- 12 Toriumi DM, Checcone MA. New concepts in nasal tip contouring. *Facial Plast Surg Clin North Am* 2009;17(01):55–90, vi
- 13 Pastorek N, Ham J. The underprojecting nasal tip: an endonasal approach. *Facial Plast Surg Clin North Am* 2004;12(01):93–106
- 14 Shah AR, Miller PJ. Structural approach to endonasal rhinoplasty. *Facial Plast Surg* 2006;22(01):55–60
- 15 Carron MA, Zoumalan RA, Pastorek NJ. Measured gain in projection with the extended columellar strut-tip graft in endonasal rhinoplasty. *JAMA Facial Plast Surg* 2013;15(03):187–191
- 16 Pastorek NJ, Bustillo A, Murphy MR, Becker DG. The extended columellar strut-tip graft. *Arch Facial Plast Surg* 2005;7(03):176–184