




An Interesting Case of Bilateral Hilar Lymphadenopathy Presented with Visual Impairment

Chandramouli MT¹ Nandakishore Baikunje¹  Sunil Kumar Y² Subrahmanya Bhat K³ Darshan Bajaj⁴
Giridhar Belur Hosmane¹

¹Department of Pulmonary Medicine, K S Hegde Medical Academy, Mangalore, India

²Department of Pathology, K S Hegde Medical Academy, Mangalore, India

³Department of Ophthalmology, K S Hegde Medical Academy, Mangalore, India

⁴Department of Pulmonary Medicine, King George's Medical University, Lucknow, India

Address for correspondence Chandramouli MT, MBBS, MD, Department of Pulmonary Medicine, K S Hegde Medical Academy, New Boys Hostel, KSHEMA Campus, Mangalore 575018, India (e-mail: mouli.aims@gmail.com).

J Health Allied Sci^{NU} 2022;12:330–332.

Abstract

Keywords

- EBUS TBNA
- granulomatous lesion
- sarcoidosis
- uveitis

Sarcoidosis is a systemic granulomatous disease of unknown etiology. It primarily affects the lungs and lymphatics; however, the presentation is not always pulmonary. Uveitis is the presenting symptom in 5% of patients, predominantly in females. Cystoid macular edema is the most important sight-threatening sequela of ocular sarcoidosis. Histopathological evidence of noncaseating epithelioid granulomas from a biopsy is the gold standard for the diagnosis of ocular sarcoidosis. Diagnosis of sarcoidosis is made by exclusion of other causes of granulomatous disease, mainly tuberculosis and fungal infection and documentation of involvement of at least one additional organ system. The authors present a case of a patient with sarcoidosis involving lungs and eyes, who had uveitis as an initial presentation.

Introduction

Sarcoidosis is a multisystem chronic inflammatory disorder of unknown etiology, characterized pathologically by noncaseating granulomas. It usually affects young adults with variable clinical presentation. The lung is the more frequently affected organ and accounts for morbidity and mortality associated with this disease. Other organs commonly involved include the eyes, skin, and lymph nodes.

The incidence and prevalence of sarcoidosis vary substantially, depending on the region of the world. It commonly

affects women than men. Diagnosis of sarcoidosis relies on compatible clinicoradiological findings and is supported by histopathological evidence of noncaseating epithelioid granulomas in involved organs, exclusion of other causes of granulomatous disease, mainly tuberculosis and fungal infection, and documentation of involvement of at least one additional organ system.

Corticosteroids are the mainstay treatment for sarcoidosis. Additional immunosuppressive agents including methotrexate, azathioprine, mycophenolate mofetil, infliximab, and adalimumab are used in refractory systemic sarcoidosis and lung transplantation in advanced lung disease.

published online
November 5, 2021

DOI <https://doi.org/10.1055/s-0041-1736454>.
ISSN 2582-4287.

© 2021. Nitte (Deemed to be University). All rights reserved.
This is an open access article published by Thieme under the terms of the Creative Commons Attribution-NonDerivative-NonCommercial-License, permitting copying and reproduction so long as the original work is given appropriate credit. Contents may not be used for commercial purposes, or adapted, remixed, transformed or built upon. (<https://creativecommons.org/licenses/by-nc-nd/4.0/>)
Thieme Medical and Scientific Publishers Pvt. Ltd., A-12, 2nd Floor, Sector 2, Noida-201301 UP, India

Case Report

A 59-year-old female presented with redness and blurring of vision in both eyes for 20 days. An ophthalmic evaluation showed panuveitis in both eyes. Physical examination and laboratory results were unremarkable. A chest X-ray was taken, which showed bilateral upper and midzone nodular opacities and hilar lymph nodes. Further contrast-enhanced computed tomography (CECT) thorax showed bilateral symmetrical parenchymal nodular and confluent peribronchovascular opacities, perilymphatic nodules, nodular thickening of the fissure, septa with upper lobe predominance, and bilateral hilar and mediastinal enlarged lymph nodes (►Figs. 1 and 2).

Flexible bronchoscopy (FB) followed by endobronchial ultrasound (EBUS) was planned and performed under moderate sedation, and no endobronchial lesions were visualized. Bronchoalveolar lavage (BAL) was taken and sent for bacterial and fungal culture. EBUS showed bilateral hilar, subcarinal, and right paratracheal nodes. EBUS-transbronchial needle aspiration (TBNA) and rapid on-site evaluation (ROSE) were done from the subcarinal lymph node and sent for cytology and GeneXpert (►Fig. 3). *Mycobacterium tuberculosis* was not detected in GeneXpert, and cytological examination of lymph node aspirate showed noncaseating granulomatous lymphadenitis (►Figs. 4 and 5). The BAL

culture showed no growth for both bacteria and fungus. The serum angiotensin-converting enzyme (ACE) and calcium levels were normal. In the Mantoux test, no significant induration was seen. Given the diagnosis of sarcoidosis

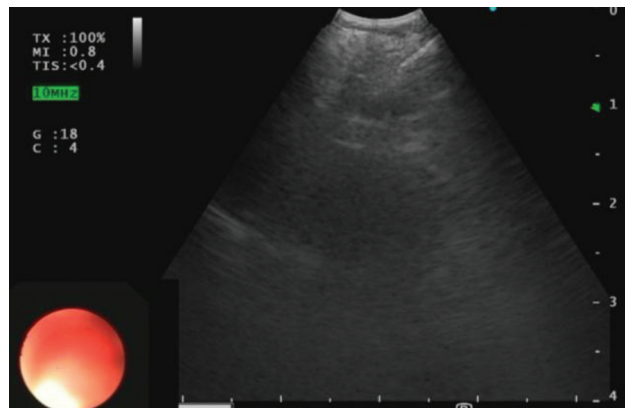


Fig. 3 Endobronchial ultrasound image demonstrating transbronchial needle aspiration from subcarinal lymph node.

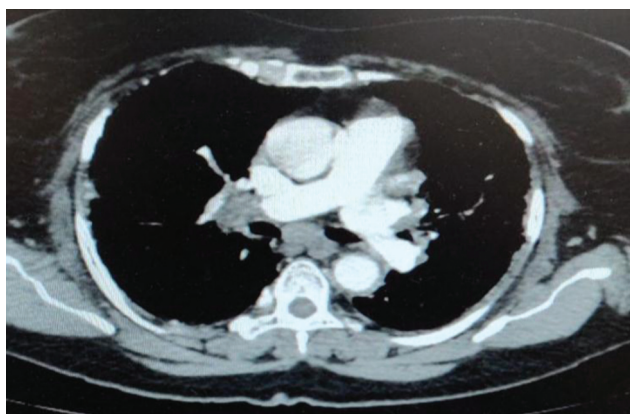


Fig. 1 Computed tomographic image of the chest demonstrating hilar and subcarinal lymph nodes.

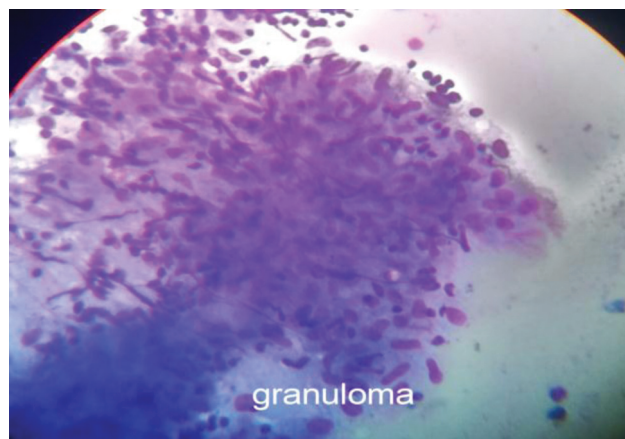


Fig. 4 Cytology of lymph node aspirate showing noncaseating granuloma.

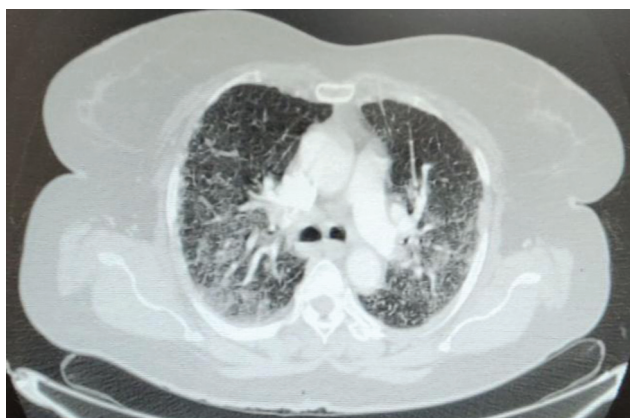

Fig. 2 Computed tomographic image of the chest demonstrating numerous perilymphatic nodules and peribronchovascular opacities.

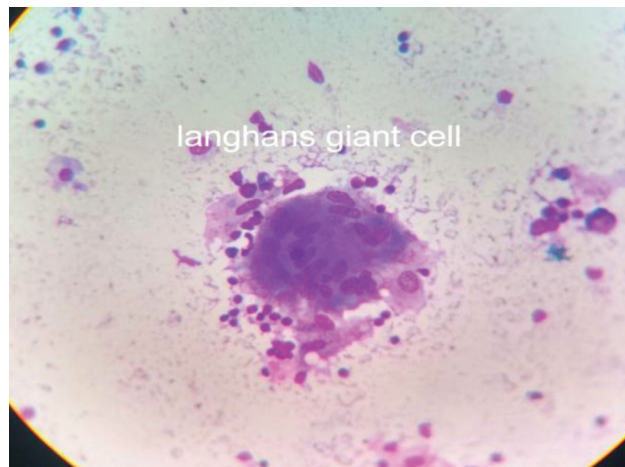

Fig. 5 Cytology of sarcoid granuloma showing Langerhans giant cell.

above, the patient was started on methylprednisolone pulse therapy, followed by oral corticosteroids.

Discussion

Sarcoidosis is a systemic chronic inflammatory granulomatous disease of unknown etiology. It usually affects young adults with variable clinical presentation. It can affect multiple organs to a varying extent and degree; lung involvement is frequent, but the presentation is not usually pulmonary. In 20 to 50% of patients, uveitis is an early feature of sarcoidosis.¹

The incidence and prevalence of sarcoidosis vary substantially, depending on the region of the world; women are commonly affected than men. Its incidence and prevalence are estimated at 15.3 to 21.7/100,000 and 10 to 20/100,000 population, respectively.² In India, sarcoidosis is an under-diagnosed disease.

Many patients with pulmonary sarcoidosis are asymptomatic with incidental chest radiograph findings. Common presenting respiratory symptoms include shortness of breath, cough, and chest pain. Wheezing may be present in patients with endobronchial involvement. Symmetrical and bilateral hilar lymphadenopathy is a classical chest radiograph finding, and right hilar adenopathy may be slightly more prominent.³ The lung parenchymal findings on the chest radiograph include diffuse reticular or ground-glass opacities, nodular opacities, and fibrocystic changes with mid-to-upper zone predominance. Bronchoscopic findings of sarcoidosis include nodules, plaques, erythema, and cobblestone appearance.⁴

Ocular sarcoidosis accounts for 10 to 50% of cases, including lacrimal gland enlargement.⁵ In A Case-Control Etiologic Study of Sarcoidosis (ACCESS study), a prospective study, 11.8% of patients had ocular manifestations as presenting symptoms.⁶ Sarcoidosis is the leading cause of uveitis in elderly patients.⁷ In retrospective series of histologically proven sarcoidosis, symptomatic uveitis accounts for 20 to 50%.⁸ Sarcoid uveitis is typically bilateral (80–90%), with anterior uveitis being the most common, accounting for 41 to 75% of sarcoid uveitis, followed by posterior, intermediate uveitis, and panuveitis.⁹ Panuveitis accounts for 7 to 14% of sarcoid uveitis and is one of the most important systemic associations in Japan and Europe.^{10,11}

Typical sarcoid uveitis presents with mutton-fat keratic precipitates, iris nodules (Koeppe, Busacca nodules), anterior and posterior synechiae, band keratopathy, and glaucoma. Posterior involvement includes vitritis, vasculitis, and chorioidal lesions. Cystoid macular edema is the most important and sight-threatening consequence of sarcoid uveitis.

No treatment is required for asymptomatic patients. In symptomatic patients, corticosteroids are the mainstay of treatment. Additional immunosuppressive agents including methotrexate, azathioprine, mycophenolate mofetil, infliximab, and adalimumab are used in refractory systemic sarcoidosis and lung transplantation in advanced lung disease.

EBUS-TBNA with ROSE has a good diagnostic yield and assists in safe, adequate specimen sampling with rapid results. EBUS-TBNA with or without ROSE is superior to conventional TBNA (c-TBNA) without ROSE in the diagnosis of sarcoidosis.¹²

Conclusion

Uveitis is a common extrapulmonary manifestation of sarcoidosis, particularly in females; however, due to lack of investigational modalities, it is underdiagnosed in India. EBUS-TBNA is exceptionally useful in the evaluation of mediastinal lymphadenopathy and early diagnosis of diseases like sarcoidosis.

Funding

None.

Conflict of Interest

None declared.

References

- Jamilloux Y, Kodjikian L, Broussolle C, Sève P. Sarcoidosis and uveitis. *Autoimmun Rev* 2014;13(08):840–849
- Crouser ED, Maier LA, Wilson KC, et al. Diagnosis and Detection of Sarcoidosis. An Official American Thoracic Society Clinical Practice Guideline. *Am J Respir Crit Care Med* 2020;201(08):e26–e51
- Spagnolo P, Rossi G, Trisolini R, Sverzellati N, Baughman RP, Wells AU. Pulmonary sarcoidosis. *Lancet Respir Med* 2018;6(05):389–402
- Sk S, Alladi M. Sarcoidosis in India: not so rare!. *J Indian Acad Clin Med* 2004;5(01):12–21
- Drent M, Costabel U. European respiratory monograph 32: sarcoidosis. European Respiratory Society 2005. Doi: 10.1183/1025448x.erm3205
- Baughman RP, Teirstein AS, Judson MA, et al; Case Control Etiologic Study of Sarcoidosis (ACCESS) research group. Clinical characteristics of patients in a case control study of sarcoidosis. *Am J Respir Crit Care Med* 2001;164(10 Pt 1):1885–1889
- Grégoire M-A, Kodjikian L, Varron L, Grange J-D, Broussolle C, Sève P. Characteristics of uveitis presenting for the first time in the elderly: analysis of 91 patients in a tertiary center. *Ocul Immunol Inflamm* 2011;19(04):219–226
- Khanna A, Sidhu U, Bajwa G, Malhotra V. Pattern of ocular manifestations in patients with sarcoidosis in developing countries. *Acta Ophthalmol Scand* 2007;85(06):609–612
- Rothova A, Alberts C, Glasius E, Kijlstra A, Buitenhuis HJ, Breebaart AC. Risk factors for ocular sarcoidosis. *Doc Ophthalmol* 1989;72(3–4):287–296
- Barisani-Asenbauer T, Maca SM, Mejdoubi L, Emminger W, Mac-hold K, Auer H. Uveitis- a rare disease often associated with systemic diseases and infections- a systematic review of 2619 patients. *Orphanet J Rare Dis* 2012;7:57
- Ohguro N, Sonoda KH, Takeuchi M, Matsumura M, Mochizuki M. The 2009 prospective multi-center epidemiologic survey of uveitis in Japan. *Jpn J Ophthalmol* 2012;56(05):432–435
- Madan K, Dhungana A, Mohan A, et al. Conventional transbronchial needle aspiration versus endobronchial ultrasound-guided transbronchial needle aspiration, with or without rapid on-site evaluation, for the diagnosis of sarcoidosis: a randomized controlled trial. *J Bronchology Interv Pulmonol* 2017;24(01):48–58