

Nerve-Sparing Robotic Radical Hysterectomy for the Beginner in Robotic Surgery

Yuji Hiramatsu, MD, PhD¹

¹Department of Obstetrics and Gynecology, Okayama City General Medical Center, Kita-Ku, Okayama, Japan

Address for correspondence Yuji Hiramatsu, MD, PhD, Okayama City General Medical Center, 3-20-1 Kitanagase-Omotemachi, Kita-Ku, Okayama 700-8557, Japan (e-mail: hiramatsu.enyu@gmail.com).

Surg J (NY) 2021;7(suppl S2):S84–S96.

Abstract

Robotic surgery is considered to be the optimal means of performing nerve-sparing radical hysterectomy (RH) because this procedure requires very precise surgery. Nerve-sparing RH has become increasingly popular in Japan. However, with open surgery the operating field is only visible to the surgeon performing this delicate procedure, which makes it difficult to educate trainee assistants. However, robotic surgery provides an expanded operation field that is visible to the surgeon and assistants, which makes it suitable for teaching purposes. To perform this procedure, it is necessary to become proficient in RH by laparotomy and then to become familiar with the characteristics of robotic surgery. In shifting from laparotomy to robotic surgery, we have found that experience with open surgery does not fully prepare surgeons for the new experiences and discoveries associated with robotic surgery, which may initially be problematic. We here provide clear instructions for the procedure with notes concerning particular potentially problematic aspects.

Keywords

- radical hysterectomy
- robotic surgery
- nerve-sparing
- cervical cancer
- complication

Steps in Performing Nerve-Sparing Radical Hysterectomy

1. Cutting the right broad ligament.
↓
2. Locating the right ureter.
↓
3. Opening the right pararectal space.
↓
4. Isolate and cutting the right uterine artery.
↓
5. Opening the right paravesical space.
↓
6. Separation, amputation, and clipping of the right uterine artery.

- ↓
7. Separating the right ureter.
↓
8. Cutting the right round ligament.
↓
9. Separating the urinary bladder.
↓
10. Dissecting the right pelvic lymph nodes.
↓
11. Performing procedures 1–10 on the left side.
↓
12. Cutting bilateral infundibulopelvic ligaments.
↓
13. Opening the pouch of Douglas.
↓
14. Separating the right hypogastric nerve and cutting the right uterosacral and rectovaginal ligaments.

published online
October 12, 2021

DOI <https://doi.org/10.1055/s-0041-1739121>.
ISSN 2378-5128.

© 2021. The Author(s).

This is an open access article published by Thieme under the terms of the Creative Commons Attribution-NonDerivative-NonCommercial-License, permitting copying and reproduction so long as the original work is given appropriate credit. Contents may not be used for commercial purposes, or adapted, remixed, transformed or built upon. (<https://creativecommons.org/licenses/by-nc-nd/4.0/>)

Thieme Medical Publishers, Inc., 333 Seventh Avenue, 18th Floor, New York, NY 10001, USA

- ↓
15. Creating a tunnel for the right ureter.
- ↓
16. Cutting the right deep uterine vein and separating the cut edge from the pelvic nerve plexus and hypogastric nerve.
- ↓
17. Cutting the right posterior vesicouterine ligament.
- ↓
18. Cutting the uterine branch of the right pelvic nerve.
- ↓
19. Cutting the right paracolpium.
- ↓
20. Perform procedures 14–19 on the left side.
- ↓
21. Amputating and suturing the vaginal wall.
- ↓
22. Suturing the bladder peritoneum, vaginal stump, and rectal peritoneum.
- ↓
23. Perform peritoneal lavage and achieve hemostasis.
- ↓
24. Removal of the patient cart and reconfirmation of hemostasis with a laparoscope.
- ↓
25. Placing drains and closing the abdominal wall incision.

Strategies

- The procedure can be performed in exactly the same way as open radical hysterectomy (RH),^{1–6} except that both infundibulopelvic ligaments are cut as late as possible to prevent the bowel from sagging into the field of view.
- In robot-assisted surgery, a very narrow area is enlarged and the operative procedure performed under zoomed-in vision. It is advisable for the operator to zoom out occasionally and proceed with a view of the whole operative field. Additionally, attention should be paid to the tilt of the camera, aiming to operate it at a normal angle as much as possible.
- Attempts must be made to use the third arm effectively.
- The operator should take care to clearly identify the ureter, lateral umbilical ligament (internal iliac artery), and uterine artery, and adequately develop the pararectal and paravesical spaces.
- The ureter, uterine artery, and hypogastric nerve, should be clipped or taped while performing the procedure to prevent accidental damage to them.
- Sufficient lymphatic and connective tissue around the cervix and the cardinal ligament should be removed while performing the procedure to enable confirmation that the nerves remain intact.
- The operator should keep in mind the risk of heat damage from using a power source.

Note

Smoothly opening the pararectal and paravesical spaces and identifying the three landmark tissues, namely, the ureter, uterine artery, and lateral umbilical ligament (internal iliac artery) can be a major problem for surgeons who change from performing open RH to robotic RH. Overcoming this obstacle makes it possible for surgeons who have performed many open RHs to successfully perform nerve-sparing robotic RH. This can be achieved by watching many videos and becoming familiar with the view of the surgical field from the position of the navel with the pelvis in a 30° head-down position.

RH requires expansion of six cavities surrounding the uterus, namely, the vesicouterine pouch (Retzius pouch), the rectouterine pouch (pouch of Douglas), and the paravesical and pararectal spaces bilaterally to enable visualization of the ligaments, blood vessels, and nerves. If the directions and layers are wrong, there is a risk of massive bleeding which could obstruct the visual field, making completion of the procedure extremely difficult. ▶**Fig. 1** shows the points of entry to each cavity.⁵

Procedure on a Representative Case

Age 40 years, cervical cancer stage Ib1

Robot Equipment used: da Vinci Surgical System S

Port Arrangement

Camera port: 20 cm cephalad to the pubis (~3 cm beyond the navel), 12 mm trocar.

First arm port: 8–10 cm to the right of the camera port, 1 to 3 cm caudad to it, 8 mm trocar.

Second arm port: 8–10 cm to the left of the camera port, 1 to 3 cm caudad to it, 8 mm trocar.

Third arm port: 8–10 cm to the left of the second port, 1 to 3 cm caudad to it, 8 mm trocar.

Assistant port: 8–10 cm to the right of the first port, 1 to 3 cm caudad to it, 12 mm trocar.

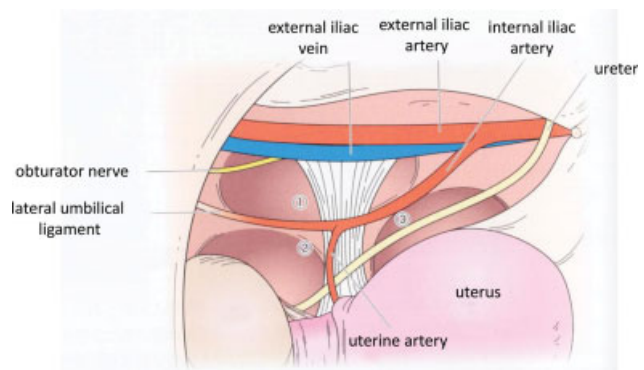


Fig. 1 Entrances of paravesical and pararectal space. ① paravesical space: between external iliac arteries and veins and lateral umbilical ligament. ② paravesical space: inside the lateral umbilical ligament, caudal to the uterine artery. ③ pararectal space: between ureter and internal iliac artery.

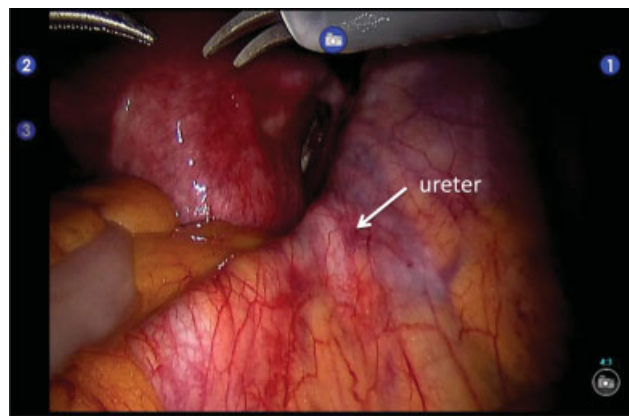


Fig. 2 Confirmation of ureter. Identify the ureter that crosses over the right common iliac artery and vein.

Equipment Setup

Patient cart: left parallel docking.

Patient position: lithotomy position with the pelvis raised at an angle of 30°.

Camera scope: this port is 20 cm cephalad to the pubis and uses a direct scope

First arm (right): monopolar curved cautery scissors, a large needle driver being substituted when sewing.

Second arm (left): Maryland bipolar.

Third arm (left): fenced forceps.

Step 1. Cutting the Right Broad Ligament

First, the condition of the abdominal cavity is inspected. In this case, the ureter can be seen crossing the common iliac arteries and veins (►Fig. 2). A transverse incision is made in the broad ligament cephalad to the right round ligament, the so-called pelvic side wall triangle (the triangular part surrounded by the round ligament, the external iliac arteries and veins, and the infundibulopelvic ligament) (►Fig. 3A), followed by cutting up along the infundibulopelvic ligament to the point where the ureter intersects with the common iliac artery (►Fig. 3B). At this time, tilting the uterus anteriorly and to the left while pulling the round ligament caudad via the third arm will readily provide a good visual field.

Step 2. Locating the Right Ureter

The ureter is located where it intersects the common iliac artery; identification of the ureter will facilitate subsequent maneuvers. Once located, the ureter is followed caudad to determine its course. At this time, pulling the ovarian ligament posteriorly with the third arm makes it easier to obtain an adequate visual field.

Step 3. Opening the Right Pararectal Space (Latzko Space)

After adequately determining the course of the ureter, the common iliac artery is traced caudad to identify the internal iliac artery, after which the space between the ureter and internal iliac artery is opened and the pararectal space expanded.^{1–4} The sparse tissue is deployed by alternately moving it up and down and left and right with the left and right arms (►Fig. 4), taking care to follow the curvature of the sacrum because there are vulnerable veins on its surface.

Tips and Notes

With the head angled 30° downward, an incision is made in the broad ligament cephalad to the round ligament, and the region expanded posteriorly, often resulting in entering the paravesical space instead of the pararectal space. Beginners need to recognize that the pararectal space is much more cephalad than they think. Therefore, we recommend that beginners approach the pararectal space from the cranial side, as described later.

Step 4. Isolation and Cutting of the Right Uterine Artery

Expansion of the pararectal space caudally enables visualization of the uterine artery, which branches from the internal iliac artery and runs diagonally toward the opposite leg. (►Fig. 5). The surrounding connective tissue is removed, freeing the uterine artery.

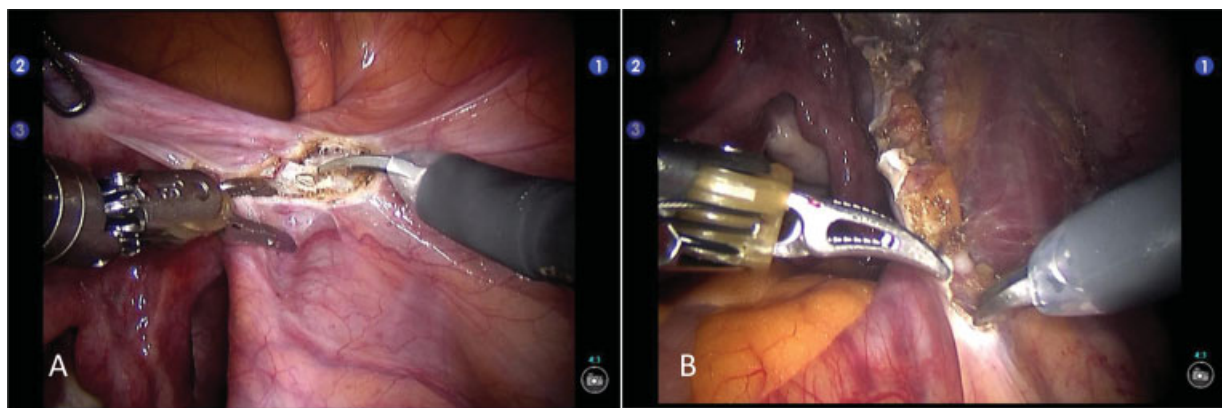


Fig. 3 Incision of the pelvic side wall triangle. In this case, the ureter is visible in the area where the ureter intersects the common iliac arteries and veins, so the incision is made while conscious of it. (A) Grasping the round ligament with the third arm and incising the broad ligament. (B) Expand this incision upward along the infundibulopelvic ligament.

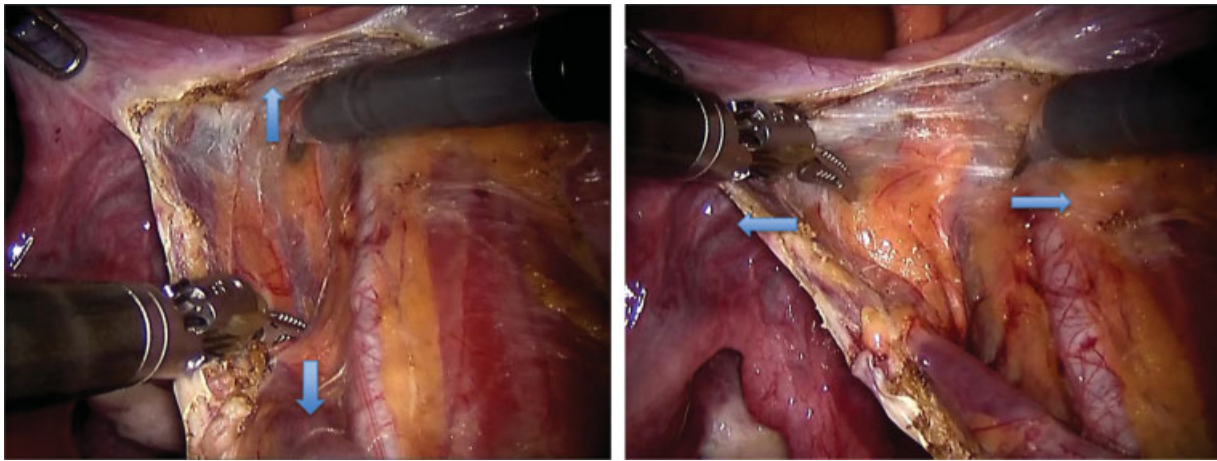


Fig. 4 Deployment of right pararectal space. When the space between the ureter and the internal iliac artery is deployed, a sparse dent appears, so the left and right arms are moved alternately forward and backward and left and right to develop the space.

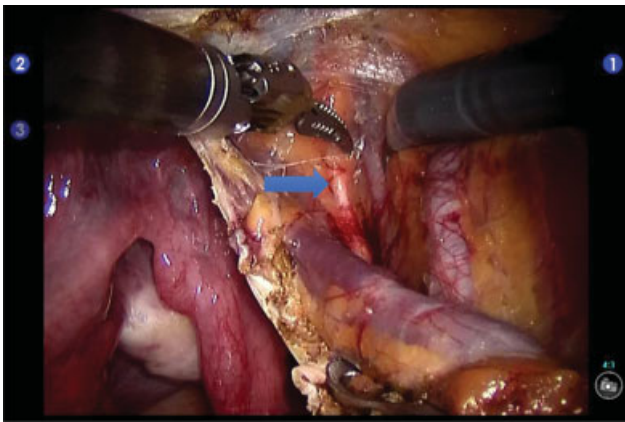


Fig. 5 Deployment of right pararectal space. By further developing the pararectal space, the uterine artery running parallel to the internal iliac artery can be found (arrow). If you are looking for an image where the uterine artery branches at a right angle from the internal iliac artery, as in the case of open RH, you cannot find it.

Tips and Notes

Tips for finding the uterine artery

When performing open RH, the paravesical and pararectal spaces are expanded and a right-angled hook inserted with the lateral umbilical ligament lateral to it and pulled caudad while pulling the uterus contralaterally cephalad. The cardinal ligament is marked, and the uterine artery identified running along a ridge. When located in this way, the uterine artery appears to branch from the internal iliac artery at almost a right angle. However, because no hooks are deployed with robotic RH, the uterine artery cannot be identified if searched for with this orientation in mind. Rather, the operator must search for it with a mental image of it, branching from the trunk of a tree or running parallel to the internal iliac artery and ureter. (→Fig. 5).

Tips and Notes

Tips for finding the ureter

When inspecting the inside of the abdominal cavity with a laparoscope before docking, the point of intersection of the ureter with the common iliac artery can readily be found on the right side. However, this intersection may not be visible on the left side. Thus, it is helpful to prepare the colon laparoscopically to enable visualization of this intersection.

Even if the intersection is visible through a laparoscope, it may be difficult to visualize it with the robot. This depends on the degree of pelvic elevation, the position of the camera port, and whether a direct view scope or a 30° perspective scope is used.

Three Approaches to Locating the Uterine Artery and Ureter

It is necessary to be fully aware that there are various approaches to locating the uterine arteries and ureters.

(1) Cephalad Approach

When the ureter is found at the intersection of the common iliac arteries and veins (→Fig. 2), the internal iliac artery branching off the common iliac artery can also be located in the vicinity of the ureter (→Figs. 1 and 4). Next, the region between the internal iliac artery and ureter is opened and the pararectal space expanded, which enables identification of the uterine artery branching from the internal iliac artery (→Fig. 5). It is important to keep in mind that the uterine arteries may appear to run parallel to the internal iliac arteries.

(2) Side Approach

The pelvic side wall triangle broad ligament is incised cephalad to the right round ligament, the pararectal space expanded, and the internal iliac and uterine arteries identified. At this time, the lateral umbilical ligament is always visible caudally, so it is the internal iliac artery that can be found by imagining that it is on the extension of that line. In both this and the cephalad approach, the uterine artery often appears to run parallel to the internal iliac artery.

When the uterine artery is released and separated posteriorly, the ureter can be found attached to the posterior lobe of the broad ligament.

(3) Anterior Approach

The second assistant tilts the uterus posteriorly and to the left side. The broad ligament is extended caudad to the round ligament, the bladder peritoneum dissected from this region, the round ligament pulled anteriorly and to the right, exposing the lateral umbilical ligament, and traced cephalad and the superior vesical and uterine arteries identified. The uterine artery is then separated medially and its intersection with the ureter near the uterine wall located.

We prefer the cephalad approach when the intersection of the ureter with the common iliac artery is visible. If this method cannot be performed, either the second or third approaches are used. In any case, it is important to understand the three-dimensional anatomy of the three structures between the ureter, uterine artery, and lateral umbilical ligament (internal iliac artery). Once one of these three landmarks has been found, the other two can be developed in sequence.

Step 5. Opening of the Right Paravesical Space

The paravesical space, which is located caudal to the uterine artery and medial to the lateral umbilical ligament, is expanded¹⁻⁴ (► Fig. 6).

When deploying the paravesical space, the adipose tissue on the uterine side must be scraped off to enable managing the posterior layer of the vesicouterine ligament, as described below.

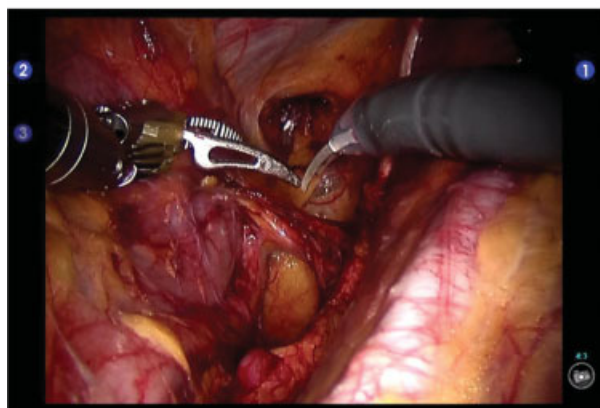


Fig. 6 Opening of the right paravesical space. If the caudal part of the uterine artery and the inside of the lateral umbilical ligament are expanded, the paravesical space can be expanded.

Step 6. Separation, Amputation, and Clipping of Right Uterine Artery

After the paravesical and pararectal spaces have been fully deployed, the uterine artery is separated toward the uterus (► Fig. 7), then clipped and coagulated with bipolar cautery or LigaSure®. Given that robotic procedures involve considerable zooming in, clipping of the uterine side stump of the uterine artery is useful as a marker when subsequently digging a tunnel for the ureter.

Tips and Notes

The superficial uterine vein runs posterior to the uterine artery and must be separated from it and cut so as not to damage it. This procedure can be performed more easily during robotic than laparotomy surgery because of the viewing angle. Separation of the uterine artery and vein together makes subsequent manipulation of the ureteral tunnel difficult.

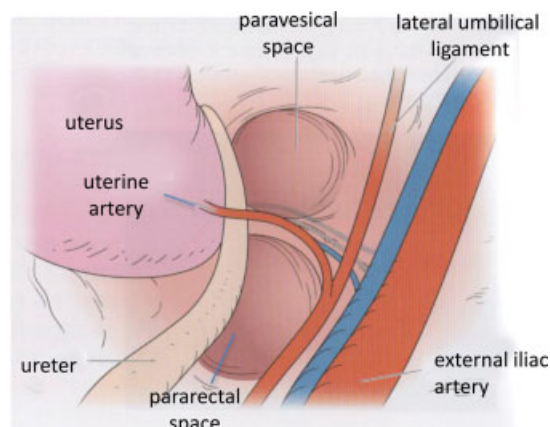
Step 7. Separating the Right Ureter

The ureter is separated from the posterior lobe of the broad ligament, peeled back to the entrance of the ureteral tunnel, and marked with tape. Care must be taken to prevent damage to the adventitia and muscular wall of the ureter because, if the ureter is touched during the procedure, bleeding can occur from surrounding small blood vessels. Stopping such bleeding with a power source increases the risk of ureteral injury.

Thus, taping of the ureter enables confirmation of its position at a glance, which is useful when forming a ureteral tunnel because the tape can be pulled without damaging the ureter.

Step 8. Cutting of the Right Round Ligament

The right round ligament is coagulated and cut, after which the anterior broad ligament is incised toward the bladder.



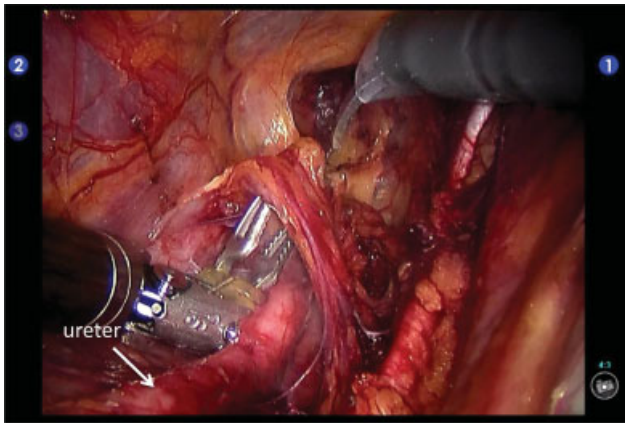


Fig. 7 Separation of the uterine artery. Scoop the uterine artery with Maryland forceps and dissect the connective tissue at the end of the forceps with a monopolar to make a hole and release the uterine artery.

Step 9. Separating the Urinary Bladder

It is important for the second assistant to assist the manipulator such that the operator can visualize the position of the cup of the V-Care® uterine manipulator. The region of separation is then under good tension. Next, the tissue is solidified slightly by minimal application of the power source, following which it is peeled off by pushing with the back of some scissors (→ Fig. 8). Separation of the bladder should begin in the central cervix and spread laterally and expose the anterior layer of the vesicouterine ligament.

Step 10. Dissecting the Right Pelvic Lymph Nodes

Pelvic lymph node dissection can be performed systematically by the same procedure as during open RH.^{1–4,6} It is important that both ends of the lymph vessels are clipped or solidified with LigaSure® to prevent postoperative development of lymphatic cysts.

① Common iliac and external iliac lymph nodes

Lymph node dissection begins on the surface of the common iliac and external iliac arteries, which are less prone to vascular injury. The assistant pulls the intestinal tract cephalad and develops the operative field. The lymph duct is clamped just above the point where the ureter crosses the common iliac artery and the lymph nodes on the common iliac artery dissected caudad. Subsequently, the lymph nodes on the external iliac artery are removed (→ Fig. 9) and the vascular sheath around the external iliac artery and vein separated and removed. The pudendal femoral nerve, which runs along the surface of the iliopsoas muscle with the external iliac artery, is preserved as much as possible.

Tips and Notes

The subsequent part of the procedure will be easier if clean dissection and removal of the vascular sheath and complete

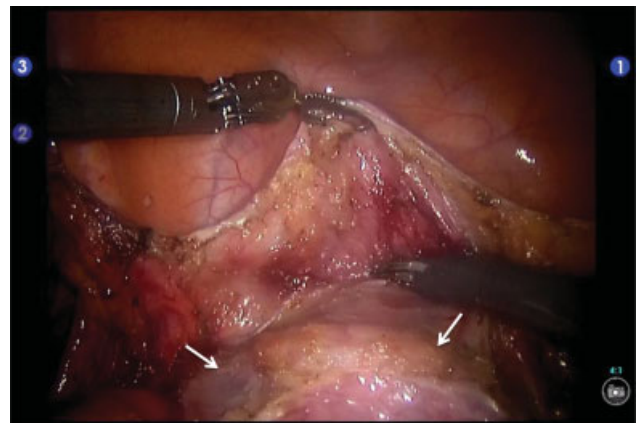


Fig. 8 Separating the urinary bladder. Check the position of the V-Care cup (arrow) and use it as a guideline to remove the bladder.

dissection of the pelvic lymph nodes is achieved. In addition, even if a large blood vessel is accidentally injured, achieved hemostasis is facilitated because the blood vessel has already been exposed. This is why lymph node dissection is performed after separation of the vascular sheath.

② Lateral suprainguinal lymph nodes

The field of view required for dissecting the lateral suprainguinal lymph nodes is obtained by pulling the cut end of the round ligament caudad with the third arm. Care must be taken not to dissect this area excessively, otherwise leg edema may develop postoperatively. It is also important to note that there may be an iliac circumflex vein in this area. The surgeon should also try to preserve the thick lymphatic vessels that run anterior to the iliopsoas muscle.

③ Medial suprainguinal and obturator lymph nodes

After sufficient expansion of the paravesical space has been achieved, the region between the external iliac arteries and veins and the iliopsoas muscle is expanded. Adequate displacement of the external iliac arteries and veins

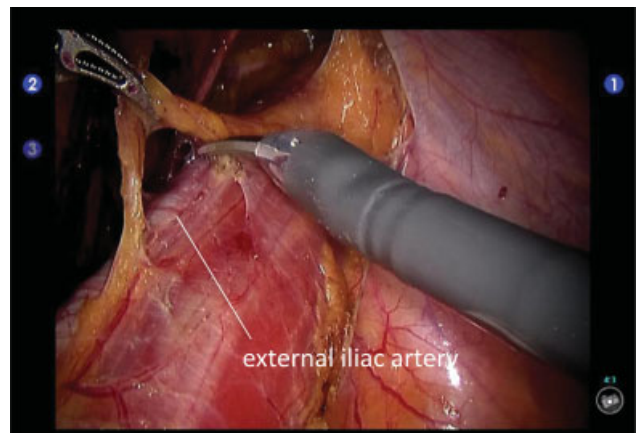


Fig. 9 Pelvic lymph node dissection. It can be removed by the same procedure as systematic pelvic lymph node dissection at open radical hysterectomy (RH). The picture shows lymph node dissection around the external iliac artery. The vascular sheath is released to show external iliac artery.

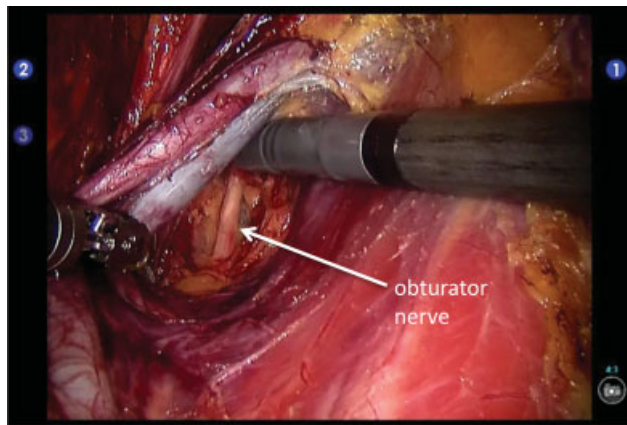


Fig. 10 Obturator lymph node dissection. Release the external iliac arteries and veins from the iliopsoas muscle. Obturator nerve can be found by advancing the development of loose areolar tissue while coagulating venules. Lymphoid tissue is detached from the iliopsoas muscle and pushed inward.

medially with the third arm creates a wide visual field. Keeping in mind that there are venules between the external iliac vein and the iliopsoas muscle in some cases, the lymphatic tissues are detached from the iliopsoas muscle and moved medially while coagulating and cutting the small blood vessels. The obturator nerve may be identified during this process as a whitish thread (►Fig. 10). The medial suprainguinal and obturator lymph nodes can be dissected en bloc (►Fig. 11).

In robotic surgery, the obturator veins can be clearly seen running dorsal to the obturator nerve, which enables their preservation in most cases; however, they may have to be cut. Carefully remove the lymph nodes and fat posterior to the obturator nerve.

④ Internal iliac lymph nodes

First, the lymph nodes around the cardinal ligament are dissected, the courses of the external iliac artery and vein, internal iliac artery, ureter, and obturator nerve reconfirmed, and this vascular trigone expanded with the third arm, after which the internal iliac lymph nodes are dissected. The internal iliac vein runs at the bottom of this site, and it is a dangerous site where bleeding is difficult to stop, so operate it carefully. The cephalad end of the dissected lymphoid tissue must be clipped or coagulated with LigaSure®.

After opening the piriformis fascia during dissection of the internal iliac lymph nodes, the pelvic origin of visceral nerve S2 may become visible. After dissection of the piriformis fascia, dissection in a caudad direction also involves dissection of the remaining cardinal ligament nodes, and the cardinal ligament is marked.

Tips and Notes

Use of monopolar cautery scissors around the obturator nerve involves considerable power; thus, the legs may

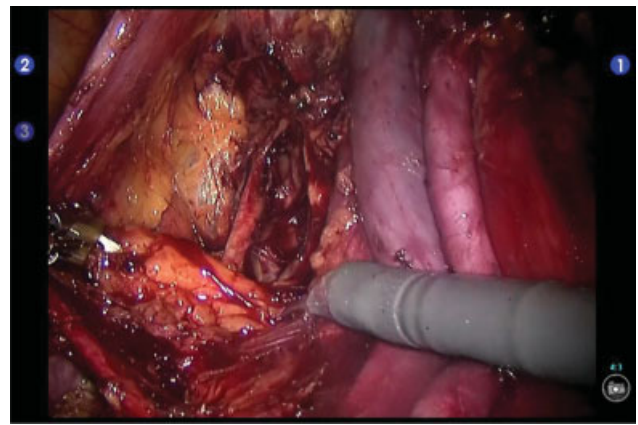


Fig. 11 Right pelvic lymph node dissection. The lymph nodes that have been detached from the iliopsoas muscle and sent inward are removed as *en bloc*.

move even when operating the scissors far away from the obturator nerve. In addition, because damage to the S2 pelvic visceral nerve will result in sciatic nerve damage, it is important to refrain from using a power source in this area. Therefore, at this site, the assistant must use suction to remove residual lymphoid tissue.

Step 11. Performing Procedures 1–10 on the Left Side

►Fig. 12 shows the left pelvic cavity expanded in the same way.

Step 12. Cutting bilateral Infundibulopelvic Ligaments

The infundibulopelvic ligaments are clipped or coagulated with LigaSure® and then cut bilaterally. At the same time, the posterior lobe of the broad ligament is incised to the uterosacral ligament.

Step 13. Opening the Pouch of Douglas

The posterior lobe of the broad ligament is incised toward the uterosacral ligament, while the second assistant tilts the uterus anteriorly so that the pouch of Douglas can be seen. The first assistant then pulls the rectum cephalad to stretch the pouch of Douglas and incises its peritoneum, after which the left and right forceps are moved left and right and back and forth to open the rectovaginal space to the rectovaginal ligaments (►Fig. 13).

Tips and Notes

When dissection is performed near the rectum, bleeding that is difficult to stop may occur as a result of damage to veins on the surface of the rectum. From this point to completion of the procedure, nerve preservation is a top priority. To this end, it is necessary to be familiar with the course of the hypogastric nerve and its uterine branches and the bladder branches that separate from the pelvic

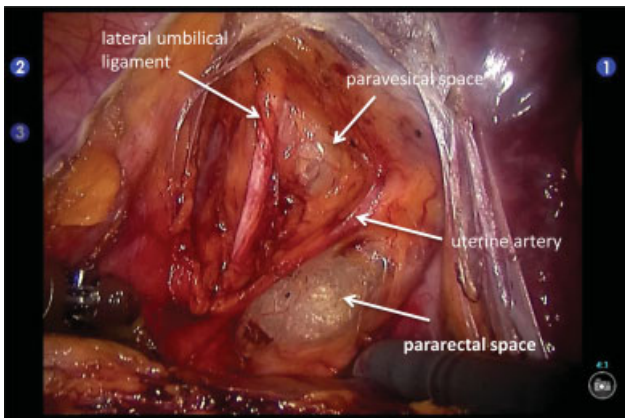


Fig. 12 Deployment of the left paravesical and pararectal space. The left paravesical and pararectal space are developed, and the internal iliac artery and the uterine artery running on the ridge of the cardinal ligament are observed.

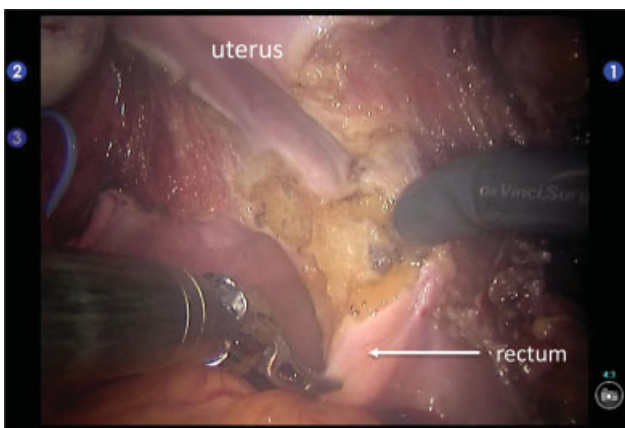


Fig. 13 Deployment of rectovaginal space. The *cul de sac* peritoneum is incised, and the rectovaginal space is opened by moving the left and right forceps left and right and back and forth.

nerve plexus. Expansion is achieved in the space indicated by the arrow, the uterine branches are cut, and finally the bladder branches are preserved as a nerve plane⁵ (► Fig. 14). Performing this maneuver enables cutting of the paravaginal tissue without causing nerve damage.

Step 14. Separating the Right Hypogastric Nerve and Cutting the Right Uterosacral and Rectovaginal Ligaments

The pararectal space of Okabayashi is expanded and the uterosacral ligament is cut. The hypogastric nerve and rectovaginal ligament are separated, and the rectovaginal ligament is cut with LigaSure®. The hypogastric nerve bundle is then taped (► Figs. 15 and 16). If followed, it will be found to join the pelvic nerve plexus in the lower cardinal ligament.

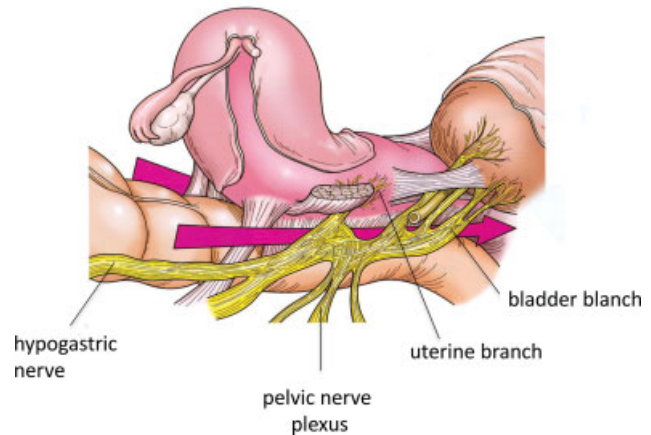


Fig. 14 Schematic diagram of nerve running around the uterus. For nerve sparing radical hysterectomy (RH), it is necessary to understand the running of nerves around the uterus. (Yoshikawa H, OGS NOW 5³).

Step 15. Creating a Right Ureteral Tunnel

After confirming that the bladder has been sufficiently dissected and the vesicouterine ligament has been marked, a ureteral tunnel is created. The ureteral tape is pulled by the third arm, the uterine artery stump lifted by the second arm, and the anterior layer of the vesicouterine ligament is divided while checking the running of the ureter (► Fig. 17).

During this part of the procedure, several blood vessels (cervicovesical vessels) need to be cut; however, this is easy to do because the small vessels are magnified and can be easily identified. At the end of maneuver, the ureter is released, allowing for so-called ureteral rolling (► Fig. 18), and a depression (Okabayashi's vaginal cavity) becomes apparent.

Tips and Notes

After this step, the most important consideration is avoidance of heat damage to the nerves and ureters. Because the power of monopolar cautery scissors is strong, the structure to be incised is always pulled and tensioned, and the necessary minimum coagulation and incision deployed, after which the structure is pushed away with the back of the monopolar scissors. LigaSure® should be used when cutting thicker blood vessels and tissues.

In robotic surgery, it is necessary to pay meticulous attention to potential heat damage: a nerve may lose its function despite being preserved anatomically. It is important to keep this in mind and to operate with extreme care.

Step 16. Cutting the Right Deep Uterine Vein and Separating the Cut Edge from the Pelvic Nerve Plexus and Hypogastric Nerve

If the cardinal ligament lymph nodes are still in situ at this point, dissecting them will reveal the deep blood vessels of the cardinal ligament (► Fig. 19). The surrounding tissues are

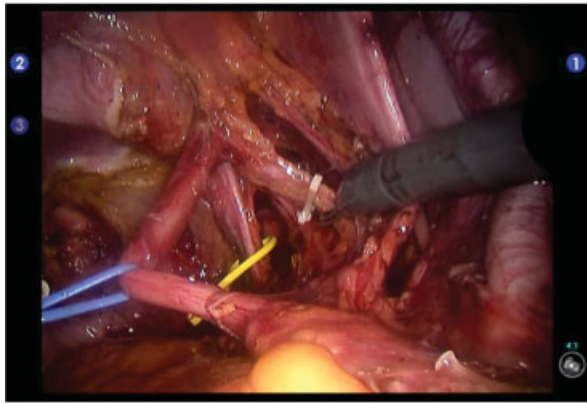


Fig. 15 Scene at the end of pelvic lymph node dissection ①. The uterine artery (clipping), ureter (blue tape), and hypogastric nerve (yellow tape) are separated, and the running is shown.

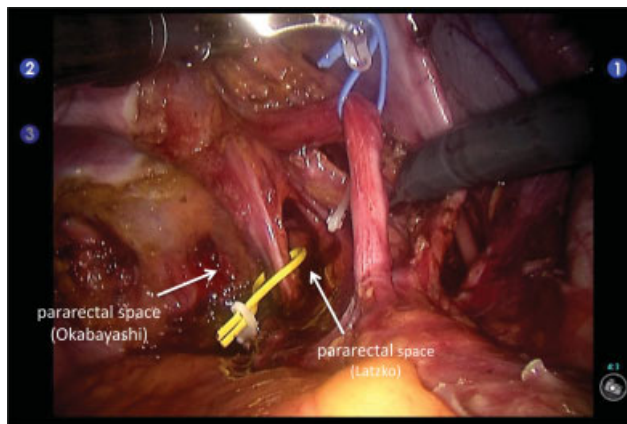
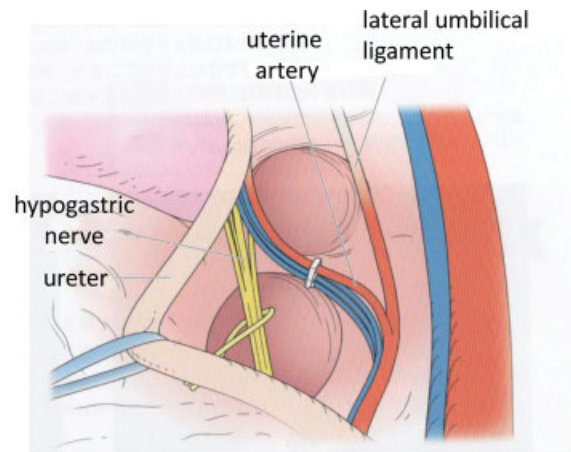


Fig. 16 Scene at the end of pelvic lymph node dissection ②. The uterine artery (clipping), the ureter (blue tape), and the hypogastric nerve (yellow tape) were separated, and their running were revealed.

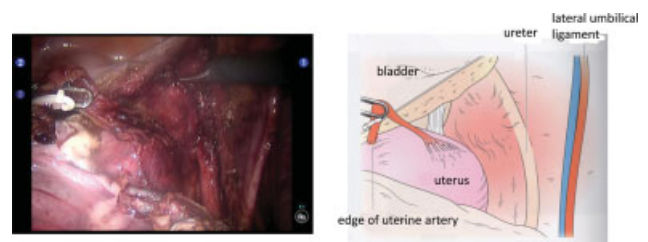


Fig. 18 Dissection of the anterior layer of the right vesicouterine ligament. Dissect the anterior layer of vesicouterine ligament while coagulating and cutting several cervicovesical vessels in this step, but this operation is easy, because they are enlarged and look good. At the end of this procedure, the ureter is released, allowing for so-called “ureter rolling,” and the posterior layer of the vesicouterine ligament appears.

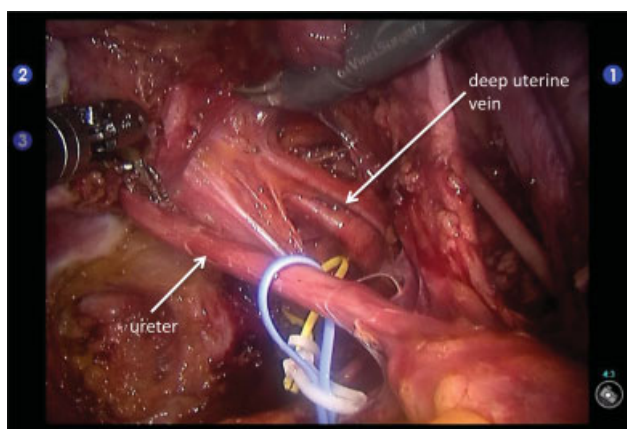


Fig. 17 Creating a ureteral tunnel. The ureteral tunnel is dug while pulling the uterine artery stump. Minimization of monopolar use and effective use of LigaSure® are important for nerve sparing.

excluded, and the superficial and deep uterine veins released, coagulated, and cut with LigaSure® (►Fig. 20). The deep uterine vein is clipped, so that it can be readily identified and, while pulling on its stump, the cervical side wall is

cut off (►Fig. 21), keeping in mind that the number of deep uterine veins varies.

This procedure achieves good visualization of the course of the pelvic nerve plexus of the cardinal ligament.

Step 17. Cutting the Right Posterior Vesicouterine Ligament

Again, returning to dealing with the ureter, it is rolled sufficiently to access the posterior vesicouterine ligament. While operating in this area, the remaining lymph nodes in the paravesical space should be rechecked. If they are still in situ, the adipose tissue on the lateral cervix and back of the bladder should be scraped off, during which it is very important to use the manipulator and third arm to maintain tension on the posterior vesicouterine ligament.

Once the connective tissue in the posterior vesicouterine ligament has been removed, a bladder vein connecting to the deep uterine vein becomes visible. This should be separated and cut with LigaSure® (►Fig. 22). When the posterior vesicouterine ligament has been freed up, the bladder and ureter can be moved away from the cervix to secure a large operative field.

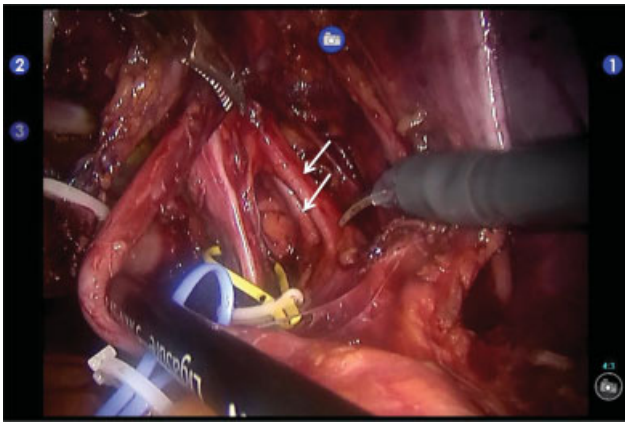


Fig. 19 Cutting the right deep uterine vein. Superficial and deep uterine veins of the cardinal ligament can be confirmed (arrows). Ureter (blue tape), hypogastric nerve (yellow tape).

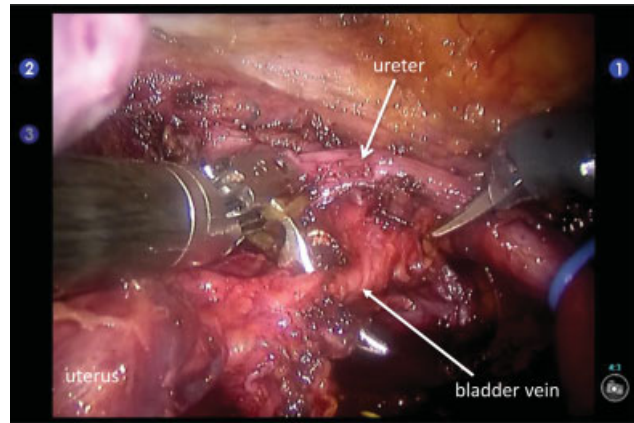


Fig. 22 Transect the bladder vein in the posterior layer of the vesicouterine ligament. Cutting of the bladder vein in the posterior layer of the vesicouterine ligament widens the operative field and makes the pelvic nerve bladder branch visible.

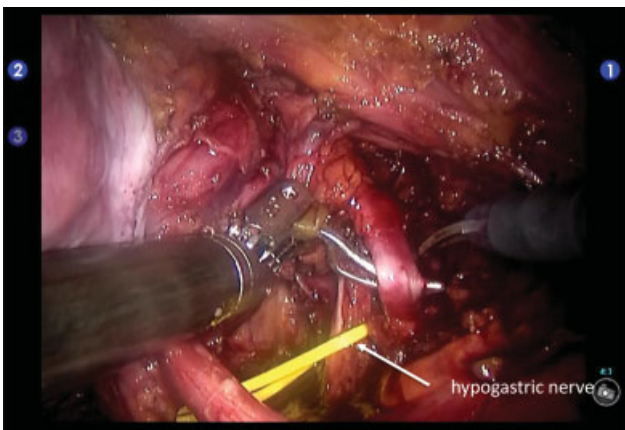


Fig. 20 Separation and cutting of the right deep uterine vein. Remove the surrounding tissue, release the deep uterine vein, and coagulate and cut with LigaSure®. Clip the uterine side of the deep uterine vein, so that you can see it immediately.

Step 18. Cutting the Uterine Branch of the Right Pelvic Nerve

At this stage, the uterine and bladder branches of pelvic nerve can be identified (►Fig. 23). In robotic surgery, the local area can be zoomed in on, which makes this part of the procedure easier than with open surgery. If the deep uterine vein stump has not been sufficiently raised, this is achieved, and the hypogastric nerve manipulated, so as to be at the same level as the pelvic nerve plexus, after which the uterine branch nerve is cut (►Fig. 24). This results in the hypogastric nerve, pelvic nerve plexus, and bladder branch forming a T-shape, which enables separation of the nerve plane from the cervix (►Fig. 14).

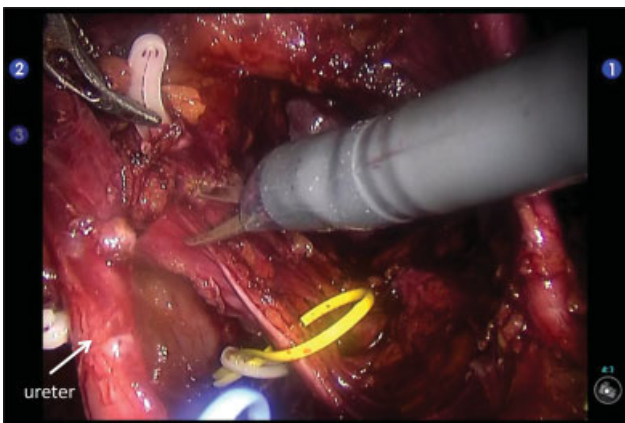


Fig. 21 Scraped up the edge of the deep uterine vein from the cardinal ligament. The deep uterine vein (white clip) is grasped and scraped up, and the hypogastric nerve bundle (yellow tape) and the pelvic nerve are processed into an L-shape.

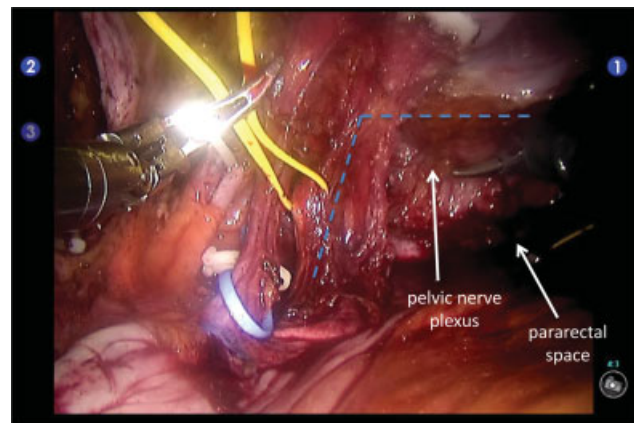


Fig. 23 View of the pelvic nerve plexus and the hypogastric nerve. After sufficient separation of the deep uterine vein, the hypogastric nerve bundle (yellow tape) and the pelvic plexus remain in an L-shape. Blue tape indicates the right ureter.

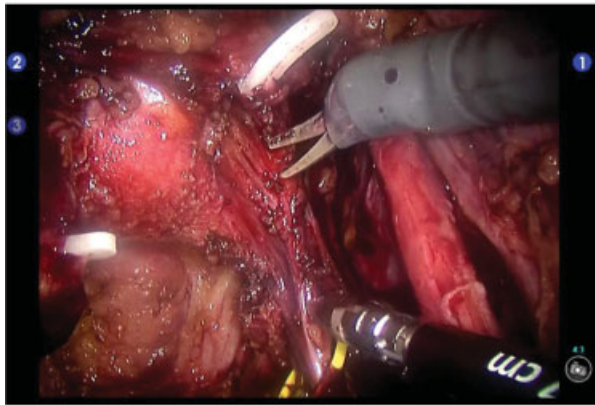
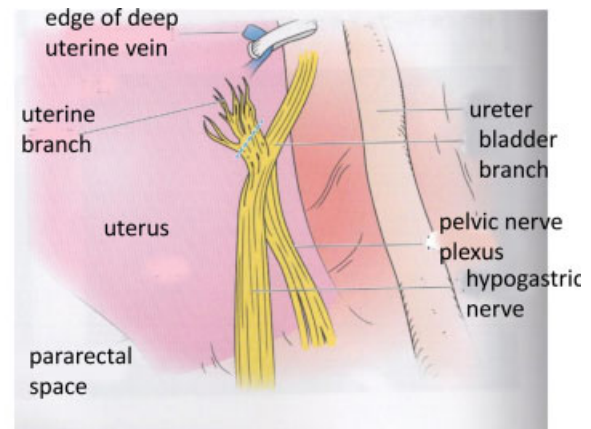


Fig. 24 Cutting the right uterine branch. Cutting off the uterine branch that branches off from the pelvic plexus (blue dotted line).



Tips and Notes

During laparotomy, the uterine branch nerve can be grasped with thin Pean forceps and cut and ligated with scissors; however, given that a power source must be used to achieve this in robotic surgery, great care must be taken to avoid heat nerve damage.

Step 19. Cutting the Right Paracolpium

A V-Care® uterine manipulator is pushed up and the bladder peeled off to the required extent with reference to the protrusion of the cup. The bladder branch nerve runs parallel to the paravaginal vein; thus, it must be separated carefully and the paracolpium is cut to the vaginal incision point with LigaSure® (► Fig. 25). When there are abundant blood vessels at the paracolpium site, it may be necessary to ligate and cut them with scissors.

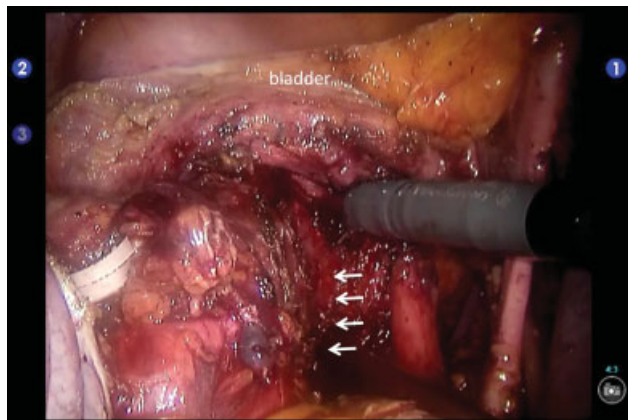


Fig. 25 Cutting the right paracolpium. Push up on V Care and remove the bladder to the required area by referring to the protrusion of the cup. Then, the paracolpium tissue (arrow portion) is cut with LigaSure®.

Step 20. Performing Procedures 14–19 on the Left Side

Step 21. Amputating and Suturing the Vaginal Wall

The second assistant pushes up the manipulator to tilt the uterus posteriorly, exposing the vaginal incision line. After confirming that the incision line has been secured around the cervix, an incision is made from the left anterior vaginal wall to the anterior and right vaginal walls (► Fig. 26). Then, the uterus is tilted anteriorly, and an incision made from the right posterior wall to left posterior and left lateral walls (► Fig. 27). The uterus is then extracted from the vagina, and rubber gloves packed with cotton balls are used to prevent air leakage.

The right stump edge of the vaginal wall is then sutured with 1–0 synthetic absorbent thread, after which continuous suturing is performed. During this continuous suturing, the third arm or assistant pulls the thread to keep it taut.

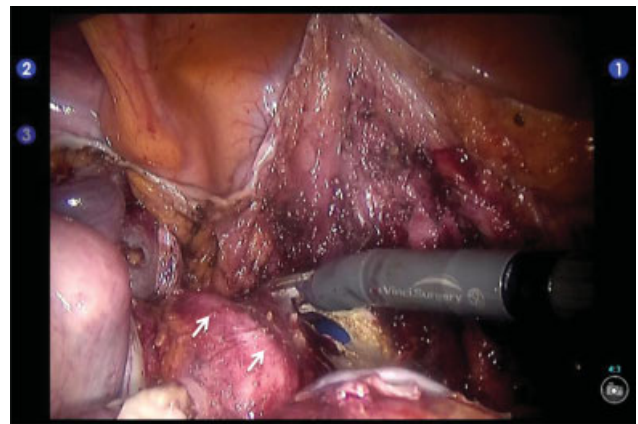


Fig. 26 Vaginal wall incision. Push up on the manipulator to flex the uterus and make the incision line visible. After confirming that the incision line is secured around the entire circumference of the cervix, an incision is made from the left front wall of the cervix to the right front wall and the right side wall of the cervix. The upper part of the vagina is indicated by the arrow.

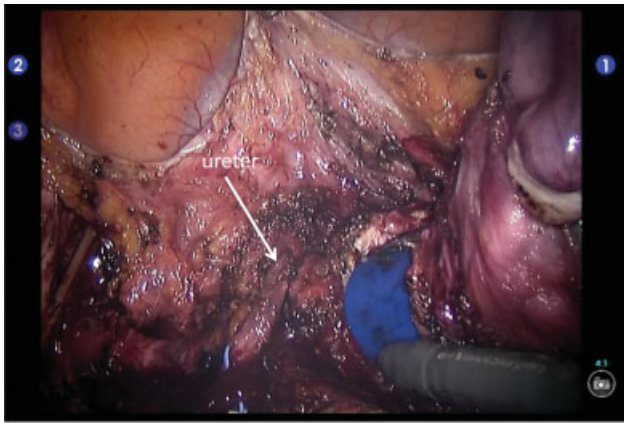


Fig. 27 Left vaginal wall incision. Make sure that the vaginal wall incision line is secured over the entire circumference, the ureters are sufficiently separated, and the vaginal wall is incised. The bladder is suspended by the third arm.

Tips and Notes

Pitfalls and tips for vaginal wall incisions

V-Care® uterine manipulators have two cups (► **Fig. 28**), and therefore the number of centimeters of the vaginal wall to be removed can be decided with reference to the cup lines. The second assistant pushes up the manipulator with appropriate strength and takes care not to cut the vagina too much. If the vagina is removed too much, then gas leaks from the vagina and the pressure in the pneumoperitoneum will then suddenly drop, making it difficult and dangerous to complete the operative procedure. For this reason, it is advisable to mark a guideline on the vaginal wall with monopolar cautery scissors before making the incision.

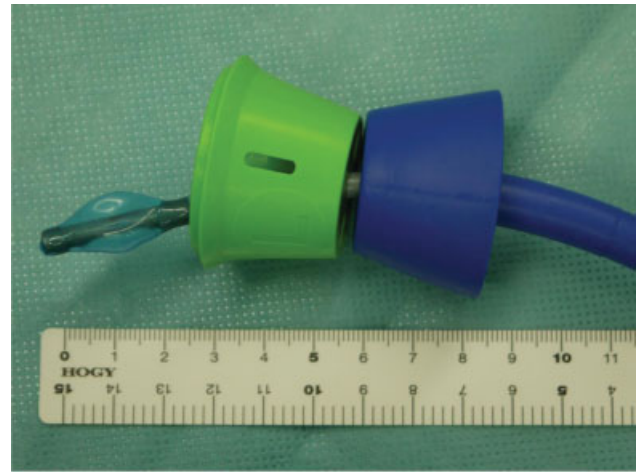


Fig. 28 Uterine manipulator. The tip of V Care® is shown. Since the length of one cup is 2 cm, determine the vaginal cut length with reference to this.

Step 22. Suturing the Bladder Peritoneum, Vaginal Stump, and Rectal Peritoneum

Next, the bladder peritoneum, vaginal stump, and Douglas fossa peritoneum are sutured with three needles. Hemostasis is checked while washing the abdominal cavity with warm saline. ► **Fig. 29** shows the condition of the pelvis at the end of this surgery. Lymph node dissection to the caudad end of the lateral cavity of the bladder enables seeing that the hypogastric nerve, pelvic splanchnic nerve, and bladder branch coming from it have been preserved, forming a T-shape. ► **Fig. 30** shows the excised specimen. The patient whose procedure is presented in this report progressed smoothly and had no dysuria.

Step 23. Removal of the Patient Cart and Reconfirming Hemostasis with a Laparoscope

The patient cart is removed and hemostasis reconfirmed by upper abdominal laparoscopy. In robotic surgery, even though the pelvis is elevated, the patient has a pneumoperitoneum,

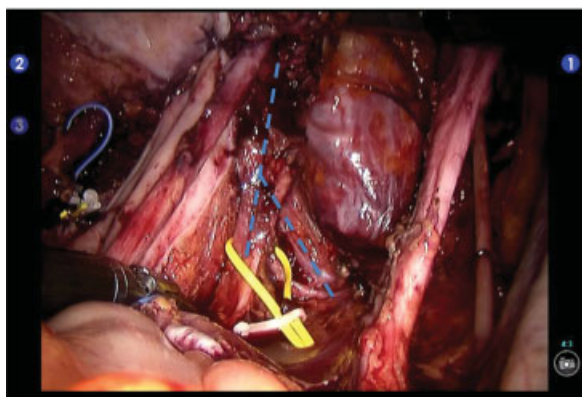


Fig. 29 Pelvis state at the end of surgery. The lymph nodes are cleanly dissected to the pelvic floor fascia surface. The hypogastric nerve (yellow tape), pelvic splanchnic nerve, and bladder branch are preserved in T-shape (blue dotted line).

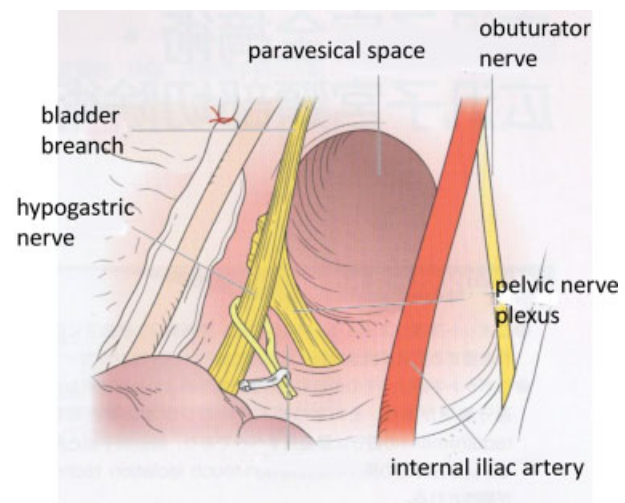

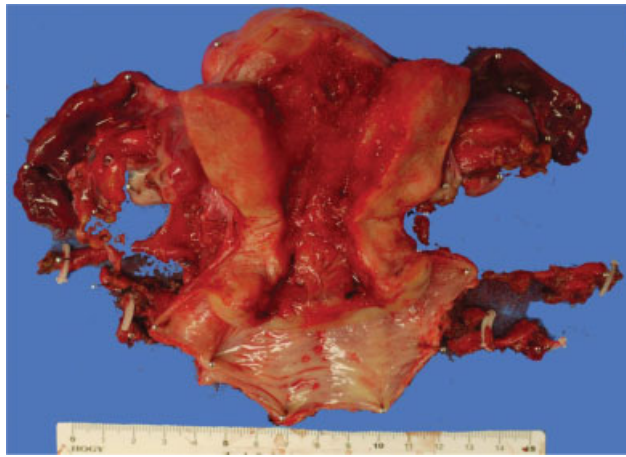


Fig. 30 Extracted specimen.

and the organs are excluded, the equipment is taken in and out through a space that the operator cannot reach, so care must be taken to ensure that no organ damage occurs.

Step 24.Placing Drains and Closing the Abdominal Wall Incision

Drains are placed in both retroperitoneal cavities from the port, an Interceed® attached to the pelvic floor, and the port sutured. Vaginal lavage is performed, thus completing the operative procedure.

Robot Surgery Requires a Team

In this article, we have focused on describing means of solving methods that may be encountered when shifting from open RH to robotic RH. Further experience is required before operating on patients with more advanced disease. It

is desirable to practice first on patients with stage IB1 disease, and then to proceed to operating on patients with more advanced disease.

Also, because robotic surgery requires a team and involves more staff than open surgery, it is important to have daily in-depth discussions to prepare for procedures and work individually on every problem that arises.

Conflict of Interest

None declared.

Acknowledgment

We thank Dr. Trish Reynolds, MBBS, FRACP, from Edanz Group (<https://en-author-services.edanzgroup.com/ac>) for editing a draft of this manuscript.

References

- 1 Hiramatsu Y, Kusumoto T, Nishida T. Robotic radical hysterectomy. In: Hiramatsu Y, Konishi I, Sakuragi N, Takeda S, eds. OGS NOW No. 21 Robot assisted Gynecologic Operations. Tokyo: Medical View; 2015: 118–135
- 2 Hiramatsu Y, Sekiba K. Radical hysterectomy. In: Practical Methods for Hysterectomy. Tokyo: Nankodo; 1997: 109–138
- 3 Sekiba K, Hiramatsu Y. Radical hysterectomy. Obstetrics and Gynecology Therapy 1991;63:9–21
- 4 Hiramatsu Y. How to expand the six cavities surrounding the uterus. In: Hiramatsu Y, Konishi I, Sakuragi N, Takeda S, eds. OGS NOW No.17, How To Expand The Cavity And How To Use The Hook, Which Is Useful To Learn. Tokyo: Medical View; 2014: 22–31
- 5 Yoshikawa H. Radical hysterectomy (Kobayashi technique). In: Hiramatsu Y, Konishi I, Sakuragi N, Takeda S, eds. OGS NOW No.5 Surgery For Cervical Cancer And Vulvar Cancer. Tokyo: Medical View; 2011: 46–55
- 6 Okabayashi H. Radical abdominal hysterectomy for cancer of the uterine cervix. Modification of the Takayama operation. Surg Obstet Gynecol 1921;33:335–341