

Alternating Hemiplegia of Childhood in a Child Harboring a Novel *TBC1D24* Mutation: Case Report and Literature Review

Ramona Cordani^{1,*} Livia Pisciotta^{1,2,*} Maria Margherita Mancardi³ Michela Stagnaro³
Giulia Prato³ Thea Giacomini^{1,3} Giovanni Morana^{4,5} Peter Walsh⁶ Twinkle Ghia⁶ Lino Nobili^{1,3}
Elisa De Grandis^{1,3}

¹ Department of Neurosciences, Rehabilitation, Ophthalmology, Genetics, Maternal and Child Health (DINO GMI), University of Genoa, Genoa, Italy

² Child Neuropsychiatry Unit, ASST Fatebenefratelli-Sacco, Milano, Italy

³ Department of Clinical and Surgical Neurosciences and Rehabilitation, Child Neuropsychiatry Unit, Giannina Gaslini Institute, Genoa, Italy

⁴ Department of Neurosciences, University of Turin, Turin, Italy

⁵ Neuroradiology Unit, Giannina Gaslini Institute, Genoa, Italy

⁶ Department of Neurology, Children's Neuroscience Service, Princess Margaret Hospital for Children, Perth, Western Australia, Australia

Address for correspondence Elisa De Grandis, MD, PhD, Department of Neuroscience, Rehabilitation, Ophthalmology, Genetics and Maternal and Child Health, University of Genoa, Child Neuropsychiatry Unit, Giannina Gaslini Institute, Largo Gaslini 5, Genova, 16147, Italy (e-mail: elisadegrandis@gaslini.org).

Neuropediatrics 2022;53:69–74.

Abstract

Alternating Hemiplegia of Childhood (AHC) is a rare neurological disease characterized by early-onset recurrent paroxysmal events and persistent neurological deficits. *TBC1D24* gene variants have been associated with a phenotypic spectrum having epilepsy as the main clinical manifestation. Herein, we report the case of a child affected by developmental delay, polymorphic seizures, and nonepileptic episodes characterized by hemiplegia or bilateral plegia, pallor, hypotonia, and dystonic postures without loss of consciousness that resolved with sleep. Noteworthy, the patient fulfills all the diagnostic criteria for AHC. An epilepsy gene panel revealed a novel *TBC1D24* mutation. This variant may be considered a PM5, according to the American College of Medical Genetics and Genomics guidelines. *TBC1D24* gene variants are associated with various clinical features, and increasing data confirms the association with permanent and paroxysmal movement disorders. Our report suggests that the *TBC1D24* molecular analysis could be considered in the diagnostic workup of AHC patients.

Keywords

- ▶ Alternating Hemiplegia of Childhood
- ▶ *TBC1D24* gene
- ▶ movement disorders
- ▶ epilepsy

Introduction

Alternating Hemiplegia of Childhood (AHC) is a rare neurological disease characterized by early-onset recurrent

paroxysmal events of alternating hemiplegia/hemiparesis, dystonic attacks, paroxysmal abnormal ocular movements, and persistent neurological deficits.¹ Epilepsy and episodes of autonomic dysfunction may also be associated. Paroxysmal episodes are often triggered by contact with water, changes in temperature, physical or psychological

* R.C. and L.P. contributed equally to this work.

received
January 8, 2021
accepted after revision
September 15, 2021
published online
December 1, 2021

© 2021. Thieme. All rights reserved.
Georg Thieme Verlag KG,
Rüdigerstraße 14,
70469 Stuttgart, Germany

DOI <https://doi.org/10.1055/s-0041-1739132>
ISSN 0174-304X.

stress, or intense emotions and anxiety. The disorder is caused by *ATPIA3* gene mutations in up to 80% of patients.¹ Research for other causative genes is currently ongoing.

Several drugs have been administered as prophylaxis for paroxysmal attacks. Although no therapy is completely effective, flunarizine, a nonselective blocker of voltage-dependent calcium channels, reduces attacks' frequency and duration.²

The *TBC1D24* gene is involved in regulating synaptic vesicle transport and cellular oxidative stress response, and its mutations are related to several phenotypes. *TBC1D24*-related clinical features include deafness, onychodystrophy, osteodystrophy, mental retardation, and seizures (DOORS) syndrome. Epilepsy ranges from benign patterns to epileptic encephalopathies. Myoclonic seizures and status epilepticus may be frequent.³

Permanent movement disorders such as dystonia and ataxia have also been described in a review of the literature with several series of *TBC1D24* patients.⁴ Moreover, recent reports have shown an association between *TBC1D24* gene mutations and paroxysmal, nonepileptic, disorders.^{5–11}

We report a child harboring a novel *TBC1D24* mutation with paroxysmal and nonparoxysmal features overlapping with AHC.

Case Report

This 5-year-old girl is the first-born child of unrelated parents of Italian origin (from two small neighboring towns), with a healthy sister. Hypotonia and abnormal rotatory eye movements have been observed very early during the child's life. Right focal clonic seizures, generalized tonic-clonic, and myoclonic seizures appeared at 5 months of age. After several therapeutic approaches (clonazepam, clobazam, levetiracetam), zonisamide (3.5 mg pro Kg every day) and oxcarbazepine (20 mg pro Kg every day) led to complete seizure control.

At 5 months of age, episodes characterized by hypotonia, bilateral plegia or hemiplegia, pallor, and sometimes dystonia without loss of consciousness appeared. These events were both bilateral and, more often, unilateral, presenting an alternation of laterality affecting the left or, more commonly, the right side. Epileptic origin was excluded by performing video-EEG. These episodes, triggered by tiredness, heat or illness, occurred more frequently in the afternoon and the evening and lasted several hours until resolving with sleep.

The patient had psychomotor delay. She sat unassisted at 10 to 11 months, walked at the age of 25 months, and she uttered her first words when she was 1-year-old, after which language development stopped. Next-generation sequencing (NGS) epilepsy gene panel was performed and showed a homozygous missense variant in the *TBC1D24* gene, NM_001199107.1 (*TBC1D24*): c.545[C > T]; p.[(Thr182Met)];[Thr182Met]. Segregation analysis in her parents revealed that they were both heterozygous for this variant, confirming biparental inheritance of the patient's homozygous missense variant. Considered the clinical picture, analysis of *ATPIA3* gene was

performed by Massively Parallel Sequencing and did not reveal clinically relevant sequence variants.

The child came to our attention at the age of 4 years. Neurological examination showed generalized hypotonia with drooling, normal deep tendon reflexes, no tremors, dysmetria, or ataxic gait. Generalized dystonia with oromandibular component and varying patterns (sometimes prevalent on the left) was evident during spontaneous movements. She understood the examiner's instructions, and she was able to count from 1 to 10.

She experienced paroxysmal attacks characterized by bilateral plegia (sometimes hemiplegia), dysarthria/anarthria, drooling, and pallor variably lasting, from 15 minutes to many hours, three to four times per week. Nocturnal sleep interrupted the episodes. However, the daytime sleep of brief duration only led to temporary interruption of the symptoms, but these reappeared after the awakened, during long-lasting episodes.

Brain magnetic resonance imaging (MRI) showed left hippocampal sclerosis and localized cerebellar gliotic changes (→ Fig. 1).

During video-EEG, an episode lasting about 2 hours and characterized by right-sided weakness followed by gradual dystonic posturing of the right upper limb associated with anarthria was recorded. Comprehension was maintained: the child responded with gestures to simple requests. During the episode, the child was initially drowsy; later, she fell asleep. The concomitant video-EEG showed slight amplitude asymmetry (right > left) (→ Fig. 2) but no epileptiform discharge. During sleep, the paroxysmal episode resolved and upon awakening, the child had no more symptoms and reactivity and interaction improve.

Flunarizine was started at a very low dosage (1.25 mg) but was discontinued after about 3 weeks due to drowsiness.

Discussion

This report describes paroxysmal episodes and chronic movement disorder in a child harboring a novel *TBC1D24* gene mutation. Epileptic origin of the episodes was excluded on the basis of clinical features and EEG recording.

Regarding the genetic findings, the c.545C > T variant has never previously been reported in the literature; nevertheless, recessive missense variants in the same domain have been described in *TBC1D24*-related disorders by Balestrini et al.³ The substitution affects a highly conserved threonine residue in the Rab GTPase activating protein TBC domain of the gene; multiple in silico prediction tools support possible pathogenicity. Moreover, an analysis of the specific exon of the *TBC1D24* gene by genomic DNA Sanger sequencing revealed that both of the patient's parents are heterozygous for the c.545C > T(p.Thr182Met) variant, thus confirming biparental inheritance of the patient's *TBC1D24* missense variant. Based on this data, this variant may be considered a PM5, according to the American College of Medical Genetics and Genomics guidelines.

Recent reports have shown an association between the *TBC1D24* gene mutation and paroxysmal movement disorders (→ Table 1). Duru et al⁵ and Guven et al⁶ reported

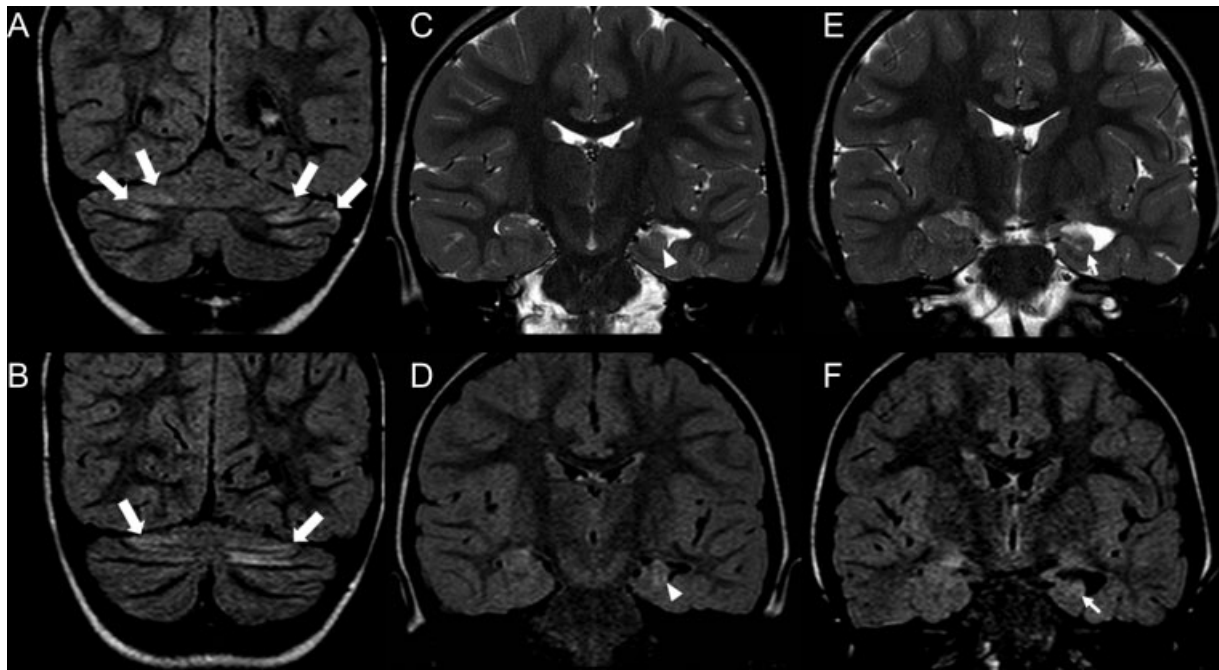


Fig. 1 Coronal fluid-attenuated inversion recovery (FLAIR) images demonstrate localized gliotic changes along the cortical regions of both cerebellar hemispheres (thick white arrows, A, B) with mild widening of the adjacent cerebellar sulci on T2- and T1-weighted images (not shown). Coronal T2-weighted (C, E) and FLAIR (D, F) images also show left-sided incomplete hippocampal inversion (arrowheads, C, D) with reduced volume and definition of the normal architecture of the hippocampal head (thin arrow, E), mild increase in FLAIR signal (thin arrow, F), and enlargement of the ipsilateral temporal horn, suggestive of concomitant mesial temporal sclerosis.

polymorphic episodic phenomena, postictal hemiparesis, dystonia, alternating and migrating jerks, and neurovegetative episodes within the same family. Luthy et al described a family with Rolandic epilepsy and dystonia triggered by sustained exercise: after a 20-year-long follow-up period, epilepsy was found to have a benign course, and exercise-induced dystonia was the most prominent and long-lasting manifestation.⁷ Zimmern et al reported a boy with a complex movement disorder, mainly triggered by fever and fatigue, characterized by facial myoclonus involving a single eyelid and generalizing to the entire face, and occasionally accompanied by alternating limb tremors. These episodes eventually evolved into left-sided ataxic episodes, tremor of the left upper limb, confusion, and diminished speech.⁸ Zhou et al reported a case of Epilepsia Partialis Continua (EPC) with a homozygous *TBC1D24* mutation. The patient developed episodes of jerks triggered by fatigue, emotions, or fever that lasted from minutes to hours.⁹ Ngho et al described two siblings with infantile-onset multifocal polymyoclonus, developmental delay, atrophy of the lateral parts of the cerebellar hemispheres, and symmetrical signaling abnormalities on MRI.¹⁰ Paroxysmal manifestations represented the main characteristic shared by all these subjects. However, the only patient presenting a constellation of symptoms consistent with AHC in association with a *TBC1D24* variant was reported by Ragona et al.¹¹ These authors described a 5-year-old girl affected by daily episodes of unresponsiveness and hypotonia, variably associated with abnormal eye movements and hemi- or tetraplegia, all of which resolved with sleep. In this case, the child also presented rhythmic clonic jerks of a body part that persisted

during sleep, consistent with EPC. Unlike our patient, this girl showed poor response to antiepileptic drugs but a partial response to flunarizine. It is worth pointing out that flunarizine's efficacy could not be adequately tested in our patient, since the drug had to be discontinued due to intense sedation. Similarly to this girl, our patient fulfills the clinical diagnostic criteria for AHC described by Neville and Ninan in 2007.¹² She presented (1) onset before 18 months of age, (2) repeated episodes of hemiplegia, (3) episodes of bilateral hemiplegia or quadriplegia, starting either as a generalization of a hemiplegic episode or bilaterally, (4) other paroxysmal disturbances including tonic/dystonic attacks, nystagmus, strabismus, dyspnea, and other autonomic phenomena occurring during hemiplegic attacks or in isolation, (5) immediate disappearance of all symptoms upon going to sleep, with recurrence 10 to 20 minutes after awakening in long-lasting attacks, and (6) evidence of developmental delay and neurological abnormalities.

Interestingly, our patient also presented spells of lethargy and drowsiness lasting minutes to hours, which were variably associated with hemiplegia along with staring and reduced responsiveness. These episodes, described by her parents and recorded during video-EEG (► **Videos 1 and 2**), are very similar to Reduced Awareness Spells, which have recently been reported as non-epileptic paroxysmal episodes in about one-third of AHC cases.¹³ It is important to remark that the disappearance of paroxysmal symptoms after sleep is typical of AHC; however, since the first reports of this disorder, it has been reported that the long-lasting episodes would reappear after a few minutes from sleep, as occurs in our patient, in particular after brief episodes of daytime sleep.¹⁴

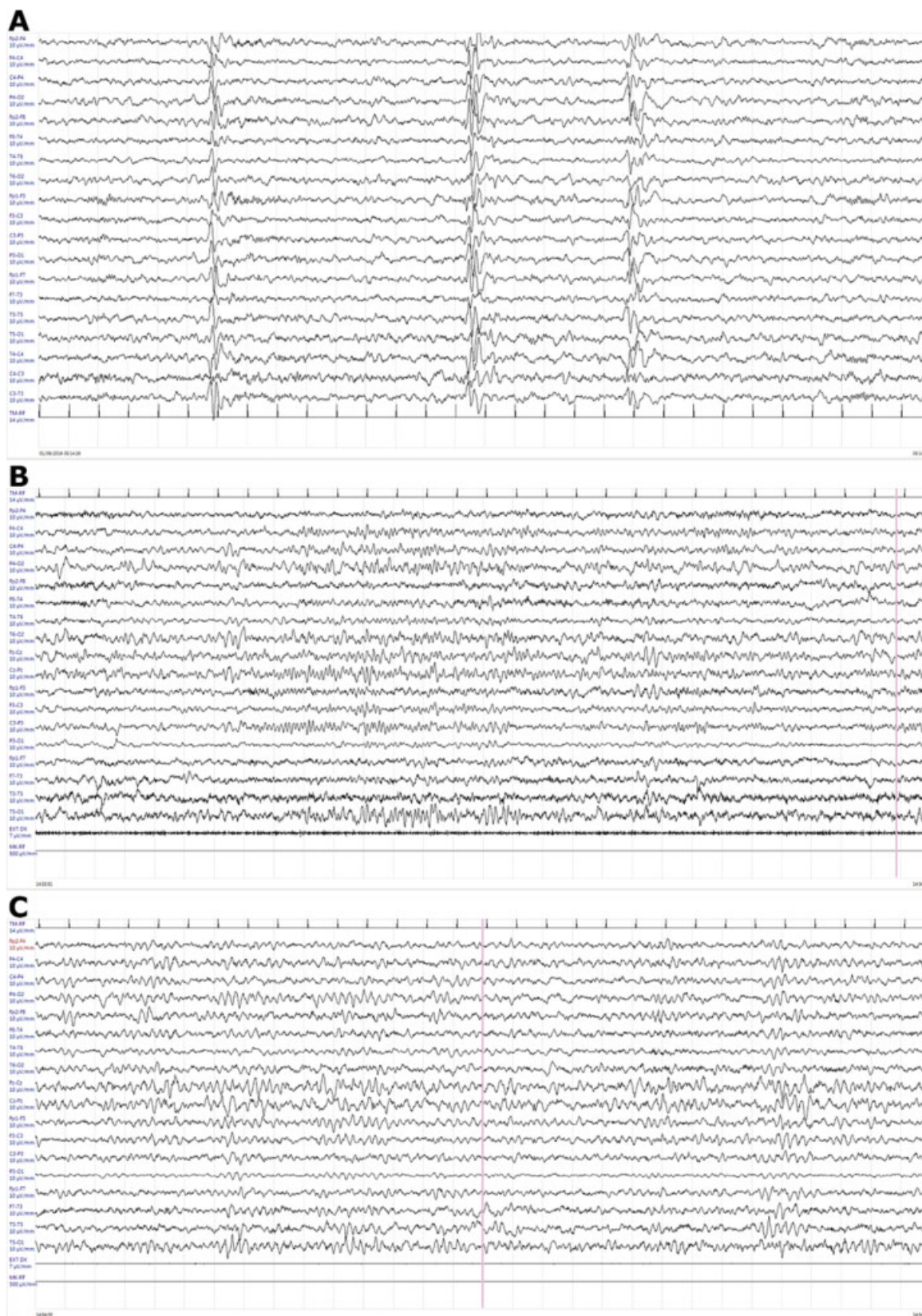


Fig. 2 (A) 24h Holter EEG recording. SI 10–20, longitudinal montage, 10 uV/m, HF 70 Hz, LF 0.1 second. Non-rapid eye movement (REM) sleep: there are generalized sharp waves. (B-C) Video-EEG during an episode characterized by weakness of the right side of the body, followed by dystonic posturing of the right upper limb associated to anarthria. During the episode comprehension was maintained and the child responded with gestures to simple requests. During the episode, the child was initially drowsy, later she fell asleep. EEG showed slight hemispheric voltage asymmetry (right > left) but no epileptic discharges.

Table 1 Characteristics of *TBC1D24* patients with movement disorders

Mutation (reference)	Country of origin	Consanguinity	Family members	Permanent movement Disorder	Paroxysmal Movement Disorder	Age at onset (movement disorder)	EEG correlation	Treatment	Response to treatment	Sleep response	Brain imaging
NA ^{5,6}	Turkey	+	5 (4 M, 1 F)	+	Dystonic attacks, postictal hemiparesis, startles	< 18 months	-	Antiepileptic drugs, tetraosactrin, vitamin B6, coenzyme Q, IVIG	-	NA	Diffuse delay in myelination and thin corpus callosum
c.457G > A + c.545del ¹⁰	Poland	-	2 (1 M, 1 F)	-	Myoclonic twitching and jerking movements involving different muscle groups	< 18 months	-	Anti-epileptic drugs, coenzyme Q10, biotin, riboflavin, thiamine, levodopa, piracetam, ketogenic diet, bromocriptin	-	+	Hypoplasia of frontal and temporal lobes in the first and cerebellar atrophy in the 2nd patient
c.116C > T ¹ c.457G > A ¹	Italy	-	1 F	+	Abnormal eye movements, hemi or tetraplegia, jerks	< 18 months	-	Flunarizine	+	+	Normal
c.229_240del ⁹	China	+	1 F and 1 relative	-	Hemilateral jerks	5 years	-	Anti-epileptic drugs	-	+	Normal
c.304C > T ⁺ c.410T > C ⁸	Switzerland	+	1 M and 3 relatives	-	Facial myoclonus, alternating hemidystonic attacks sometimes associated to tremor, anarthria and confusion	22 months (first evaluation)	-	Anti-epileptic drugs	+	NA	Cerebellar T2 hyperintensity
p.181_K84del + c.1499C4T (brother and sister) c.545C4T + c.1531G4A (cousin) ⁷	Italy	+	2 (1 M, 1 F) and 1 cousin	-	Dystonic episodes and tremor, brief jerking episodes	< 18 months	-	Anti-epileptic drugs, flunarizine, acetazolamide Oxcarbazepine carbidopaj/levodopa	-	+	Normal

F, female; M, male; +, present; -, not present; EEG correlation, epileptic discharge during paroxysmal attacks; response to treatment, improvement of paroxysmal movement disorders after therapies indicated in "treatment" column; IVIG, intravenous immunoglobulin; NA, data not available.

Video 1

This episode was recorded during a video-EEG. The child presents a right hemiparetic episode: her inability to grasp an object with her right arm is evident. The child is able to understand the examiner's requests; however, communication abilities and contact are reduced. Ictal EEG presents intermittent hemispheric asymmetry in voltage (right > left) without any epileptiform discharges. Online content including video sequences viewable at: <https://www.thieme-connect.com/products/ejournals/html/10.1055/s-0041-1739132>.

Video 2

The episode is followed by sleep and when the child wakes up, hemiplegia resolves, and reactivity and interaction improve. Online content including video sequences viewable at: <https://www.thieme-connect.com/products/ejournals/html/10.1055/s-0041-1739132>.

Regarding neuroradiological features, two other patients with *TBC1D24* mutations reportedly had cerebellar sequelae characterized by gliosis and/or atrophy and showed gliotic changes similar to the ones we observed in our patient (► **Table 1**). MRI also revealed the presence of mesial temporal sclerosis; interestingly, concomitant mesial temporal sclerosis (► **Fig. 1**) has been described in other AHC patients^{15,16} and may be linked to severe epilepsy.

AHC is caused by mutations in *ATP1A3* gene in approximately 80% of patients. Although a second major causative gene has not yet been identified, other gene mutations (*ATP1A2*, *CACNA1A*, *ADCY5*, *TANGO2*, *SLC1A3*) have occasionally been related to AHC.¹⁷ In our patient, the majority of “non-conventional” AHC genes were tested by the NGS epilepsy gene panel (*ATP1A2*, *CACNA1A*, *SLC2A1*, *SCN1A*), while *ATP1A3* and *ADCY5* genes were tested afterward. Therefore, based on the possible pathogenicity of the *TBC1D24* variant, and as per similar *TBC1D24* phenotypes already described in the literature, we assume that the genetic variant suffices to explain the clinical features of our patient.

Conclusions

Our report further expands the broad phenotypic spectrum of *TBC1D24*-related disorders and suggests considering an analysis of this gene in the diagnostic workup of patients fulfilling AHC clinical criteria, especially for *ATP1A3*-negative subjects. Further researchers on this topic could clarify the role of *TBC1D24* gene mutation in AHC.

Conflicts of Interests

The authors declare that they have no conflicts of interests.

Acknowledgments

We thank the Italian Association for Alternating Hemiplegia of Childhood (AISEA) for its organizational support. We acknowledge the aid of Dr. Dimitar Azmanov for providing access to their patients' files. We thank Ms. Valerie Frances Perricone for English editing.

References

- Panagiotakaki E, De Grandis E, Stagnaro M, et al; Italian IBAHC Consortium French AHC Consortium International AHC Consortium. Clinical profile of patients with *ATP1A3* mutations in Alternating Hemiplegia of Childhood—a study of 155 patients. *Orphanet J Rare Dis* 2015;10:123–135
- Pisciotta L, Gherzi M, Stagnaro M, et al; I.B.AHC Consortium. Alternating hemiplegia of childhood: pharmacological treatment of 30 Italian patients. *Brain Dev* 2017;39(06):521–528
- Balestrini S, Milh M, Castiglioni C, et al. *TBC1D24* genotype-phenotype correlation: Epilepsies and other neurologic features. *Neurology* 2016;87(01):77–85
- Carecchio M, Mencacci NE. Emerging monogenic complex hyperkinetic disorders. *Curr Neurol Neurosci Rep* 2017;17(12):97
- Duru N, Iseri SA, Selçuk N, Tolun A. Early-onset progressive myoclonic epilepsy with dystonia mapping to 16pter-p13.3. *J Neurogenet* 2010;24(04):207–215
- Güven A, Tolun A. *TBC1D24* truncating mutation resulting in severe neurodegeneration. *J Med Genet* 2013;50(03):199–202
- Lüthy K, Mei D, Fischer B, et al. *TBC1D24*-TLDC-related epilepsy exercise-induced dystonia: rescue by antioxidants in a disease model. *Brain* 2019;142(08):2319–2335
- Zimmern V, Riant F, Roze E, et al. Infantile-onset paroxysmal movement disorder and episodic ataxia associated with a *TBC1D24* mutation. *Neuropediatrics* 2019;50(05):308–312
- Zhou Q, Lin Y, Ye J, et al. Homozygous *TBC1D24* mutation in a case of epilepsy partialis continua. *Front Neurol* 2018;8:750
- Ngo A, Bras J, Guerreiro R, et al. *TBC1D24* mutations in a sibship with multifocal polymyoclonus. *Tremor Other Hyperkinet Mov (N Y)* 2017;7:452
- Ragona F, Castellotti B, Salis B, et al. Alternating hemiplegia and epilepsy partialis continua: a new phenotype for a novel compound *TBC1D24* mutation. *Seizure* 2017;47:71–73
- Neville BG, Ninan M. The treatment and management of alternating hemiplegia of childhood. *Dev Med Child Neurol* 2007;49(10):777–780
- Uchitel J, Helseth A, Prange L, et al. The epileptology of alternating hemiplegia of childhood. *Neurology* 2019;93(13):e1248–e1259
- Bourgeois M, Aicardi J, Goutières F. Alternating hemiplegia of childhood. *J Pediatr* 1993;122(5 Pt 1):673–679
- Sasaki M, Ishii A, Saito Y, Hirose S. Progressive brain atrophy in alternating hemiplegia of childhood. *Mov Disord Clin Pract (Hoboken)* 2017;4(03):406–411
- Panagiotakaki E, Gobbi G, Neville B, et al; ENRAH Consortium. Evidence of a non-progressive course of alternating hemiplegia of childhood: study of a large cohort of children and adults. *Brain* 2010;133(Pt 12):3598–3610
- Sen K, Hicks MA, Huq AHM, Agarwal R. Homozygous *TANGO2* single nucleotide variants presenting with additional manifestations resembling alternating hemiplegia of childhood—expanding the phenotype of a recently reported condition. *Neuropediatrics* 2019;50(02):122–125