



# Most Frequent Compressive Limb Neuropathies: A Literature Review

## *Neuropatias compressivas mais frequentes que acometem os membros: Revisão da literatura*

Donizete Tavares da Silva<sup>1</sup> Pedro Jorge Luz Alves Cronemberger<sup>1</sup>   
 Matheus Henrique de Sousa Moura<sup>1</sup> Barhbara Brenda Dias Garcez<sup>2</sup> Márcio da Silva Pereira<sup>3</sup>  
 José Nazareno Pearce de Oliveira Brito<sup>4</sup>

<sup>1</sup>Medicine, Department of Health Sciences Center, Universidade Federal do Piauí, Teresina, PI, Brazil

<sup>2</sup>Medicine, Universidade Estadual do Piauí, Teresina, PI, Brazil

<sup>3</sup>Department of Neurosurgery, Hospital São Marcos, Teresina, PI, Brazil

<sup>4</sup>Department of Neurosurgery, Hospital São Marcos, Teresina, PI, Brazil

Address for correspondence Dr. Donizete Tavares da Silva, Medical Student, Universidade Federal do Piauí, Av. Universitária s/n, Ininga, Teresina, PI, CEP: 64.049-550, Brazil (e-mail: tavaresdonizete700@gmail.com).

Arq Bras Neurocir 2023;42(1):e40–e51.

### Abstract

#### Keywords

- ▶ entrapment neuropathy
- ▶ median nerve neuropathy
- ▶ ulnar neuropathy
- ▶ radial neuropathy
- ▶ meralgia paresthetica
- ▶ peroneal neuropathy

### Resumo

#### Palavras-chave

- ▶ neuropatia por aprisionamento
- ▶ neuropatia do nervo mediano
- ▶ neuropatia radial
- ▶ neuropatia ulnar
- ▶ meralgia parestésica
- ▶ neuropatia fibular

Peripheral nerve injuries vary in length and severity, and they can occur secondary to trauma, compression and ischemia, leading to both motor and sensory neurological deficits. Nerve compression can occur in both the upper and lower limbs. These injuries can affect the quality of life, including the total or partial loss of the individual's productive capacity. The diagnostic methods are based on clinical criteria, but they may also include imaging and electroneurophysiological studies. A clinical examination using the Tinel and Phalen tests, for example, may suggest carpal tunnel syndrome. Complementary exams are used to confirm the diagnosis and rule out other possibilities, and the most used are electroneuromyography (ENMG), computed tomography (CT), magnetic resonance imaging (MRI), and ultrasonography (US). Depending on the type of injury, recovery may be spontaneous or may require conservative or surgical treatment.

As lesões nervosas periféricas variam em extensão e gravidade, as quais podem ocorrer secundárias a trauma, compressão e isquemia, e acarretam déficits neurológicos tanto motores quanto sensoriais. A compressão nervosa pode ocorrer nos membros superiores e inferiores. Estas lesões podem afetar a qualidade de vida, incluindo a perda total ou parcial da capacidade produtiva do indivíduo. Os métodos diagnósticos são baseados em critérios clínicos, mas também podem incluir métodos de imagem e estudos eletro-neurofisiológicos. O exame clínico por meio dos testes de Tinel e de Phalen, por exemplo, pode sugerir síndrome do túnel do carpo. Os exames complementares servem para confirmar o diagnóstico e descartar outras possibilidades, sendo os mais utilizados a eletroneuromiografia (ENMG), a tomografia computadorizada (TC), a ressonância magnética (RM) e a ultrassonografia (US). De acordo com o tipo da lesão, a recuperação pode ser espontânea ou necessitar de tratamento conservador ou cirúrgico.

received  
October 22, 2020  
accepted  
June 16, 2021

DOI <https://doi.org/10.1055/s-0041-1739278>.  
ISSN 0103-5355.

© 2022. Sociedade Brasileira de Neurocirurgia. All rights reserved. This is an open access article published by Thieme under the terms of the Creative Commons Attribution-NonDerivative-NonCommercial-License, permitting copying and reproduction so long as the original work is given appropriate credit. Contents may not be used for commercial purposes, or adapted, remixed, transformed or built upon. (<https://creativecommons.org/licenses/by-nc-nd/4.0/>)  
Thieme Revinter Publicações Ltda., Rua do Matoso 170, Rio de Janeiro, RJ, CEP 20270-135, Brazil

## Introduction

Peripheral nerve injuries vary in length and severity, and they can occur secondary to trauma, compression and ischemia, leading to both motor and sensory neurological deficits. These injuries can greatly affect the quality of life, including total or partial loss of individual's productive capacity, which has important economic and social impacts for the population. Depending on the type of injury, recovery can be spontaneous, or conservative therapy or surgical intervention may be required.<sup>1</sup>

Peripheral nerve syndromes can be related to a variety of symptoms, such as: motor weakness, sensory disorders, imbalance, and pain. Nerve compression can occur in both upper and lower limbs.<sup>1</sup>

Among compression neuropathies in the upper limb, carpal tunnel syndrome, characterized by compression of the median nerve, has a higher prevalence in the population.<sup>2</sup>

Other examples are the compressive syndromes of the radial nerve, which present themselves in different ways: they can be purely sensory, motor, or mixed. This group encompasses several syndromes, such as radial tunnel syndrome, Wartenberg syndrome, and posterior interosseous nerve syndrome. As these syndromes affect different compression sites, they may present with different clinical features and have diagnostic intersection with other pathological conditions, such as lateral elbow epicondylitis. The most common compression syndromes are distal to the elbow.<sup>3</sup>

The methods to diagnose these lesions are based on clinical criteria, but they can also include imaging methods and electroneurophysiological studies.<sup>2</sup>

The diagnostic methods used for compressive neuropathies range from clinical examination and anamnesis through semiological tests, such as the Tinel test (percussion over the region of the median nerve, which results in dysesthesia) and the Phalen test (the symptoms are triggered by complete palmar flexion of the wrists for 30 to 60 seconds, causing a characteristic pain) performed in carpal tunnel syndrome. In addition, with the advancement in radiological methods, complementary exams are used to confirm the diagnosis and rule out other possibilities, using electroneurography (ENMG), computed tomography (CT), magnetic resonance imaging (MRI) and ultrasonography (US).<sup>4</sup>

The present study aims to analyze the factors related to the main compressive neuropathies through a review of articles in databases.

## Material And Methods

The present study was performed through bibliographic research conducted between February and March 2020. The literature review was performed in the PubMed, UpToDate, SciELO and MEDLINE databases. We used the following keywords: *entrapment neuropathy*, *ulnar neuropathy*, *radial neuropathy*, *median neuropathy*, *meralgia paresthetica*, and *peroneal neuropathy*.

The filters were: year of publication, type of article, and text availability. The inclusion criteria were as follows: papers published since 2015, case reports, simple literature reviews, randomized controlled trials, clinical trials, systematic reviews with or without meta-analysis, texts available in full, and adequacy to the topic of the present study. And the exclusion criteria were: articles without the full text available online, animal studies, works published before 2015, and those not available written in Portuguese, English, or Spanish.

A total of 30 articles were selected, which addressed the most prevalent compressive neuropathies of the limbs with involvement of the median, ulnar, radial, fibular and femoral nerves. We excluded the articles that did not meet the inclusion criteria.

## Results

In total, 388 potentially-eligible articles were found on the PubMed, UpToDate, SciELO and MEDLINE databases, 30 of which were selected because they addressed the topic of the present review in a comprehensive manner, with pathophysiological description, clinical presentation, diagnostic elements, treatment of the peripheral neuropathies herein discussed, and availability of the full text in English, Spanish and Portuguese. There were 25 articles written in English, and 5, in Portuguese.

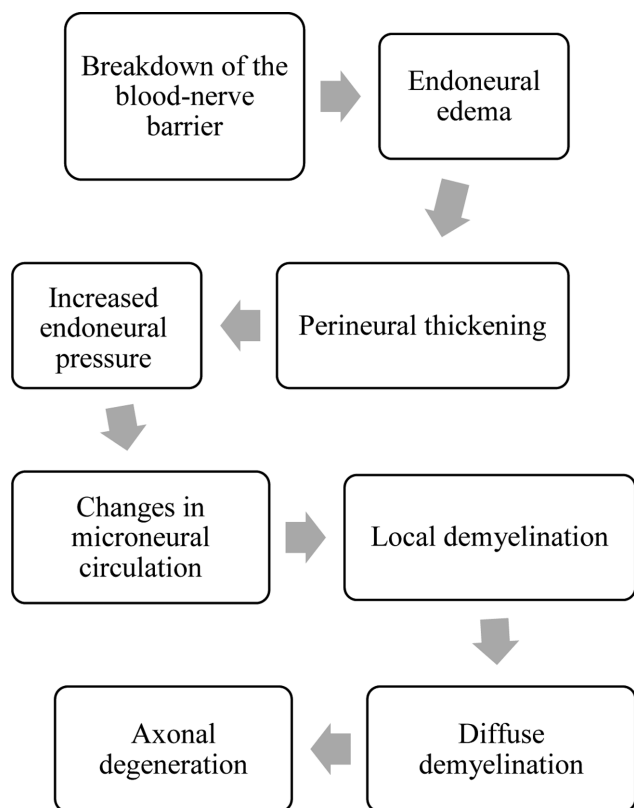
## Discussion

### Pathophysiology

The compression of a nerve results in microvascular lesions, destruction of the myelin, and, eventually, axonal degeneration.<sup>5</sup> This sequence of neural changes will occur depending on the intensity and duration of the compression. Slight compressions can obstruct the venous flow, causing edema, while severe compressions result in ischemia. Persistent compressions result in chronic inflammation and fibrosis, which contributes to mechanical compression.

The histopathological changes caused by chronic nerve compression (→ Fig. 1) begin with the rupture of the blood-nerve barrier, followed by endoneurial edema and perineurial thickening. The increase in endoneurial pressure will result in changes in microneurial circulation and make the nerve susceptible to dynamic ischemia. With increased compression, there will be localized and eventually diffuse demyelination, which decreases the axonal conduction velocity and may cause partial or total blocks of the action potential. The combination of these factors in the long term causes Wallerian axonal degeneration.<sup>6</sup>

Neural changes may not occur uniformly across the nerve and may vary depending on the distribution of compressive forces across the nerve. Superficial fascicles will be affected sooner and it can result in symptoms within a single nerve distribution. For example, in the initial stages of carpal tunnel syndrome, the superficial fascicles of the long finger and ring finger are usually affected before the fascicles of the thumb and the radial side of the index finger.<sup>5</sup>



**Fig. 1** Histopathological changes in compressive neuropathies.

Electrophysiological studies play an important role in the diagnosis of compressive neuropathies.<sup>6</sup> The initial stage of nerve compression is associated with dynamic ischemic events. Thus, the results of electrodiagnostic studies are generally normal. As the compression progresses, demyelination occurs, and the conduction speed decreases at the site of the compression. Axonal loss does not usually occur until advanced stages of the neuropathy.<sup>7</sup>

Although electrophysiological studies remain the gold standard to confirm compressive neuropathies, neuromuscular ultrasound has gained importance as a tool to assist in their diagnosis. The nerves are usually enlarged at or near the compression site. High-resolution ultrasound confirms the diagnosis by demonstrating edema of the nerve proximal to the compression area, and establishes the presence of dynamic compression, nerve subluxation, or extrinsic compression.<sup>7</sup>

The clinical features differ according to the degree of nerve compression, and the sensory and motor functions may be affected to different degrees, as shown in **Table 1**.

**Table 1** Clinical degrees of compressive neuropathy

	Mild	Moderate	Severe
Sensitive	Intermittent paresthesia	Persistent paresthesia, numbness, subjective sensory deficit	Objective sensory deficit
Motor	Without changes	Incoordination and subjective weakness	Weakness, paralysis, atrophy

Source: Lee and Lim (2019).<sup>6</sup>

## Compressive Neuropathies of the Upper Limbs

### Median Nerve

#### Anatomy and Entrapment Sites

The most common and well-known compressive neuropathy is carpal tunnel syndrome (CTS), which results from the compression of the median nerve within the wrist. However, other less common areas of entrapment should be discussed and acknowledged in the differential diagnosis of compressions of the median nerve. Differential diagnosis with radiculopathies and upper-limb plexopathies should be considered.<sup>8</sup>

The median nerve is formed from the medial and lateral divisions of the brachial plexus, receiving contributions from nerve roots from C5 to T1. It follows the path of the brachial artery in the arm medially, without emitting branches. In the proximal forearm, it innervates the pronator teres, the radial flexor of the carpus, and the superficial flexor of the fingers. In this region, a structure that is present in some individuals and that constitutes a rare cause of compression of the median nerve is the Struthers ligament, which lies between the supracondylar process and the medial epicondyle of the humerus.<sup>9</sup>

In the antecubital region, the nerve travels below the bicipital aponeurosis to the elbow and goes between the heads of the pronator teres muscle, which in itself can be a rarer site of compression. Approximately 4cm before the medial epicondyle, the main trunk of the median nerve gives rise to the anterior interosseous nerve, which innervates the long flexor of the thumb, the deep flexor of the second and third digits, and the square pronator, and is involved in anterior interosseous syndrome.<sup>10</sup>

The median nerve enters the hand when it passes through the carpal tunnel, a restricted anatomical space located in the middle third of the wrist that is formed by the trapezium, trapezoid, capitate, and hamate bones and the transverse carpal ligament (flexor retinaculum). In the distal part of the carpal tunnel, the median nerve divides into motor and sensory branches, and it innervates the pronator muscles of the forearm, as well as most of the flexors of the fingers and wrist in the forearm.<sup>9</sup>

#### Carpal Tunnel Syndrome

The most common compressive neuropathy of the upper extremity is CTS, with a prevalence of 3% to 5% in the general population, and of 6% among women aged >40 years. It occurs about five times more in women, with two peaks

observed in the sixth and 8th decades of life. The risk factors for CTS include obesity, the female gender, coexisting conditions (such as, diabetes, pregnancy, rheumatoid arthritis, hypothyroidism, connective tissue diseases), genetic predisposition, and repetitive use of the wrist.<sup>11</sup>

Carpal tunnel syndrome occurs due to a decrease in the size of the carpal tunnel, leading to compression of the median nerve when the tissues surrounding the flexor tendons in the wrist (synovial sheaths) become inflamed, causing edema.<sup>12</sup> The dimensions of the canal may be compromised by arthritis, tendinopathy, local edema, and the accumulation of substances such as amyloid. Repetitive movements and vibrating tools increase the likelihood of developing carpal tunnel syndrome.<sup>13</sup>

However, other less common areas of entrapment should be mentioned and considered in the differential diagnosis of compressions of the median nerve. Differential diagnosis with radiculopathies and plexopathies of the upper limb should be considered. For this, in addition to the differences in the sensory and motor involvement of each neuropathy, complementary exams can be performed, especially electro-neuromyography, which is the gold standard for any compressive mononeuropathy.<sup>8</sup>

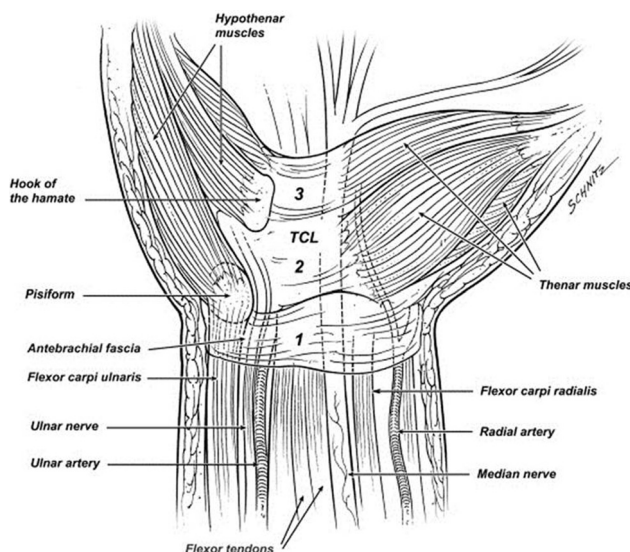
Patients affected with this mononeuropathy have numbness, tingling, or other paresthesias that affect the first to the third fingers and the lateral region of the fourth finger, exacerbated by wrist flexion. Muscle weakness occurs in the most advanced cases, manifested by weakness in opposition and thumb abduction accompanied by atrophy of the thenar region.<sup>14</sup>

The electrodiagnostic evaluation proved to be useful to identify lesions of the median nerve in the wrist and to differentiate those from lesions of the proximal median nerve, brachial plexus, and roots of the cervical nerve. Although the results of electrodiagnostic tests are considered the gold standard for the diagnosis of CTS by some authors,<sup>13</sup> the test is not 100% sensitive.

The treatment of CTS consists of conservative therapy with a wrist splint, especially at night or during activities that exacerbate the symptoms. In case of failure, injecting steroids into the wrist is usually helpful in relieving symptoms (at least temporarily, in most cases). Surgical release of the flexor retinaculum is indicated, with excellent results, for patients with persistent symptoms who do not respond to conservative therapy.<sup>15</sup> The flexor retinaculum in the carpal tunnel consists of three segments (► Fig. 2).<sup>31</sup>

### Proximal Median Nerve Neuropathies

Injuries to the median nerve at or above the elbow are uncommon. The causes include fracture of the humerus, and compression in a supracondylar region, in the Struthers ligament, or within the pronator teres muscle, as well as iatrogenic causes, such as brachial artery catheterization or creation of an arteriovenous fistula for hemodialysis. The pattern of electrodiagnostic abnormalities expected in lesions near or close to the elbow are reduced amplitudes of sensory and motor nerve conduction responses, normal



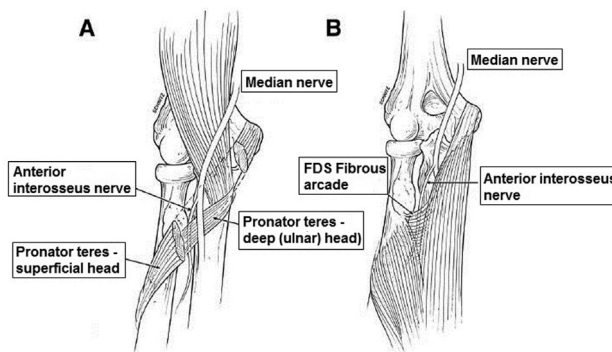
**Fig. 2** The flexor retinaculum in the carpal tunnel consists of three segments: The proximal segment (1) is inseparable from the antebrachial fascia, whereas the transverse carpal ligament (TCL) makes up the second portion (2). The distal segment (3) consists of the aponeurosis between the thenar and hypothenar muscles. Source: Koo J, Szabo R (2004).<sup>31</sup>

distal latencies, and possibly a slight deceleration of the forearm conduction speed.<sup>13</sup>

### Anterior Interosseous Nerve (AIN) Syndrome

Lesions on this branch of the median nerve are uncommon. The most common clinical presentation is unilateral weakness of the flexor digitorum profundus muscles (digits I and II), with preservation of the thumb abduction and opposition. Flexion of the wrist tends to be spared, but there may be demonstrable weakness of the pronator quadratus muscle.<sup>16</sup> The common sites of compression in AIN syndrome are shown in ►Fig. 3.<sup>31</sup>

The expected electrodiagnostic pattern includes median nerve normal motor and sensory conduction studies. In electromyography, it is expected to be abnormal in the flexor pollicis longus, pronator quadratus, and median part of the flexor digitorum profundus muscles. The thenar muscles remain normal, as well as the pronator teres and the flexor



**Fig. 3** Common sites of compression in anterior interosseous nerve (AIN) syndrome. (A) Deep head of the pronator. (B) Fibrous arcade at the proximal margin of the flexor digitorum superficialis (FDS) to the middle finger. Source: Koo and Szabo (2004).<sup>31</sup>



carpi radialis. The expected pattern of results includes reduced amplitude of motor response and slight elongation of latency from the elbow to the muscle.<sup>16</sup>

## Ulnar Nerve

### Anatomy and Entrapment Sites

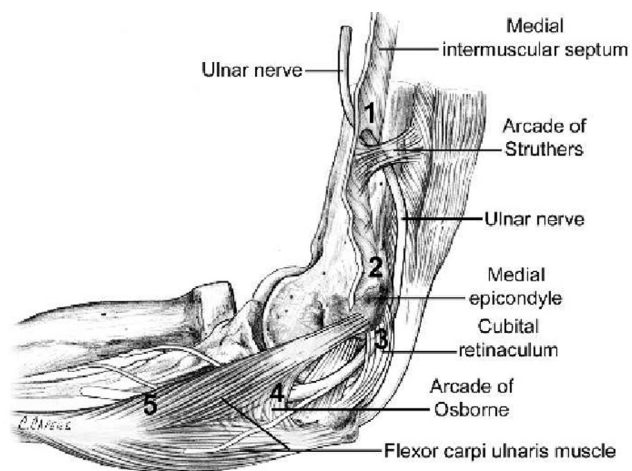
Due to anatomical features, the ulnar nerve is more vulnerable to compression in the elbow and wrist. The cubital tunnel in the elbow is the most common site of entrapment of the ulnar nerve, and, less commonly, the Guyon canal in the wrist.<sup>17</sup> The common sites of compression of the ulnar nerve are shown in ►Fig. 4.<sup>32</sup>

The ulnar nerve is formed from the lower trunk and medial fascicle of the brachial plexus, receiving contributions from the nerve roots of C8 and T1. It continues medially in the arm, crosses the medial intermuscular septum, and passes through the brachial fascia and fibers of the medial head of the biceps that form the arcade of Struthers.

At the level of the elbow, the ulnar nerve crosses superficially between the medial epicondyle and olecranon, a region called the groove for the ulnar nerve. The ulnar nerve enters the cubital tunnel distally at the elbow. The tunnel is formed by the Osborne ligament (a ligament between the two heads of the flexor carpi ulnaris muscle), the joint capsule and the collateral ligament of the elbow, the medial epicondyle, the olecranon, the medial collateral ligament, and the fascia between the two heads of the ulnar flexor carpi muscle.<sup>17</sup>

In the region of the elbow, the main sites that may compress the ulnar nerve are the arcade of Struthers, the medial intermuscular septum, the medial epicondyle, the cubital tunnel through the Osborne ligament, and the fascia of the flexor-pronator muscle group of the forearm.<sup>13</sup>

In the forearm, the ulnar nerve is located medially and above to the flexor digitorum profundus, and deep into the flexor carpi ulnaris, providing branches to innervate these muscles along its course. The ulnar nerve is lateral to the flexor carpi ulnaris muscle and medial to the ulnar artery.



**Fig. 4** Common sites of compression of the ulnar nerve: medial intermuscular septum, arcade of Struthers, medial epicondyle, cubital tunnel, arcade of Osborne and flexor-pronator muscle group. Source: Terry and Zeigler (2002).<sup>32</sup>

At the level of the wrist, the ulnar nerve and artery enter the Guyon canal, which is fibro-osseous canal formed by the transverse ligament of carpus, hypothenar muscles, carpal volar ligament, pisiform, pisohamate ligaments and the hook of the hamate.<sup>17,18</sup>

The ulnar nerve originates two branches, one dorsal (sensitive) and one palmar (mixed) branch. The palmar branch enters the Guyon canal with the ulnar artery and originates a sensory branch (which goes to the little finger and the ulnar side of the ringer finger) and a motor branch (which innervates the intrinsic muscles of the hand).

### Ulnar Neuropathy in the Elbow

The elbow is the second extremity of the upper limb most affected by compressive neuropathies, with several places of entrapment. One of these sites, the cubital tunnel, is formed by the ulna, the collateral ligament, and the aponeurosis of the flexor carpi ulnaris muscle joint. The ulnar nerve is also susceptible to compression immediately proximal to the medial epicondyle. The impact mechanism is still undefined. There is some evidence to suggest that elbow subluxation may decrease the chance of developing ulnar neuropathy.<sup>13</sup>

Patients affected with this mononeuropathy present numbness, tingling, and other paresthesias that affect the territory of the ulnar nerve (fourth and fifth fingers), and that usually worsen at night. In severe cases, weakness and atrophy of the intrinsic musculature of the hand may be evident. The Duchenne sign (ulnar claw) due to weakness of the third and fourth lumbrical muscles, and the Wartenberg sign (patient with the fifth finger abducted when at rest) due to weakness of the third palmar interosseous muscle, may be present. The Froment sign is evidenced by the flexion of the thumb to compensate for the weakness of the adduction during the grip of an object.<sup>17</sup>

An injury to the ulnar nerve in the elbow can be diagnosed by finding a deceleration in the conduction velocity of the elbow segment. According to the American Association of Neuromuscular and Electrodiagnostic Medicine (AANEM), the deceleration of the elbow segment speed to less than 50 m/s with the elbow at 90° of flexion is the first abnormality criterion.<sup>19</sup>

An ulnar lesion in the elbow can also be diagnosed by decelerating the speed of the elbow in relation to the forearm by 10 m/s. This is the second AANEM criterion for abnormality.<sup>20</sup>

Studies of ulnar sensory conduction can contribute to the location of the lesion. In C8-T1 radiculopathy, the ulnar sensory action potential is normal because the lesion is preganglionic. The ulnar sensory response of the fifth finger remains normal if the elbow injury is purely demyelinating, because the axons distal to the elbow remain intact. When axonal damage is present, the amplitude of the sensory nerve action potential (SNAP) is reduced or absent.<sup>19</sup>

Non-ulnar muscles of the C8 myotome (abductor pollicis brevis, extensor indicis proprius) should be tested to exclude C8 radiculopathy or lower trunk/brachial plexopathy of the medial cord.<sup>13</sup>

The conservative treatment is indicated for patients with mild to moderate ulnar neuropathy in the elbow, characterized by intermittent or persistent sensory loss and weakness, and without structural damage.<sup>21</sup>

The surgical treatment is recommended for patients with convincing clinical and electrophysiological evidence of moderate to severe ulnar neuropathy in the elbow caused by trauma, structural abnormality, or nerve compression. The surgical treatment is chosen for those who show moderate to severe progressive symptoms and signs lasting six months, despite conservative measures.<sup>21</sup>

The two main categories of surgery currently performed for ulnar neuropathy in the elbow are in situ decompression of the ulnar nerve and ulnar transposition.<sup>21</sup>

Simple decompression for ulnar neuropathy in the elbow is usually performed by cutting the aponeurosis of the flexor carpi ulnaris (humeroulnar arcade) to decompress the ulnar nerve. Transposition of the ulnar nerve can be achieved by first cutting the humeroulnar arcade, and then mobilizing the ulnar nerve from the retrocondylar sulcus to a more anterior position.<sup>22</sup>

#### Ulnar Neuropathy in the Distal Forearm and Hand

Ulnar nerve injury in the distal forearm and hand is uncommon. Proximal to the wrist, the cutaneous palmar and cutaneous ulnar dorsal nerves branch off. When the nerve enters the hand through the Guyon Canal, it divides into deep and superficial terminal branches. The deep branch innervates all the muscles of the ulnar hand, except the palmaris brevis muscle. The superficial branch innervates the palmaris brevis muscle and then provides sensory innervation to the palmar aspects of the fourth and fifth fingers. Lesions can involve any of these branches individually or together.<sup>13</sup>

The nerve may be trapped or traumatized in the Guyon canal when it enters the hand. Ganglion cysts are a common cause. The most common clinical pattern is weakness sparing the hypothenar muscles, but involving all other muscles supplied by the ulnar nerve. An injury that produces only sensory deficits is rare.<sup>13</sup>

The electrodiagnostic assessment should include ulnar motor conduction to the hypothenar and first dorsal interosseous muscles, and sensory conduction to the fingers. The dorsal ulnar skin branch that appears in the region of the distal forearms should be tested if the sensory study of the fingers is abnormal. The results include prolongation of the distal motor latency. The amplitude of the Compound Muscle Action Potential (CMAP) test will be reduced if the axon is lost.<sup>13</sup>

Conduction velocities in the elbow and forearm segments should be normal. Sensory studies of the fourth or fifth fingers may show prolonged distal latency and reduced amplitude of response, if the superficial terminal branch is involved. The dorsal ulnar skin study should be normal. Electromyography will show abnormalities in the hypothenar muscles, the first dorsal interosseous or both, depending on the injury site. The forearm muscles innervated by the ulnar nerve must be normal.<sup>13</sup>

Conservative treatment is suggested as an initial treatment for patients with mild to moderate ulnar neuropathy in the wrist, characterized by intermittent or persistent loss and sensory weakness, and without structural damage. In addition, conservative treatment is recommended as an initial treatment for patients with moderate to severe but stable ulnar neuropathy, lasting less than six months.<sup>22</sup> For the less common condition of ulnar neuropathy in the wrist, surgery consists of decompression of the ulnar tunnel.<sup>22</sup>

#### Radial Nerve

The radial nerve is rarely affected by chronic compressions, but it is a common target for acute compressions. The most common etiology of radial neuropathies is trauma usually related to fracture of the humerus. Nerve entrapment usually occurs in the groove for the radial nerve in the humerus.<sup>9</sup> The common sites of compression of the radial nerve are shown in **Fig. 5**.<sup>33</sup>

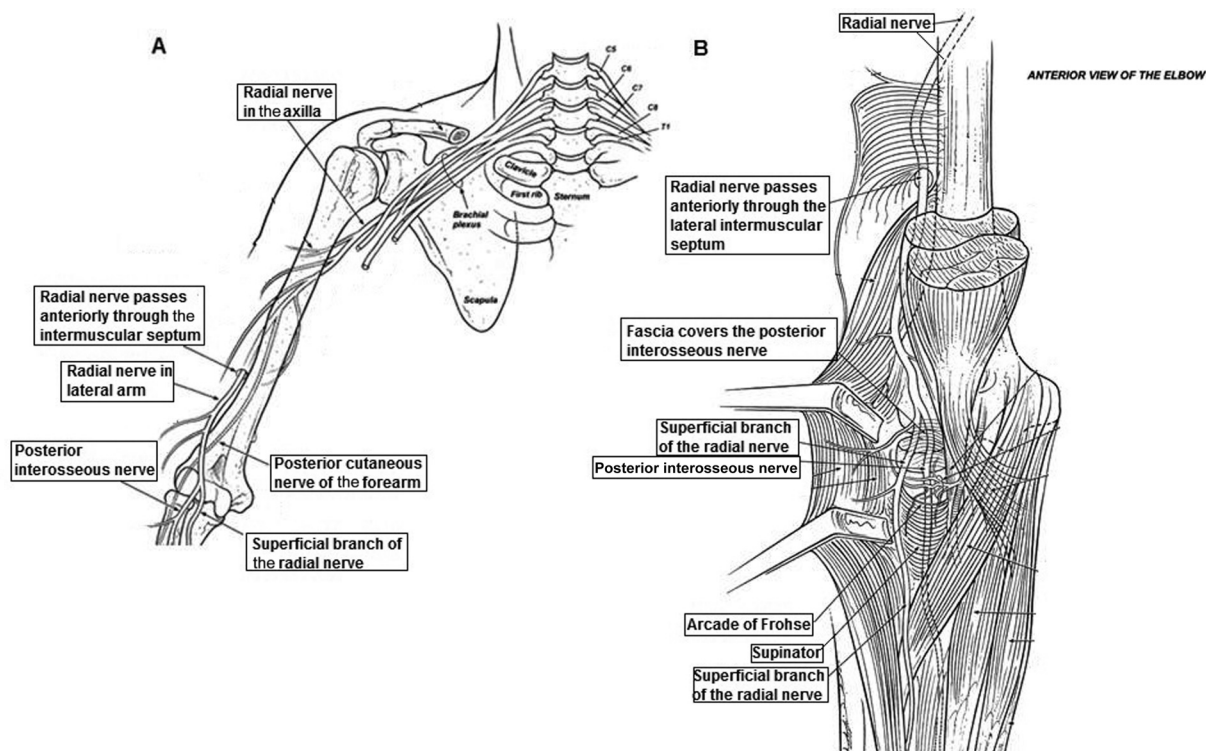
The radial nerve receives innervation from C5 to T1 through the posterior divisions of the three trunks of the brachial plexus to form the posterior fascicle, which then gives rise to the subscapular, axillary and radial nerves. In the arm, the radial nerve emits three branches: the posterior cutaneous nerve, the lower lateral cutaneous nerve, and the posterior cutaneous nerve of the forearm. Then, it goes along with the brachial artery deeply between the long head of the triceps and the humerus, and through the groove of the radial nerve. At the level of the elbow, the nerve then forks into two terminal branches, a superficial sensitive and a deep motor branch, called the posterior interosseous nerve.<sup>8</sup>

The posterior interosseous nerve passes through the arcade of Fröhse, which is formed by the fibrous arch that arises from the superficial head of the supinator muscle at its connection to the lateral epicondyle. It innervates the muscles responsible for supination of the forearm, wrist extension, finger extension, and thumb extension. The superficial sensitive branch is responsible for the cutaneous innervation of the dorsolateral region of the hand.<sup>23</sup>

#### Radial Neuropathy in the Arm (Saturday Night Paralysis)

Compression of the radial nerve is often described at the Arcade of Fröhse, but it can occur in the arm pit, in the spiral groove of the humerus. The entrapment of the radial nerve at the level of the radial groove of the humerus is the most common site. It can occur due to prolonged immobilization or direct compression of the nerve on the humeral bone (Saturday night paralysis). In this syndrome, the patient presses the middle third of the arm against a surface (for example, arm outstretched against crutches or back of a chair) mainly during sleep, intoxication or sedation.<sup>13</sup>

This part of the nerve can also be traumatized by humeral fractures, gunshot wounds, and intramuscular injections. Weakness of the wrist and finger extension occurs along with a sensation of disturbance on the dorsolateral aspect of the hand. Partial elbow flexion weakness may also be present due to brachioradial involvement. Elbow extension generally remains normal because the branches of the triceps leave the main proximal nerve trunk at the level of the humerus.<sup>13</sup>



**Fig. 5** Common sites of compression of the radial nerve: (A) axilla, groove for the radial nerve in the humerus. (B) Posterior interosseus nerve at the arcade of Fhronse. Source: Markiewitz and Merryman (2005).<sup>33</sup>

The results of radial conduction studies by electromyography can help locate the lesion site and also assist in the design of local demyelinating components versus axonal components. The sensory response of the superficial radial nerve remains normal if demyelination is the predominant pathology in lesions above the nerve bifurcation in the sensitive and motor branches of the elbow. A low amplitude or absent response indicates loss of the axon.<sup>24</sup>

The triceps muscles are spared when the lesion is below the humerus.<sup>24</sup>

Conservative treatment is usually the rule for patients with a single compression injury to the radial nerve, and its most important features are physical therapy, wrist splint (to maintain function), and pain control. The prognosis for full recovery is generally good.<sup>7</sup>

### Posterior Interosseous Syndrome

Posterior interosseous syndrome is a pure motor neuropathy which results from compression of the posterior interosseous nerve in the arcade of Fröhse related to excessive supination movements, trauma, and compressive injuries at the site, such as cysts and aneurysms. This syndrome presents with weakness in the extension of the fingers and, to a lesser extent, in the extension of the wrist. There is no sensory deficit.<sup>23</sup>

Low amplitudes of the indicator extensor, thumb extensor, extensor digitorum communis or extensor carpi ulnaris in the CMAP test are expected when the axon is lost.<sup>13</sup>

The non-radial muscles of the forearm should always be tested when the manifestations are predominantly radial. Multifocal motor neuropathy can also involve this nerve

more prominently than other nerves in the forearm or hand.<sup>13</sup>

► **Table 2** summarizes the provocative tests related to injuries to the main nerves in the upper limb. ► **Table 3**, on the other hand, shows the main sites of compression of the median, ulnar and radial nerves.

## Compressive Neuropathies of the Lower Limb

### Fibular Nerve

The common peroneal nerve (CPN), or common fibular nerve, consists of nerve fibers from the medullary roots of L4, L5, and S1. These fibers pass through the lumbosacral plexus, later forming, together with the neurons destined for the tibial nerve, the sciatic nerve. The path of the sciatic nerve runs through the posterior thigh, branching immediately above the popliteal fossa in its two primary branches: the tibial and common peroneal nerves. Then, the CPN follows distally and laterally, entering deeply into the lateral compartment of the leg, where it involves the fibular head anteriorly. Due to the close contact with this bone protuberance in the proximal and lateral regions of the leg, the nerve is more susceptible to excessive stretching or compressions that culminate in the development of compressive neuropathies.<sup>25–27</sup>

Inferior to the fibular head, the CPN is subdivided into superficial and deep branches. The superficial fibers are responsible for the sensitivity of the instep and the latero-distal portion of the leg, as well as for the motricity of the peroneus brevis and longus muscles (both responsible for eversion of the foot). The deep fibers are responsible for the

**Table 2** Provocative tests for nerve compression<sup>34</sup>

Nerve	Compression site	Provocative testing	Conservative management
Median	Carpal tunnel	Pressure proximal to the carpal tunnel	Wrist splint in neutral position at night
		Phalen test	
		Reverse Phalen test (wrist hyperextension)	
	Proximal forearm	Pressure on the proximal forearm in the region around the pronator muscle, with the forearm in supination	Use of stretching exercises for the pronator teres muscle
Resistance to elbow flexion, pronation, and finger flexion			
Ulnar	Guyon canal	Pressure proximal to the Guyon canal	Wrist splint in neutral position at night
		Reverse Phalen test	
	Cubital tunnel	Flexion and pressure of the elbow proximal to the cubital tunnel	Education about elbow position: position elbow in extension, and direct decrease in pressure on nerve
Radial (posterior interosseous)	Arcade of Fröhse	Pressure on the supine	Supine position and avoid repetition of pronation and supination activities
		Supination resistance	
		Finger extension and resisted wrist extension test (Cozen's test)	
Radial (sensitive)	Forearm	Pressure on the brachioradial junction/carpal radial extensor tendon	Avoid repeated pronation and supination activities
		Pronation of the forearm with ulnar flexion of the wrist	

Source: Mackinnon and Novak (2005).

sensitivity of the first interphalangeal region of the foot, and for the motricity of the anterior tibial muscles (dorsiflexion of the foot), the fibular third (dorsiflexion and eversion of the foot), and the short and long extensors of the hallux and toes (responsible for dorsiflexion of the toes).<sup>25-27</sup>

**Peroneal or Fibular Neuropathy**

The clinical picture of peroneal neuropathy (PN) usually leads to a dropped foot, decreased muscle strength for dorsiflexion of the foot, hallux and foot eversion, paresthesias, and loss of sensation on the anterolateral portion of the

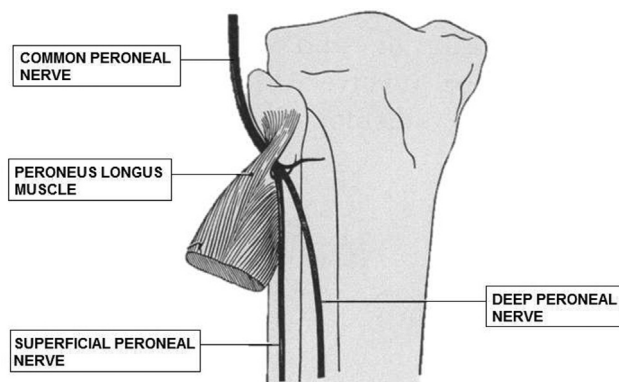
lower leg and on the instep. Other signs and symptoms that can be observed are: pain at night when the sheets touch the anterior side of the affected leg, antalgic gait, and slapping gait. Therefore, the physical examination of these patients must include a complete assessment of sensitivity (pain, touch, and vibration), motor skills, and motor coordination of the lower limbs, performing the Romberg test to identify a possible proprioceptive disorder and assessing the presence or absence of pathological gait.<sup>25-27</sup> The common site of compression in fibular (peroneal) nerve entrapment is shown in **Fig. 6**.<sup>35</sup>

Peroneal neuropathy is the most common compressive neuropathy of the lower limb.<sup>26,27</sup> Its onset may be acute, as in trauma episodes (such as in proximal fractures of the fibula), or due to chronic external compressive processes. The causes of chronic PN can be masses (such as ganglion cysts) or pressures exerted during prolonged periods of immobilization (such as procedures with the use of anesthetics, use of orthoses, or during the usual leg crossing). The main risk factors are related to the decrease in subcutaneous cell tissue, as in patients with low body mass index (BMI), or in those who have experienced episodes of rapid weight loss, since they make the nerve more susceptible to compression injuries. Diabetic neuropathy should be considered in this context, since the accumulation of sorbitol in the tissue of the CPN can lead to its engorgement. Another factor predisposing to common peroneal neural injury is excessive prolonged squats.<sup>25,26</sup>

**Table 3** Nerve compression sites in the upper limbs

Nerve	Compression site
Median	Wrist (carpal tunnel syndrome)
	Anterior interosseous
	Elbow (pronator syndrome)
Ulnar	Elbow (cubital tunnel syndrome)
	Guyon canal
Radial	Armpit
	Groove for the radial nerve of the humerus
	Posterior interosseous
	Superficial sensitive branch (meralgia paresthetica)





**Fig. 6** Common site of compression in fibular (peroneal) nerve entrapment. The common peroneal nerve wraps around the head of the fibula in the proximal lateral lower leg. Source: Kopell and Thompson (1960).<sup>35</sup>

The main differential diagnoses for peroneal neuropathy are more proximal lesions of the sciatic nerve, lumbosacral plexus, or nerve roots from L4 to S1.<sup>25,26</sup> Weakness of foot plantar flexors (mediated by the gastrocnemius muscles innervated by the tibial nerve [L5-S2]) or of the hip abductors (mediated by the middle gluteal muscle, innervated by the upper gluteal nerve [L5-S1]), as well as the involvement of the patellar and achilles reflexes should alert to other causes of dropped feet that are not peroneal mononeuropathy.<sup>26</sup> Electrophysiological studies are particularly useful in the assessment of peroneal neuropathy. Electroneuromyography and nerve conduction studies enable the delimitation of the topography of the neurological lesion as exclusive to the peroneal nerve, and they provide evidence of focal compressions at the level of the fibular head, and are able to determine the extent of the axonal lesion, therefore enabling a prognostic assessment.<sup>26,27</sup> Electrophysiological studies should be performed in all patients with onset of foot drop, and repeated every three months to assess the improvement or worsening of the disease. In cases of trauma or postoperative neuropathy, these tests should be postponed for two to six weeks. Monitoring by neurophysiological tests can dictate the course of the treatment, including the surgical indications. The finding of an important nerve conduction delay along the CPN (> 50%) and ENMG showing significant impairment of motor innervation are used in some centers as criteria for surgical decompression.<sup>27</sup>

Imaging tests, such as US and MRI, are not routinely used; however, they are useful in complementing the clinical evaluation, especially in those individuals with suspected compressive mass.<sup>26</sup>

The prognosis of peroneal mononeuropathy is in most cases favorable. The treatment is generally conservative, consisting of supportive measures, such as patient education, removal of predisposing factors, indication of support equipment (such as orthoses for dropped feet, splints for nightly use, padding of the region of the fibular head), and physiotherapy. The predictors of a worse prognosis are advanced age, severe paresis at the beginning of the presentation of the disease, and evidence of denervation on ENMG. Surgical decompression is still controversial, due to the excellent

results of the conservative treatment, and is therefore limited to those individuals who do not improve after three months of conservative treatment or who show progressive symptoms in the absence of a clear cause for nerve compression.<sup>26,27</sup>

### Femoral Nerve

The lateral femoral cutaneous nerve (LFCN) originates from the lumbar plexus, consisting of fibers from the nerve roots of L2 and L3.<sup>26,28,29</sup> The nerve appears approximately at the level of the lateral margin of the psoas major muscle, then acquiring an oblique path along the abdomen toward the inguinal ligament on the anterior surface of the iliac muscle, a region in which it is surrounded by the dense layer of iliac fascia tissue.<sup>28</sup> The exit point of the LFCN from the abdomen presents considerable anatomical variation, with some configurations showing a greater predisposition to the development of compressive neuropathies, such as those in which the nerve is located within the inguinal ligament, within the tendon insertion of the sartorius muscle, or in those in which the nerve courses above the iliac crest.<sup>26</sup>

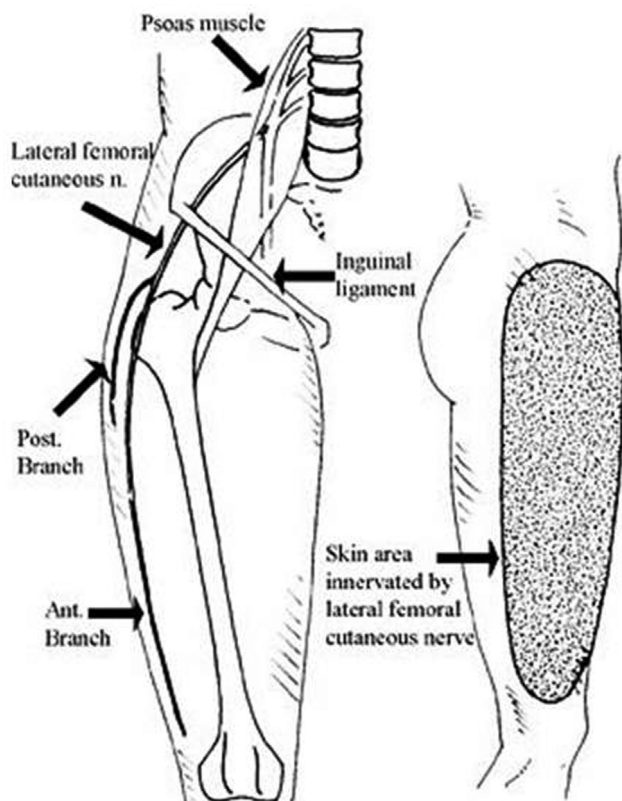
The close anatomical relationships of the LFCN with the pelvic margins is the main factor predisposing to compressive injuries.<sup>26</sup> In 85% of the individuals, the nerve leaves the abdominal region medially to the sartorius muscle; however, even in these situations, it has different proximity relations with the anterosuperior iliac crest (ASIC). The average distance from the LFCN to the ASIC is of ~ 8 mm, which can vary from a minimum of 0 mm to a maximum of 40 mm. It is postulated that the closer proximity of the nerve to ASIC, as well as the other abnormal trajectories (the remaining 15%), increase the chance of developing meralgia paresthetica (MP).<sup>28</sup>

### Meralgia Paresthetica: Neuropathy of the Lateral Femoral Cutaneous Nerve

Meralgia paresthetica is the second most common mononeuropathy of the lower limbs, with ~ 30 to 40 new cases per 100 thousand inhabitants per year.<sup>26,28,30</sup> The main risk factors for this pathology are obesity, diabetes, and the male gender. Its symptoms include sensory disturbances (pain, discomfort, numbness, paresthesia, burning, and hypersensitivity to touch) in the anterolateral region of the affected thigh. An important characteristic of MP is the lack of involvement of the patient's degree of muscle strength, since the LFCN is not constituted by any motor fibers; thus, MP is an exclusively sensitive disease.<sup>26,28-30</sup> There are numerous reported causes of MP, which are classified as spontaneous or iatrogenic.<sup>28</sup> Among the spontaneous etiologies, the following can be highlighted: intense compressions and excessive stretching of the nerve due to the use of external clothing and accessories (very tight pants and belts or fanny packs for heavy objects), increased abdominal weight (in obese, pregnant, and ascitic individuals), and acute trauma caused by the seat belt during automobile accidents.<sup>26,29</sup> One of the most frequent iatrogenic injuries to the LFCN in the clinical practice are spine surgeries in which the patient remains in prone position (the incidence of

MP ranges from 12% to 24%); obese patients or those with long periods of immobilization during surgery are at higher risk; however, in these cases, the injury is temporary, with spontaneous regression of symptoms.<sup>28</sup> Other invasive procedures that involve an iatrogenic risk of developing MP are the anterior approaches to the hip and pelvis, external fixations of the pelvis with insertion of screws in the ASIC, and techniques for removing bone grafts from the iliac crest.<sup>26</sup> The common site of compression of the LFCN is shown in ►Fig. 7.<sup>36</sup>

The diagnosis of MP is eminently clinical, through anamnesis and physical examination. These should demonstrate a well-defined sensory disturbance in the anterolateral thigh region, extending from the femoral trochanter to the upper margin of the patella.<sup>26</sup> Most patients report the sensation of numbness in the affected limb; however, burning and tingling are also frequently reported. The history of the disease can vary from intermittent symptoms with spontaneous resolution in a short time (~ 25% of individuals show spontaneous improvement) to continuous symptoms for long periods of time (with reports of up to 30 years in duration).<sup>28,29</sup> Any conditions that generate greater pressure or stretching of the LFCN can worsen the symptoms, such as, long periods of standing or excessive extensions of the hip joint when driving or walking.<sup>28</sup> The pelvic compression test, performed at the level of the inguinal ligament, is a non-invasive semiological tool which is useful in the diagnosis of



**Fig. 7** Common site of compression of lateral femoral cutaneous nerve (LFCN). The close anatomical relationships of the LFCN with the pelvic margins are the main factor predisposing to compressive injuries. Source: Goulding et al. (2010).<sup>36</sup>

MP, with a study<sup>28</sup> showing a sensitivity of 95% and a specificity of 93.3%. The presence of concomitant motor abnormalities makes it necessary to investigate other etiologies. The presence of paresis of the iliopsoas muscle, in particular, identified by the decrease in muscle strength in hip flexion, suggests the involvement of the medullary level of L2 (as in the case of high lumbar disc hernias), and is an important differential diagnosis to be considered.<sup>26,29</sup>

Ultrasonography is extremely useful to locate the LFCN, for it enables the identification of atypical nerve pathways and acts as a guide to perform interventions such as anesthetic blocks. However, its importance in the diagnosis of MP remains poorly established by scientific evidence. Some studies correlated data such as the presence of hypoechoic or swollen LFCN with MP, and have stated that certain parameters, such as the cross-sectional area and the maximum diameter of the nerve, can be used as diagnostic criteria. However, larger and more methodologically-elaborate studies are still needed to establish US as a diagnostic method.<sup>28</sup>

Other imaging exams, such as the MRI, the CT, and radiography, have limited usefulness in the diagnosis of LFCN mononeuropathy, and are indicated in an attempt to evaluate other neurological diseases that are part of the differential diagnosis of MP (such as lumbar disc herniation and tumors located in the region of the lumbar plexus).<sup>28</sup>

Electrophysiological studies help confirm the diagnosis, although they are not routinely performed and present technical difficulties due to the intense anatomical variability of the neural pathway among patients.<sup>26</sup> Motor conduction studies must be normal, which makes it possible to rule out spinal cord and nerve root diseases, or polyneuropathies. The two main tests available to assess MP are somatosensory evoked potentials (SSEPs) and sensory nerve conduction tests.<sup>28-30</sup> The SSEPs have the main advantage of their greater accessibility and easy performance, especially in obese patients; however, despite its good specificity (76%), the test has a sensitivity of only 52%. This results in a high rate of false-negatives and, consequently, in the underdiagnosis of the population with MP. Sensitive nerve conduction tests, on the other hand, enable the calculation of the sensitive nerve action potential (SNAP) and the side-to-side amplitude ratio (SSAR), with better accuracy. Amplitudes of the SNAP below 3 diagnose PM in 73.3% of the patients, whereas a SSAR of 2.3 has a specificity greater than 98.75%.<sup>28</sup>

The therapeutic approaches for this pathology can be divided into three main modalities: conservative treatment, the use of nerve blocks, and surgical interventions.<sup>28,30</sup> Currently, there is still little scientific evidence to indicate the superiority of one modality in relation to another; however, the majority of patients are submitted to conservative treatment due to the lower risks involved and the good rate of improvement of the symptoms. The conservative management includes general supportive measures, reduction of risk factors (such as weight loss for obese patients and avoiding the use of tight clothing or accessories around the waist), and use of non-steroidal anti-inflammatory drugs, anticonvulsants, and antidepressants to alleviate the

neuropathic pain.<sup>26,28,29</sup> As a good number of individuals report improvement with the aforementioned measures, interventional therapies, anesthetic and corticosteroid injections, and surgical decompression remain as exceptional approaches (second option, depending on the risks and benefits) for MP.<sup>26</sup>

The two main surgical approaches to MP are neurolysis and neurotomy. In the former, the surgeon's objective is to relieve the compression points of the NCFL along its path, and the main technique consists of three steps: cutting the inguinal ligament in its portion on the nerve, cutting the iliac fascia that surrounds the nerve, and making distal cuts in the thigh fascia for each division of the nerve. The average success rate for this procedure is of 80% (range: 60% to 99%). Neurotomy, on the other hand, consists of direct injury to the LFCN, providing relief from unpleasant sensory symptoms at the cost of remaining numb in the affected region as a sequela of the procedure. The success rate is higher than that of neurolysis, varying from 85% to 100% of the cases, with studies even showing that most individuals were not bothered by the sequelae of the operation. Therefore, it is up to the physician to inform the patient of the therapeutic options, and together they can decide on the best strategy in surgical cases.<sup>28,30</sup>

## Conclusion

The present review showed the importance of better understanding regarding clinical presentation and more accurate diagnostic methods to assist in the management of compressive neuropathies of the limbs.

### Conflict of Interests

The authors have no conflict of interests to declare.

## References

- Karvat J, Vieira L, Kakihata C, et al. Crioterapia em modelo de compressão do nervo isquiático: análise funcional e morfológica. *Rev Bras Med Esporte* 2018;24(01):54–59
- Monteiro JD. Síndrome do túnel do carpo associado à prática clínica de Medicina Dentária. Porto. [Dissertação mestrado]. Repositório Institucional da Universidade Fernando Pessoa; 2017
- Moraes MA, Gonçalves RG, Santos JBGD, Belloti JC, Faloppa F, Moraes VY. Diagnosis and treatment of posterior interosseous nerve entrapment: systematic review. *Acta Ortop Bras* 2017;25(01):52–54
- Figueiredo R. O Papel da Ultrassonografia no acompanhamento da Síndrome do Túnel do Carpo. *Revista da Sociedade Brasileira de Ultrassonografia* 2018:25–30
- Doughty CT, Bowley MP. Entrapment Neuropathies of the Upper Extremity. *Med Clin North Am* 2019;103(02):357–370
- Lee EY, Lim AYT. Nerve Compression in the Upper Limb. *Clin Plast Surg* 2019;46(03):285–293
- Rutkove S. Overview of upper extremity peripheral nerve syndromes. In: Eichler A, ed. *UpToDate*. Access in: 2020 (12 Fev). 2019[https://www.uptodate.com/contents/overview-of-upper-extremity-peripheral-nerve-syndromes?search=Neuropatias%20compressivas%20do%20membro%20superior&source=search\\_result&selectedTitle=1~150&usage\\_type=default&display\\_rank=1](https://www.uptodate.com/contents/overview-of-upper-extremity-peripheral-nerve-syndromes?search=Neuropatias%20compressivas%20do%20membro%20superior&source=search_result&selectedTitle=1~150&usage_type=default&display_rank=1)
- Hobson-Webb LD, Juel VC. Common Entrapment Neuropathies. *Continuum (Minneapolis)* 2017;23(02 Selected Topics in Out-patient Neurology):487–511
- Malek E, Salameh JS. Common Entrapment Neuropathies. *Semin Neurol* 2019;39(05):549–559
- Schmid AB, Hailey L, Tampin B. Entrapment Neuropathies: Challenging Common Beliefs With Novel Evidence. *J Orthop Sports Phys Ther* 2018;48(02):58–62
- Dec P, Zyluk A. Bilateral carpal tunnel syndrome - A review. *Neurol Neurochir Pol* 2018;52(01):79–83
- Mendes GA. Avaliação do uso de smartphones na incidência da neuropatia compressiva: síndrome do tunel do carpo. in: 1º congresso internacional de ergonomia aplicada [blucher engineering proceedings, v. 3 n. 3]. São Paulo: blucher; 2016:933–942
- Kincaid JC. Upper extremity neuropathies. *Handb Clin Neurol* 2019;161(03):197–205
- Fowler JR. Nerve conduction studies for carpal tunnel syndrome: gold standard or unnecessary evil. *Orthopedics* 2017;40(03):141–142
- Kothari M. Carpal tunnel syndrome: Clinical manifestations and diagnosis. In: Eichler A, ed. *UpToDate*. Accessed in: 2020 (Fev). 2019[https://www.uptodate.com/contents/carpal-tunnel-syndrome-clinical-manifestations-and-diagnosis?search=Neuropatias%20compressivas%20do%20membro%20superior&topicRef=5282&source=see\\_link#references](https://www.uptodate.com/contents/carpal-tunnel-syndrome-clinical-manifestations-and-diagnosis?search=Neuropatias%20compressivas%20do%20membro%20superior&topicRef=5282&source=see_link#references)
- Kumbhare D, Robinson L, Buschbacher R. *Bushbacher's manual of nerve conduction studies*. third ed. New York: Demos Medical; 2016
- Mathias RN, Siqueira MG, Martins RS, Neto HS, Foroni L, Teixeira MJ. Compression of the Ulnar Nerve in the Elbow Region - Cubital Tunnel Syndrome: Review of the Literature. *Braz Neurosurg* 2015;34:128–133
- Dy CJ, Mackinnon SE. Ulnar neuropathy: evaluation and management. *Curr Rev Musculoskelet Med* 2016;9(02):178–184
- Pugdahl K, Beniczky S, Wanscher B, et al. Neurophysiological localisation of ulnar neuropathy at the elbow: Validation of diagnostic criteria developed by a taskforce of the Danish Society of clinical neurophysiology. *Clin Neurophysiol* 2017;128(11):2205–2210
- Omejec G, Podnar S. Normative values for short-segment nerve conduction studies and ultrasonography of the ulnar nerve at the elbow. *Muscle Nerve* 2015;51(03):370–377
- Shah CM, Calfee RP, Gelberman RH, Goldfarb CA. Outcomes of rigid night splinting and activity modification in the treatment of cubital tunnel syndrome. *J Hand Surg Am* 2013;38(06):1125–1130.e1
- Doherty T. Ulnar neuropathy at the elbow and wrist. In: Eichler A, ed. *UpToDate*. Accessed in: 2020 (Fev). 2018[https://www.uptodate.com/contents/ulnar-neuropathy-at-the-elbow-and-wrist?sectionName=Conservative%20treatment&search=Neuropatias%20compressivas%20do%20membro%20superior&topicRef=5282&anchor=H626065&source=see\\_link#H626065](https://www.uptodate.com/contents/ulnar-neuropathy-at-the-elbow-and-wrist?sectionName=Conservative%20treatment&search=Neuropatias%20compressivas%20do%20membro%20superior&topicRef=5282&anchor=H626065&source=see_link#H626065)
- Strohl AB, Zelouf DS. Ulnar Tunnel Syndrome, Radial Tunnel Syndrome, Anterior Interosseous Nerve Syndrome, and Pronator Syndrome. *J Am Acad Orthop Surg* 2017;25(01):e1–e10
- Kim JG, Kim D, Seok HY, et al. A method of radial nerve measurement based on cadaveric investigation. *Arch Phys Med Rehabil* 2017;98(03):596–599
- Anderson JC. Common Fibular Nerve Compression: Anatomy, Symptoms, Clinical Evaluation, and Surgical Decompression. *Clin Podiatr Med Surg* 2016;33(02):283–291
- Bowley MP, Doughty CT. Entrapment Neuropathies of the Lower Extremity. *Med Clin North Am* 2019;103(02):371–382
- Poage C, Roth C, Scott B. Peroneal Nerve Palsy: Evaluation and Management. *J Am Acad Orthop Surg* 2016;24(01):1–10
- Sanjaya A. Meralgia paresthetica: finding an effective cure. *Postgrad Med* 2020;132(01):1–6
- Schuh A, Handschu R, Eibl T, Janka M, Hönle W. Die Meralgia paraesthetica. *MMW Fortschr Med* 2017;159(19):66–68
- Payne R, Seaman S, Sieg E, Langan S, Harbaugh K, Rizk E. Evaluating the evidence: is neurolysis or neurectomy a better treatment for meralgia paresthetica? *Acta Neurochir (Wien)* 2017;159(05):931–936

- 31 Koo J, Szabo R. Compression neuropathies of the median nerve. *J Am Soc Surg Hand* 2004;4(03):156-175
- 32 Terry G, Zeigler T. Cubital Tunnel Syndrome. *Operative Treatment of Elbow Injuries* 2002:131-139
- 33 Markiewitz A, Merryman J. Radial Nerve Compression in the Upper Extremity. *J Am Soc Surg Hand* 2005;5(02):87-99
- 34 Mackinnon SE, Novak CB. Compression neuropathies. In: Green DP, Hotchkiss RN, Pederson WC, (eds) *Green's operative hand surgery*. . Churchill Livingstone, New York, pp 999-1046, Elsevier Churchill Livingstone Philadelphia, Pa, USA, 2005
- 35 Kopell HP, Thompson WA. [Peripheral entrapment neuropathies of the lower extremity]. *N Engl J Med* 1960;262(02):56-60
- 36 Goulding K, Beaulé PE, Kim PR, Fazekas A. Incidence of lateral femoral cutaneous nerve neuropraxia after anterior approach hip arthroplasty. *Clin Orthop Relat Res* 2010;468(09):2397-2404