



# Percutaneous Vertebroplasty: Efficacy of Unipedicular Vertebroplasty as Compared to Bipedicular Vertebroplasty

Mahendra Kumar Dwivedi<sup>1</sup> Vikrant Bhende<sup>1</sup> Dnyaneshwar Narayanrao Panchbhaiyye<sup>1</sup>  
Madhura Vijay Bayaskar<sup>1</sup>

<sup>1</sup> Department of Radio Diagnosis, Shri Shankaracharya Institute of Medical Sciences, Junwani, Bhilai, Chhattisgarh, India

Address for correspondence Vikrant Bhende, Department of Radio Diagnosis, Shri Shankaracharya Institute of Medical Sciences, Junwani, Chhattisgarh, Bhilai (e-mail: drvikrant13@gmail.com).

Indian J Radiol Imaging 2021;31:867–872.

## Abstract

**Introduction** Percutaneous vertebroplasty has been used for treatment of intractable painful fractures of vertebral bodies. With the help of refined procedures and standard techniques, the interventional radiologist can now offer help to orthopedics and neurosurgeons in these cases, which include treatment of vertebral compression fracture. Vertebroplasty is aimed at reducing the pain induced by collapse. Vertebroplasty is the standard mode of treatment for vertebral collapse, and in our study, bipedicular vertebroplasty was compared with unipedicular approach as bipedicular vertebroplasty is the routinely used approach.

**Aim** To compare efficacy of unipedicular percutaneous vertebroplasty with that of bipedicular percutaneous vertebroplasty.

**Material and Methods** A total of 52 vertebroplasties were done over a period of 2 years. Out of 52 patients, 28 patients underwent unipedicular vertebroplasty and 24 patients underwent bipedicular vertebroplasty. Visual analogue scale (VAS) scores were used to assess the pain prior to vertebroplasty and after vertebroplasty. Efficacy of the two procedures were assessed by comparing VAS scores.

**Results** There was no statistically significant difference observed in the preprocedure and postprocedure VAS scores ( $p$ -value  $< 0.0001$ ,  $< 0.0001$ , respectively). The mean procedure time was lesser in unipedicular vertebroplasty ( $41.9 \pm 3.90$ ) than bipedicular vertebroplasty ( $54.5 \pm 3.4$ ).

**Conclusion** Unipedicular vertebroplasty is as effective as bipedicular vertebroplasty, as there is insignificant difference in postprocedure VAS scores between the unipedicular and bipedicular vertebroplasty.

## Keywords

- ▶ Bipedicular vertebroplasty
- ▶ Percutaneous Vertebroplasty
- ▶ Unipedicular vertebroplasty
- ▶ Visual analogue scale

## Introduction

Vertebroplasty procedure consists of fluoroscopic-guided percutaneous injection of polymethyl methyl acrylate

(PMMA) surgical bone cement into the vertebral body. Injection of PMMA provides immediate stability.

Vertebral compression fracture is a common clinical problem, with osteoporosis being the leading cause of

published online  
January 10, 2022

DOI <https://doi.org/10.1055/s-0041-1739375>.  
ISSN 0971-3026.

© 2022. Indian Radiological Association. All rights reserved.  
This is an open access article published by Thieme under the terms of the Creative Commons Attribution-NonDerivative-NonCommercial-License, permitting copying and reproduction so long as the original work is given appropriate credit. Contents may not be used for commercial purposes, or adapted, remixed, transformed or built upon. (<https://creativecommons.org/licenses/by-nc-nd/4.0/>)  
Thieme Medical and Scientific Publishers Pvt. Ltd., A-12, 2nd Floor, Sector 2, Noida-201301 UP, India

nontraumatic vertebral fracture.<sup>1</sup> Osteoporosis is low-bone mass and microarchitectural deterioration of bone tissue, leading to decreased bone strength and an increased susceptibility to fractures. Osteoporosis is a major global health problem affecting an increasing number of women and men beyond 50 years of age.<sup>2</sup> The prevalence of vertebral fractures reported in Indian women is 17%.<sup>3</sup> Vertebral compression fracture causes pain and deformity, leading to disability and poor quality of life. Early detection and treatment of vertebral compression fracture helps to improve the quality of life.<sup>1</sup>

Benign and malignant collapse of vertebrae is common in the middle-aged and elderly population.<sup>4</sup> Malignancies of breast, prostate, thyroid, and lung have tendency to metastasize to bone, which can lead to collapse of vertebra,<sup>5</sup> and in 10 to 15% cancers, the spine is a common site of metastasis.<sup>6</sup> Primary bone tumors and lymphoproliferative malignancies such as lymphoma and multiple myeloma can be the cause of collapse of vertebra in addition to metastasis.<sup>7</sup>

Traumatic injuries of spine are usually caused by axial loading or lateral flexion which, in turn, cause loss of vertebral body height or disruption of the vertebral endplate. In less severe compression injuries, only the anterior portion of the vertebral body is involved. Increased force results in burst fractures and involves the posterior vertebral body with varying degrees of retropulsion.<sup>8</sup>

Traditionally, uncomplicated vertebral compression fractures were treated with analgesia, bracing and rehabilitation. Open reduction and internal fixation is rarely performed due to poor bone stock and multiple underlying comorbidities. Percutaneous vertebroplasty is a less invasive therapeutic option for elderly patients with multiple comorbidities, which allows early mobilization and thus remains a commonly used and safe technique for the symptomatic treatment of vertebral compression fractures for both osteoporotic and neoplastic.<sup>9</sup>

Technique of vertebroplasty has developed considerably since it was first done by Galibert and Deramond in 1984.<sup>10</sup> Jensen et al described 90% pain relief for osteoporotic vertebral collapse in 1997.<sup>11</sup> Since then, vertebroplasty has come a long way and has become standard mode of treatment for painful osteoporotic compression fracture of the spine.<sup>12</sup> Bipedicular approach is routinely used, although reports show similar results in unipedicular and bipedicular approach.<sup>13</sup>

We conducted the study to compare efficacy of unipedicular percutaneous vertebroplasty with that of bipedicular percutaneous vertebroplasty.

## Materials and Methods

Institutional ethical committee clearance was taken. We included 52 vertebroplasties in our study from January 2017 to December 2019.

### Inclusion Criteria

Inclusion criteria were (a) patients with persistent pain after compression fracture; (b) patients with painful osteoporotic

vertebral collapse in whom conservative treatment have failed; (c) patient with midline pain with loading of spine and relief with recumbency; (d) patients with vertebral collapse fracture with bone marrow edema or fluid cleft in magnetic resonance imaging (MRI).

### Exclusion Criteria

Exclusion criteria were (a) patients with bleeding disorder, (b) patients with spinal infection, (c) patients with other systemic comorbid conditions, (d) vertebral compression with epidural component, (e) vertebral collapse with posterior vertebral cortical breach or retropulsed fragments, and (f) involvement of posterior elements. Multidetector computed tomography (MDCT) was done to see the breach in posterior margin of vertebra. Balloon kyphoplasty and CT fluoroscopy-guided kyphoplasty were not included in our study, although these procedures are used to reduce pain and give stability.

Out of 52 patients, 28 patients underwent unipedicular vertebroplasty and 24 patients underwent bipedicular vertebroplasty. Visual analogue scale (VAS) scores were used to assess the pain prior to vertebroplasty and after the vertebroplasty. Efficacy of the two procedures was assessed by comparing VAS scores before and 24 hours after the procedure. Follow-up was done only at 24 hours after the procedure for assessment of VAS score. As most patients got relief after 24 hours, so they did not come for follow-up.

Patients were assigned a serial number, according to the sequence of admission in hospital and distributed in two different groups, that is, unipedicular vertebroplasty group and bipedicular vertebroplasty group by lottery method.

## Technique of Vertebroplasty

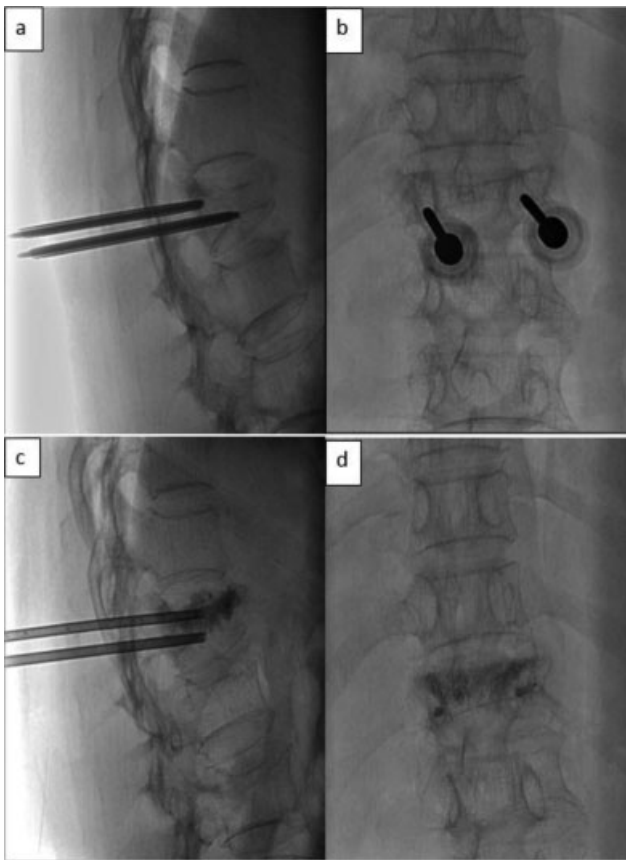
Vertebroplasty was done under local anesthesia and short sedation by diazepam/midazolam (3–4 mg). Antibiotic 1 g of cefazolin was routinely given intravenously (IV) before procedure. Procedure was done under C-arm guidance with patient in prone position under all aseptic precautions. After localization of vertebral pedicle, local anesthesia was given up to periosteum of vertebra. Entry point of needle was 3 o'clock and 9 o'clock position of vertebral pedicle.

Needle was advanced through the pedicle into body under C-arm. The ideal location of tip of needle is at the junction of anterior and middle third of vertebral body (→ **Figs. 1** and **2**), the area of less side venous plexuses. Needle was advanced by repeated taps.

To predict the leak before injection of PMMA, iohexol was injected through needle, and if leak was visualized, the needle tip was further adjusted. In case there is leak of iohexol, despite needle adjustment, the injection is stopped and not attempted again. The patients were shifted in the recovery room till the effects of anesthesia wore off.

Under fluoroscopic guidance, injection of PMMA bone cement was administered into vertebral body.

Volume of PMMA injected was less than 3 mL with hand injection. Cement was injected when it had toothpaste-like consistency.



**Fig. 1** Spot fluoroscopic images obtained during bipedicular vertebroplasty. (a) and (b) intraprocedural lateral and AP projections demonstrates tips of needle in situ. (c) and (d) Spot lateral and AP fluoroscopic images following percutaneous vertebroplasty with filling of vertebral body by cement without evidence of leak.

The venogram was obtained to visualize the sites of leak, and if leak was found, the needle tip was further adjusted. The contrast media used for venography was iohexol 300. Postprocedure MDCT thorax study was done to rule out pulmonary artery embolization due to cement leak (► **Fig. 3**).

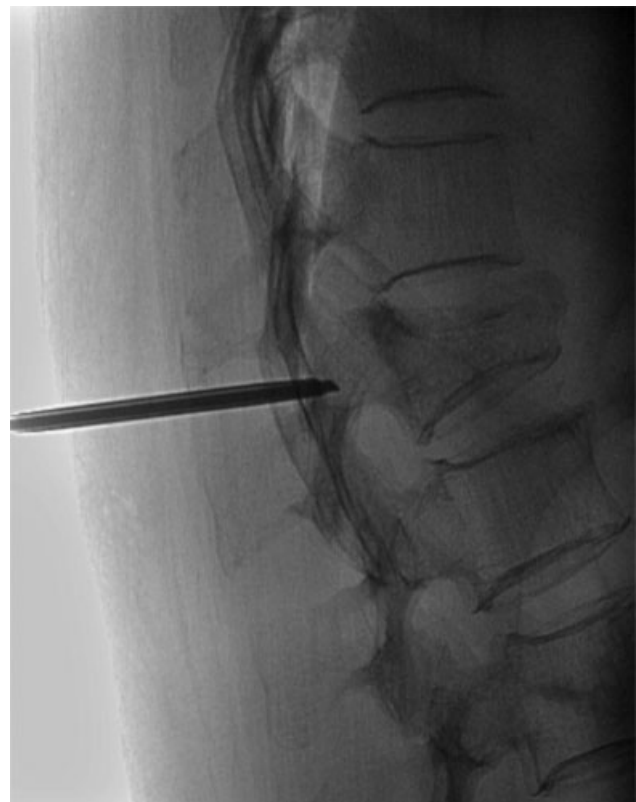### Complications of Procedure

Leakage of cement into venous system may lead to pulmonary embolization.<sup>11</sup> This complication is more encountered in lytic metastasis and where there is leakage of cement into the soft tissues.

Leakage into intervertebral disc will increase the chances of adjacent vertebral body fracture by increasing stiffness of disc. Leakage of cement into neural foramina and spinal canal (► **Fig. 4**) can produce radicular pain, which can be detected on CT scan.

Cement leakage into intervertebral disc or spinal canal can be prevented by using high-quality digital subtraction angiography (DSA) C-arm and slow injection of optimum viscous PMMA under direct visualization during fluoroscopy.

Theoretically, there are chances of fat embolism due to extropulsion of bone marrow. Other complications can be due to anesthesia, misplaced needles, cement extravasations, injections, and fracture at adjacent levels.



**Fig. 2** Spot lateral fluoroscopic image during unipedicular vertebroplasty with tip of needle in situ.

### Outcome Analysis

Outcomes of the two procedures were assessed by comparing VAS score before and after the procedure as marker of analgesic efficacy, procedure time and complications of procedure. Follow-up was done at 24 hours postprocedure for assessment of VAS score. As most of the patients got relief after 24 hours, so they did not come for follow-up.

### Statistical Analysis

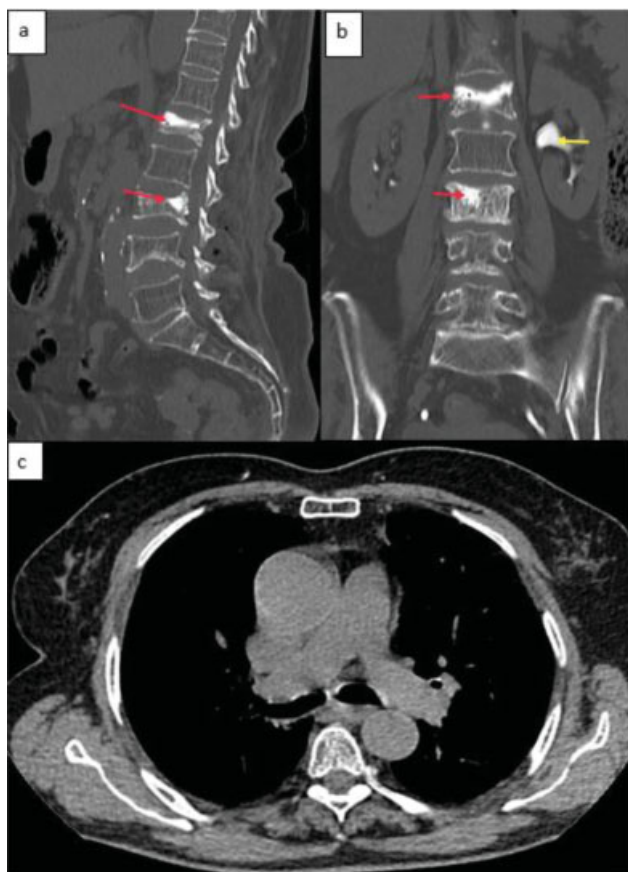
Data entry was done using Microsoft Excel 2016. Data was analyzed using epi info 7.2.2.2. Data analysis was two-tailed, and significance values were considered if less than 0.05.

After testing the normality of data, using Wilcoxon signed rank Test (for categorical data) and independent *t*-test (for nominal data), we deduced the results.

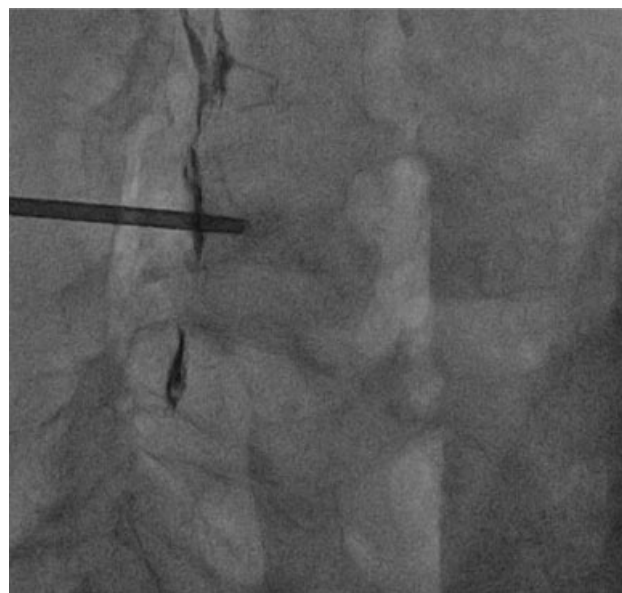
### Results/Our Experience

Out of 52 cases, there were 44 cases of osteoporotic collapse. There were 8 cases of spinal metastasis with lytic lesions (4—breast, 4—lung). Male to female ratio was 1:3 (► **Table 1**). Significant pain relief is defined as decrease of VAS score of > 50%, and it was reported in all the 52 patients.

In unipedicular vertebroplasty, 16 had lumbar collapse, 9 had thoracic collapse, and 3 had both thoracic and lumbar collapse. In bipedicular vertebroplasty, 13 had lumbar collapse, 8 had thoracic collapse, and 3 had both thoracic and lumbar collapse.



**Fig. 3** Postprocedure computed tomography (CT) images sagittal (a) and coronal (b) reconstruction show two levels, that is, L1 and L3 vertebral compression fracture treated successfully with percutaneous vertebroplasty (red arrow) excreted contrast in renal pelvicalyceal system (yellow arrow) injected intravenously to obtain venogram to visualize the sites of leak. (c) postprocedure CT thorax study does not demonstrate pulmonary embolism.



**Fig. 4** Spot lateral fluoroscopic image during unipedicular vertebroplasty with leakage of cement without satisfactory filling of vertebral body.

There was no significant difference between the two groups in terms of the preprocedure ( $p < 0.0001$ ) and postprocedure ( $p < 0.0001$ ) VAS scores (→ **Table 2**).

In cases undergoing unipedicular vertebroplasty, the mean pain score on the VAS was 8.03 prior to procedure and decreased to 2.60 in postprocedure period after 24 hours.

In cases undergoing bipedicular vertebroplasty, the mean pain score on the VAS was 8.25 prior to procedure and decreased to 2.45 in postprocedure period after 24 hours.

**Table 1** Table showing comparison of two study groups ( $n = 52$ ) After testing the normality of data, using Wilcoxon signed rank test (for categorical data) and independent  $t$ -test (for nominal data), we deduced the following results.

Parameter	Unipedicular vertebroplasty group	Bipedicular vertebroplasty group	$p$ -Value
Cases ( $n$ )	28	24	–
Male: Female	1:3	1:3	$< 0.0001$
Age (years)	$72.2 \pm 5.07$	$69.16 \pm 5.67$	0.044
Procedure time in minutes	$41.9 \pm 3.90$	$54.5 \pm 3.4$	$< 0.0001$
Volume of injected cement in mL	$2.22 \pm 0.34$	$2.2 \pm 0.34$	0.823
Complications	6 (21.4%)	3 (12.5%)	0.406

The  $p$ -values for between-group comparison were determined by  $t$ -tests, statistically significant ( $p$ -value  $< 0.05$ )

**Table 2** Table showing clinical outcome of two groups ( $n = 52$ )

VAS	Unipedicular vertebroplasty group	Bipedicular vertebroplasty group	$p$ -Value
Pre procedure	$8.03 \pm 0.88$ (IQR = 2)	$8.25 \pm 0.94$ (IQR = 1)	$< 0.0001$
Post procedure	$2.60 \pm 0.68$ (IQR = 1)	$2.45 \pm 0.58$ (IQR = 1)	$< 0.0001$

Abbreviations: IQR, interquartile range; VAS, visual analogue scale.

The  $p$ -values for between-group comparison were determined by  $t$ -tests, statistically significant ( $p$ -value  $< 0.05$ )

The mean procedure time was  $41.9 \pm 3.90$  minutes in unipedicular vertebroplasty, which was lesser than in bipedicular vertebroplasty where the procedure time was  $54.5 \pm 3.4$  minutes (**Table 1**).

The average bone cement (PMMA) volume was  $2.22 \pm 0.34$  mL in unipedicular vertebroplasty and  $2.20 \pm 0.34$  mL in bipedicular vertebroplasty (**Table 1**).

We encountered minor complications in 6 (21%) patients in unipedicular vertebroplasty and in 4 (15%) patients in bipedicular vertebroplasty in the form of leakage of cement, which was statistically insignificant ( $p = 0.406$ ). However, patients were asymptomatic, and no further treatment was required.

## Discussion

Compression fractures of vertebral bodies is a major cause of considerable mortality and morbidity. Vertebroplasty is a highly effective procedure if the traditional form of conservative management fails. Analgesia, bracing, and rehabilitation are the conservative means of treatment for vertebral compression fracture. The procedure is relatively noninvasive and is safe in experienced hands. Some authors put the patients on conservative therapy for 4 to 6 weeks before performing vertebroplasty.<sup>14</sup> Patients with painful osteoporotic vertebral collapse in whom conservative treatment have failed should be considered as ideal candidates for vertebroplasty, irrespective of neurological deficit or radicular pain, and should be referred for it as early as possible.<sup>15</sup> An early intervention gives good results for pain relief and prevents progressive kyphosis and its sequelae.<sup>16</sup> Careful selection of patients is necessary for successful results of vertebroplasty.<sup>13</sup> Patient with midline pain with loading of spine and relief with recumbency will have better result. It has been observed that patients with axial pain are more likely to be benefited than patients with radicular pain, as the latter is due to nerve compression. Patients afflicted with vertebral collapse fracture with bone marrow edema or fluid cleft in MRI, suggestive of Kummell's disease (nonunion with osteonecrosis), are good candidates for vertebroplasty.<sup>17</sup> We did not consider paravertebral muscle mass or atrophy in predicting postvertebroplasty outcome.

Previously, it was thought that unipedicular vertebroplasty may lead to fracture in adjacent vertebra due to inadequate correction. However, recent studies show that results are same both for unipedicular and bipedicular vertebroplasty.<sup>13,18</sup>

In the present study, both unipedicular and bipedicular vertebroplasty groups achieved satisfactory outcome in the form of VAS scores for pain relief when compared with preprocedural scores. As procedure time for unipedicular vertebroplasty is less compared with bipedicular vertebroplasty, it results in reduction in radiation exposure in unipedicular vertebroplasty.<sup>13,18</sup>

Thus, unipedicular approach is less time-consuming, reduces the radiation exposure and can be employed for multilevel involvement of vertebral collapse. Also, with unipedicular vertebroplasty, complications are less compared

with bipedicular vertebroplasty with similar clinical outcome.<sup>19</sup>

The limitations of our study include relatively small sample size, with follow-up restricted to 24 hours postprocedure. Other limitations include lack of comparison among different vertebral segments and no comparison done between vertebroplasty and kyphoplasty.

## Conclusion

Unipedicular vertebroplasty is as effective as bipedicular vertebroplasty when compared with postprocedure pain relief assessed by VAS. Unipedicular vertebroplasty can be preferred approach over bipedicular vertebroplasty for vertebral compression fractures, as it is less traumatic, less time-consuming with resultant decrease in radiation exposure, and less complications compared with bipedicular vertebroplasty.

### Funding Source

None.

### Conflict of Interest

None declared.

## References

- Panda A, Das CJ, Baruah U. Imaging of vertebral fractures. *Indian J Endocrinol Metab* 2014;18(03):295–303
- World Health Organization. Prevention and management of osteoporosis. *World Health Organ Tech Rep Ser* 2003; 921:1–164
- Marwaha RK, Tandon N, Gupta Y, et al. The prevalence of and risk factors for radiographic vertebral fractures in older Indian women and men: Delhi Vertebral Osteoporosis Study (DeVOS). *Arch Osteoporos* 2012;7(1–2):201–207
- Baur-Melnyk A. Malignant versus benign vertebral collapse: are new imaging techniques useful? *Cancer Imaging* 2009;9 Spec No A(Special issue A):S49–S51
- Coleman RE. Skeletal complications of malignancy. *Cancer* 1997; 80(8, Suppl):1588–1594
- Porter BA, Shields AF, Olson DO. Magnetic resonance imaging of bone marrow disorders. *Radiol Clin North Am* 1986;24(02): 269–289
- Mauch JT, Carr CM, Cloft H, Diehn FE. Review of the imaging features of benign osteoporotic and malignant vertebral compression fractures. *AJNR Am J Neuroradiol* 2018;39(09): 1584–1592
- Khurana B, Sheehan SE, Sodickson A, Bono CM, Harris MB. Traumatic thoracolumbar spine injuries: what the spine surgeon wants to know. *Radiographics* 2013;33(07):2031–2046
- Nairn RJ, Binkhamis S, Sheikh A. Current perspectives on percutaneous vertebroplasty: current evidence/controversies, patient selection and assessment, and technique and complications. *Radiol Res Pract* 2011;2011:175079
- Galibert P, Deramond H, Rosat P, Le Gars D. [Preliminary note on the treatment of vertebral angioma by percutaneous acrylic vertebroplasty]. *Neurochirurgie* 1987;33(02):166–168
- Jensen ME, Evans AJ, Mathis JM, Kallmes DF, Cloft HJ, Dion JE. Percutaneous polymethylmethacrylate vertebroplasty in the treatment of osteoporotic vertebral body compression fractures: technical aspects. *AJNR Am J Neuroradiol* 1997;18(10): 1897–1904

- 12 Mathis JM, Barr JD, Belkoff SM, Barr MS, Jensen ME, Deramond H. Percutaneous vertebroplasty: a developing standard of care for vertebral compression fractures. *AJNR Am J Neuroradiol* 2001;22(02):373–381
- 13 Zhang L, Liu Z, Wang J, et al. Unipedicular versus bipedicular percutaneous vertebroplasty for osteoporotic vertebral compression fractures: a prospective randomized study. *BMC Musculoskelet Disord* 2015;16(01):145
- 14 Truumees E, Hilibrand A, Vaccaro AR. Percutaneous vertebral augmentation. *Spine J* 2004;4(02):218–229
- 15 Klazen CA, Lohle PN, de Vries J, et al. Vertebroplasty versus conservative treatment in acute osteoporotic vertebral compression fractures (Vertos II): an open-label randomised trial. *Lancet* 2010;376(9746):1085–1092
- 16 Cotten A, Boutry N, Cortet B, et al. Percutaneous vertebroplasty: state of the art. *Radiographics* 1998;18(02):311–320, discussion 320–323
- 17 Jensen ME, Dion JE. Percutaneous vertebroplasty in the treatment of osteoporotic compression fractures. *Neuroimaging Clin N Am* 2000;10(03):547–568
- 18 Song BK, Eun JP, Oh YM. Clinical and radiological comparison of unipedicular versus bipedicular balloon kyphoplasty for the treatment of vertebral compression fractures. *Osteoporos Int* 2009;20(10):1717–1723
- 19 Chen C, Bian J, Zhang W, Zhang W, Zhao C, Wei H. Unilateral versus bilateral vertebroplasty for severe osteoporotic vertebral compression fractures. *J Spinal Disord Tech* 2014;27(08):E301–E304