Article published online: 2022-09-05

New Technique Seeking Prophylaxis in the Displacement of Distal Ventriculoperitoneal Shunt Catheter – Case Report

Nova técnica buscando profilaxia no desacoplamento do cateter distal de derivação ventriculoperitoneal – Relato de caso

João Victor Oliveira de Melo[1] Rebeca Brasil da Silva[1] Franklin Reis[1,2] Robson Luís Oliveira de Amorim[1,3]

[1] Clinical Surgery Department, School of Medicine, Universidade Federal do Amazonas, Manaus, AM, Brazil
[2] Clinical Surgery Department, Faculdade Metropolitana de Manaus, Manaus, AM, Brazil
[3] Division of Neurosurgery, Hospital das Clínicas, Universidade de São Paulo, São Paulo, Brazil

Address for correspondence João Victor Oliveira de Melo, undergraduate student, School of Medicine, Federal University of Amazonas (UFAM), – Rua Conde de Anadia, N23, Cond. Residencial Miami Park, 69054718 Manaus, Brasil (e-mail: jvictor71@yahoo.com.br).

Arq Bras Neurocir 2023;42(1):e85–e88.

Abstract

Idiopathic intracranial hypertension is a comorbidity treated in neurosurgical practice today with the ventriculoperitoneal derivation technique. However, despite its great safety and efficacy, this technique is susceptible to infrequent failures, such as displacement of the catheter leading to the need for reoperation. In the present article, we report a case involving a peritoneal catheter tip retropulsion for subcutaneous tissue in an obese patient with posterior correction using an extending connector to the distal catheter, without harming the drainage flow. In our case report, the patient went on without complications and without the occurrence of new displacement after 8 months of surgery. The results obtained by this technique supported the idea that this alternative construction minimizes the risk of displacement of the peritoneal tip catheter in obese patients and with high intra-abdominal pressure, helping to reduce the need for reoperations. In addition, the present case report supports the need for further studies and clinical trials on the subject.

Keywords
- ventriculoperitoneal shunt
- catheter displacement
- shunt complication

received March 25, 2021
accepted September 6, 2021

DOI https://doi.org/10.1055/s-0041-1740164.
ISSN 0103-5355.

© 2022. Sociedade Brasileira de Neurocirurgia. All rights reserved.
This is an open access article published by Thieme under the terms of the Creative Commons Attribution-NonDerivative-NonCommercial-License, permitting copying and reproduction so long as the original work is given appropriate credit. Contents may not be used for commercial purposes, or adapted, remixed, transformed or built upon. (https://creativecommons.org/licenses/by-nc-nd/4.0/)
Thieme Revinter Publicações Ltda., Rua do Matoso 170, Rio de Janeiro, RJ, CEP 20270-135, Brazil

Resumo

A hipertensão intracraniana idiopática é uma comorbidade tratada na prática neurocirúrgica usualmente com técnica de derivação ventriculoperitoneal. No entanto, apesar de sua grande segurança e eficácia, a técnica é sujeita a falhas, pouco frequentes, como o desacoplamento do cateter, levando à necessidade de reoperação. Relatamos, no presente artigo, um caso de correção cirúrgica a partir de prolongamento do cateter distal com a utilização de conector extensor sem prejuízo ao fluxo de drenagem em paciente obeso acometido por recidiva de migração da ponta do cateter peritoneal para o tecido subcutâneo. Em nosso relato de caso, o paciente seguiu sem complicações e sem a ocorrência de novos desacoplamentos após 8 meses do ato operatório. Os resultados obtidos pelo estudo corroboram a necessidade de maiores investigações buscando o conhecimento da eficácia e segurança da técnica empregada buscando minimizar os riscos de migração da ponta do cateter peritoneal em pacientes obesos e de elevada pressão intra-abdominal, ajudando a diminuir a necessidade de reoperações.

Palavras-chave
- derivação ventriculoperitoneal
- migração de cateter
- complicação da derivação

Introduction

The ventriculoperitoneal shunt method is commonly used in neurosurgical practice for the treatment of comorbidities related to the production or drainage of cerebrospinal fluid, being recognized since the appearance of the first valves removed for this purpose in 1950 by Holtes and Spitz.[1] It is commonly used for the treatment of idiopathic intracranial hypertension.[2] However, despite their considerable effectiveness, these devices are often plagued by mechanical and functional failures.

These complications, which commonly occur in the shunt distal catheter, are caused by mechanical failures, bacterial infections, and displacements with extrusion of the peritoneal connection to the subcutaneous tissue.[3]

In the present report, we present a recent case of an obese patient with migration of the tip of the distal catheter to the abdominal subcutaneous adipose tissue, requiring two sequential surgical reviews. After using and failing conventional practices of sutural repositioning and anchoring, we used the experimental technical application of coupling and extension of the distal catheter from the connector to a second catheter. The technique apparently proved to be efficient in the search for reducing the complications related to it is displacement without compromising the possibility of subsequent surgical revision of different needs.

Methodology for Literature Review

The information and references contained in the review of the present article were obtained through research on a search platform, using the SciELO, PubMed, and Up to Date databases looking for more recent data on the topic.

The keywords and search strategies, used to review the topic Pseudotumor cerebri and looking for historical precedents similar to the case presented, were: *pseudotumor* AND *cerebri*, *ventriculoperitoneal* AND *shunt* AND *obese*. It was also used to collect updated information a time limit for works produced in the past 5 years.

Case Report

Female patient, 52 years old, body mass index (BMI) = 45.88 (1.52 cm and 106 kg). Initially admitted with a clinical condition of holocranial headache, presenting the upper limit on the numerical rating scale (NRS), claiming to be the worst pain of her life, persistent, without symptomatic relief with the use of analgesics and progressive for 7 days, along with nausea and emesis. On clinical examination, the patient presented papilledema. In imaging studies, it did not show any significant radiological alterations or something that justified the current clinical alterations. For diagnostic confirmation, a tap test was performed with the use of a digital spinal manometer with an opening pressure of 15 mmHg and with symptomatic relief after removal of 30 ml of cerebrospinal fluid, leading to the diagnostic confirmation of idiopathic intracranial hypertension (IIH).

First, the patient follows the clinical management with acetazolamide, a carbonic anhydrase inhibitor commonly used in the treatment of IIH; however, after using the drug in the ideal dose, the patient did not show any clinical improvement; therefore, surgical intervention was chosen.

Ventriculoperitoneal shunt (VPS) was performed using the stereotaxic method, without complications of the surgical procedure, just with the presence of only ~ 11 cm of the distal catheter in the intraperitoneal region. Along with the clinical improvement of the previous symptoms of the patient, it was observed relief in the immediate postoperative period, and she was discharged 2 days after the surgery.

Seven days after the surgery, the patient returned to medical care with abdominal pain. For the investigation, an ultrasound of the abdomen was performed, in which a liquid collection was found in the subcutaneous tissue with extrusion of the distal catheter from the intraperitoneal region – with its displacement to the subcutaneous region, causing dissection of the abdominal subcutaneous mesh and, therefore, pain.

The distal catheter was repositioned using anchoring techniques. However, after 5 days, the patient returned to

 © 2022. Sociedade Brasileira de Neurocirurgia. All rights reserved.

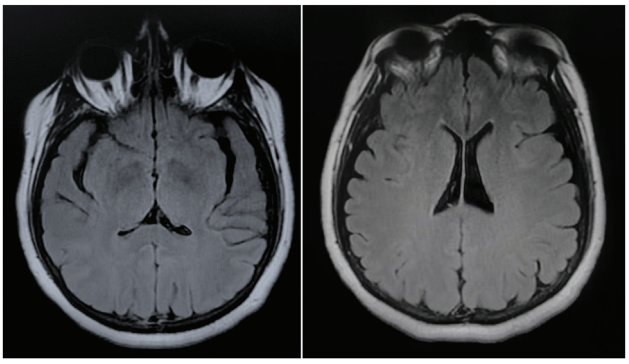

Fig. 1 FLAIR-weighted nuclear magnetic resonance imaging showing unaltered ventricular system and brain parenchyma evidencing the absence of hydrocephalus and indicating idiopathic intracranial hypertension.

Fig. 2 T-connector used to set and extend the distal tip of the ventricle peritoneal shunt system catheter to prevent displacement: (A) receives the first catheter from the shunt. (B) This end of the connector remains closed. (C) The tip that receives the peritoneal catheter.

medical care, presenting with recurrence of abdominal pain similar to the previous one.

Due to the persistence of the case, it was decided to order a second distal catheter from the VPS along with an appropriate connector for catheters. As operative technique, the connection of two distal catheters connected from the connector was chosen in order to obtain a greater length of the catheter in the intraperitoneal region. No changes were made to the proximal catheter.

Today, 8 months after the last surgery, the patient presents complete improvement of the signs and symptoms of both cephalic issues and abdominal pain.

Discussion

Peritoneal complications of VPS are previously known and widely exposed, being described in the literature with the need for surgical revision of the distal tip of the peritoneal catheter due to displacement in $\sim$ 50% of cases.[4] Obesity is considered an independent risk factor for migration of the distal catheter (odds ratio = 6.38, 95% confidence interval [CI] = 1.16–35.21; $p = 0.033$).[5]

However, this correlation is not yet fully physiopathologically elucidated, but it is believed that the increase of intra-abdominal pressure is one of the causes responsible for the susceptibility to displacement. It is important to highlight the direct linear relationship between the increase in BMI and the increase in intra-abdominal pressure ($r = 0.52$; $p = 0.018$) with a deviation of 0.31 ($p = 0.001$).[6] The sum of these relationships is notable when the epidemiological correlation between this complication and the incidence in obese patients is noticeable.[7] The interaction of the hydrophilic characteristics of the catheter, which, on one hand, helps to reduce scar fibrosis, but makes it more susceptible to uncoupling, is also significant.[8]

The results obtained with the process of extending the distal catheter through a connected connector are favorable to the belief that this technique is opportune in preventing migration of the tip of the peritoneal catheter in the case of obese patients, with great thickness of the subcutaneous adipose panicle and increased intra-abdominal pressure.

The technique is interesting because it does not require changes in the size of the standard incision, and it does not compromise the opportunity for subsequent surgical revision, a difficulty found in the subcutaneous anchoring techniques. However, despite the success achieved by the team, it is important to note that, the technique does not change the difficulties generated by the low coefficient of friction between the catheter and the adipose tissue, requiring more case studies to confirm its widespread efficacy.

In our research, we found two case reports also describing alternative techniques for the resolution of recurrence of displacement of the peritoneal catheter. However, none of the narrated techniques fully resembles the one used in the present case. Morrison et al reported a method performed on three patients using synthetic mesh for hernias to increase the friction of the catheter and prevent its retropulsion.[1] In 2017, Carnevale et al. detailed the procedure performed, successfully, with modification using the T connector[8]

Conclusions

The present study supports the use of the distal catheter extension technique with the use of a connector and complement of two continuous tubes aiming to prophylactically reduce the incidence of extrusion of the peritoneal tip for patients with high BMI. The results of the study support the need for further investigation seeking knowledge of the effectiveness and safety of the technique employed.

Funding
The present work and its authors did not receive any form of external funding.

Conflict of Interests
The authors have no conflict of interests to declare.

References

1 Morrison JF, Sung KE, Bergman AM, Rosenblatt MS, Arle JE. A novel solution to reduce the complications of distal shunt catheter displacement associated with obesity. J Neurosurg 2010;113 (06):1314–1316. Doi: 10.3171/2010.6.JNS10300

 © 2022. Sociedade Brasileira de Neurocirurgia. All rights reserved.

2 Balakrishnan V, Jeanmonod R. Two episodes of ventriculoperitoneal shunt migration in a patient with idiopathic intracranial hypertension. Case Rep Emerg Med 2014;2014:280793. Doi: 10.1155/2014/280793
3 Aquino HBDE. Complicações abdominais do cateter distal no tratamento da hidrocefalia com migração, perfuração e/ou extrusão: uma hipótese inflamatória [dissertation]. Campinas (SP): Universidade Estadual de Campinas. Faculdade de Ciências Médica; 2004
4 Chung JJ, Yu JS, Kim JH, Nam SJ, Kim MJ. Intraabdominal complications secondary to ventriculoperitoneal shunts: CT findings and review of the literature. AJR Am J Roentgenol 2009;193(05):1311–1317. Doi: 10.2214/AJR.09.2463
5 Abode-Iyamah KO, Khanna R, Rasmussen ZD, et al. Risk factors associated with distal catheter migration following ventriculoperitoneal shunt placement. J Clin Neurosci 2016;25(12):46–49. Doi: 10.1016/j.jocn.2015.07.022
6 Sahuquillo J, Arikan F, Poca MA, Noguer M, Martinez-Ricarte F. Intra-abdominal pressure: the neglected variable in selecting the ventriculoperitoneal shunt for treating hydrocephalus. Neurosurgery 2008;62(01):143–149, discussion 149–150. Doi: 10.1227/01.NEU.0000311071.33615.E1
7 Lee AG, Wall M. Idiopathic intracranial hypertension (pseudotumor cerebri): Epidemiology and pathogenesis. 2020 UpToDate. Published online 2020:496–497. Avaible from: https://www.uptodate.com/contents/idiopathic-intracranial-hypertension-pseudotumor-cerebri-epidemiology-and-pathogenesis/print
8 Carnevale JA, Ahmedli N, Morrison JF, Asaad WF, Klinge P, Telfeian A. T-connector modification for reducing recurrent distal shunt failure: Report of 2 cases. Oper Neurosurg (Hagerstown) 2017;13(06):E33–E36. Doi: 10.1093/ons/opx050

 © 2022. Sociedade Brasileira de Neurocirurgia. All rights reserved.