



# Prevalence of Heterotopic Ossification after Cervical Disk Arthroplasty at 5 Years

## *Prevalencia de la osificación heterotópica tras artroplastia de disco cervical a los 5 años*

Ivan A. Stepanov<sup>1</sup>  Vladimir A. Beloborodov<sup>1</sup>

<sup>1</sup>Department of General Surgery and Anesthesiology, Irkutsk State Medical University, Irkutsk, Russia

Address for correspondence Ivan A. Stepanov, MD, 1 Krasnogo Vosstaniya Str., 664003, Irkutsk, Irkutskaya Oblast', Russia (e-mail: stepanovivanneuro@gmail.com).

Rev Chil Ortop Traumatol 2021;62(3):e174–e179.

### Abstract

**Introduction** In recent years, cervical disk arthroplasty (CDA) has become widely used in patients as a substitute to anterior cervical discectomy and fusion (ACDF). However, heterotopic ossification (HO) and spontaneous fusion after CDA have been reported, and maintenance of motion following arthroplasty can be hindered by the development of HO.

**Materials and Methods** The CDA procedure with Activ C and M6-C prostheses was performed on 127 patients. The mean follow-up time was of 58.4 months, ranging from 51 to 66 months.

**Results** Grade-1 ossifications were present in 11 (8.6%) levels. A total of 45 (35.4%) segments showed grade-2 HO. Cases of HO that led to restrictions in the range of motion were present in 13 (10.2%) patients. Five year postoperatively, there were only 9 (7.0%) patients with grade-4 ossifications in the M6-C artificial disk prosthesis group. In the survival analysis after HO occurrence, the median survival of the patients was of  $28.3 \pm 5.6$  months. The Activ C artificial disk prosthesis group had a statistically longer survival ( $49.5 \pm 7.8$  months) than the M6-C disk group.

**Conclusion** In the present study, 61.4% of the patients developed HO at a mean follow-up period of 58.4 months. In the survival analysis after HO occurrence, the median survival of the patients was of  $28.3 \pm 5.6$  months. The Activ C artificial disk prosthesis group had a statistically longer survival ( $49.5 \pm 7.8$  months) than the M6-C disk group.

### Keywords

- ▶ anterior cervical discectomy and fusion
- ▶ cervical disk arthroplasty
- ▶ heterotopic ossification
- ▶ prevalence
- ▶ activ C prosthesis
- ▶ M6-C prosthesis

received  
June 3, 2020  
accepted  
August 6, 2021

DOI <https://doi.org/10.1055/s-0041-1740171>.  
ISSN 0716-4548.

© 2021. Sociedad Chilena de Ortopedia y Traumatología. All rights reserved.

This is an open access article published by Thieme under the terms of the Creative Commons Attribution-NonDerivative-NonCommercial-License, permitting copying and reproduction so long as the original work is given appropriate credit. Contents may not be used for commercial purposes, or adapted, remixed, transformed or built upon. (<https://creativecommons.org/licenses/by-nc-nd/4.0/>)

Thieme Revinter Publicações Ltda., Rua do Matoso 170, Rio de Janeiro, RJ, CEP 20270-135, Brazil

## Resumen

**Introducción** En los últimos años, la artroplastia de disco cervical (ADC) se ha utilizado ampliamente en pacientes como alternativa a la disectomía y fusión cervical anterior (DFCA). Sin embargo, se han informado osificación heterotópica (OH) y fusión espontánea después de ADCs, y el desarrollo de OH puede dificultar el mantenimiento de movimiento después de la artroplastia.

**Materiales y Métodos** El procedimiento ADC con prótesis Activ C y M6-C se realizó en 127 pacientes. El tiempo medio de seguimiento fue de 58.4 meses, con un rango de 51 a 66 meses.

**Resultados** Las osificaciones de grado 1 estuvieron presentes en 11 niveles (8,6%). Un total de 45 (35,4%) segmentos eran de OH de grado 2. Las OHs que produjeron restricciones del rango de movimiento estuvieron presentes en 13 (10,2%) casos. A los 5 años de seguimiento, sólo había 9 (7,0%) pacientes con osificación de grado 4 en el grupo de prótesis de disco artificial M6-C. En el análisis de la supervivencia tras la ocurrencia de OH, la mediana de los pacientes fue de  $28,3 \pm 5,6$  meses. El grupo de prótesis de disco artificial Activ C tuvo una supervivencia estadísticamente más larga ( $49,5 \pm 7,8$  meses) que el grupo de disco M6-C.

**Conclusiones** En este estudio, el 61,4% de los pacientes desarrollaron OH en un período de seguimiento medio de 58,4 meses. En el análisis de la supervivencia tras la ocurrencia de OH, la mediana de los pacientes fue de  $28,3 \pm 5,6$  meses. El grupo de prótesis de disco artificial Activ C tuvo una supervivencia estadísticamente más larga ( $49,5 \pm 7,8$  meses) que el grupo de disco M6-C.

### Palabras Clave

- ▶ disectomía y fusión cervical anterior
- ▶ artroplastia de disco cervical
- ▶ osificación heterotópica
- ▶ prevalencia
- ▶ prótesis Activ C
- ▶ prótesis M6-C

## Introduction

Anterior cervical discectomy and fusion (ACDF) is the golden standard for the surgical treatment of cervical degenerative disk disease with a long-term clinical success.<sup>1,2</sup> In recent years, cervical disk arthroplasty (CDA) has become widely used in patients as a substitute for ACDF.<sup>3</sup> The introduction of CDA began with the concept of motion preservation to treat cervical disk degenerative disease. Motion preservation most closely mimics the natural motion of the cervical spine, and is believed to preserve the adjacent segments from degeneration over the long term compared with ACDF.<sup>4</sup> Randomized controlled trials<sup>5-7</sup> have reported good outcomes and high levels of patient satisfaction after CDA.

However, heterotopic ossification (HO) and spontaneous fusion after CDA have been reported,<sup>8</sup> and maintenance of motion following arthroplasty can be hindered by the development of HO, which is defined as the formation of the bone outside the skeletal system. It is a well-known phenomenon in the field of total hip or knee joint arthroplasty that hinders the activity of patients after surgery.<sup>9</sup> McAfee et al.<sup>10</sup> have already described and classified the phenomenon of HO for lumbar total disk arthroplasty. The rate of HO following CDA is unclear, because the reported rates vary drastically, creating more debate and concern around the true rate and impact of HO. The long-term effects of HO resulting in unintended fusion have not been sufficiently studied.

The purpose of the present study was to evaluate the prevalence of HO and to conduct a survival analysis after HO onset among patients after cervical disk arthroplasty at 5 years follow-up.

## Methods

### Patient Population

The CDA procedure with the Activ C (B. Braun, Sheffield, UK) and M6-C (Spinal Kinetics, Sunnyvale, CA, US) prostheses was performed on 127 patients, including 65 (51.1%) women and 62 (48.8%) men who had symptomatic cervical disk degenerative disease that was unresponsive to the conservative treatment from January 2009 to June 2011. The patients were younger than 50 years, with a mean age of 38.4 (range: 18–49) years.

### Eligibility Criteria and Follow-up

The inclusion criterion was symptomatic cervical disk herniation at the levels from C3-C4 to C6-C7 with preserved mobility ( $> 3^\circ$  and  $< 11^\circ$ ) within the affected segment. The exclusion criteria were trauma, kyphotic deformity, ossification of the posterior longitudinal ligament, or instability of the cervical spine. Advanced osteoporosis, rheumatoid arthritis, and ankylosing spondylitis (Bekhterev disease) were also exclusion criteria. The mean follow-up was of 58.4 months, ranging from 51 to 66 months. The study protocol was approved by the local ethics committee following the Declaration of Helsinki.<sup>11</sup>

### Surgical Procedure

After a standard microsurgical anterior Cloward approach, the midline was marked under fluoroscopic control. Discectomy and decompression were performed, and the segment was distracted and held in distraction by retaining screws. After testing the height and width of the intervertebral disk by fluoroscopy, the appropriate prosthesis was implanted.

The patients were asked to get off the bed 24 hours later. Wearing a neck collar was required for no longer than one week.

### Clinical Assessment

The clinical outcomes of the patients included the scores on the Neck Disability Index (NDI) and the Visual Analogue Scale (VAS) neck/arm pain, and the Physical Component Score (PCS)/Mental Component Score (MCS) of the Short (12) Form (SF-12) health survey.

### Radiological Assessment

Lateral cervical radiographs obtained at scheduled time points before and after surgery were used to identify HO (►Fig. 1). In some cases, HO was confirmed using computed tomography (CT) (►Fig. 2). The cases of HO were classified according to the McAfee et al.<sup>10</sup> classification. The rate of occurrence, the occurrence-free period, the location, and the grade of the cases of HO were investigated according to the different types of prosthesis. The behavior of the HO was observed by two independent spine surgeons.

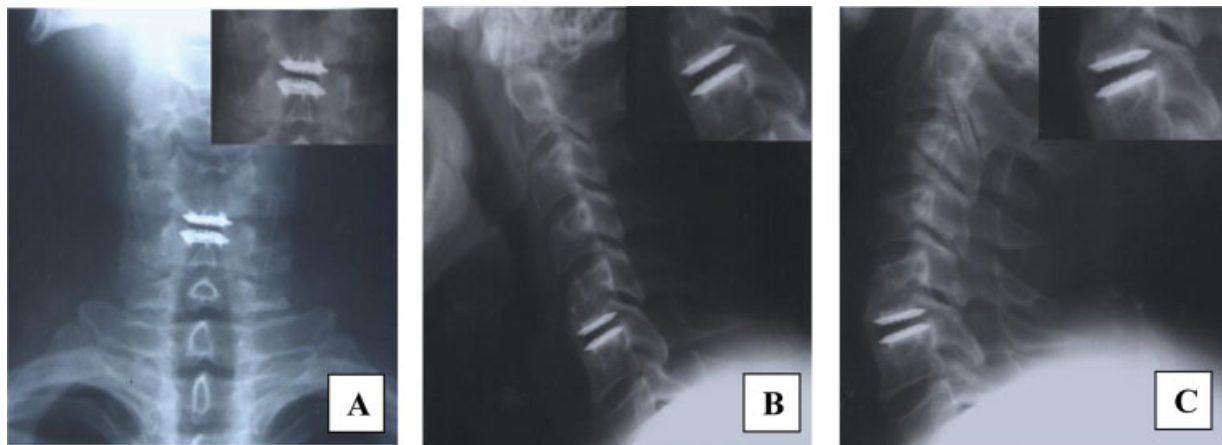
### Statistical Analysis

Data analyses were conducted using the Microsoft Office Excel 2016 (Microsoft Corp., Redmond, WA, US) and the Statistical Package for the Social Sciences (IBM SPSS Statistics for Windows, IBM Corp., Armonk, NY, US), version 21.0. A significance level of 0.05 was adopted for all tests. The statistical analysis was performed using *t*-tests and Wilcoxon tests.

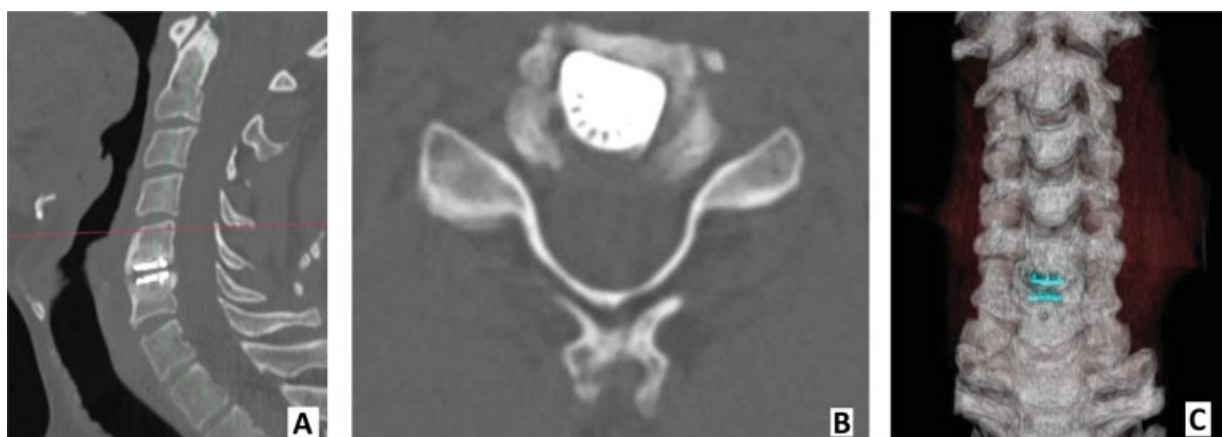### Results

The baseline characteristics and scores of the patients were sorted into clinically relevant and nonrelevant HO present at 5 years (►Table 1). These results were categorized to evaluate for trends; therefore, statistics were not run on these data.

In 49 (38.5%) treated segments, no HO was detectable. Grade-1 ossifications were present in 11 (8.6%) levels. A total of 45 (35.4%) segments showed grade-2 HO. There were 13 (10.2%) cases of HO that led to restrictions in the range of motion. Five-year postoperatively, only 9 (7.0%) patients



**Fig. 1** A 41-year-old male patient with C5-C6 intervertebral disk degenerative disease treated by the CDA procedure. Clear signs of grade-III HO can be observed, with no significant reduction in motion of the prosthesis in flexion and extension at the 5-year follow-up: (A) frontal radiograph; (B) lateral radiograph in flexion; (C) – lateral radiograph in extension.



**Fig. 2** Computed tomography (CT) scans of grade-III HO (previous clinical case): (A) sagittal CT scan; (B) axial CT scan; (C) three-dimensional CT scan.

**Table 1** Baseline characteristics of the patients with low- and high-grade HO 5 years after CDA

	Low-grade HO group (n = 56)	High-grade HO group (n = 22)	p
Mean age (years)	39.2 ± 7.3	38.6 ± 6.6	0.81
Female gender: n (%)	11 (19.6%)	16 (72.2%)	0.07
Height (cm)	173.5 ± 11.3	175.5 ± 11.2	0.26
Weight (kg)	75.2 ± 10.8	79.3 ± 17.4	0.08
Body Mass Index*	25.4 ± 2.5	25.7 ± 3.8	0.74
Neck Disability Index	17.9	19.9	0.17
Visual Analog Scale for neck pain	19.2	21.1	0.37
Visual Analog Scale for arm pain	15.4	16.9	0.44
SF-12: PCS	46.8	45.3	0.27
SF-12: MCS	50.5	50.2	0.96
Level C5-C6 operated: n (%)	16 (28.5%)	12 (54.5%)	0.19

Abbreviations: CDA, cervical disk arthroplasty; HO, heterotopic ossification; PCS, physical component score; MCS, mental component score; SF-12, Short Form (12) health survey  
 Note: \*The body mass index is the weight in kilograms divided by the square of the height in meters.

with grade-4 ossifications were found in the M6-C artificial disk prosthesis group.

As for location, anterior ossifications were more frequent than posterior ossifications, but the difficulty in the detection of posterior ossifications using plain radiographs should be considered. The distribution of the different grades of HO according to the prosthesis type are shown in ► **Table 2**.

In the survival analysis after HO onset, the median survival of the patients was of 28.3 ± 5.6 months. The Activ C artificial disk prosthesis group had a statistically longer

**Table 2** Distribution of the different grades of heterotopic ossification according to the type of prosthesis

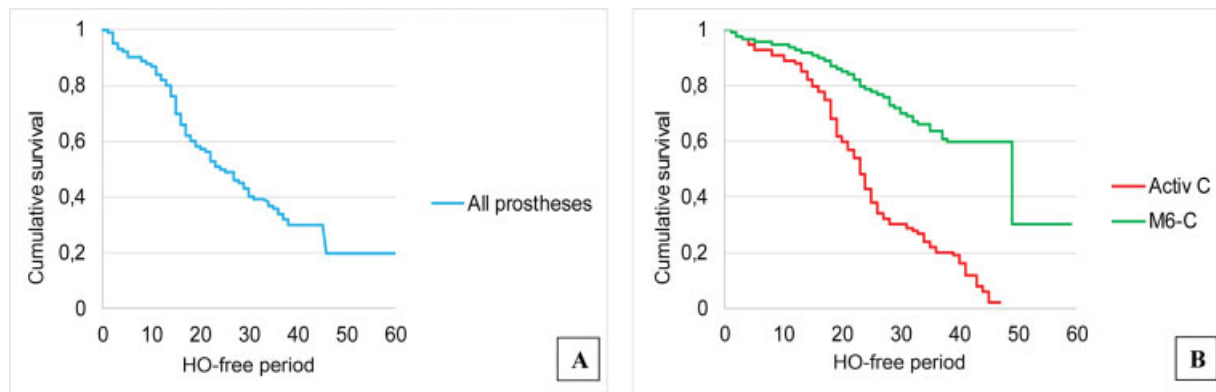
	Grade 1	Grade 2	Grade 3	Grade 4
Activ C	5 (3.9%)	27 (21.3%)	8 (6.3%)	7 (5.5%)
M6-C	6 (4.7%)	18 (14.1%)	5 (3.9%)	2 (1.5%)
All prostheses	11 (8.6%)	45 (35.4%)	13 (10.2%)	9 (7.0%)

survival (49.5 ± 7.8 months) than the M6-C disk group (p = 0.003) (► **Fig. 3**).

**Discussion**

It is common knowledge that the onset of HO is an inevitable postoperative complication after the CDA procedure, and it can decrease the range of motion of the operated segment, which goes against the fundamental goal of implanting an artificial disk.<sup>12,13</sup> Previous studies reported various results on the onset of HO. Lee et al.<sup>14</sup> reported that 78.6% of the patients exhibited HO at a mean follow-up period of 43.4 months, but Leung et al.<sup>15</sup> reported 17.8% of cases of HO at 12 months of follow-up. In the study conducted by Yang et al.,<sup>16</sup> the prevalence of HO was of up to 90%, but their results were based on a 30-year follow-up. In the present investigation, only 38.5% of the patients did not show any signs of HO after CDA. There is a hypothesis that HO is not a static, but rather a dynamic and progressive phenomenon that is affected by the environment.<sup>17</sup> If so, different lengths of follow-up would definitely affect the final results.

The factors associated with HO onset have not been clarified. Nunley et al.<sup>18</sup> showed that odds ratios indicated the follow-up visit, the male gender, and the preoperative score on the Visual Analogue Scale (VAS) for neck pain are related to HO onset, whereas hazard ratios indicated the male gender, obesity, endplate coverage, the levels treated, and the preoperative VAS score for neck pain. Yi et al.<sup>19</sup> found the differences in the onset of HO according to different types of prosthesis. The use of the Bryan Disk, which provides the most



**Fig. 3** Survival analysis of HO onset: (A) the median survival of the patients was of 28.3 ± 5.6 months; (B) the Activ C artificial disk prosthesis group had a statistically longer survival (49.5 ± 7.8 months) than the M6-C prosthesis group (p = 0.003).

unconstrained motion, resulted in a significantly lower incidence of HO onset in comparison with other prosthesis. The authors<sup>19</sup> proposed that differences in the design, biomechanical property, and prosthesis-specific endplate articulation component could contribute to the onset of HO. In the present study, the use of the M6-C prosthesis also resulted in a significantly lower incidence of HO in comparison with Activ C artificial disk. Park et al.<sup>20</sup> found that the surgical technique for the CDA influenced the development of HO. In this study, two spine surgeons performed all CDA procedures. However, they had different techniques for trimming endplates. One spine surgeon used a fluted ball-type burr, while the other used a diamond-type burr. The study showed that the use of the fluted ball-type burr resulted in a significantly higher incidence of HO.

Several other possible causal factors regarding HO have been discussed, such as not treating patients with nonsteroidal anti-inflammatory drugs (NSAIDs) after different surgical procedures. The use of NSAIDs to prevent HO after total hip replacement has been previously reported.<sup>21</sup> The study protocols of clinical trials for CDA undertaken by the US Food and Drug Administration (FDA) included the perioperative use of NSAIDs as an attempt to prevent the occurrence of HO. One study<sup>22</sup> has reported a trend toward decreased HO development in patients who used NSAIDs after CDA compared with those who did not, but the difference was not statistically significant. In the present investigation, NSAIDs were not used routinely, and further studies should assess the role of NSAIDs in the development of HO after the CDA procedure.

Other predisposing factors that have been discussed are age and gender. The male gender has previously been reported to correlate with HO formation,<sup>23</sup> and it could be a contributing factor regarding the observed difference in HO occurrence compared with other reports. However, the present male/female ratio was not much different from that of the other studies. There was no relationship between high- and low-grade HO and age or gender in the present study.

## Limitations

The limitations of the present study are that only two types of artificial disk were investigated, and that the sample was relatively small. Moreover, in the present investigation, the determination of cases of HO was standardized only using the McAfee et al.<sup>10</sup> classification.

## Conclusion

In the present study, 61.4% of the patients developed HO at a mean follow-up of 58.4 months. In the survival analysis of HO onset, the median survival of the patients was of  $28.3 \pm 5.6$  months. The Activ C artificial disk prosthesis group had a statistically longer survival ( $49.5 \pm 7.8$  months) than the M6-C disk group. This information is useful to enable surgeons and patients to gain a better understanding of HO during follow-up. Randomized controlled trials with even longer

follow-ups are needed for more definitive answers concerning HO onset, the factors associated with it, and its impact on mobility as well as on the clinical outcome.

### Ethical Approval

Institutional review board approval was obtained by the ethics committee at Irkutsk State Medical University (2013–51/5).

### Funding

The authors have no sources of funding to declare.

### Conflict of Interests

The authors have no conflict of interests to declare.

### Acknowledgments

The authors would like to thank the staff of the Department of General Surgery and Anesthesiology at Irkutsk State Medical University for their support.

## References

- Ofluoglu AE, Erdogan U, Aydogan M, Cevik OM, Ofluoglu O. Anterior cervical fusion with interbody cage containing beta-tricalcium phosphate: Clinical and radiological results. *Acta Orthop Traumatol Turc* 2017;51(03):197–200. Doi: 10.1016/j.aott.2017.03.001
- Wang T, Wang H, Liu S, An HD, Liu H, Ding WY. Anterior cervical discectomy and fusion versus anterior cervical corpectomy and fusion in multilevel cervical spondylotic myelopathy: A meta-analysis. *Medicine (Baltimore)* 2016;95(49):e5437. Doi: 10.1097/md.00000000000012618
- Byvaltsev VA, Stepanov IA, Riew DK. Mid-term to long-term outcomes after total cervical disk arthroplasty compared with Anterior discectomy and fusion: a systematic review and meta-analysis of randomized controlled trials. *Clin Spine Surg* 2020;33(05):192–200. Doi: 10.1097/BSD.0000000000000929
- Skeppholm M, Svedmark P, Noz ME, Maguire GQ Jr, Olivecrona H, Olerud C. Evaluation of mobility and stability in the Discover artificial disc: an in vivo motion study using high-accuracy 3D CT data. *J Neurosurg Spine* 2015;23(03):383–389. Doi: 10.3171/2014.12.spine14813
- Gornet MF, Lanman TH, Burkus JK, et al. Cervical disc arthroplasty with the Prestige LP disc versus anterior cervical discectomy and fusion, at 2 levels: results of a prospective, multicenter randomized controlled clinical trial at 24 months. *J Neurosurg Spine* 2017;26(06):653–667. Doi: 10.3171/2016.10.spine16264
- Rožanković M, Marasanov SM, Vukić M Cervical Disk Replacement With Discover Versus Fusion in a Single-Level Cervical Disk Disease: A Prospective Single-Center Randomized Trial With a Minimum 2-Year Follow-up. *Clin Spine Surg* 2017;30(05):E515–E522. Doi: 10.1097/bsd.0000000000000170
- Sundseth J, Fredrikli OA, Kolstad F, et al; NORCAT study group. The Norwegian Cervical Arthroplasty Trial (NORCAT): 2-year clinical outcome after single-level cervical arthroplasty versus fusion—a prospective, single-blinded, randomized, controlled multicenter study. *Eur Spine J* 2017;26(04):1225–1235. Doi: 10.1007/s00586-016-4922-5
- Zeng J, Liu H, Chen H, et al. Comparison of Heterotopic Ossification After Fixed- and Mobile-Core Cervical Disc Arthroplasty. *World Neurosurg* 2018;120:e1319–e1324. Doi: 10.1016/j.wneu.2018.09.075



- 9 Arnold PM, Anderson KK, Selim A, Dryer RF, Kenneth Burkus J. Heterotopic ossification following single-level anterior cervical discectomy and fusion: results from the prospective, multicenter, historically controlled trial comparing allograft to an optimized dose of rhBMP-2. *J Neurosurg Spine* 2016;25(03):292–302. Doi: 10.3171/2016.1.spine15798
- 10 McAfee PC, Cunningham BW, Devine J, Williams E, Yu-Yahiro J. Classification of heterotopic ossification (HO) in artificial disk replacement. *J Spinal Disord Tech* 2003;16(04):384–389
- 11 Williams JR. The Declaration of Helsinki and public health. *Bull World Health Organ* 2008;86(08):650–652
- 12 Tu TH, Wu JC, Huang WC, et al. Heterotopic ossification after cervical total disc replacement: determination by CT and effects on clinical outcomes. *J Neurosurg Spine* 2011;14(04):457–465. Doi: 10.3171/2010.11.spine10444
- 13 Mehren C, Suchomel P, Grochulla F, et al. Heterotopic ossification in total cervical artificial disc replacement. *Spine* 2006;31(24):2802–2806. Doi: 10.1097/01.brs.0000245852.70594.d5
- 14 Lee SE, Jahng TA, Kim HJ. Correlation between cervical lordosis and adjacent segment pathology after anterior cervical spinal surgery. *Eur Spine J* 2015;24(12):2899–2909. Doi: 10.1007/s00586-015-4132-6
- 15 Leung C, Casey AT, Goffin J, et al. Clinical significance of heterotopic ossification in cervical disc replacement: a prospective multicenter clinical trial. *Neurosurgery* 2005;57(04):759–763, discussion 759–763. Doi: 10.1093/neurosurgery/57.4.759
- 16 Yang H, Lu X, Yuan W, Wang X, Chen D, Zhao D. Artificial disk replacement in the treatment of degenerative cervical disk disorder: a 30-year follow-up study. *Spine* 2014;39(19):1564–1571. Doi: 10.1097/brs.0000000000000484
- 17 Jin YJ, Park SB, Kim MJ, Kim K-J, Kim H-J. An analysis of heterotopic ossification in cervical disc arthroplasty: a novel morphologic classification of an ossified mass. *Spine J* 2013;13(04):408–420. Doi: 10.1016/j.spinee.2012.11.048
- 18 Nunley PD, Cavanaugh DA, Kerr EJ III, et al. Heterotopic Ossification After Cervical Total Disc Replacement at 7 Years-Prevalence, Progression, Clinical Implications, and Risk Factors. *Int J Spine Surg* 2018;12(03):352–361. Doi: 10.14444/5041
- 19 Yi S, Kim KN, Yang MS, et al. Difference in occurrence of heterotopic ossification according to prosthesis type in the cervical artificial disc replacement. *Spine* 2010;35(16):1556–1561. Doi: 10.1097/brs.0b013e3181c6526b
- 20 Park JH, Rhim SC, Roh SW. Mid-term follow-up of clinical and radiologic outcomes in cervical total disc replacement (Mobi-C): incidence of heterotopic ossification and risk factors. *J Spinal Disord Tech* 2013;26(03):141–145. Doi: 10.1097/BSD.0b013e31823ba071
- 21 Sodemann B, Persson PE, Nilsson OS. Prevention of heterotopic ossification by nonsteroid antiinflammatory drugs after total hip arthroplasty. *Clin Orthop Relat Res* 1988;(237):158–163
- 22 Tu TH, Wu JC, Huang WC, et al. Postoperative nonsteroidal antiinflammatory drugs and the prevention of heterotopic ossification after cervical arthroplasty: analysis using CT and a minimum 2-year follow-up. *J Neurosurg Spine* 2015;22(05):447–453. Doi: 10.3171/2014.10.spine14333
- 23 Yi S, Shin DA, Kim KN, et al. The predisposing factors for the heterotopic ossification after cervical artificial disc replacement. *Spine J* 2013;13(09):1048–1054. Doi: 10.1016/j.spinee.2013.02.036