



Comparative Analysis of the Treatment of Skin Lesions of the Lower Limbs with Sural Flap versus Propeller Flap*

Análise comparativa do tratamento de lesões cutâneas dos membros inferiores com retalho sural versus retalho propeller

Katherine V. Tenezaca¹ Gustavo Bersani Silva¹ Raquel Bernardelli lamaguchi¹
Marcelo Rosa de Rezende¹ Teng Hsiang Wei¹ Álvaro B. Cho¹

¹ Hand and Microsurgery Group, Instituto de Ortopedia e Traumatologia, Hospital das Clínicas da Faculdade de Medicina da Universidade de São Paulo (IOT-HCFMUSP), São Paulo, SP, Brazil

Address for correspondence Katherine V. Tenezaca, Intern of Hand and Microsurgery Group, Instituto de Ortopedia e Traumatologia do Hospital das Clínicas da IOT-HCFMUSP, Rua Ovídio Pires de Campos, 333, Cerqueira Cesar, São Paulo, SP, 05403-010, Brazil (e-mail: md.katherinetenezaca@gmail.com).

Rev Bras Ortop 2022;57(5):781–787.

Abstract

Objective The objective of the present study was to prospectively compare the sural and propeller flaps for soft-tissues coverage of the lower extremity. The following variables were evaluated: incidence of complete or partial flap loss and donor area morbidity (primary closure versus skin graft).

Methods Prospective and randomized analysis of data collected from all patients presenting with soft tissue defects of the lower third of the leg and heel treated with reverse sural or propeller flaps.

Results Twenty-four patients aged between 4 and 60 years old were evaluated between 2011 and 2017. Complete coverage was obtained in 22 of the 24 patients (91.6%). Two flaps failed (8.4%). The sural flap, being the most popular option, continues to represent a safe and versatile alternative for skin defects of the lower third of the leg and heel region. Likewise, the propeller flap was a comparable option to treat these challenging defects.

Conclusion Sural and propeller flaps are good options for soft tissues coverage of the lower extremity, with low complication rates (partial or total flap loss).

Keywords

- ▶ perforator flap
- ▶ surgical flaps
- ▶ transplant donor site

Resumo

Objetivo O objetivo do presente estudo foi comparar prospectivamente os retalhos sural e propeller para cobertura de partes moles da extremidade inferior. Foram

* Study developed at the Hand and Microsurgery Group of the Instituto de Ortopedia e Traumatologia do Hospital das Clínicas da Faculdade de Medicina da Universidade de São Paulo, São Paulo, SP, Brazil.

received
March 18, 2021
accepted after revision
August 13, 2021
published online
February 9, 2022

DOI <https://doi.org/10.1055/s-0041-1740199>.
ISSN 0102-3616.

© 2022. Sociedade Brasileira de Ortopedia e Traumatologia. All rights reserved.
This is an open access article published by Thieme under the terms of the Creative Commons Attribution-NonDerivative-NonCommercial-License, permitting copying and reproduction so long as the original work is given appropriate credit. Contents may not be used for commercial purposes, or adapted, remixed, transformed or built upon. (<https://creativecommons.org/licenses/by-nc-nd/4.0/>)
Thieme Revinter Publicações Ltda., Rua do Matoso 170, Rio de Janeiro, RJ, CEP 20270-135, Brazil

avaliadas as seguintes variáveis: incidência de perda total ou parcial do retalho e morbidade da área doadora (fechamento primário *versus* enxerto de pele).

Métodos Análise prospectiva e randomizada de dados coletados de todos os pacientes apresentando defeitos em tecidos moles da extremidade distal da perna e do retopé submetidos aos retalhos em questão.

Resultados Foram avaliados 24 pacientes com idades entre 4 e 60 anos, entre 2011 e 2017. Cobertura completa foi obtida em 22 dos 24 pacientes (91,6%) e observamos falha em 2 retalhos (8,4%). O retalho sural, sendo a opção mais popular, continua a representar uma alternativa segura e versátil para defeitos cutâneos do terço distal da perna e da região do calcanhar. O retalho propeller, da mesma maneira, mostrou-se uma opção comparável para o tratamento destas lesões desafiadoras.

Conclusão Os retalhos sural e propeller são boas opções para a cobertura de partes moles da extremidade inferior, demonstrando baixas taxas de complicações como perda parcial ou total do retalho.

Palavras-chave

- ▶ retalho perfurante
- ▶ retalhos cirúrgicos
- ▶ sitio doador de transplante

Introduction

The treatment of skin lesions of the lower limbs is a subject of interest not only due to the high frequency with which they present themselves, but mainly because of the difficulty that they impose on orthopedists and plastic surgeons.¹⁻³ Wounds located between the distal third of the leg and the hindfoot are especially complex^{2,4} due to the small number of local flaps that can be used to cover this region.⁵ In addition, they are often the result of high-energy traumas (notably motorcycle accidents) that cause extensive injuries of a serious nature.^{6,7} Classically, the reverse sural flap is a treatment option, and recently, with the development of flaps based on the concept of skin perforating, the helix or propeller flap has become an additional tool in the therapeutic arsenal to cover defects around the ankle.⁸⁻¹²

To date, there are no prospective studies comparing the sural flap with the propeller flap regarding the survival rate of the flaps, the quality of coverage and/or the morbidity of the donor area, a fact that motivated the performance of the present study.

The aim of the present study was to compare the sural and propeller flaps, objectively evaluating, prospectively:

- The incidence of total flap loss
- The incidence of partial flap loss
- The morbidity of the donor area: primary closure versus skin graft.

Casistry and Methods

The present research project was registered under the number 1,551,439 on the Brazil platform. The authors prospectively and randomized analyzed data collected from patients with soft tissue defects in the leg or foot who were treated by the Hand and Reconstructive Microsurgery Group of the Institute of Orthopedics and Traumatology of the Hospital das Clínicas of the Faculty of Medicine of the Universidade de São Paulo (IOT HC/FMUSP, in the Portuguese acronym) between 2011 and 2017. The inclusion criterion

was the fasciocutaneous flap (sural or propeller) to cover the distal half of the leg and/or the hindfoot, regardless of age. Patients with skin loss in other regions were excluded, as well as those in whom there would be no option of skin coverage with one of the two types of flaps studied.

The secondary defect, originated by mobilization of the sural or propeller flap, was closed primarily or through skin grafting (► **Figure 1**).

A total of 24 patients, 22 men and 2 women, with a mean age of 37.7 years old (4–60 years old) were included in the present study. The characteristics of the patients and the etiology of the lesions are summarized in ► **Table 1**.

All procedures were performed in a single public institution, comprising patients from the outpatient clinic or

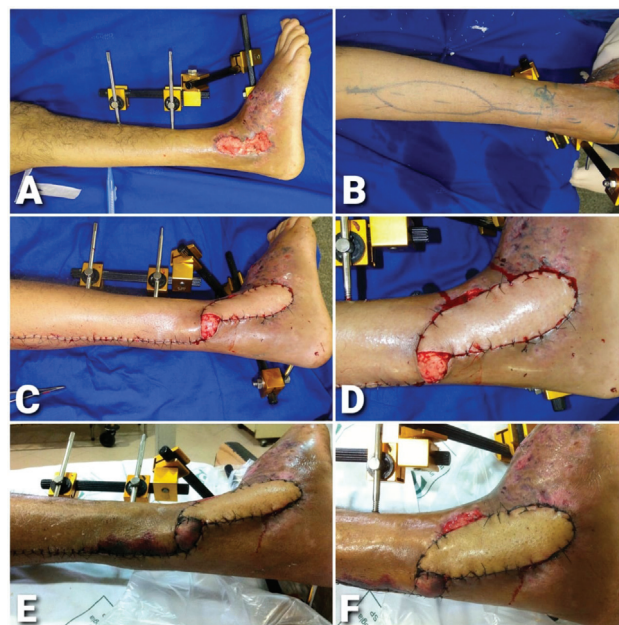


Fig. 1 (A and B) Defect on the lateral malleolus. (B) Sural flap marking. (C and D) Dissected flap, postoperative result. Primary closure of the donor area, with a small partial skin graft on the pedicle of the flap. (E and G) Postoperative period (2 weeks).

Table 1 Casuistry

No.	Age	Gender	Location	Comorbidities	Etiology	Flap	Artery of origin	Dimensions
1	28	M	Lateral malleolus	Denies	Open fracture	Propeller	FA	13 × 6 cm
2	42	M	Medial malleolus	Denies	Trauma	Sural	mSA	11 × 4 cm
3	31	M	AP Ankle Region	Denies	Accident with chainsaw	Propeller	PTA	22 × 7 cm
4	58	F	Heel and back region of the foot	RA	Open fracture	Sural	mSA	10 × 5 cm
5	57	M	AP Ankle Region	Denies	Postoperative dehiscence	Propeller	FA	12 × 6 cm
6	4	M	Medial malleolus	Denies	Run over	Propeller	PTA	18 × 7 cm
7	26	M	AP Ankle Region	Denies	Open fracture	Sural	mSA	19 × 6 cm
8	25	M	Medial malleolus	Denies	Motorcycle accident	Sural	mSA	14 × 8 cm
9	49	M	Lateral malleolus	Abdominal Ao aneurysm	Ankle fracture-dislocation	Sural	mSA	10 × 6 cm
10	23	M	Lateral malleolus	Denies	Open fracture	Sural	mSA	10 × 8 cm
11	36	F	Lateral malleolus	Sickle-cell anemia	Bimalleolar open fracture	Propeller	FA	15 × 5 cm
12	43	M	AP Ankle Region	Denies	Sequelae of exposed fracture	Propeller	PTA	15 × 8 cm
13	59	M	Lateral malleolus	Denies	Trauma	Sural	mSA	15 × 8 cm
14	42	M	Medial malleolus	Smoker	Run over	Propeller	PTA	19 × 6 cm
15	47	M	Heel and back region of the foot	Lymphoma in Hodking	Open calcaneus fracture	Sural	mSA	9 × 6 cm
16	18	M	Lateral malleolus	Denies	Postoperative dehiscence	Sural	mSA	10 × 7 cm
17	17	M	Lateral malleolus	Denies	Trauma	Sural	mSA	10 × 6 cm
18	59	M	Medial malleolus	Denies	Tibial pylon fracture	Propeller	PTA	20 × 6 cm
19	28	M	Medial malleolus	Denies	Open fracture	Propeller	PTA	18 × 5 cm
20	36	M	Heel and back region of the foot	Denies	Trauma	Propeller	PTA	20 × 4 cm
21	60	M	AP Ankle Region	Denies	Gunshot wound	Propeller	PTA	14 × 4 cm
22	33	M	Lateral malleolus	Denies	Sequela of tibial pylon fracture	Sural	mSA	10 × 6 cm
23	43	M	Heel and back region of the foot	Denies	Calcaneus fracture	Sural	mSA	10 × 5 cm
24	41	M	AP Ankle Region	Smoker	COM	Sural	mSA	9.5 × 6.5 cm

Abbreviations: AP, anterior, posterior; AF, Fibular artery; COM, chronic osteomyelitis; mSA, medial sural artery; PTA, posterior tibial artery.

Table 2 Comparison between patients in the Sural and Propeller groups

	Sural Group	Propeller Group
Patients (n. of cases)		
Men	12	10
Women	1	1
Age (years)		
Statistical average \pm SD	38.30 \pm 5.63	35.25 \pm 3.89
Maximum	60	59
Minimum	04	17
Primary disease (n. of cases)		
Post-traumatic injury	11	9
Surgical complication: dehiscence	0	1
Chronic ulcer	1	1
Chronic infection	1	0
Location for reconstruction (n. of cases)		
Malleolar	8	7
Ankle	2	4
Heel and back of foot	3	1

Abbreviation: SD, standard deviation.

emergency room. In all cases, data collection was performed through the protocol completed by the study authors (**►Appendix 1**, available online).

The patients were divided into two groups according to the flap selected for skin coverage: Sural Group and Propeller Group (**►Table 2**). The allocation of the patients to each group was randomized when skin coverage of the affected limb was indicated. Thus, 13 patients were included in the Sural Group and 11 patients were included in the Propeller Group, 3 of them based on perforating fibular artery ($n=3$) and 8 based on posterior tibial artery perforations ($n=8$).

The sural flap was delineated in the posterior-proximal region of the leg with its pivot point marked 5 cm proximally to the end of the lateral malleolus (**►Figure 1**). The blood circulation of the flap was supplied by venocutaneous and neurocutaneous branches from the vessels that accompany the sural nerve and the parva saphenous vein, whose arterial irrigation, in turn, connects to the fibular artery system. Its dissection was performed according to the classical description by Masquelet et al.¹³ (**►Figure 2**).

The propeller flap was of two types, depending on the location of the skin defect:

- Elevated in the medial aspect of the leg, based on perforating of the posterior tibial artery;
- Elevated in the lateral aspect of the leg, based on perforating of the fibular artery.

The use of Doppler ultrasound to locate the perforating perforants was optional and performed in 45% of the patients ($n=5$) of the Propeller Group (**►Figure 3**).

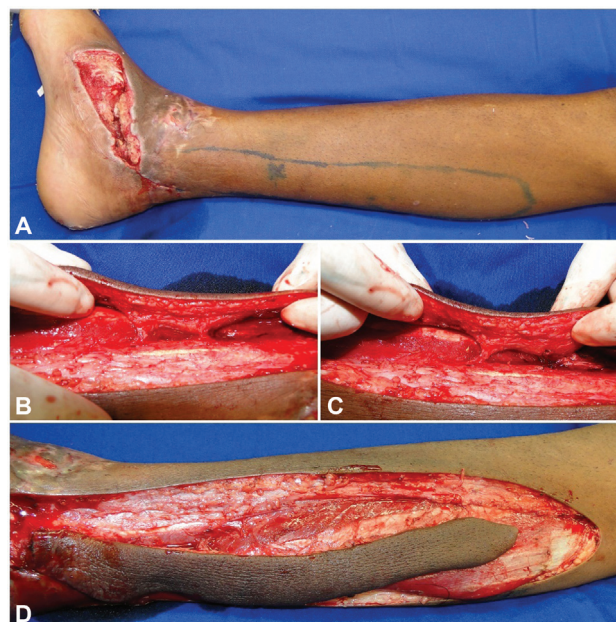

Fig. 2 (A) Male, 31 years old, with soft tissue defect on the medial malleolus (8 \times 5 cm). Medial propeller flap marking [PM]. (B) Dissected flap (posterior tibial artery perforations). (C) Choice of a perforating artery as the main axis of the flap. (D) Dissected flap.

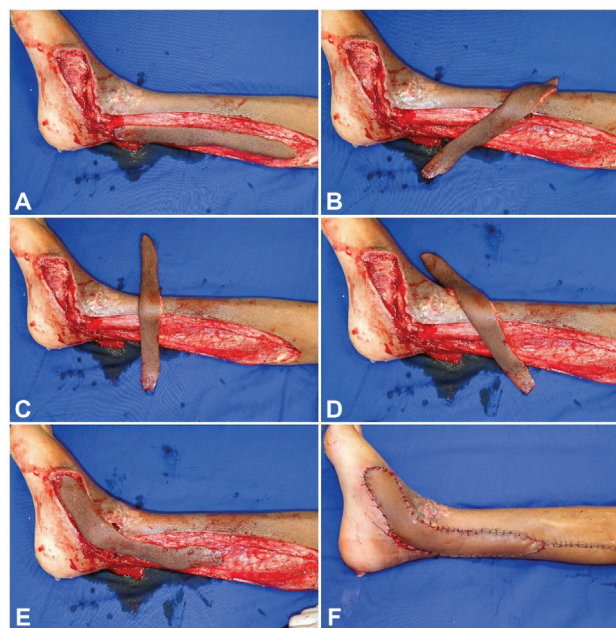


Fig. 3 (A-E) Rotation sequence of the propeller medial flap [PM], approximately 180° counterclockwise, to cover the defect. (F) Final aspect, with primary closure of the donor area.

In both groups, the following variables were recorded: age, etiology, size and location of the defect, flap survival rate, postoperative complications, and secondary revision surgeries. Statistical analysis was performed using IBM SPSS Statistics for Windows version 25 (IBM Corp., Armonk, NY, USA). The vascular status of the lower limb involved was clinically evaluated by the perfusion status, capillary filling time, and palpation of the pulses.

Table 3 Comparison between the flaps of the Sural and Propeller groups

	Sural Group	Propeller Group	
Flap Dimensions (Mean ± SD; range)			t-test
Compliance (cm)	11.35 ± 2.8; 19.0–9.0	16.91 ± 3.2; 20.0 - 12.0	$p = 0.0002$
Width (cm)	6.2 ± 1.2; 8.0–4.0	5.8 ± 1.2; 8.0 - 4.0	$p = 0.38$
Area (cm ²)	71.98 ± 26.3; 120–44	98.64 ± 29.8; 154 - 56	$p = 0.02$
Closure of the donor area (n. of cases [%])			Chi-squared test
Primary	10 (41.67%)	6 (25.0%)	$p = 0.17$
Graft	3 (12.50%)	5 (20.8%)	$p = 0.34$
Postsurgical complications (n. of cases [%])			
Infection	1 (4.10%)	2 (8.30%)	$p = 0.57$
Partial necrosis	2 (8.30%)	3 (12.50%)	$p = 0.62$
Total necrosis	2 (8.30%)	0 (0%)	$p = 0.24$
Additional surgery (n. of cases)			
Graft	1	2	
New flap	3	1	
Repositioning	0	1	

Abbreviation: SD, standard deviation.

Statistical Analysis

All data were presented as a mean and standard deviation (SD), trying to summarize the characteristics of patients and the two groups of flaps. The dimensions of the flaps were compared between the two groups using the Student t-test. The closure of the donor area and the complications were analyzed with the chi-squared test. GraphPad Prism (GraphPad Software, San Diego, CA, USA) was used for statistical analysis, and a p -value < 0.05 was considered statistically significant (► **Table 3**).

Results

In the Sural Group, the mean flap size was 14×6 cm, the partial loss rate was 15% (2/13), and the total loss rate was 15% (2/13). Additional surgery was required for debridement in four patients and additional skin coverage with skin graft in one patient or with a new flap in three patients. The donor area was closed primarily in 10 patients, and skin grafting was required in 3 patients.

In the Propeller Group, the mean flap size was 18×6 cm, the partial loss rate was 27% (3/11), and the total loss rate was 0%. Additional surgery was required for debridement in four patients and additional skin coverage with skin graft in two patients or with a new flap in one patient (partial loss of heis). The donor area was closed primarily in six patients, and skin grafting was required in five patients (► **Figure 4**).

Considering the total group of patients (sural and heis groups), no significant differences were found between the incidences of partial and total flap loss, and complete skin coverage was obtained in 22 of the 24 patients (91.6%). Two

flaps (Sural Group) showed failure evolving to total loss (15%; 2/13 Sural Group).

In 22 patients whose flaps evolved favorably, 16 did not present any type of complication (66%). Three developed infection (12.5%), 2 with distal border necrosis with partial flap loss (8.3%), and 1 patient (4.1%; Propeller Group) presented with impairment of the flap perfusion after its

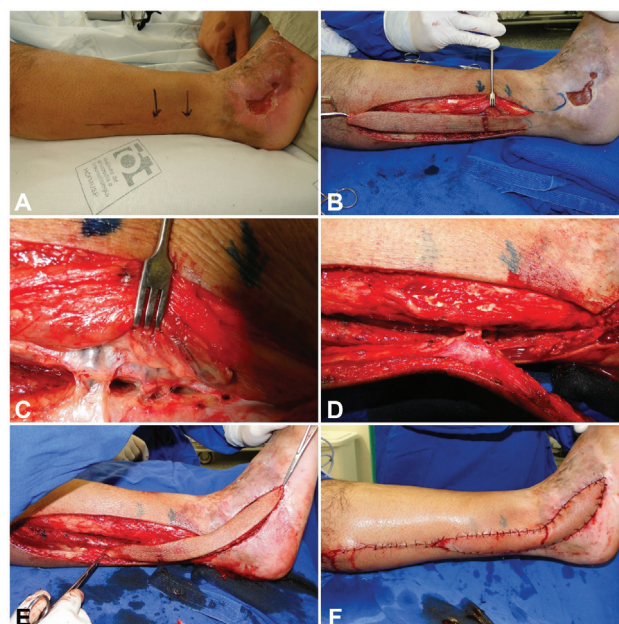


Fig. 4 (A) Soft tissue defect on the lateral malleolus (7×4 cm). (B) Propeller lateral flap marking [PL]. (C) Flap based on perforating fibular artery. (D) Ligation of secondary perforating artery. (E) Rotation of the propeller lateral flap [PL] of approximately 180° clockwise. (F) Final aspect of the primary closure of the donor area.

Table 4 Complications according to the type of flap

		Complications					Total
		No.	Infection	Partial loss	Repositioning	Total loss	
Flap	Sural	9	1	1	0	2	13
	Propeller	7	2	1	1	0	11
Total		16	3	2	1	2	24

Table 5 Closing of the donor area according to the type of flap

		Closing of the donor area		Total
		Primary	Graft	
Flap	Sural	10	3	13
	Propeller	6	5	11
Total		16	8	24

mobilization to the receiving area, and it was necessary to reposition it to the original bed for autonomization and final mobilization after 1 week, finally succeeding in covering the lesion (► **Table 4**).

Three patients (2 Propeller, 1 Sural) also required repositioning and skin graft coverings in residual bloody areas, in association with flaps.

The comparative analysis of the sural and propeller flaps showed no difference in the morbidity of the donor area. The primary closure of the donor area was performed in 67% of patients (16/24) ($p=0.17$), and partial skin grafting was required in 33% (8/24) ($p=0.34$) (► **Table 5**). Primary closure was possible in 76% of the patients in the sural group, while in the propeller group the closure was possible in 55% of the patients.

Discussion

The goal of reconstructive surgery of the lower limb is to obtain functionally and aesthetically adequate limbs. The complexity of reconstruction depends, among other factors, on the energy and mechanism of trauma, on limb irrigation, and on the comorbidities of each patient.^{14,15} The options are: single regional flaps (perforating or neurocutaneous, for example), multiple combined flaps, and microsurgical flaps.¹⁶

Regional flaps have as benefits the lower complexity in their elevation (dispensing the microsurgical technique), use of tissues of the injured limb itself, shorter surgical time, and preservation of the vascular axes of the lower limbs. Regional fasciocutaneous flaps provide a safe and versatile shape for covers in the distal segment of the leg and in the hindfoot.^{15,16}

The reverse sural flap, first identified by Taylor et al.¹⁷ in 1975, is the regional flap of axial pattern most used for the distal region of the leg and the hindfoot.¹⁸ It was popularized by Masquelet et al.¹³ in 1992, who confirmed the retrograde arterial supply, its relationship with the sural nerve, and its venous drainage.

The introduction of helix or propeller flaps expanded the options for skin coverage of the lower limbs. First described by Hyakusoku et al.,¹⁹ the propeller flap can be designed anywhere where there is a perforating present. In addition, the morbidity of the donor site may be minimal, and primary closure is generally possible.¹⁹ The surgical technique has been gradually improved in recent years; therefore, currently, propeller flaps are considered safe and effective.³

The posterior region of the leg is supplied by the sural angiosome, based on the musculocutaneous sural arteries: middle, median, and lateral superficial sural arteries, supplying the skin and fascia of this region. The median superficial artery is the largest, proximally studying from the popliteal fossa and following between the two heads of the gastrocnemius muscles (raphe). Proximally, its path is subfascial (deeper) and, distally, it becomes subdermal at the level of the musculotendinous union of the lateral gastrocnemius muscle. At the ankle, this arteriola is accompanied by the sural nerve and is medial to the small saphenous vein at the level of the lateral malleolus. It maintains numerous anastomoses with the fibular artery along its course, vessels that will be connected and divided during dissection for mobilization of the reverse sural flap. Distally, at between 5 and 6 cm proximal from the tip of the lateral malleolus, is located the potentially more distal pivot point of the pedicle, which allows a greater range of rotation of the flap.²⁰

Currently, there are few studies comparing the sural flap versus the propeller. Demiri et al.¹⁵ published a retrospective comparative study on the reverse neurocutaneous versus helix perforating flaps (Propeller) for reconstruction of the diabetic foot, obtaining high success rates (between 95 and 97%) with both flaps. The results of the present study also show high success rates regarding skin coverage, with low rates of complications (partial or total loss). The sural flap, being more used, continues to represent a safe and versatile alternative for cutaneous defects of the distal third of the leg and of the calcaneus tendon. Also, the propeller flaps based on perforating fibular or posterior tibial artery were viable options for skin coverage of this region. When a primary closure in the donor area was not possible, a partial skin graft was used in the present series with adequate functional and aesthetic results.

Even with the small number of patients studied, we believe that the prospective and randomized analysis of the techniques contributes to the decision-making of reconstructive surgeons.

Conclusion

The sural and propeller flaps were viable options for the treatment of soft tissue lesions of the lower third of the leg and the hindfoot. The prospective and randomized comparison between the techniques showed low rates of partial or total loss of flaps, as well as of complications.

Sources of Funding

The present research did not receive any specific funding from funding agencies in the public, commercial or not-for-profit sectors.

Conflict of Interests

The authors have no conflict of interests to declare.

References

- Zhang F, Lin S, Song Y, Zhang G, Zheng H. Distally based sural neuro-lesser saphenous veno-fasciocutaneous compound flap with a low rotation point: microdissection and clinical application. *Ann Plast Surg* 2009;62(04):395–404
- Aoki S, Tanuma K, Iwakiri I, et al. Clinical and vascular anatomical study of distally based sural flap. *Ann Plast Surg* 2008;61(01):73–78
- Jakubietz RG, Jakubietz MG, Gruenert JG, Kloss DF. The 180-degree perforator-based propeller flap for soft tissue coverage of the distal, lower extremity: a new method to achieve reliable coverage of the distal lower extremity with a local, fasciocutaneous perforator flap. *Ann Plast Surg* 2007;59(06):667–671
- Tos P, Innocenti M, Artiaco S, et al. Perforator-based propeller flaps treating loss of substance in the lower limb. *J Orthop Traumatol* 2011;12(02):93–99
- Noack N, Hartmann B, Küntscher MV, Ku MV. Measures to prevent complications of distally based neurovascular sural flaps. *Ann Plast Surg* 2006;57(01):37–40
- Moscatiello F, Masià J, Carrera A, Clavero JA, Larrañaga JR, Pons G. The 'propeller' distal anteromedial thigh perforator flap. Anatomical study and clinical applications. *J Plast Reconstr Aesthet Surg* 2007;60(12):1323–1330
- Costa-Ferreira A, Reis J, Pinho C, Martins A, Amarante J. The distally based island superficial sural artery flap: clinical experience with 36 flaps. *Ann Plast Surg* 2001;46(03):308–313
- Rajendra Prasad JS, Cunha-Gomes D, Chaudhari C, Bhatena HM, Desai S, Kavarana NM. The venoneuroadipofascial pedicled distally based sural island myofasciocutaneous and muscle flaps: anatomical basis of a new concept. *Br J Plast Surg* 2002;55(03):203–209
- Murakami M, Hyakusoku H, Ogawa R. The multilobed propeller flap method. *Plast Reconstr Surg* 2005;116(02):599–604
- Lu TC, Lin CH, Lin CH, Lin YT, Chen RF, Wei FC. Versatility of the pedicled peroneal artery perforator flaps for soft-tissue coverage of the lower leg and foot defects. *J Plast Reconstr Aesthet Surg* 2011;64(03):386–393
- Pignatti M, Ogawa R, Hallock GG, et al. The "Tokyo" consensus on propeller flaps. *Plast Reconstr Surg* 2011;127(02):716–722
- Panse NS, Bhatt YC, Tandale MS. What is safe limit of the perforator flap in lower extremity reconstruction? Do we have answers yet?. *Plast Surg Int* 2011;2011:349357
- Masquelet AC, Romana MC, Wolf G. Skin island flaps supplied by the vascular axis of the sensitive superficial nerves: anatomic study and clinical experience in the leg. *Plast Reconstr Surg* 1992;89(06):1115–1121
- Akhtar S, Ahmad I, Khan AH, Khurram MF. Modalities of soft-tissue coverage in diabetic foot ulcers. *Adv Skin Wound Care* 2015;28(04):157–162
- Demiri E, Tsimponis A, Pavlidis L, Spyropoulou GA, Foroglou P, Dionysiou D. Reverse neurocutaneous vs propeller perforator flaps in diabetic foot reconstruction. *Injury* 2020;51(Suppl 4):S16–S21
- Ibrahim A, Oneisi A. Lower Extremity Reconstruction. In: Abu-Sittah G, Hoballah J, Bakhach J, editors. *Reconstructing the War Injured Patient*. Cham, Switzerland: Springer International Publishing; 2017:79–88
- Taylor GI, Daniel RK. The anatomy of several free flap donor sites. *Plast Reconstr Surg* 1975;56(03):243–253
- Donski PK, Fogdestam I. Distally based fasciocutaneous flap from the sural region. A preliminary report. *Scand J Plast Reconstr Surg* 1983;17(03):191–196
- Hyakusoku H, Yamamoto T, Fumiiri M. The propeller flap method. *Br J Plast Surg* 1991;44(01):53–54
- Cho AB, Pohl PH, Ruggiero GM, Aita MA, Mattar TG, Fukushima WY. The proximally designed sural flap based on the accompanying artery of the lesser saphenous vein. *J Reconstr Microsurg* 2010;26(08):501–508