Article published online: 2021-12-17

CT-Guided Transhepatic Catheter Drainage of Deep Postoperative Collections: Initial Experience

Akhil Baby[1] Danny Joy[2] Nihar R. Dash[2] Sujoy Pal[2] Deep N. Srivastava[1] Kumble S. Madhusudhan[1]

[1] Department of Radiodiagnosis and Interventional Radiology, All India Institute of Medical Sciences, New Delhi, India
[2] Department of Gastrointestinal Surgery and Liver Transplantation, All India Institute of Medical Sciences, New Delhi, India

Address for correspondence Kumble S. Madhusudhan, MD, FRCR, Department of Radiodiagnosis and Interventional Radiology, All India Institute of Medical Sciences, Ansari Nagar, New Delhi, 110029, India (e-mail: drmadhuks@gmail.com).

J Clin Interv Radiol ISVIR 2022;6:158–162.

Abstract

Purpose This article assesses the safety and utility of transhepatic drainage of deep seated postoperative intra-abdominal collections under computed tomography (CT) guidance in a short series.

Methods This retrospective study included five patients (mean age: 45.8 years; 3 males, 2 females) who underwent CT-guided transhepatic drainage of postoperative abdominal abscess in our department between April 2019 and December 2020. The clinical and surgical details and the details of the transhepatic drainage procedure were evaluated along with success rates and complications.

Results The surgical procedures were Whipple's pancreaticoduodenectomy in four patients and gastrectomy in one patient. Four out of five abscesses were drained through the right lobe of liver, while one was through the left lobe with a technical success rate of 100%. The mean total time for catheter drainage procedure including patient positioning and preparation was 29.2 minutes. None of the patients had procedure-related complications. Mean duration of catheter drainage was 12 days. All patients had complete resolution of symptoms after drainage and the clinical success rate was 100%.

Conclusion Transhepatic approach is safe and effective for the drainage of inaccessible postoperative abdominal collections or abscesses where a standard percutaneous approach is not possible.

Keywords
- postop collection drainage
- interventional radiology
- computed tomography guided drainage

Introduction

Development of intra-abdominal abscesses or collections is a common complication following various intra-abdominal surgeries.[1] If these abscesses or collections are left untreated, it could result in a series of complications such as intra-abdominal bleed, sepsis, and mortality ranging from 45 to 100%.[2] Over the past 20 years, image-guided percutaneous drainage has surpassed surgical drainage and has become the standard therapy for intra-abdominal abscesses.[3] However, conventional percutaneous approaches for abscess drainage may not be suitable for deeply located and inaccessible

article published online
December 17, 2021

DOI https://doi.org/10.1055/s-0041-1740572.
ISSN 2457-0214.

© 2021. Indian Society of Vascular and Interventional Radiology. All rights reserved.
This is an open access article published by Thieme under the terms of the Creative Commons Attribution-NonDerivative-NonCommercial-License, permitting copying and reproduction so long as the original work is given appropriate credit. Contents may not be used for commercial purposes, or adapted, remixed, transformed or built upon. (https://creativecommons.org/licenses/by-nc-nd/4.0/)
Thieme Medical and Scientific Publishers Pvt. Ltd., A-12, 2nd Floor, Sector 2, Noida-201301 UP, India

abscesses or collections because of many obstacles, such as surrounding viscera, like liver, stomach, bowel, spleen, and kidney, and intervening vascular structures along the catheter tract.[4] Few sporadic studies have described the safety and efficacy of transhepatic drainage of inaccessible intra-abdominal abscesses under computed tomography (CT) or ultrasonographic (USG) guidance.[5–7] Here, we report a short series of five patients who developed deep intra-abdominal abscess after surgery and were successfully managed by transhepatic catheter drainage. We also review the literature on transhepatic drainage.

Materials and Methods

This retrospective study was approved by the institute ethics committee and informed consent was waived. Between April 2019 and December 2020, five patients (mean age: 45.8 ± 15 years; 3 men and 2 women) underwent CT-guided transhepatic drainage of postoperative abdominal abscess in our department and were included in this case series.

Patient Data

The demographic and clinical data, surgical details, laboratory results, indication for drainage, and postprocedure data were obtained from institutional medical records. The imaging and procedure-related details were obtained from the departmental picture archiving and communication system and patient records. All abscesses were confirmed on the contrast-enhanced CT scan and the decision to drain was made after a discussion between the gastrointestinal surgeons and the interventional radiologists. In all the five patients, the collections were surrounded by liver, bowel, and vessels (►**Figs. 1** and **2**) and hence a transhepatic route was chosen for drainage. Informed consent for the procedure was obtained from each patient before the procedure.

Drainage Procedure

All procedures were performed under CT guidance on a dual energy CT scanner (Somatom Definition, Siemens, Erlangen, Germany) under local anesthesia and with patients lying either in supine or left decubitus position. The transhepatic trajectory of the drainage was planned on the diagnostic CT scan. A peripheral portion of the liver parenchyma was chosen as the entrance site to avoid any major hepatic vascular and biliary injury. Seldinger technique of drainage was used in all patients. An 18-gauge 15-cm long diamond-tipped two-part puncture needle was used to enter the abscess through the liver (►**Fig. 3A**). Then the stylette of the puncture needle was removed and the fluid was aspirated to ensure the correct placement of needle. Subsequently, the needle was removed over an extrastiff guidewire (Cook Medical, Bloomington, United States) and the tract was dilated. Finally, an 8F ($n = 3$) or 10F ($n = 2$) pigtail catheter was inserted over the extrastiff guidewire and the position was confirmed on CT scan (►**Fig. 3B**). The catheter was fixed to the skin using sutures and connected to a collecting bag.

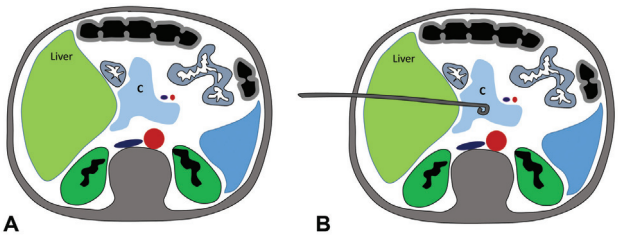

Fig. 1 Schematic diagrams (A, B) showing a deep-seated collection (C) surrounded by bowel loops and vessels with drainage performed through transhepatic route (**B**).

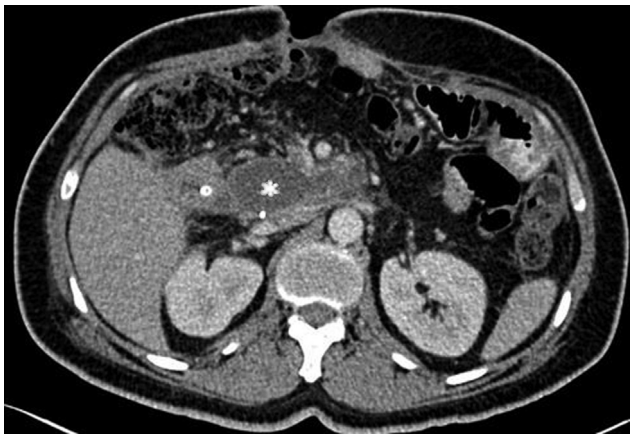

Fig. 2 Axial contrast-enhanced computed tomography (CT) image in a patient after Whipple's procedure showing a well-defined collection (white asterisk) surrounded by liver and duodenum on right side, kidneys and major vessels posteriorly, superior mesenteric vessels and bowels loops anteriorly and to left.

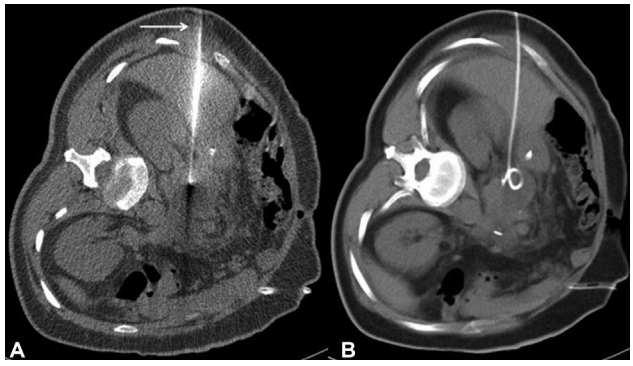

Fig. 3 (**A**) Axial computed tomography (CT) section with same patient as in ►**Fig. 2** in left decubitus position showing an18-gauge, 15-cm long diamond-tipped two-part puncture needle (white arrow) reaching the abscess through the right lobe of liver (segment 6), between duodenum and right kidney.(**B**) Axial CT scan at the end of the procedure shows the catheter with tip in the abscess cavity.

Postprocedure Evaluation

All patients were monitored clinically after the procedure and the drain volume was recorded daily. Any complications developing during this time was recorded. The catheter was removed when the patient showed clinical improvement (no fever or leukocytosis) and when there was no output in the catheter for more than 48 hours. In doubtful cases, CT scan was repeated to assess response. The technical and clinical

 © 2021. Indian Society of Vascular and Interventional Radiology. All rights reserved.

success of the procedure and the duration of catheter drainage were also assessed.

Results

Demographic and clinical details of the patients are described in ►**Table 1**. The surgical procedures were Whipple's pancreatoduodenectomy in four patients (80%) and gastrectomy in one patient (20%). All patients presented with fever and elevated total leucocyte counts (mean: $16.5 \pm 8.7 \times 10^3$/µL). Mean duration between the surgery and insertion of transhepatic drainage catheter was 12.6 ± 5.9 days (range: 9–23 days). All catheter drainages were performed within 24 hours of diagnosis of the abscess by CT scan. The mean longest diameter of the abscess was 8.3 ± 1.15 cm.

All catheters were placed via the preplanned route with a technical success rate of 100%. Four out of five (80%) abscesses were drained through the right lobe of liver, while one (20%) was through the left lobe. The mean total time for catheter drainage procedure from the initial scan including patient positioning and preparation, till the catheter fixation to the skin using sutures was 29.2 ± 7.4 minutes.

There were no procedure-related complications in any patient. Mean duration of catheter drainage was 12 ± 3.5 days. All patients had successful drainage of the abscess with resolution of fever and normalization of total leucocyte count. Thus, the clinical success was 100%. Two patients had follow-up CT scans after a mean period of 12 days after catheter drainage. The scans showed near-complete resolution of the abscess (►**Fig. 4**). All patients were discharged after catheter removal in stable condition. The findings are summarized in ►**Table 1**.

Discussion

Image-guided percutaneous drainage with catheter is the treatment of choice in the management of patients with intra-abdominal abscesses.[3] In a majority of cases, the percutaneous access route is straightforward and the abscesses are drained under either USG or CT guidance. However, uncommonly, the simple percutaneous approach may not be possible because of the deep and inaccessible location of the abscess and the intervening critical structures like bowel, liver, and vessels.[4] Various CT-guided approaches with modifications and improvisations have been described in the literature for the drainage of such intra-abdominal and pelvic abscesses.[4] This entails the use of angled gantry technique, hydrodissection to displace the critical structures, and traversing less critical structures like stomach, rectum, vagina, and liver.[8]

The transhepatic approach for the drainage of abscesses was first described by Mueller et al in 1985.[6] They successfully and safely performed this procedure in 12 patients, 8 of whom had postoperative collections requiring drainage. Subsequently, the safety and efficacy of this approach in the drainage of deep-seated abscesses or collections were confirmed by Yamakado et al[7] in 12 patients, Ciftci et al[5] in 30 patients, and Zhao et al[9] in 32 patients. Image-guided catheter drainage of deep liver abscesses and obstructed biliary ducts routinely involves a pathway via the liver parenchyma and is considered safe.[10,11] However, compared with liver abscess or biliary drainage, transhepatic drainage of deep-seated abscesses necessitates the passage of the catheter with breach of liver capsule at two points. Few suggestions have been made for safe transhepatic drainage.[4] These include confirming a normal coagulation profile, using the shortest path through the liver, and avoiding major blood vessels, dilated bile ducts, and other organs like the gallbladder. The third and sixth segments of liver parenchyma are usually preferred for transhepatic access, because of the absence of major vascular and biliary branches.[5] Furthermore, it is important to ensure that the side-holes of the catheter are in the abscess cavity and not in the liver parenchyma to avoid liver infection. However, when there is uncorrectable coagulopathy, liver cirrhosis, and dilated bile ducts, this procedure should be avoided.[6] CT is generally preferred over USG as the guiding modality since it allows better visualization of the deeper structures in the abdomen and is not limited by bowel gas or obesity. Further, in the postoperative period, inflammation also affects visualization by USG. Hence, we and most of the cases in the studies reported used CT guidance for transhepatic drainage. However, one study has reported the safe use of USG as guidance for transhepatic drainage of abscesses.[5]

Mean time required for the procedure as reported in the published series ranged from 12 to 19 minutes which was less than our series. However, the studies did not define what constituted procedure time. The technical success of transhepatic drainage of abdominal abscesses ranges from 97 to 100% in the reported studies.[5–7,9] The clinical success rates, which are based on clinical improvement and resolution of the abscess on imaging, ranged from 94 to 100%. The reasons for clinical failure were the need for surgery, recurrence of the abscess after catheter removal, and death due to sepsis.[5,7,9] Our short series had 100% technical and clinical success rates. The mean duration of catheter drainage ranged from 18 to 33 days with patients having a fistula or leak requiring placement for a longer time.[5,7,9] The common sizes of the catheters used were 8F and 10F. Our series also used 8F and 10F catheters for a mean duration of 12 ± 3.5 days.

No major procedure or catheter-related complications occurred in any of our patients. Various complications associated with transhepatic intra-abdominal abscess drainage include vascular and biliary injury, bacteremia, liver abscess due to secondary bacterial contamination through the catheter track, and catheter-related minor complications such as dislodgment, accidental removal, obstruction, and kinking of drainage catheters.[5,7] Fistulous communications with small bowel and biliary tree have also been reported.[5] Catheter-related complications were significantly more frequent with 8F compared to 10F or 12F catheters.[5] Although accidental catheter dislodgement is uncomplicated, a case of fatal liver injury and bleeding has been reported.[12] Although there is a theoretical possibility of higher procedure-related pain due to the puncture of liver capsule at two sites, this has not been addressed in the published literature.

 © 2021. Indian Society of Vascular and Interventional Radiology. All rights reserved.

Table 1 Demographic clinical and laboratory details of the patients

	Patient 1	Patient 2	Patient 3	Patient 4	Patient 5
Age, sex	43, male	42, female	60, male	60, female	leading="8pt"24, male
Presenting complaints	Pain in RUQ and progressive jaundice × 2 mo	Pain in RUQ and progressive jaundice × 3 mo	painless progressive jaundice × 1 mo	Fever and painless progressive jaundice × 7 mo	Corrosive ingestion under alcohol influence
Primary diagnosis	Periampullary carcinoma	Periampullary carcinoma	Periampullary carcinoma	Mid-CBD cholangiocarcinoma	Acute corrosive injury with sealed gastric perforation
Surgery performed	Whipple's procedure	Whipple's procedure	Whipple's procedure	Whipple's procedure	Total gastrectomy with tube duodenostomy and feeding jejunostomy
Symptoms suggesting collection/abscess during post operative period	Pain abdomen Fever	Pain abdomen Fever	Pain abdomen Fever	Pain abdomen Fever	Pain abdomen Fever
Time between surgery and symptoms (days)	20	10	7	8	7
WBC counts prior to drainage ($n \times 10^3/\mu L$)	12.7	12.5	11.5	12	33.9
Duration between surgery and transhepatic drainage (d)	23	12	9	9	10
Access route for drainage/Segment of liver	Right lobe of liver/segment 6	Right lobe of liver/segment 6	Right lobe of liver/segment 6	Right lobe of liver/segment 6	Left lobe of liver/segment 3
Size of drainage catheter	8-Fr	8-Fr	10-Fr	10-Fr	8-Fr
Duration of the procedure (min)	31	21	22	37	35
Procedure or catheter-related complications	Nil	Nil	Nil	Nil	Nil
Duration of catheter drainage (days)	9	15	16	8	12
WBC counts at catheter removal ($n \times 10^3/\mu L$)/fever status	10.2/afebrile	8.8/afebrile	4.96/afebrile	2.46/afebrile	10.7/afebrile

Abbreviations: CBD, common bile duct; RUQ, right upper quadrant; WBC, white blood cell.

 © 2021. Indian Society of Vascular and Interventional Radiology. All rights reserved.

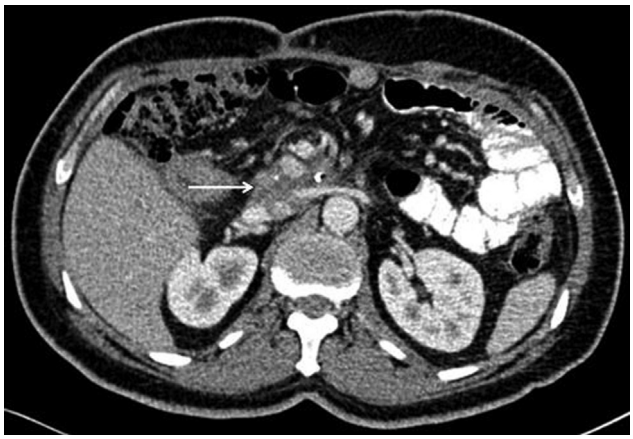

Fig. 4 Axial computed tomography (CT) scan during follow-up of the same patient after catheter removal showing near-complete resolution of the abscess (white arrow).

There have been reports in literature regarding endoscopic ultrasound (EUS)-guided drainage of postoperative abdominal collections and abscesses.[13,14] The clinical success rates of this procedure were reported to be 70 to 80%.[13] Significant advantage of EUS-guided drainage over percutaneous or surgical drainage is the lack of longstanding fistula.[13] There is also a decreased risk of injury to interposed blood vessels. However, due to modified bowel anatomy in postoperative cases, many of these abscesses and collections may not be accessible under EUS guidance. To our knowledge, there are no reports comparing the outcomes of EUS-guided drainage and image-guided percutaneous drainage for the treatment of postoperative intra-abdominal abscesses.

In conclusion, the transhepatic approach is safe and effective for the drainage of inaccessible postoperative abdominal collections or abscesses where a standard percutaneous approach is not possible.

Funding
None.

Conflict of Interest
None declared.

References

1 Schulick RD. Complications after pancreaticoduodenectomy: intraabdominal abscess. J Hepatobiliary Pancreat Surg 2008;15(03):252–256
2 Men S, Akhan O, Köroğlu M. Percutaneous drainage of abdominal abscess. Eur J Radiol 2002;43(03):204–218
3 Jaffe TA, Nelson RC. Image-guided percutaneous drainage: a review. Abdom Radiol (NY) 2016;41(04):629–636
4 Maher MM, Gervais DA, Kalra MK, et al. The inaccessible or undrainable abscess: how to drain it. Radiographics 2004;24(03):717–735
5 Ciftci TT, Akinci D, Akhan O. Percutaneous transhepatic drainage of inaccessible postoperative abdominal abscesses. AJR Am J Roentgenol 2012;198(02):477–481
6 Mueller PR, Ferrucci JT Jr, Simeone JF, et al. Lesser sac abscesses and fluid collections: drainage by transhepatic approach. Radiology 1985;155(03):615–618
7 Yamakado K, Takaki H, Nakatsuka A, et al. Percutaneous transhepatic drainage of inaccessible abdominal abscesses following abdominal surgery under real-time CT-fluoroscopic guidance. Cardiovasc Intervent Radiol 2010;33(01):161–163
8 McDermott S, Levis DA, Arellano RS. Approaches to the difficult drainage and biopsy. Semin Intervent Radiol 2012;29(04):256–263
9 Zhao N, Li Q, Cui J, Yang Z, Peng T. CT-guided special approaches of drainage for intraabdominal and pelvic abscesses: one single center's experience and review of literature. Medicine (Baltimore) 2018;97(42):e12905
10 Madhusudhan KS. Percutaneous biliary interventions. In: Mukund A, ed. Basics of Hepatobiliary Interventions. New Delhi: Springer, Singapore; 2021:9–43
11 Haider SJ, Tarulli M, McNulty NJ, Hoffer EK. Liver abscesses: factors that influence outcome of percutaneous drainage. AJR Am J Roentgenol 2017;209(01):205–213
12 Lee SH, Kang CM, Chung YE, Park JY, Lee WJ. Fatal liver injury complicated by percutaneous catheter drainage after distal pancreatosplenectomy in a patient with pancreatic cancer. Korean J Hepatobiliary Pancreat Surg 2014;18(02):64–67
13 Gupta T, Lemmers A, Tan D, Ibrahim M, Le Moine O, Devière J. EUS-guided transmural drainage of postoperative collections. Gastrointest Endosc 2012;76(06):1259–1265
14 Tilara A, Gerdes H, Allen P, et al. Endoscopic ultrasound-guided transmural drainage of postoperative pancreatic collections. J Am Coll Surg 2014;218(01):33–40

 © 2021. Indian Society of Vascular and Interventional Radiology. All rights reserved.