


# Sinonasal Neuroendocrine Carcinoma: 15 Years of Experience at a Single Institution

Charles A. Keilin<sup>1</sup>  Kyle K. VanKoevering<sup>2,3</sup> Jonathan B. McHugh<sup>4</sup> Erin L. McKean<sup>5,6</sup>

<sup>1</sup>University of Michigan Medical School, Ann Arbor, Michigan, United States

<sup>2</sup>Division of Skull Base Surgery, Department of Otolaryngology-Head and Neck Surgery, The Ohio State University, Columbus, Ohio, United States

<sup>3</sup>Department of Neurosurgery, The Ohio State University, Columbus, Ohio, United States

<sup>4</sup>Department of Pathology, Michigan Medicine, Ann Arbor, Michigan, United States

<sup>5</sup>Division of Skull Base Surgery and Rhinology, Department of Otolaryngology-Head and Neck Surgery, Michigan Medicine, Ann Arbor, Michigan, United States

<sup>6</sup>Department of Neurosurgery, Michigan Medicine, Ann Arbor, Michigan, United States

**Address for correspondence** Erin L. McKean, MD, MBA, Department of Otolaryngology-Head and Neck Surgery, Michigan Medicine, 1500 E. Medical Center Drive, Ann Arbor, MI 48109, United States (e-mail: elmk@med.umich.edu).

J Neurol Surg B Skull Base 2023;84:51–59.

## Abstract

**Objectives** Sinonasal neuroendocrine carcinomas (SNECs) are among the rarest paranasal sinus cancers. Consensus guidelines for therapy are difficult to develop due to limited data regarding the natural history and successful treatment of these tumors. This study presents 15 years of experience treating SNEC at a single institution and a review of the literature.

**Design** Retrospective review.

**Setting** Academic medical center in the United States.

**Participants** Patients diagnosed with primary SNEC.

**Main Outcome Measures** Overall survival.

**Results** Thirteen patients were identified and included. Overall estimated survival was 74.6% at 5 years. Ten of 13 (76.9%) patients were diagnosed with high-grade neuroendocrine carcinoma and three (23.1%) with intermediate or low grade. All three patients with low- or intermediate-grade cancer survived more than 10 years from their initial diagnosis (median survival: 11.6 years) and are currently alive. The four patients who died had high-grade carcinoma, and estimated overall 5-year survival for all patients with high-grade carcinomas was 65.6%. Five patients, all with high-grade carcinoma, of seven who completed primary chemoradiation therapy (CRT) required salvage resection, and 60% are alive without disease.

**Conclusion** This cohort has a higher overall rate of survival than many recent case series and reviews. There is consensus that multimodal therapy is preferred over monotherapy, but approaches to treatment vary widely. Our approach of surgical resection as primary therapy for low-grade tumors and primary CRT for high-grade SNEC has been successful, and could indicate hope for improved survival among these patients.

## Keywords

- ▶ sinonasal neuroendocrine carcinoma
- ▶ skull base
- ▶ small cell carcinoma
- ▶ SNEC

received

October 20, 2021

accepted after revision

November 12, 2021

article published online

January 10, 2022

© 2022. Thieme. All rights reserved.

Georg Thieme Verlag KG,

Rüdigerstraße 14,

70469 Stuttgart, Germany

DOI <https://doi.org/>

10.1055/s-0041-1740968.

ISSN 2193-6331.

## Introduction

Sinonasal neuroendocrine carcinomas (SNECs) are among the rarest cancers of the paranasal sinuses. SNEC was first described almost 30 years ago as being morphologically distinct from olfactory neuroblastoma (ONB),<sup>1</sup> and more recently, this categorization has been further refined to distinguish these tumors from sinonasal undifferentiated carcinomas (SNUCs).<sup>2,3</sup> Still, these tumors can be difficult to distinguish from one another histopathologically, with a recent report by Choi et al showing that 63% of SNEC, 43% of SNUC, and 4% of ONB cases at the MD Anderson Cancer Center were reclassified after review by an experienced head and neck pathologist.<sup>4</sup> This likely highlights the reality that these tumors exist along a continuum, despite their distinct characteristics. In addition, SNEC still encompasses a variety of diagnoses, including carcinoid (low-grade), atypical carcinoid (intermediate-grade), small- and large-cell (high-grade), and well- or moderately differentiated neuroendocrine cancers that arise primarily in the nasal cavity or paranasal sinuses. The rarity of these tumors has limited previous study to case reports and small case series. A meta-analysis in 2016 found only 242 cases of SNEC published.<sup>5</sup> These cancers can be quite aggressive and are often identified at an advanced stage. Despite limited data to guide therapy, multimodal treatment is most frequently recommended.<sup>6–8</sup> Our aim is to present 15 years of experience treating these cancers at the University of Michigan (UM) and to review prior published data.

## Materials and Methods

The Electronic Medical Record Search Engine (EMERSE) was used to search both the current and legacy electronic medical record systems at UM for keywords used in clinical notes, including radiology, pathology, and other reports, dating back to 1998. An EMERSE search was performed using the keywords “sinonasal neuroendocrine carcinoma” that generated a list of 11 patients who fit our inclusion criteria. Additional EMERSE searches using the keywords “ethmoid neuroendocrine carcinoma” and “sphenoid neuroendocrine carcinoma” were performed. From these lists, one further patient was identified. Finally, a recently diagnosed patient was identified by the treating physician (K.K.V.) after these searches were performed. A total of 13 patients were identified from 2005 to May 2020. All of their original pathologic slides were re-reviewed by an experienced head and neck pathologist with particular expertise in endocrine pathology (J.B.M.) to confirm their diagnoses, including overall grade and tumor characteristics. These 13 patients received some or all of their treatment at UM and were included in the analysis after review and confirmed the diagnosis of SNEC in accordance with 2017 World Health Organization diagnostic criteria.<sup>9</sup> Follow-up data were included in our analysis through March 25, 2021. In the case of patients lost to follow-up, an internet search for obituaries and the social security death index (SSDI; updated with data through July 28, 2017) were used to determine patient status. Data

were analyzed using SPSS (IBM, Armonk, New York, United States), and the Kaplan–Meier method was used to estimate survival. The log-rank test was used for hypothesis testing comparing Kaplan–Meier curves to determine statistical significance. Institutional Review Board approval was obtained, and a thorough review of medical records was conducted.

## Results

The gender split was roughly even (6/13 women and 7/13 men). Twelve patients were Caucasian, and one was Asian. Our cohort included four patients diagnosed with small cell carcinoma (smCC; 30.8%), two with large cell (15.4%), two with mixed small cell and adenocarcinoma (15.4%), two with low-grade neuroendocrine carcinoma (15.4%), one with mixed smCC and squamous differentiation (7.7%), one with high-grade neuroendocrine carcinoma arising within ONB (7.7%), and one with intermediate-grade NEC (7.7%). Disease staging was retrospectively determined for the time of diagnosis according to the criteria in the American Joint Committee on Cancer Staging Manual, 7th edition,<sup>10</sup> and included 11 T4b (84.6%), 1 T3 (7.7%), and 1 T1 (7.7%). In addition, one patient (7.7%) had evidence of nodal disease in the neck at the time of diagnosis, one (7.7%) had unknown nodal status, and one (7.7%) had evidence of distant metastasis to the lung at the time of diagnosis. Demographic, pathology, staging, treatment, and survival data are given in ►Table 1.

Overall estimated survival for our cohort was 74.6% at 2, 3, and 5 years (►Fig. 1). Given the survival more than 50%, no median was calculated. The three patients' deaths prior to 5 years occurred at 6.3, 11.5, and 18.6 months, and one patient died almost 9 years after initial diagnosis with disease.

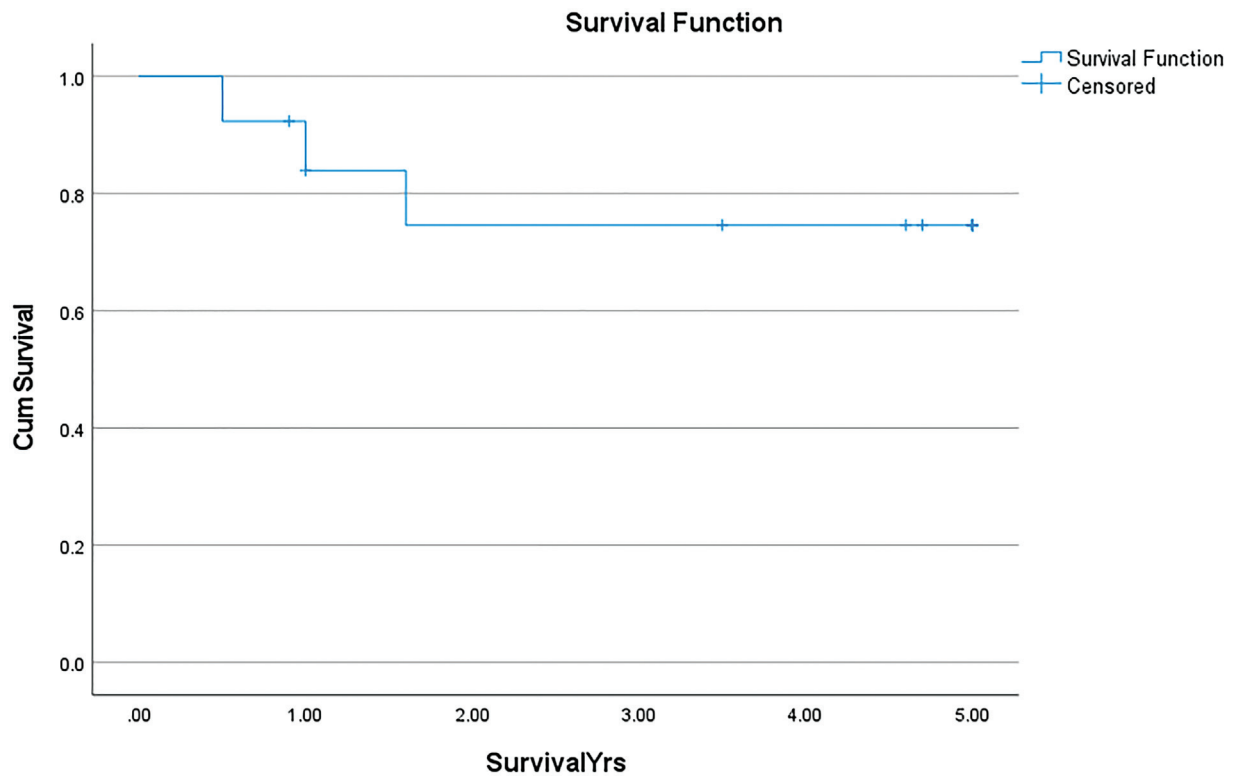
Ten of 13 (76.9%) patients had a diagnosis of high-grade neuroendocrine carcinoma, while one (7.7%) had intermediate grade and two (15.4%) had low grade. As the samples of low- and intermediate-grade tumors were small, these categories were combined for the purpose of analysis. All three patients with low- or intermediate-grade cancer survived more than 10 years from their initial diagnosis, with a median survival of 11.6 years, and are currently alive. All four patients who have died had high-grade carcinoma, and estimated overall 5-year survival for patients with high-grade carcinomas was 65.6%. The difference in survival between patients with low- and high-grade cancers was not statistically significant (chi-square test = 1.17; critical value = 3.84;  $p = 0.279$ ). Survival by tumor grade is shown in ►Fig. 2.

Age at diagnosis ranged from 14 to 75 years. The mean age was 58 years, and the median was 50 years. Incidence generally increased with age, with more than half of our patients diagnosed after the age of 50 years and a peak incidence in the fifth decade. However, age does not appear to correlate directly with disease course. Four of 13 patients (30.8%) were under the age of 40 years at initial diagnosis. Mean estimated survival of these patients was 2.95 years

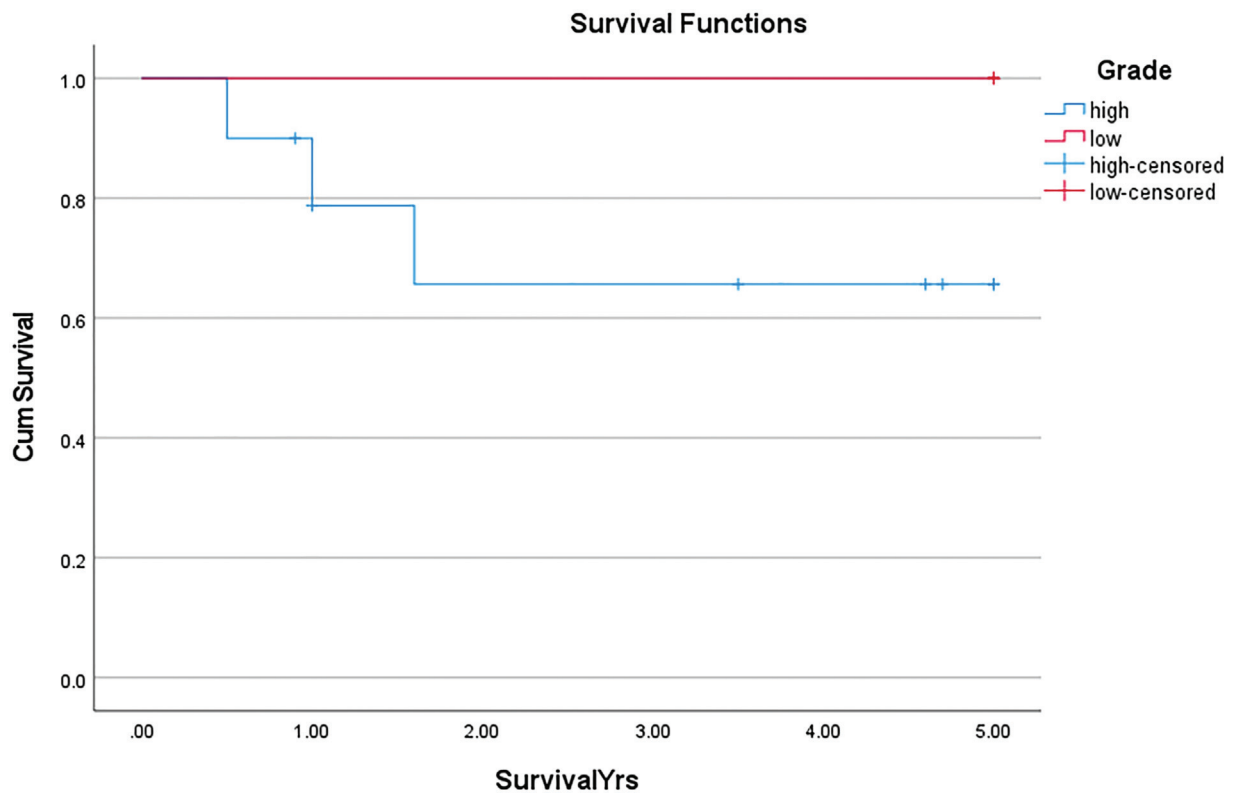
**Table 1** Demographics, pathology, treatment, staging, and survival raw data

Age at dx	Sex	Date of dx	Tumor pathology (grade)	Prim Tx = Primary Treatment	Op	Marg	Age at death	AJCC stage at dx	Tobacco	Chemo	XRT (with dose in Gy, if known)	Pattern of recurrence	Time to death after dx
14	M	January 10, 2014	Mixed smCC and adenocarcinoma (high)	Surg	Y	+	15	T4bNXM0	N	Cis/etoposide, topotecan, irinotecan/temodar, pazopanib, crizotinib	Y (58 to primary; 64 at failure)	N/A	18.6 mo (DWD)
46	M	June 24, 2014	smCC (high)	CRT	Y	-	N/A	T4bN0M0	N	Cis/etoposide, carbo/etoposide	Y (70)	N/A	Alive (ADF)
75	F	March 17, 2020	Large-cell NEC (high)	CRT	Y	-	N/A	T3N0M0	Y	carbo/etoposide/atezolizumab	Y (68)	N/A	Alive (ADF)
28	M	May 9, 2017	Large-cell NEC (high)	CRT	Y	-	29	T4bN0M0	Y	Cis/carbo/etoposide, carbo/irinotecan	Y (70)	N/A	11.5 mo (DWD)
65	F	July 5, 2016	smCC (high)	Surg	Y	-	N/A	T1N0M0	N	Unknown	Y	Regional	Alive (ADF)
29	M	October 9, 2017	smCC (high)	CRT	N	N/A	N/A	T4bN0M0	Y	cis/etoposide	Y (43.5)	N/A	Alive (ASU)
60	F	April 13, 2011	Mixed smCC and squamous cell carcinoma (high)	Surg	Y	-	69	T4bN0M0	Y	Cis, carbo/paclitaxel/nivolumab	Y (60 to primary, 60 for recurrence, 21 at wide failure)	Local and distant	107.3 mo (DWD)
69	M	August 17, 2015	Mixed smCC and adenocarcinoma (high)	CRT	Y	-	70	T4bN0M0	Y	Carbo/etoposide	Y (70)	N/A	6.3 mo (DSU)
37	F	August 30, 2016	High-grade NEC arising in ONB (high)	CRT	Y	-	N/A	T4bN0M0	N	Cis/etoposide	Y (70)	N/A	Alive (ADF)
59	F	September 17, 2009	Low-grade NEC (low)	Surg	Y	+	N/A	T4bN0M0	N	Octreotide	N	N/A	Alive (AWD)
63	M	August 20, 2009	Intermediate-grade NEC (intermediate)	CRT	N	N/A	N/A	T4bN0M0	Y	carbo/etoposide	Y (70)	N/A	Alive (ASU)
51	F	January 7, 2005	Low-grade NEC (low)	Surg	Y	+	N/A	T4bN0M0	N	None	Y	N/A	Alive (ASU)
58	M	May 1, 2020	smCC (high)	Chemo	N	N/A	N/A	T4bN0M1	Y	Carbo/etoposide/atezolizumab with maintenance atezolizumab	N	N/A	Alive (AWD)

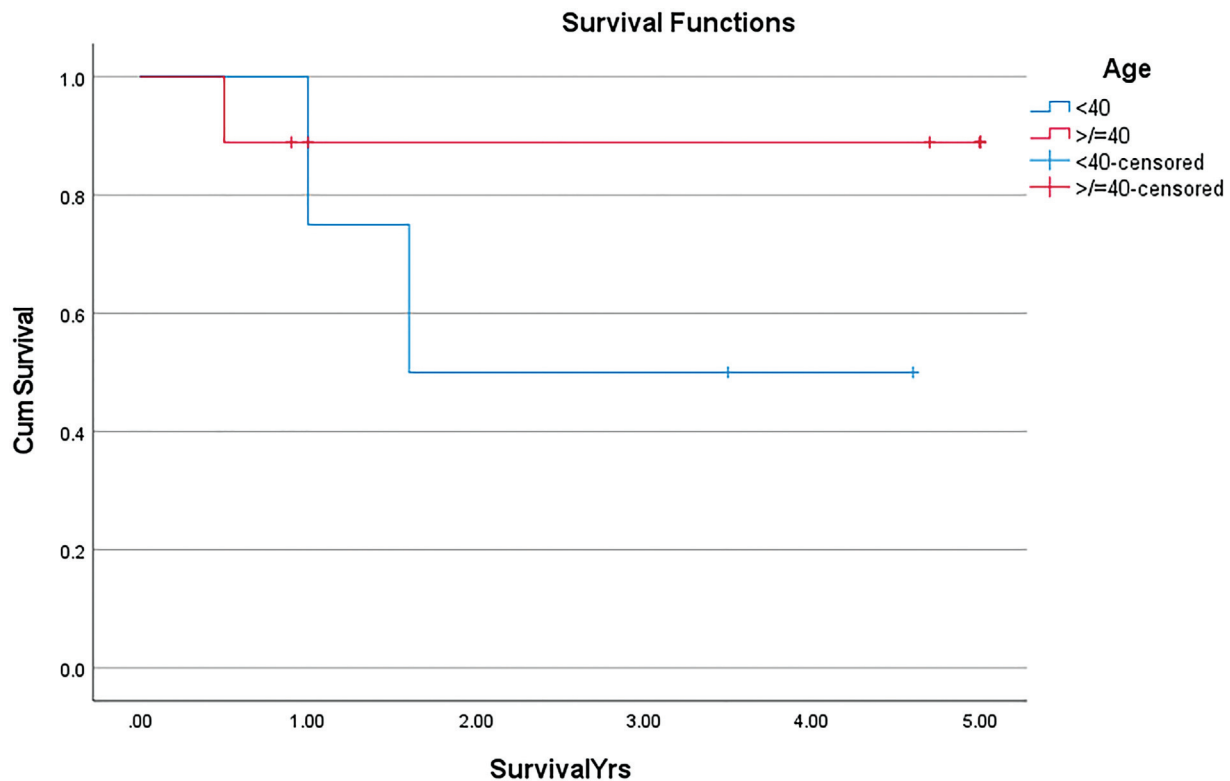
Abbreviations: ADF, alive, disease-free; AJCC, American Joint Committee on Cancer; ASU, alive, status unknown; AWD, alive with disease; carbo, carboplatin; cis, cisplatin; CRT, chemoradiation therapy; DSU, dead, status unknown; DWD, dead with disease; dx, diagnosis; Marg, margin status; N, no; N/A, not available; NEC, neuroendocrine carcinoma; ONB, olfactory neuroblastoma; Op, received operative treatment; smCC, small cell carcinoma; Surg, primary surgical resection; XRT, radiation therapy; Y, yes.



**Fig. 1** Overall survival.



**Fig. 2** Overall survival by tumor grade.



**Fig. 3** Overall survival by age.

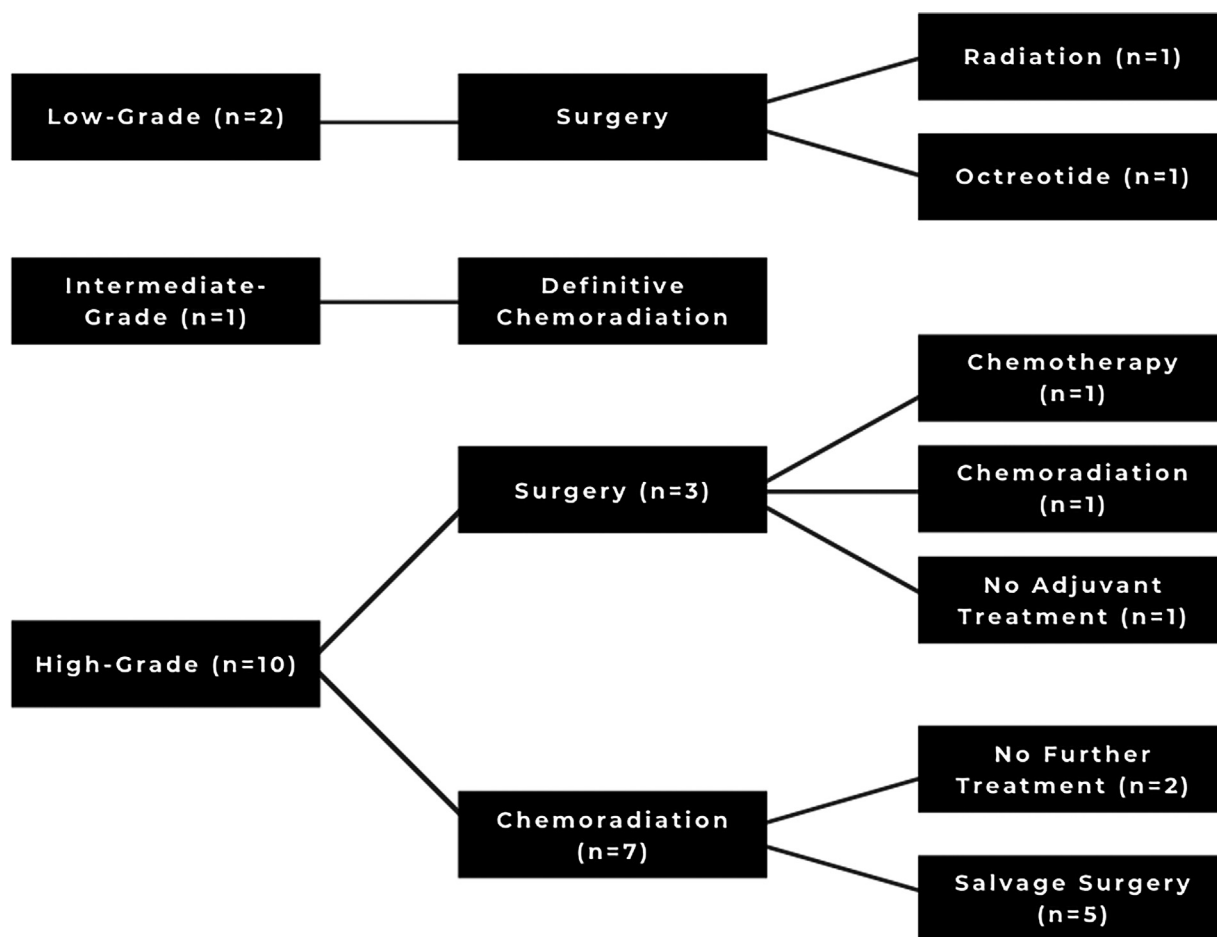
(95% confidence interval [CI], 1.32–4.58 years), and only two remain alive. Patients diagnosed at 40 years or older had a mean survival of 4.50 years (95% CI, 3.58–5.42 years), and seven of these nine patients remain alive. The difference in survival between patients diagnosed at or above 40 years and those diagnosed before 40 years was not statistically significant (chi-square test = 1.49; critical value = 3.84;  $p = 0.223$ ). The age-related survival curves are shown in ►**Fig. 3**.

Five of 13 patients (38.5%) had primary surgery for their tumor as either definitive treatment or part of a multimodal approach—three high-grade and two low-grade tumors. Three of these five patients (60.0%) had known positive surgical margins (two low grade and one high grade) and underwent adjuvant therapy. Neoadjuvant radiation was recommended to one of these patients with low-grade carcinoma because definitive, margin-negative resection was thought to be unlikely. This patient proceeded with primary surgical resection at another institution and returned to UM for adjuvant radiation. The other patient with low-grade carcinoma received octreotide, while the patient with high-grade carcinoma received chemoradiation therapy (CRT). Of the two patients with negative margins, one patient had surgery alone as definitive therapy (although was later found to have nodal disease in the neck), while the other received adjuvant radiation therapy. Seven patients (53.8%) received primary CRT, and the remaining patient received chemotherapy alone. All eight of these patients received cis- or carboplatin and etoposide. Treatment approach is outlined in ►**Figure 4**.

Five of the seven patients who completed primary CRT had residual tumor. All had high-grade carcinoma and underwent salvage resection with negative margins. Four of

these five had residual high-grade tumor in the specimen, while the pathology for the fifth showed residual ONB, with no remaining high-grade neuroendocrine carcinoma from the initial diagnosis. Three of these five (60%) are alive without disease, now 1.0, 4.6, and 6.8 years after diagnosis. No patients with low- or intermediate-grade tumors had recurrence after being thought to be disease free. Two patients (20.0%) with high-grade carcinoma experienced such a recurrence. Both had primary surgical resection with negative margins. One received no adjuvant therapy and developed disease in the submandibular gland 3 months after initial diagnosis. This was managed with bilateral levels I to IV selective neck dissection and CRT, and the patient remains alive without disease. The other patient received adjuvant radiation for their primary tumor, and the recurrence was found 6.7 years after initial diagnosis. Original pathology for this tumor described a “poorly differentiated carcinoma with squamous and neuroendocrine differentiation,” and review for this study revealed mixed squamous cell carcinoma (SCC) and smCC, while the recurrence only appeared to have squamous differentiation. This patient received cisplatin and radiation therapy for this recurrence, but subsequently failed distantly 1 year later. This distant spread was treated with CRT, but the patient recently died. All patients with high-grade SNEC who received radiation therapy received radiation to their upper neck and retropharyngeal lymph nodes.

Nine of 13 patients (69.2%) remain alive. Follow-up time for these patients ranges from 10.8 months to more than 10 years. Four of these nine patients have been lost to follow-up at our institution; however, all have more recently sought



**Fig. 4** Treatment approach flow diagram.

unrelated care elsewhere at some point between August 2019 and March 2021. As of their last visit, three were disease free and the other had stable but persistent disease. An additional internet search for obituaries and review of SSDI suggests all four remain alive.

## Discussion

SNEC is a rare disease that is difficult to treat due to both its diverse biology and limited data. While our approach to treating these tumors has evolved over time as data have become available, the mainstay has been aggressive, multimodal therapy, and the survival in our cohort (74.6% 5-year overall survival) has been higher than similar reports (► **Table 2**). These results are particularly notable when considering that 84.6% of our patients presented with stage T4 tumors and 76.9% of our patients had high-grade pathology. While some authors have distinguished smCC (previously thought to be the only high-grade SNEC) from other SNECs,<sup>7,11–13</sup> and others have focused exclusively on smCC, our cohort included patients with all types and grades of SNEC.

This is important because these high-grade cancers are more aggressive than other types of SNECs, and smCC has consistently been found to have lower survival than other types of SNEC.<sup>5,14–17</sup> For these tumors, surgical resection

may not be the ideal treatment. Not only can margins be difficult to clear, as they often extend well beyond gross tumor margins. In addition, their aggressive nature and high propensity for metastatic spread mean that regional and distant disease, even if occult at the time of diagnosis, is more likely, and should be considered in treatment planning. This particular point was seen in one of our patients with smCC who had primary surgery with negative margins but was later found to have cancer in the submandibular gland that required further surgical management and CRT.

Interestingly, we identified four patients in our cohort with mixed pathology: two with mixed smCC and adenocarcinoma, one with mixed smCC and SCC, and one with a high-grade SNEC arising within an ONB. As only the smCC/SCC tumor was properly identified at the time of diagnosis, the mixed smCC and adenocarcinoma pathology did not affect our approach to treating these patients, but it is important to note that both of these patients had aggressive disease and died less than 2 years after diagnosis. These mixed tumors are still not widely reported, but our poor outcomes in these cases are consistent with previous reports.<sup>18</sup>

Over the past 15 years, our institution has adapted our treatment paradigm based on the most current evidence, but we have consistently treated these tumors aggressively with multimodal therapy. This philosophy is consistent with other

**Table 2** Comparison of outcomes

Case series	UM	Turri-Zanoni et al <sup>11</sup>			Faisal et al <sup>15</sup>	Kuan et al <sup>16</sup>	Likhacheva et al <sup>6</sup>	Mitchell et al <sup>8</sup>	Wang et al <sup>21</sup>	van der Laan et al <sup>5</sup>
Year	2020	2017		2018	2017	2011	2012	2008	2016	
NEC types in study	SNEC (including smCC)	SNEC (including smCC)	Mixed	smCC	smCC	SNEC	SNEC	SNEC/smCC combined	SNEC	smCC
No. of patients	13	22	5	8	82	20	28	10	127	115
% treated surgically	76.9%	100%	100%	25.0%	62.2%	75.0%	46.4%	90.0%	70.0% <sup>a</sup>	56.9% <sup>b</sup>
Local control (%)	-	41.7% (3 y)	26.6% (3 y)	-	-	75% (3 y)	-	80% (5 y)	-	-
Alive, disease-free	30.8% follow-up range overall (6.3–138.2 mo)	27.3% (1–163 mo)	20% (11–29 mo)	62.5% (38 mo median follow-up)	-	55% (13–172 mo)	-	50% (11–206 mo)	-	-
Alive with disease	15.4%	13.6%	20.0%	-	-	0%	-	10%	-	-
Alive, status unknown	23.1%	-	-	-	-	-	-	-	-	-
Dead with disease	23.1%	54.5%	60.0%	-	-	30%	-	40%	-	-
Dead of other cause	-	-	-	-	-	15%	-	-	-	-
Dead, status unknown	7.7%	4.5%	0.0%	-	-	-	-	-	-	-
Overall survival	74.6 (5 y)	42.6 (5 y)	40.0 (3 y)	-	33.4 (5 y)	-	66.9 (5 y), 43.8% DFS (5 y)	70.0 (5 y)	70.2% (5 y DSS)	46.1% (5 y DSS)

Abbreviations: DFS, disease-free survival; DSS, disease-specific survival; NEC, neuroendocrine carcinoma; UIM, University of Michigan; smCC, small cell carcinoma; SNEC, sinonasal neuroendocrine carcinoma.

<sup>a</sup>Treatment only known for 90 patients.

<sup>b</sup>Treatment only known for 109 patients.



studies that have suggested the efficacy of multimodal therapy.<sup>6,8,13,19</sup> In particular, a meta-analysis published by van der Laan et al in 2016 demonstrated that surgery has a beneficial effect on survival in both SNEC and smCC, with smCC responding best to a combination of surgery and radiotherapy. Although surgery as monotherapy produced the highest overall 5-year disease-specific survival (DSS; 83.3%) among patients with SNEC, their analysis did not show statistically significant differences in outcomes between this group and those who underwent multimodal therapy including surgery.<sup>5</sup> This was consistent with results reported by Kuan et al, who found surgery was the only independent predictor of survival in their cohort of 82 smCC patients in the Surveillance, Epidemiology, and End Results database.<sup>16</sup> It is important to note that these analyses could not distinguish the timing of therapies (i.e., adjuvant vs. neoadjuvant chemotherapy and radiation and primary vs. salvage surgery) given the limitations of their data sources. Our current approach is to treat high-grade SNEC with CRT (with or without induction chemotherapy) and follow-up with a biopsy for any residual signal abnormality. Further treatment, if necessary, is determined by the resulting pathology. For low-grade tumors, primary surgical resection is attempted with adjuvant radiation, if indicated by pathology, and consideration for octreotide for recurrent or persistent disease. While there are little data on its effectiveness as an antiproliferative in SNEC, octreotide, a somatostatin analog, has been shown to be an effective antiproliferative treatment in gastrointestinal neuroendocrine tumors,<sup>20</sup> and we have used it to effectively manage an incompletely resected low-grade (carcinoid) tumor in one of our patients for more than 10 years. We have attempted to stop this treatment, but the patient reported progression of symptoms, and treatment was restarted. Since then, there has been no evidence of disease progression, which suggests octreotide can play a role in managing persistent low-grade SNEC.

Particle beam radiotherapy has shown promise in both primary and adjuvant treatments of skull base malignancies, with the primary advantage over conventional photon intensity-modulated radiation therapy (IMRT) being the sharp Bragg peak in the dose delivery that allows more precise dosing and potentially limiting toxicity to critical adjacent structures. To date, there is a paucity of data on particle beam radiation with regard to SNEC specifically, but we anticipate that this technology may supplant conventional IMRT as the primary radiation modality for all skull base malignancies.

Our overall results appear most similar to those presented by Wang et al,<sup>21</sup> even though only 30.0% of their patients had stage T4 tumors at diagnosis compared with 84.6% in our population. Despite this, we report a similar overall 5-year survival and percentage of patients alive without disease. Further, our survival rate exceeds the 5-year DSS rate reported by van der Laan et al for SNEC patients, which is particularly notable given that this meta-analysis separated smCC cases, which had a 5-year DSS rate of only 46.1%. Their analysis did show improved outcomes for patients reported

after 2006, which suggests a positive effect from improved diagnostic and treatment modalities over time.<sup>5</sup> While the reports referenced here were all published after that date, it is unknown when these patients were diagnosed and treated. Since only one of our patients was diagnosed prior to 2006 (and then only in 2005), it is possible that the relative recency of our cohort is contributing to the increased survival we observed.

Interestingly, among our cohort, recurrent and persistent disease were not associated with particularly poor outcomes. In fact, all patients with persistent high-grade cancers after primary CRT underwent negative-margin salvage resection, and 60% remain alive and disease free. This suggests that prognosis after recurrence may not be as poor as once thought, and surgical salvage is a feasible treatment option, even for those with high-grade carcinomas. However, it is also true that patients with persistent tumor accounted for 75% of all observed deaths in our cohort, with these deaths occurring within 19 months of diagnosis. This is not entirely unexpected, as patients with persistent disease likely had the most aggressive tumors, and in fact, two had mixed pathology, but our salvage rate suggests more optimism for these patients than previously believed. It is also important to note that our results are somewhat limited by our small sample size, particularly among those with low- and intermediate-grade tumors. While we did not find a statistically significant difference in the overall survival between patients with low/intermediate- and high-grade cancers, this is likely due to the limited power resulting from the rarity of the disease and the size of our cohort.

Despite our high 5-year survival, only 30.8% of our patients are known to be alive without disease at the time of this writing, which is at the lower end of the range reported by other authors (0–62.5% for smCC and 20.0–85.7% for SNEC).<sup>6,11,13,15,22,23</sup> Three of our 13 patients have been lost to follow-up. At the time of last visit, one had stable but persistent disease, and the others were disease free. Outside records and SSDI review suggest all three remain alive, but disease status is unknown, contributing to a lower disease-free rate.

## Conclusion

SNEC is a very rare, complex, and variable disease that is defined by a diverse range of pathologies and tumor behaviors. With an aggressive, multimodal treatment strategy, outcomes in our institution have been better than many recent case series and reviews. As with most of the existing case series, our cohort is small, and further studies will be required to determine an optimal treatment methodology for these patients; however, our approach of surgical resection as primary therapy for low-grade tumors and primary CRT for high-grade SNEC has been successful, and could indicate hope for improved survival among these patients.

## Conflict of Interest

None declared.



## References

- 1 Silva EG, Butler JJ, Mackay B, Goepfert H. Neuroblastomas and neuroendocrine carcinomas of the nasal cavity: a proposed new classification. *Cancer* 1982;50(11):2388–2405
- 2 Frierson HF Jr, Mills SE, Fechner RE, Taxy JB, Levine PA. Sinonasal undifferentiated carcinoma. An aggressive neoplasm derived from schneiderian epithelium and distinct from olfactory neuroblastoma. *Am J Surg Pathol* 1986;10(11):771–779
- 3 Bell D, Hanna EY, Weber RS, et al. Neuroendocrine neoplasms of the sinonasal region. *Head Neck* 2016;38(S1):E2259–E2266
- 4 Choi KY, Amit M, Tam S, et al. Clinical implication of diagnostic and histopathologic discrepancies in sinonasal malignancies. *Laryngoscope* 2020
- 5 van der Laan TP, Iepma R, Witjes MJH, van der Laan BFAM, Plaat BEC, Halmos GB. Meta-analysis of 701 published cases of sinonasal neuroendocrine carcinoma: The importance of differentiation grade in determining treatment strategy. *Oral Oncol* 2016;63:1–9
- 6 Likhacheva A, Rosenthal DI, Hanna E, Kupferman M, Demonte F, El-Naggar AK. Sinonasal neuroendocrine carcinoma: impact of differentiation status on response and outcome. *Head Neck Oncol* 2011;3(01):32
- 7 Rosenthal DI, Barker JL Jr, El-Naggar AK, et al. Sinonasal malignancies with neuroendocrine differentiation: patterns of failure according to histologic phenotype. *Cancer* 2004;101(11):2567–2573
- 8 Mitchell EH, Diaz A, Yilmaz T, et al. Multimodality treatment for sinonasal neuroendocrine carcinoma. *Head Neck* 2012;34(10):1372–1376
- 9 El-Naggar AK, Chan JKC, Grandis JR, Takata T, Slootweg PJ, eds. WHO Classification of Head and Neck Tumours. 4th ed. International Agency for Research on Cancer. Lyon, France: 2017
- 10 Edge SB, Byrd DR, Compton CC, Fritz AG, Greene FL, Trotti A, (editors). *AJCC cancer staging manual*, 7th edition. France: Springer; 2010
- 11 Turri-Zanoni M, Maragliano R, Battaglia P, et al. The clinicopathological spectrum of olfactory neuroblastoma and sinonasal neuroendocrine neoplasms: Refinements in diagnostic criteria and impact of multimodal treatments on survival. *Oral Oncol* 2017;74:21–29
- 12 Patel TD, Vazquez A, Dubal PM, Baredes S, Liu JK, Eloy JA. Sinonasal neuroendocrine carcinoma: a population-based analysis of incidence and survival. *Int Forum Allergy Rhinol* 2015;5(05):448–453
- 13 van der Laan TP, Bij HP, van Hemel BM, et al. The importance of multimodality therapy in the treatment of sinonasal neuroendocrine carcinoma. *Eur Arch Otorhinolaryngol* 2013;270(09):2565–2568
- 14 Perez-Ordóñez B, Caruana SM, Huvos AG, Shah JP. Small cell neuroendocrine carcinoma of the nasal cavity and paranasal sinuses. *Hum Pathol* 1998;29(08):826–832
- 15 Faisal M, Haider I, Adeel M, Waqas O, Hussain R, Jamshed A. Small cell neuroendocrine carcinoma of nose and paranasal sinuses: the Shaikat Khanum Memorial Cancer Hospital experience and review of literature. *J Pak Med Assoc* 2018;68(01):133–136
- 16 Kuan EC, Alonso JE, Tajudeen BA, Arshi A, Mallen-St Clair J, St John MA. Small cell carcinoma of the head and neck: a comparative study by primary site based on population data. *Laryngoscope* 2017;127(08):1785–1790
- 17 VanKoeveering KK, Sabetsarvestani K, Sullivan SE, Barkan A, Mierzwa M, McKean EL. Pituitary dysfunction after radiation for anterior skull base malignancies: incidence and screening. *J Neurol Surg B Skull Base* 2020;81(01):75–81
- 18 La Rosa S, Furlan D, Franzi F, et al. Mixed exocrine-neuroendocrine carcinoma of the nasal cavity: clinico-pathologic and molecular study of a case and review of the literature. *Head Neck Pathol* 2013;7(01):76–84
- 19 López F, Lund VJ, Suárez C, et al. The impact of histologic phenotype in the treatment of sinonasal cancer. *Adv Ther* 2017;34(10):2181–2198
- 20 Stueven AK, Kayser A, Wetz C, et al. Somatostatin analogues in the treatment of neuroendocrine tumors: past, present and future. *Int J Mol Sci* 2019;20(12):3049
- 21 Wang C-P, Hsieh C-Y, Chang Y-L, et al. Postirradiated neuroendocrine carcinoma of the sinonasal tract. *Laryngoscope* 2008;118(05):804–809
- 22 Chang C-F, Li W-Y, Shu C-H, Ho C-Y. Sino-nasal neuro-endocrine carcinoma. *Acta Otolaryngol* 2010;130(03):392–397
- 23 Austin JR, Cebrun H, Kershnik MM, et al. Olfactory neuroblastoma and neuroendocrine carcinoma of the anterior skull base: treatment results at the m.d. Anderson cancer center. *Skull Base Surg* 1996;6(01):1–8