



How to Choose Between the Transolecranon and Triceps-Reflecting Approaches to Treat Distal Humerus Fractures in Adults: A Prospective Study*

Como escolher entre as abordagens transolecraniana e por reflexão do tríceps para tratar fraturas distais do úmero em adultos: Um estudo prospectivo

Kalom Jamoh¹  Gyneshwar Tonk²

¹Department of Orthopedics, ESIC-PGIMSR, New Delhi, India

²Department of Orthopedic, LLRM Medical College, Meerut, Uttar Pradesh, India

Address for correspondence Kalom Jamoh, MS Orthopedic, Assistant Professor, Department of Orthopedics, ESIC-PGIMSR, Basaidarapur, New Delhi, India (e-mail: kalom19jamoh@gmail.com).

Rev Bras Ortop 2022;57(2):301–307.

Abstract

Objective To choose an appropriate posterior approach for distal humerus fractures in adults.

Methods Fifty patients with distal humerus fractures were analyzed prospectively. The fractures were classified using the Arbeitsgemeinschaft für Osteosynthesefragen/Orthopaedic Trauma Association (AO, Working Group for Bone Fusion Issues, in German/OTA) classification. The patients were divided into group A and group B. Olecranon osteotomy (the transolecranon approach) was performed in 30 patients, and the triceps-reflecting approach was used in 20 patients. The functional results were evaluated using the Mayo Elbow Performance Score (MEPS) and the Disabilities of the Arm, Shoulder and Hand (DASH) questionnaire.

Results The average operative time was of 92.62 ± 8.73 minutes for group A, and of 78.63 ± 7.02 minutes for group B, ($p < 0.01$), and the average blood loss was of 222.78 ± 34.93 mL for group A, and of 121.61 ± 19.85 mL for group B, ($p < 0.01$), which were statistically significant. The mean scores on the MEPS and DASH of both groups were found to be insignificant. Complications like infection, neurapraxia and soft tissue irritation were observed more in group A.

Conclusion The triceps-reflecting approach results in a shorter operative time, a lower levels of blood loss, and a low rate of complications, and olecranon osteotomy provides better accuracy in terms of articular reduction. But there were no significant

Keywords

- ▶ humeral fractures
- ▶ olecranon process
- ▶ osteotomy

* Study developed by the Department of orthopedic ESIC-PGIMSR, New Delhi, India.

received
May 19, 2021
accepted after revision
September 20, 2021
published online
February 9, 2021

DOI <https://doi.org/10.1055/s-0041-1741444>.
ISSN 0102-3616.

© 2021. Sociedade Brasileira de Ortopedia e Traumatologia. All rights reserved.
This is an open access article published by Thieme under the terms of the Creative Commons Attribution-NonDerivative-NonCommercial-License, permitting copying and reproduction so long as the original work is given appropriate credit. Contents may not be used for commercial purposes, or adapted, remixed, transformed or built upon. (<https://creativecommons.org/licenses/by-nc-nd/4.0/>)
Thieme Revinter Publicações Ltda., Rua do Matoso 170, Rio de Janeiro, RJ, CEP 20270-135, Brazil

differences between the two groups regarding the functional outcome. Therefore, we have proposed a new classification that is a modification of the AO/OTA classification: type 1 includes AO grades 13A to C2 (B3 excluded); and type 2, AO 13C3. For type-1 fractures, the triceps-reflecting approach may be considered, and, for type-2 fractures, olecranon osteotomy.

Resumo

Objetivo Escolher uma abordagem posterior adequada para fraturas distais do úmero em adultos.

Métodos Cinquenta pacientes com fraturas distais do úmero foram analisados prospectivamente. As fraturas foram classificadas por meio da classificação Arbeitsgemeinschaft für Osteosynthesefragen/Orthopaedic Trauma Association (AO/OTA). Os pacientes foram divididos em grupo A e grupo B. A osteotomia olecraniana (abordagem transolecraniana) foi realizada em 30 pacientes, e a abordagem por reflexão do tríceps foi usada em 20 pacientes. Os resultados funcionais foram avaliados por meio do Mayo Elbow Performance Score (MEPS) e do questionário Disabilities of the Arm, Shoulder and Hand (DASH).

Resultados O tempo médio da cirurgia foi de $92,62 \pm 8,73$ minutos para o grupo A, e de $78,63 \pm 7,02$ minutos para o grupo B ($p < 0,01$) e a média da perda sanguínea foi de $222,78 \pm 34,93$ mL no grupo A, e de $121,61 \pm 19,85$ mL no grupo B ($p < 0,01$), os quais foram estatisticamente significativos. As pontuações médias no MEPS e no DASH de ambos os grupos foram consideradas insignificantes. Complicações como infecção, neurapraxia e irritação de tecidos moles foram mais observadas no grupo A.

Conclusão A abordagem por reflexão do tríceps resulta em menor tempo de operação, menor perda de sangue, e baixas taxas de complicações, e a osteotomia olecraniana proporciona uma melhor precisão da redução articular. Mas não houve diferença significativa entre os dois grupos em termos do resultado funcional. Por isso, propusemos uma nova classificação, que é uma modificação da classificação AO/OTA: o tipo 1 inclui os graus AO 13A a C2 (excluído o B3); e o tipo 2, AO 13C3. Para fraturas do tipo 1, a abordagem por reflexão do tríceps pode ser considerada, e, para as fraturas do tipo 2, a osteotomia olecraniana.

Palavras-chave

- fraturas do úmero
- processo olecraniano
- osteotomia

Introduction

Distal humerus fractures comprise approximately 2% of all fractures.¹ They have a bimodal age distribution, with peak incidences occurring in individuals between the ages of 12 and 19 years, usually in males, and in those aged 80 years and older, characteristically more among females. In young adults, the fractures are typically caused by high-energy injuries such as motor vehicle collisions, fall from heights, sports activities, industrial accidents, and firearm injuries.² In elderly individuals, the fractures are usually caused by low-energy injuries like falls to ground.

Distal humerus fractures remain some of the most challenging injuries to treat. They are commonly multi-fragmented and have a complex anatomy, with limited options for internal fixation.^{2,3} The treatment outcomes are often associated with elbow stiffness, instability, and pain. A painless, stable, and mobile elbow joint is desired, as it enables the hand to perform the activities of daily living, most notably personal hygiene and feeding. Therefore, starting with a highly-traumatized distal humerus and finishing with a stable, mobile, and pain-free joint required an intelli-

gent approach. Olecranon osteotomy (also known as the transolecranon approach) is the preferred surgical approach in the literature, and it provides excellent exposure. However, olecranon osteotomy has its own disadvantages, such as delayed union, nonunion, heterotopic ossification, extensor weakness, and prominent hardware. To avoid such complications, an extensor mechanism-sparing, triceps-reflecting, posterior approach to the distal humerus through a midline posterior incision has been suggested by many surgeons.⁴ We conducted the present study to evaluate the outcomes of adult patients with distal humerus fractures treated with the triceps-reflecting and olecranon osteotomy approaches in terms of: accuracy of articular the reduction, operative time, blood loss, functional results, and immediate, early and late complications.

Methods

The present prospective study was hospital-based and conducted after obtaining clearance from the ethical committee (S-1/2019/9159). From December 2017 to March 2021, the records of 50 patients aged between 20 and 70 years were

assessed, and they were divided into two groups: group A was composed of patients submitted to olecranon osteotomy, and group B, of patients submitted to the triceps-reflecting approach. Randomization was performed based on the patient's inpatient number (an even number underwent olecranon osteotomy, and an odd number underwent the triceps-reflecting procedure). All closed fracture and type-I open fractures of the distal humerus on the Gustillo and Anderson classification were included. Cases of type-II and -III open fractures of the distal humerus, patients aged <20 years or >70 years, fractures with associated vascular injuries, uncooperative patients, injuries older than 3 weeks, all pathological distal humeral fractures due to neoplastic or infective pathologies (active or sequelae), and polytrauma patients were excluded.

Following immediate emergency care, hemodynamic stabilization of the patient and proper splinting of the affected limbs was performed. All demographic data of the patients along with contact numbers and addresses was recorded. After thorough history-taking, the patients were first evaluated clinically, to assess whether the injury was closed or open, and the Gustillo-Anderson classification was applied to cases of open fractures. Radiographs of the affected elbow (on the anteroposterior and lateral views) were taken, and the fractures were classified according to the Arbeitsgemeinschaft für Osteosynthesefragen/Orthopaedic Trauma Association (AO, Working Group for Bone Fusion Issues, in German/OTA) classification system. However, in case of doubt regarding the intra-articular extension or the classification of the fracture, a computed tomography (CT) scan of the affected elbow was performed and this assessment was mainly performed for AO/OTA type-C2 fractures.

Operative Procedure

The patient was positioned on lateral decubitus with the affected limb hanging over a bolster, and a tourniquet was applied on the upper arm on both procedures.

Olecranon Osteotomy

A longitudinal midline incision was made on the posterior aspect of the elbow, beginning approximately 7.5 cm to 10 cm above the olecranon and extending 5 cm to 7 cm distally from the tip of the olecranon process. Just above the tip of the olecranon, the incision was curved laterally so that it did not cause necrosis over the weight-bearing tip of the olecranon and moved it away from the devices that are used to fix the osteotomy. The incision was curved medially again so that it overlay the middle of the subcutaneous surface of the ulna. The deep fascia was incised in the midline. The ulnar nerve was palpated in the bony groove behind the medial epicondyle, and the overlying fascia was incised to expose the nerve. The ulnar nerve was fully dissected and protected with an infant feeding tube passed around it. A V-shaped osteotomy with the apex directed distally was performed at the olecranon about 2 cm from its tip by multiple drilling with a guide wire or Kirschner wire (K-wire) followed by osteotome. The bone was divided until it was cut through almost entirely. The soft-tissue attach-

ments of the medial and lateral faces of the olecranon that had been subjected to osteotomy and retracted proximally were released and the triceps from the back of the humerus was elevated and stitched to the skin of the upper arm. A subperiosteal dissection around the medial and lateral borders of the bone enabled the exposure of all surfaces of the distal humerus, except the anterior surface. All of the soft-tissue attachments to bone that could be preserved were retained, particularly during fracture reduction. The ulnar nerve was kept clear off from the operative field during all stages of the dissection. The articular surface of the distal humerus and both pillars were restored, fixation was performed by plates and screws, and the range of motion (ROM) was checked on the operating table. The ulnar nerve was removed from its bed and transposed anteriorly to avoid implant impingement. Repair of the osteotomy was performed with tension band wires (TBWs), with two K-wires and a stainless steel wire (SS-wire) (► Figures 1-4).

Triceps-Reflecting Approach

A 15-cm long lazy S-shaped incision was made on the posterior aspect of the elbow, beginning approximately 7.5 cm to 10 cm above the tip of olecranon, superomedially, and ending about 5 cm inferolaterally to dissect ulnar nerve easily and avoid skin necrosis. After dissecting the ulnar nerve, a gap was made between the triceps and the medial intermuscular septum, and the triceps was elevated to the posterior aspect of the humerus. Laterally, the triceps was separated from the lateral intermuscular septum and posterior humerus in conjunction with the anconeus muscle. By

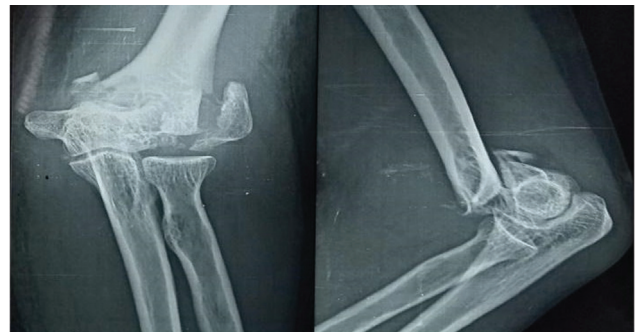

Fig. 1 Case 1: transolecranon approach; preoperative X-ray.

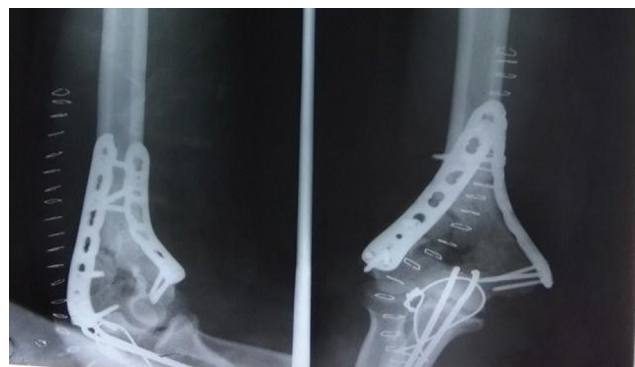

Fig. 2 Case 1: transolecranon approach; postoperative X-ray.

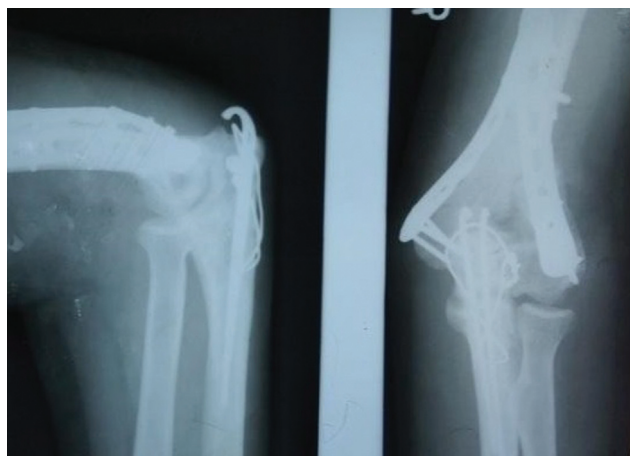


Fig. 3 Case1: transolecranon approach; X-Ray at the last follow-up.

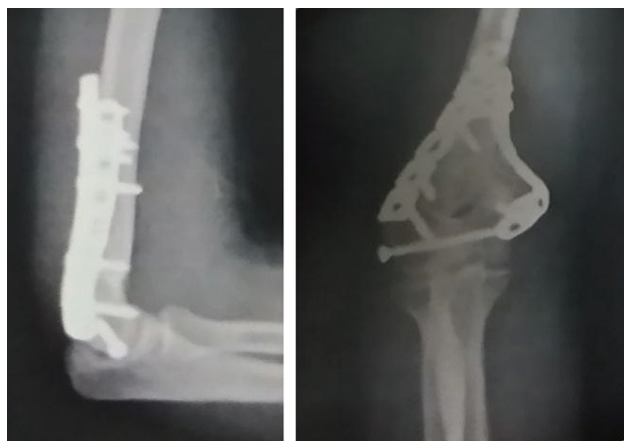


Fig. 6 Case 2: triceps-reflecting approach; X-ray at the last follow-up.

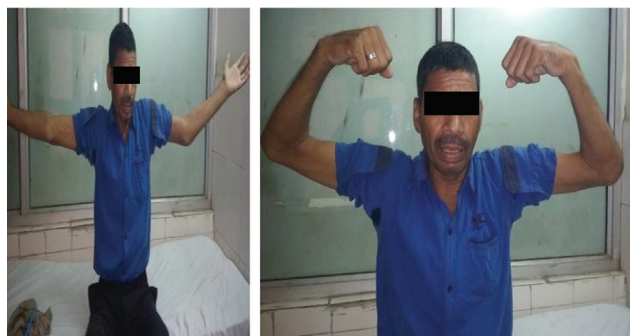

Fig. 4 Case 1: transolecranon approach; range of motion at the last follow-up.

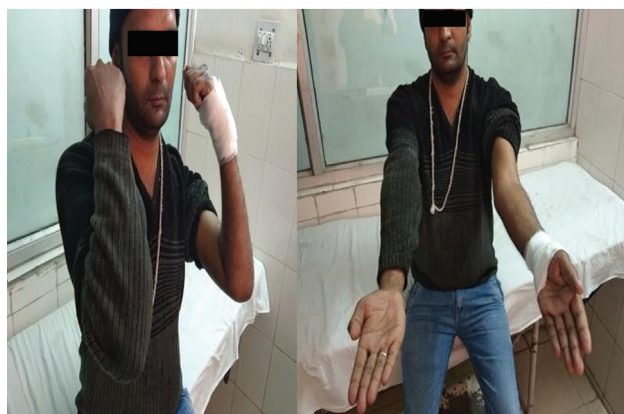

Fig. 7 Case 2: triceps-reflecting approach; range of motion at the last follow-up.

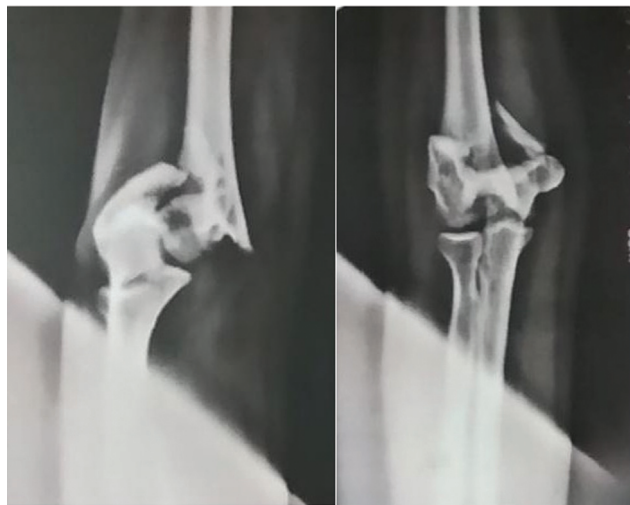

Fig. 5 Case 2: triceps-reflecting approach; preoperative X-ray.

lifting the triceps tendon, the entire distal humerus can be observed, and fixation was performed just as in the olecranon osteotomy procedure (► **Figures 5-7**).

Postoperative Management

The postoperative protocols were the same for both the approaches. Wound inspection was performed on the third

postoperative day, and then the drain was removed. Active extension of the elbow joint was allowed on third postoperative day in both procedures. Postoperative X-rays of the operated elbow (on the anteroposterior and lateral views) were performed. Active-assisted flexion and passive extension exercises of the elbow were started on fifth postoperative day, and free mobilization was allowed. The stitches were removed on twelfth postoperative day and the patients were discharged with proper instructions and called after one week. Subsequently, the patients were followed up at monthly intervals for three months, then three times a month for twelve months. During the follow-up, the patients were examined for pain, late infection, wound dehiscence, paresthesia, fracture union status, and any late complication, such as implant failure, stiffness, and non-union. The ROMs were recorded and the scores on the Disabilities of the Arm, Shoulder and Hand (DASH) and the Mayo Elbow Performance Score (MEPS) were assessed accordingly.

Statistical Analysis

Data on both groups of patients were collected, transferred to a spreadsheet using the Microsoft Excel (Microsoft Corp., Redmond, WA, US) software and studied. The analysis of data was subsequently performed using the Statistical Package for

Table 1 Comparison between the two study groups

| | Group A | Group B | p-value |
|---|----------------|----------------|---------|
| Age (years) | 38.12 ± 15.06 | 34 ± 14.11 | > 0.05 |
| Blood loss (mL) | 222.78 ± 34.93 | 121.61 ± 19.85 | < 0.01 |
| Operative time (minutes) | 92.67 ± 8.73 | 78.63 ± 7.07 | < 0.01 |
| Range of motion (degrees) | 91.04 ± 13.55 | 92.65 ± 19.07 | > 0.05 |
| Mayo Elbow Performance Score | 82.91 ± 11.60 | 86.38 ± 10.45 | > 0.05 |
| Score on the Disabilities of the Arm, Shoulder and Hand questionnaire | 36.00 ± 8.26 | 34.57 ± 9.50 | > 0.05 |

the Social Sciences (SPSS Statistics for Windows, SPSS Inc., Chicago, IL, US) software, version 17.0. Appropriate statistical tests were applied: the Chi-squared test was used for the categorical data, and the Student *t*-test and Mann Whitney test were used for the non-categorical data. Values of $p \leq 0.05$ were considered statistically significant.

Results

A total of 58 patients were operated on, 8 of whom were lost to follow-up. Therefore, the present study included 50 patients (33 [66%] male and 17 [34%] female patients) with ages ranging from 20 to 70 years. Most of the patients (33; 66%) were young adult, and there was a predominance of cases of closed fractures (46 patients; 92%), with only 4 cases (8%) of open fractures. The most common cause of injury was road traffic accident (RTA, in 57.57%), and most fractures were AO/OTA type C2 (n = 21; 42%) (► **Table 1**).

For group B, the average operative time was 78.63 minutes, and, for group A, it was 92.62 minutes, which was statistically significant ($p < 0.01$). Among the patients in group B, the average blood loss was 121.61 mL, and, among those in group A, it was 222.78 mL which was also statistically significant ($p < 0.01$). In the assessment according to the MEPS, the outcomes were slightly better for group B when compared to group A, but without statistically significant differences (► **Table 2**). In the assessment according to the DASH, the outcomes were slightly better for group A when compared to group B, without statistically significant differences either. The rate of complications was higher among group A compared to group B.

Complications

Infection was the most common complication (9 cases) observed in the present study, mostly among group A, followed by ulnar nerve neurapraxia (2 cases), heterotopic

Table 2 Outcomes according to the Mayo Elbow Performance Score

| | Excellent (≥ 90) | Good (75-89) | Fair (60-75) | Poor (< 60) |
|---------|------------------|--------------|--------------|-------------|
| Group A | 24 (80%) | 5 (16%) | 1 (4%) | 0 |
| Group B | 15 (75%) | 5 (25%) | 0 | 0 |

Table 3 Complications observed in the sample

| | Group A | Group B |
|--|---------|---------|
| Soft-tissue infection | 8 | 1 |
| Ulnar nerve neurapraxia | 2 | 0 |
| Heterotopic ossification | 0 | 1 |
| Implant prominence | 1 | 0 |
| Delayed union of the olecranon process | 0 | 0 |
| Radial nerve neurapraxia | 0 | 0 |

ossification (1 case), and implant prominence (1 case) (► **Table 3**).

Discussion

The functional outcome may vary in distal humerus fractures due to the variable pattern of fractures. Because of the low incidence of this type of fracture, only a few series, with a considerable number of cases, nevertheless, have been reported. Most cases are of intra-articular fractures, and it is generally accepted that open reduction and internal fixation (ORIF) is the standard treatment, to achieve soft tissue healing without infection, restoration of the metaphyseal bone stock, and a stable, painless, and mobile joint.⁵

Poor long-term functional outcomes are the most commonly associated with decreased ROM, because of the stiffness caused by prolonged immobilization. Therefore, the key is the stable fixation to enable early movements of the elbow joint postoperatively.⁶ Many surgical approaches have been described for the fixation of distal humerus fractures, such as olecranon osteotomy, the triceps-reflecting anconeus pedicle (TRAP) approach, triceps splitting, and the triceps-reflecting or paratricipital approaches.⁷ The quality of the evidence in the literature is either level III or level IV. The experience reported with the use of the triceps-reflecting approach to treat distal humerus fracture in adult patients is little. To our knowledge, only a few studies^{8,9} have compared the functional outcomes of the triceps-reflecting approach with olecranon osteotomy for the ORIF management of distal humerus fractures. Hence, the present study was conducted to compare these two approaches in terms of optimal exposure and functional outcome.

The present study included 50 patients with AO/OTA types A, B, and C fractures of the distal humerus: 30 were treated by olecranon osteotomy (group A), and 20, by the triceps-reflecting approach (group B).

The average age of the sample was 43.03 ± 12.05 years. The mean ages of groups A and B was of 43.23 ± 15.09 and 35.83 ± 14.01 respectively, which were similar. Most patients were male: 33 (66%). There was male predominance in other studies too, such as the one conducted by Bhandary et al.¹⁰ The higher male incidence may reflect the tendency of men to perform more outdoor activities, making them more prone to injury.

In the present study, the incidence of open fractures was of 8% ($n=4$), and all of these patients underwent definitive fixation within a week, 3 by olecranon osteotomy and 1 by the triceps-reflecting approach. The incidence of open fractures observed was comparable to that of previous studies conducted by Ek et al.¹¹ and Ali et al.¹²

In the present study, 21 (42%) patients had type-C2 fractures, 13 (26%), type-C1, and 10 (20%), type-C3. The 6 (12%) remaining cases were of type-A and -B fractures. In total, 5 patients with type-C1, 9 patients with type-C2 and 7 patients with type-C3 fractures were included in group A, and 8 patients with type-C1, 12 patients with type-C2, and 3 patients with type-C3 fractures were included in group B. Ek et al.¹¹ reported 5 out of 9 (55.55%) cases in his series as AO/OTA type-C2 fractures. Ali et al.¹² and Zhang et al.,¹³ also reported a high incidence of AO/OTA type-C2 fractures of the distal humerus: 11 out of 22 (50%) and 25 out of 67 (37.3%) respectively.

In the present study, we have observed that the triceps-reflecting is a fast and easy-to-perform (if the surgeon is experienced) approach that makes it possible to achieve good reduction in fractures with large fragments (AO/OTA types A, B, C1 and C2) and olecranon osteotomy is better for the fixation of type-C3 fractures (its provides a better visualization of the articular surface). The duration of the surgery is directly related to the type of fracture. Wilkinson and Stanley¹⁴ have shown that the difference in visualization between the triceps-reflecting and the olecranon approaches is the lack of visualization of an 11% of the surface in the triceps-reflecting procedure, and that even olecranon osteotomy leaves 43% of the surface unseen. According to Ek et al.,¹¹ the triceps-reflecting approach provides adequate exposure of fracture sites.

The mean operative time in group B (78.63 ± 7.02 minutes) was shorter than in group A (92.62 ± 8.73 minutes), and this difference was statistically significant. Similar results were also observed in a study conducted by Zhang et al.¹³ in the olecranon osteotomy group, it was of 113.89 minutes, and, in the triceps-reflecting, 89.03 minutes, which was also significant statistically.

The assessment of the outcomes of the sample of the present study was performed using two scoring systems: the MEPS, which uses clinical and functional measurements and is filled out by physicians, and the DASH, a questionnaire that assess subjective components of the condition and is filled out by the patients. At present, there are no control or

normal values for the DASH scores. The mean DASH score in the present study was of 35.25. The average DASH score for group A was 36.00, and, for group B, it was of 34.51. The mean DASH score was of 17.9 points in the study conducted by Ek et al.¹¹ The mean MEPS score for the total sample was of 84.64 (range: 75-100) in the present study. For group A, the average MEPS score was of 82.91, and, for group B, 86.31. In the present study, according to the MEPS, the results were graded as excellent in 24 (80%) cases, good in 5 (16%), fair in 1 (4.00%) patient in group A, while, in group B, excellent results were found in 15 (75%) patients, and good results, in 5 (25%) patients. No poor results were obtained in either group. This finding is comparable to that of the study done by Zhang et al.,¹³ which shows mean MEPS scores of 85.56 and 87.71 in the olecranon osteotomy and triceps-reflecting groups respectively.

The average elbow ROM in the present study was of 12.81° of extension and 104.7° of flexion (range: 90° - 130°). At the final follow-up, the mean flexion was of 104.79° (range: 30° - 140°) with a mean extension of 12.81° (range: 0° - 18°). The mean flexion in the group A was of $104.16^\circ \pm 9.16^\circ$, and, for group B, $105.42^\circ \pm 12.99^\circ$; as for the mean extension, it was of $12.87^\circ \pm 2.83^\circ$ in group A, and $12.76^\circ \pm 5.63^\circ$ in group B. Thus, the average ROM was of 91.84° , which is similar to the results of other studies. Ek et al.¹¹ and Fernandez-Valencia et al.¹⁵ reported average ROMs of 90° and 112° respectively.

Blood loss in group B was of 121.61 ± 19.85 mL, which was lower when compared to that of group A: 222.78 ± 34.93 mL which were statistically significant ($p=0.01$) and similar to the results of the study by Zhang et al.¹³

Soft-tissue infection was the most common complication (8 cases) observed in the present study, mostly observed in group A, followed by ulnar nerve neuropathy (2 cases), heterotopic ossification (1 case), and implant prominence (1 case), results similar to those of the study by Chen et al.¹⁶ No cases of non-union and delayed union were observed in the present study, maybe because TBW was used as the final fixation for olecranon osteotomy instead of using 6.5/7-mm partially-threaded screws with SS wire or plate and screws.

Iselin et al.¹⁷ also concluded that the triceps-reflecting approach is a valuable option for ORIF in distal intraarticular humerus fractures, which preserves the normal joint anatomy of the olecranon and avoids the potential complications associated with olecranon osteotomy.

Conclusion

The triceps-reflecting approach results in shorter operating time, lower levels of blood loss, and a low rate of complications. On the other hand, olecranon osteotomy provides better accuracy for articular reduction. There were no significant differences between the two groups in the terms of functional outcome. Therefore, we propose a new classification, a modification of the AO classification, in order to choose an appropriate posterior approach for distal humerus fractures. This new classification is composed of two types: type 1 includes AO-13A, 13B1, 13B2, 13C1 and 13C2, and type 2 includes AO-13C3. For type-1 fractures,

the triceps-reflecting approach may be considered, and for type-2 fractures, olecranon osteotomy.

Financial Support

The present study did not receive financial support. All costs regarding the collection, analysis, interpretation of results and writing were covered exclusively by the authors.

Conflict of Interests

The authors have no conflict of interests to declare.

References

- 1 Court-Brown C, Heckman JD, McKee M, editors. *Rockwood and Green's Fractures in Adults*. 8th ed. Philadelphia: Wolters Kluwer Health; 2015
- 2 Rose SH, Melton LJ, Morrey BF, Ilstrup DM, Riggs BL. Epidemiologic features of humeral fractures. *Clin Orthop Relat Res* 1982;(168): 24–30
- 3 Ring D, Jupiter JB, Gulotta L. Articular fractures of the distal part of the humerus. *J Bone Joint Surg Am* 2003;85(02):232–238
- 4 Singh H, Kanodia N, Singh R. Paratricipital two window approach for complex intraarticular distal humerus fractures: A prospective analysis of 27 patients. *Chin J Traumatol* 2019;22(06): 356–360
- 5 MacAusland WR. Ankylosis of the elbow: With report of four cases treated by arthroplasty. *JAMA* 1915;64:312–318
- 6 Alonso-Llames M. Bilateraltricipital approach to the elbow. Its application in the osteosynthesis of supracondylar fractures of the humerus in children. *Acta Orthop Scand* 1972;43(06):479–490
- 7 Muller ME, Allgower M, Willenegger H, Schatzker J, Bandi W. *Manual of Internal Fixation: Technique Recommended by the AO-Group*. New York: Springer-Verlag; 1970
- 8 Jupiter JB, Mehne DK. Fractures of the distal humerus. *Orthopedics* 1992;15(07):825–833
- 9 Morrey BF. Limited and extensile triceps reflecting exposures of the elbow. In: Morrey BF, editor. *Master Techniques in Orthopaedic Surgery: The Elbow*. New York: Raven Press; 1994:3–20
- 10 Bhandary B, Shetty S, Kassim MS, Moha A. Open reduction internal fixation with triceps-sparing approach in distal humerus fracture: an experience from a tertiary level hospital in Mangalore. *Int J Res Orthop* 2019;5(02):345–349
- 11 Ek ET, Goldwasser M, Bonomo AL. Functional outcome of complex intercondylar fractures of the distal humerus treated through a triceps-sparing approach. *J Shoulder Elbow Surg* 2008;17(03):441–446
- 12 Ali AM, Hassanin EY, El-Ganainy AE, Abd-Elmola T. Management of intercondylar fractures of the humerus using the extensor mechanism-sparing paratricipital posterior approach. *Acta Orthop Belg* 2008;74(06):747–752
- 13 Zhang C, Zhong B, Luo CF. Comparing approaches to expose type C fractures of the distal humerus for ORIF in elderly patients: six years clinical experience with both the triceps-sparing approach and olecranon osteotomy. *Arch Orthop Trauma Surg* 2014;134(06):803–811
- 14 Wilkinson JM, Stanley D. Posterior surgical approaches to the elbow: a comparative anatomic study. *J Shoulder Elbow Surg* 2001;10(04):380–382
- 15 Fernández-Valencia JA, Muñoz-Mahamud E, Ballesteros JR, Prat S. Treatment of AO Type C Fractures of the Distal Part of the Humerus through the Bryan-Morrey Triceps-Sparing Approach. *ISRN Orthop* 2013;2013:525326
- 16 Chen G, Liao Q, Luo W, Li K, Zhao Y, Zhong D. Triceps-sparing versus olecranon osteotomy for ORIF: analysis of 67 cases of intercondylar fractures of the distal humerus. *Injury* 2011;42(04):366–370
- 17 Iselin LD, Mett T, Babst R, Jakob M, Rikli D. The triceps reflecting approach (Bryan-Morrey) for distal humerus fracture osteosynthesis. *BMC Musculoskelet Disord* 2014;15:406