



Hair Transplant with Strip Harvest: Indications, Contraindications, and Technique

Manoj Khanna¹

¹Department of Cosmetic and Hair Transplant, Enhance Clinics, Kolkata, West Bengal, India

Indian J Plast Surg 2021;54:451–455.

Address for correspondence Manoj Khanna, MS, MCh, DNB, Department of Cosmetic and Hair Transplant, Enhance Clinics, 12, Loudon Street, Flat 5A, Kolkata 700017, West Bengal, India (e-mail: drmkhanna@gmail.com).

Abstract

The evolutionary process of modern hair transplantation began with the plug era and, transitioning through a period of minigrafting and micrografting, finally led to follicular unit transplantation (FUT). Apart from the expansion of donor:recipient ratio, this technique produces an excellent esthetic result, indistinguishable from the natural hair. The merit of strip harvest lies in the maximum amount of follicular unit harvest, minimizing the amount of hair follicle transection, and producing a single scar, irrespective of number of sessions. This article summarizes the prerequisites, indications, contraindications, and technique of strip harvest.

Keywords

- ▶ follicular unit transplantation
- ▶ FUT
- ▶ follicular unit
- ▶ hair restoration

Introduction

The basic principle of all modern hair restoration procedures is donor dominance which was discovered by Norman Orentreich in New York.¹ While Headington was the first to note the fact that scalp hair seemed to cluster together in natural groupings of one to five hairs, many years passed before the practice of creating “micrografts” that tried to keep these natural groupings intact was adopted.² The follicular unit (FU) graft produced utilizing Limmer’s technique which included the removal of the great majority of the nonhair bearing tissue surrounding the graft led to the foundation of FU transplant (FUT).³ The technique of strip harvest results in a thin linear scar hidden by the surrounding occipital hairs. Good candidates for FUT should have a favorable donor surface area and density relative to the recipient area. The successful outcome of FUT using strip harvest mandates a thorough evaluation of donor area, precise marking, and a meticulous technique.

Donor Area Evaluation

It yields information regarding the number and type of grafts per unit surface area, color contrast between the hair and the

scalp, hair texture, density of hairs per FU, anagen/telogen ratio, scalp laxity, and thickness, all of which set up the strategy for the size of strip required to cover the recipient area and placement of grafts. Some of these factors can be roughly determined by simply lifting-up the donor area hair in various areas and looking through it. It can be more accurately assessed using techniques and instruments such as Digital Trichometer, Micrometer, Canfield system, or Folliscope.

Hair diameter is the most important predictor for coverage in hair transplantation. Cole has calculated that an increase in average hair diameter of a mere 0.01 mm, increases hair bulk by an astounding 36%.⁴ The total volume of hair determines the visual impact. Doubling the hair density doubles the hair volume, while doubling the hair diameter quadruples the hair volume.⁵ It can be measured by Folliscope. Hair caliber is maximum at posterolateral aspect of the occipital region while of finer caliber as we move temporally. Cole summarized his findings which confirmed that hair density and FU density in “virgin” donor areas are generally highest in the midoccipital region and lowest in the supra-auricular area. The density in the midmastoid area usually lies between these two measurements.⁶

DOI <https://doi.org/10.1055/s-0041-1741523>.
ISSN 0970-0358.

© 2021. Association of Plastic Surgeons of India. All rights reserved. This is an open access article published by Thieme under the terms of the Creative Commons Attribution-NonDerivative-NonCommercial-License, permitting copying and reproduction so long as the original work is given appropriate credit. Contents may not be used for commercial purposes, or adapted, remixed, transformed or built upon. (<https://creativecommons.org/licenses/by-nc-nd/4.0/>)
Thieme Medical and Scientific Publishers Pvt. Ltd., A-12, 2nd Floor, Sector 2, Noida-201301 UP, India

Anagen/telogen ratio ascertains the relationship between the telogen and the anagen hairs. Normally, the ratio on the scalp is approximately 90% anagen and 10% telogen. The percentage of telogen is higher in an area which is thinning.⁷

Scalp laxity is important in determining tissue tension during wound closure and deciding precisely the widest strip that can be removed safely to harvest maximum number of FU. An excessively wide strip can lead to excess tension, potentially causing unsightly scars, hair effluvium, or tissue ischemia. It can be assessed by trying to move the donor tissue up and down, or pinching it between the fingers, using the clinical experience to gauge the laxity. Mohebi et al proposed the use of a mechanical device they developed named a "laxometer" for measurement of the scalp laxity.⁸ Mayer devised a technique to measure scalp elasticity in a reproducible and objective manner. Scalp elasticity is defined as the percentage of the original distance that lines placed 5-cm apart on the horizontal axis move when compressed maximally by the examiner's thumbs. This measurement can be made with a simple flexible ruler or with special scalp elasticity calipers. The formula is: scalp elasticity = $50 \text{ mm} - x / 50 \text{ mm}$ where x is the measurement when the skin is compressed between the examiner's fingers.⁹

Safe Donor Area

Safe donor area can be assessed on the basis of existing hair in the temporoparietooccipital region, patient's age, and family history. It is the source of permanent hairs (male pattern baldness [MPB] progresses both superior and inferior to it), and being the densest region in donor fringe, it provides with a maximum number of hairs in a single session and a minimum possibility of a visible scar.¹⁰ Unger measured areas containing at least eight hairs per 4-mm diameter circle and established the region that would be safe in approximately 80% of patients under the age of 80 years.¹¹

When marking the donor area, one has to stay below the occipital protuberance to avoid harvesting the neck hair and to avoid the pull of neck muscles on the scar. The lower limit can be marked higher in cases of retrograde hair loss (miniaturization) and if a subsequent sitting is expected.

For marking the lower limit of the strip to be harvested, a transverse line is first marked through the occipital protuberance, ending 2 cm from the postauricular hairline. This line is then extended laterally to a point 2-cm above the superior aspect of the ear and 2-cm posterior to the postauricular hairline. In advanced cases, this can be extended up to a line drawn vertically upward from the anterior aspect of the tragus about two fingerbreadths or 2-cm above the top of the ear.

The width of the scalp to be harvested can vary from 8 to 10 mm, and if scalp laxity permits, it can go up to 1.5 cm or more. The width has to be reduced in the bony mastoid region, as this is the area of maximum tension in the scalp. The length of the donor strip can vary from 15 to 30 cm, depending on the circumference of the skull. If lesser grafts are required, it is better to use one half of the scalp, and the other virgin half can be used in the subsequent session later.

Indications

It is indicated in androgenetic alopecia for both in males and females, that is, male and female patterned hair loss, eyebrow, beard, and moustache reconstruction, selected cases of scarring alopecia, and eyelash transplantation. It can be performed in any person with good donor area, in good general health and reasonable expectations. When a patient's primary goal is to achieve maximum fullness from the hair restoration, strip harvest should be considered.

Hair loss in the region of sideburns, temporal and retroauricular hairline resulting from aesthetic facial procedures, such as forehead/facelifts, scalp, and facial hair loss due to burns, hair loss due to excision of any vascular anomaly, or oncologic resection, is other indications for the procedure.

Caution should be exercised in young patients with early alopecia which is still evolving; risk of the Diffuse Unpatterned Alopecia (DUPA) is one of the reasons why many surgeons decide not to perform hair transplants on patients younger than 25 years of age.¹²

Contraindications

Apart from making an individual plan for each patient according to his age and expected long-term ratio of donor-recipient area, equally important is deciding on the suitable candidacy of the patient for surgery. Relevant history about any medical or psychological factors, such as cardiopulmonary disease, idiosyncratic drug reactions, allergies, bleeding diathesis, or psychiatric disorders should never be skipped. A patient with poor health, such as patient with poorly controlled hypertension might experience an increased chance of postoperative bleeding, and a patient with poorly controlled diabetes might lead to healing problems. The history of smoking should also be elucidated, as it is known to be associated with poor graft survival. Any medication such as anticoagulants and unreasonable expectations also present as a contraindication.

Active scarring alopecia: the scarring alopecias are non-dominant and, while active, do not respond to hair transplantation. These include discoid lupus erythematosus, lichen planopilaris (LPP), acne keloidalis nuchae, central centrifugal cicatricial alopecia, and Brocq's pseudopelade. LPP, the most common cause of cicatricial alopecia, accounting for at least 10% of cases, is an uncommon inflammatory hair disorder of unknown etiology that results in permanent alopecia and replacement of hair follicles with scar-like fibrous tissue.¹³ Frontal fibrosing alopecia (FFA), a variant of LPP, involves the frontal hairline and shares similar histological findings with those of LPP. Age at onset, patient ethnicity, history of skin diseases such as lichen planus, lupus, or other autoimmune diseases, and previous hair-care practices, along with symptoms and signs, such as itching or burning of the scalp and purulent discharge, should be noted.¹⁴ Transplanting should not be performed until treatment has controlled these diseases and until they have been quiescent for at least 6 to 12 months.

Telogen effluvium: telogen effluvium is a scalp disorder characterized by diffuse and nonscarring shedding of hair.¹⁵ Several factors, such as drugs, trauma, and emotional and physiological stress, can lead to the development of telogen effluvium. Acute telogen effluvium can usually be resolved by removing the underlying causative factors. However, the treatment of chronic telogen effluvium can be challenging.¹⁶

Ongoing trichotillomania: trichotillomania (hair-pulling disorder) is an often debilitating psychiatric condition characterized by recurrent pulling out of one's own hair, leading to hair loss and marked functional impairment.¹⁷ In the 5th edition of the diagnostic and statistical manual of mental disorders (DSM) (DSM-5),¹⁸ trichotillomania was included with obsessive-compulsive disorder (OCD) and stands as a contraindication to surgery. Patients with body dysmorphic disorder should be avoided, as these patients have low satisfaction rates and unrealistic expectations.

Alopecia areata is an autoimmune condition that attacks the hair follicles, causing nonscarring hair loss. While traditional treatment options such as corticosteroids are moderately effective, a better understanding of the disease pathogenesis may lead to the development of new treatments.¹⁹

When the miniaturization affects more than 25% of the donor area, one has to be very careful in deciding on surgical treatment because the patient is at greater risk of developing a DUPA, described by Bernstein and Rassman.²⁰ DUPA is not an absolute contraindication to hair transplant surgery, nevertheless, the surgeon has to bear in mind that the transplanted hairs may not be permanent and that the donor scars could possibly become visible in the future.

Miscellaneous: skin conditions (i.e., vitiligo and pemphigus), autoimmune-related conditions (e.g., lupus, sarcoidosis, and scleroderma), systemic infections (i.e., HIV, tuberculosis, and syphilis), local infections (i.e., tinea capitis and staphylococcal folliculitis), malnutrition and/or vitamin and mineral (iron) deficiency, recent childbirth, chemotherapy and/or radiation exposure should be avoided when planning for surgery.

Technique

The lower limit of the donor zone is marked as described in the safe donor area.

Apart from the hairs in donor area, the surrounding area of 3 to 4 mm is trimmed to a size of 2 to 4 mm and the area beyond is secured with tape. The patient lies down in a prone position and a donut pillow is used to enhance patient comfort and allow for breathing. The donor region is cleansed with Betadine and then the local anesthesia is infiltrated as a field block using continuous wheal technique beginning in the occipital area and then going laterally. The solution used for anesthesia consists of 100-mL saline, 30 mL of 2% lignocaine, 20 mL sensoricaine, and 1-mL adrenaline (1:1,000), which is infiltrated very slowly at a superficial dermal level using 2-mL syringes and 26-G needles, in conjunction with vibration anesthesia and ice pack.

The incision is scored into the epidermis and superficial dermis using a double-bladed knife with spacers to adjust the width at the occipital region. **Fig. 1** shows the scoring

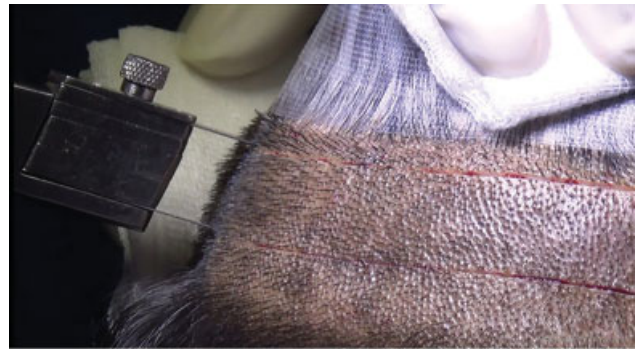

Fig. 1 Double-bladed knife with spacers for scoring incision to give a parallel cut.

incision using a double-bladed knife. The lateral limits of donor area scored with no.15 blade and joined with the previously made incision. The author prefers to score the trichophytic incision (**Fig. 2**), 1- to 2-mm inferior to the lower margin of incision, as the angulation of the hair and the overhanging ledge of the superior margin makes it look more natural. Normal saline without adrenaline is injected into the subcutaneous fat plane to hydrodissect the strip and minimizes bleeding. The incision is deepened into the subcutaneous fat, following the angulation of hairs, to avoid injury to the hair follicles. The strip is excised using two double-

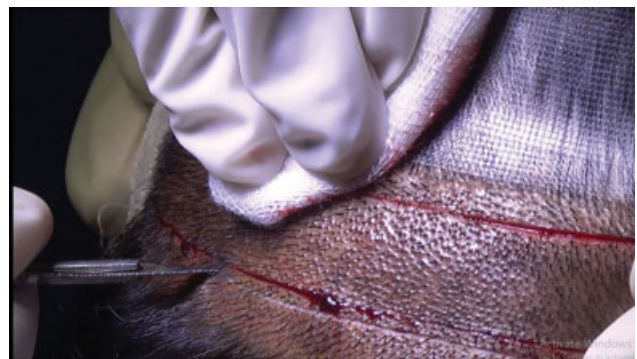

Fig. 2 Scoring the trichophytic incision below the inferior border of the incision.

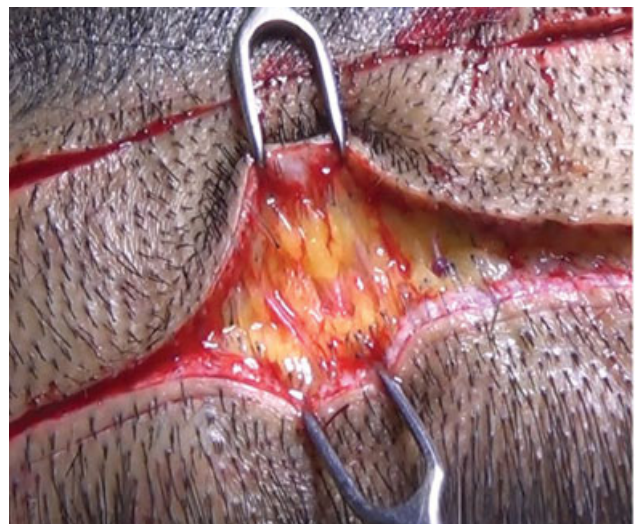


Fig. 3 Traction technique using double pronged hooks on both sides.

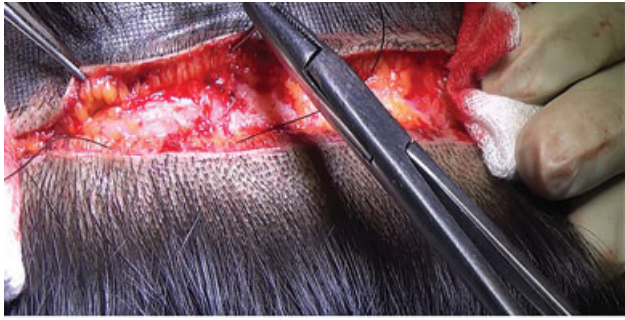


Fig. 4 Closure of deeper layer using non absorbable Nylon 2-0 suture.

pronged hooks (as shown in **Fig. 3**), with one hook pulling the strip and the other one giving counter-traction in the opposite direction. This minimizes the sharp dissection of the strip, thereby preserving the underlying neurovascular structures, to prevent postoperative paraesthesia and anaesthesia and to keep the field bloodless. Caution should be exercised to avoid elevating the scalp over the superior and inferior margins while using double hook. Next, the trichophytic incision is excised to a depth of 1 to 2 mm, and the area is temporarily closed with continuous 2-0 nylon. This helps in mechanical stretching of the two edges of the incision which leads to some tissue expansion, eventually decreasing tension on the suture line.

The incision is closed in two layers. **Fig. 4** shows the closure of the deep subcutaneous fat layer is with interrupted nonabsorbable suture (nylon 2-0), staying beneath the hair follicle. It must be ensured that reef knots are taken throughout the closure to prevent loosening of the knot and setting the stage for a good linear scar. The rationale behind using nonabsorbable sutures is that all scars continue to mature over a period of 6 months to 2 years, and most of the absorbable suture material loses 50% of the tensile strength in 3 to 6 weeks by which time the scar has not attained significant strength. The scar invariably becomes wider subsequently.

The skin is closed with either 4-0 Prolene or 4-0 Rapide Vicryl in case the patient cannot return to remove the stitches. Nylon is avoided as its color may resemble the black color of the hair and makes it difficult to identify during removal. The author uses a personalized technique of giving 20 to 30 bites simultaneously before pulling the sutures in one go to tighten them (**Fig. 5**). This gives better control

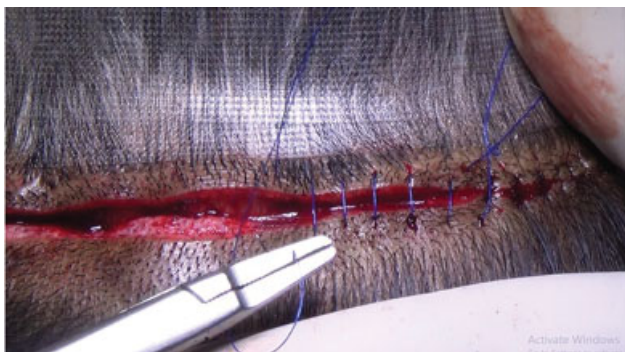

Fig. 5 Skin closure using continuous sutures of 4-0 Prolene.

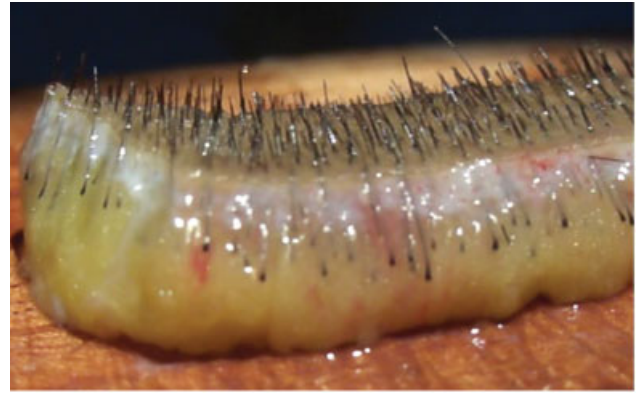

Fig. 6 Harvested strip with intact follicles.

during suturing with more symmetry, and thereby resulting in near-perfect closure and a better scar. **Fig. 6** shows harvested strip using the traction technique.

Technical points in cases of a repeat strip harvest are listed below:

- Should be avoided before 9 months to 1 year.
- Patient should be advised to do head massage to mobilize the donor area daily in the preceding month to increase scalp laxity
- Remove the scar of first procedure with the strip. This will reduce the tension during closure.

Conclusion

Strip harvesting for FUT began in the 1990s and remains the gold standard of hair restoration surgery to date. The advantage of strip harvest is that the maximal area of permanent hair could be harvested within safe limits from the permanent hair bearing zone and dissected into grafts, giving a natural appearance to the transplanted scalp.

Salient points to minimize the donor scar include harvesting a long and narrow strip instead of short and wide strip, avoid undermining superior and inferior to the incision, preservation of underlying neurovascular bundles, closure of deeper layer using nonabsorbable sutures, tension-free double-layer closure in all cases, utilization of trichophytic closure, removal of scar tissue in repeat strip harvest cases, and a good postoperative scar massage protocol for a subsequent procedure.

Conflict of Interest

None declared.

References

- 1 Orentreich N. Autografts in alopecias and other selected dermatological conditions. *Ann N Y Acad Sci* 1959;83:463-479
- 2 Headington JT. Transverse microscopic anatomy of the human scalp. A basis for a morphometric approach to disorders of the hair follicle. *Arch Dermatol* 1984;120(04):449-456
- 3 Limmer BL. Elliptical donor stereoscopically assisted micrografting as an approach to further refinement in hair transplantation. *J Dermatol Surg Oncol* 1994;20(12):789-793

- 4 Cole J. Mathematics of follicular unit transplantation. Sixth annual meeting of the International Society of Hair Restoration Surgery, Washington, DC, September 16–20, 1998
- 5 Bernstein R. Accurate follicular unit transplantation. In: Haber R, Stough D, eds. *Hair Replacement: Surgical and Medical*. St. Louis, MO: Mosby; 1996:138–42
- 6 Cole J, Devroye J. A calculated look at the donor area. *Hair Transplant Forum Intl* 2001;11(05):150–154
- 7 Devroye J. Donor area harvesting. In: Unger W, Shapiro R, eds. *Hair Transplantation*. 5th ed. London, United Kingdom: CRC Press; 2010:255–256
- 8 Mohebi P, Pak J, Rassman W. How to assess scalp laxity. *Hair Transplant Forum Int* 2008;18(05):16
- 9 Mayer ML. Evaluation of scalp elasticity. In: Unger W, Shapiro R, Unger R, Unger M, eds. *Hair Transplantation*. 5th ed. London, United Kingdom: Informa Healthcare; 2011:267–270
- 10 Devroye J. Donor area harvesting. In: Unger W, Shapiro R, eds. *Hair Transplantation*. 5th edn. London, United Kingdom: CRC Press; 2010:257–262
- 11 Unger W, Solish N, Giguere D, et al. Delineating the safe donor area for hair transplanting. *Am J Cosmet Surg* 1994;11:239–243
- 12 Devroye J. Donor area harvesting. In: Unger W, Shapiro R, eds. *Hair Transplantation*. 5th edn. London, United Kingdom: CRC Press; 2010:248
- 13 Whiting DA. Cicatricial alopecia: clinico-pathological findings and treatment. *Clin Dermatol* 2001;19(02):211–225
- 14 Filbrandt R, Rufaut N, Jones L, Sinclair R. Primary cicatricial alopecia: diagnosis and treatment. *CMAJ* 2013;185(18):1579–1585
- 15 Grover C, Khurana A. Telogen effluvium. *Indian J Dermatol Venereol Leprol* 2013;79(05):591–603
- 16 Asghar F, Shamim N, Farooque U, Sheikh H, Aqeel R. Telogen effluvium: a review of the literature. *Cureus* 2020;12(05):e8320
- 17 Woods DW, Flessner CA, Franklin ME, et al; Trichotillomania Learning Center-Scientific Advisory Board. The Trichotillomania Impact Project (TIP): exploring phenomenology, functional impairment, and treatment utilization. *J Clin Psychiatry* 2006;67(12):1877–1888
- 18 American Psychiatric Association. *Diagnostic and Statistical Manual of Mental Disorders*. 5th ed. Washington, DC: American Psychiatric Association; 2013
- 19 Muhaidat JM, Al-Qarqaz F, Khader Y, Alshiyab DM, Alkofahi H, Almalekh M. A retrospective comparative study of two concentrations of intralesional triamcinolone acetonide in the treatment of patchy alopecia areata on the scalp. *Clin Cosmet Investig Dermatol* 2020;13:795–803
- 20 Bernstein RM, Rassman WR. Follicular transplantation. Patient evaluation and surgical planning. *Dermatol Surg* 1997;23(09):771–784, discussion 801–805