

Percutaneous laser application using the SpyGlass system in a patient with intrahepatic lithiasis, liver cirrhosis, and surgically altered anatomy

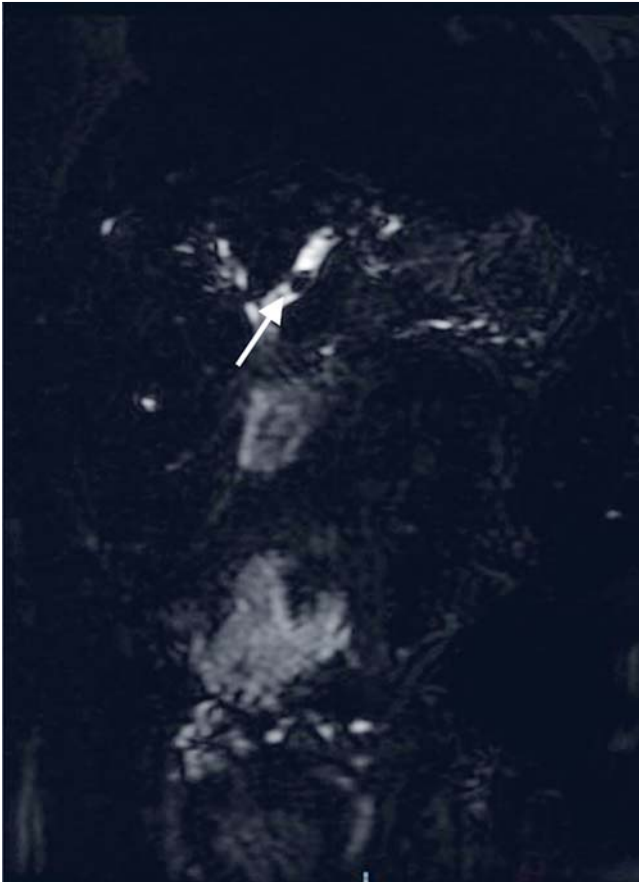


Fig. 1 Magnetic resonance cholangiopancreatography (MRCP) image showing a left intrahepatic stone (arrow).

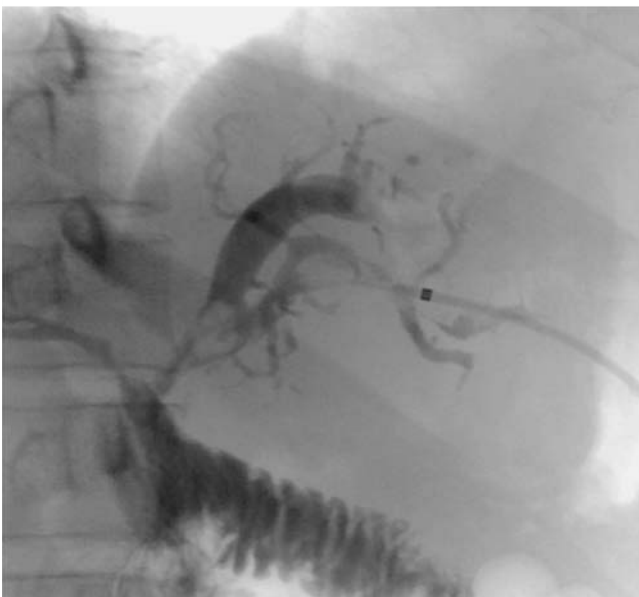

Fig. 2 View during percutaneous cholangiography showing an intrahepatic stone.

A 35-year-old woman underwent a Roux-en-Y hepaticojejunostomy in 2001 for a bile duct injury that occurred during a cholecystectomy for cholelithiasis. After the surgery, she began to experience episodes of relapsing cholangitis, approximately once a year, which were treated with antibiotics. However, from 2012 onwards, the episodes of cholangitis increased in frequency to five or six episodes per year, including some episodes that required prolonged hospitalization of up to 2 months. In 2014 she was referred to our hospital, where she was found to have clinical evidence of chronic liver disease that was classified as secondary biliary cirrhosis, and magnetic resonance cholangiopancreatography (MRCP) revealed multiple left intrahepatic stones (● **Fig. 1**).

Endoscopic retrograde cholangiopancreatography (ERCP) was not attempted by enteroscopy because of the lack of the necessary device and accessories. The patient was not a candidate for left hepatectomy because of chronic liver disease, so she was placed on a waiting list for liver transplantation.

Because of the persistence of her cholangitis, we decided to attempt percutaneous cholangioscopy with the single-operator direct-visualization SpyGlass system (Boston Scientific Inc., Natick, Massachusetts, USA) and laser application. Initially, a percutaneous 8-Fr catheter was placed radiologically to access the left bile duct (● **Fig. 2**). After 3 weeks, the SpyGlass system was used and laser lithotripsy was applied (● **Fig. 3**; ● **Video 1**), with the stone fragments being removed in an antegrade fashion using the balloon of a biliary extraction catheter (Cook Medical, Inc., Winston Salem, North Carolina, USA).

On follow-up MRCP, no evidence of intrahepatic stones was observed (● **Fig. 4**). The clinical outcome was successful, and the patient has had no new episodes of cholangitis in 10 months of follow-up.

Surgery has traditionally been considered the best option for intrahepatic stones [1]. Although enteroscopy-assisted access is an acceptable option to treat intrahepatic cholelithiasis, lack of equipment may preclude this option. Percutaneous cholangioscopy is also an acceptable option, especially in the presence of difficult intrahepatic stones or distal bile duct stenosis [2]. Other access options have included transgastric and percutaneous transhepatic rendezvous maneuvers [3].

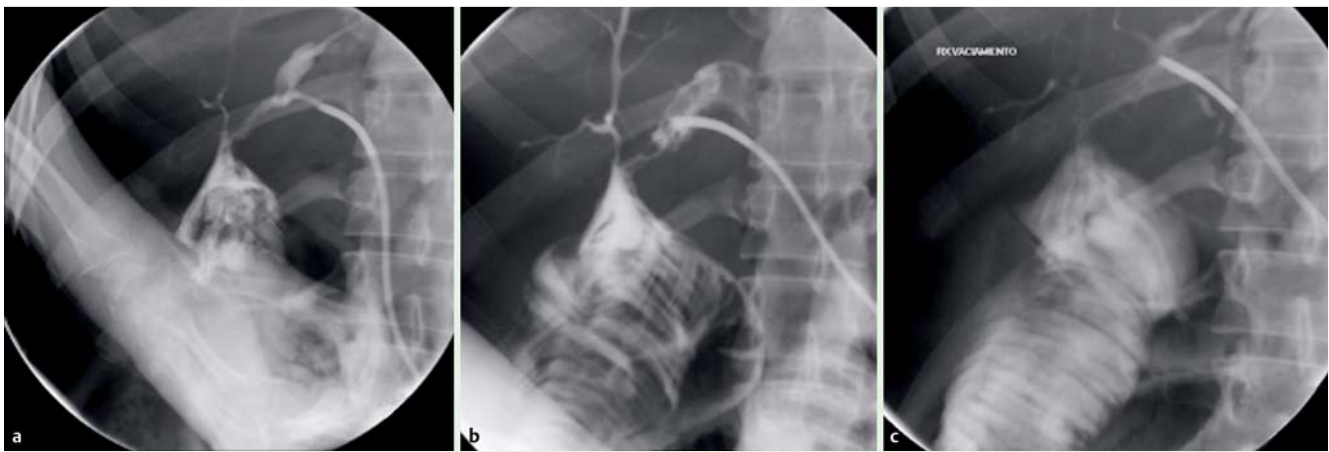


Fig. 3 Radiographic images showing: **a** cholangiography being performed with the SpyGlass system; **b** the SpyGlass in position in the left intrahepatic duct during laser application; **c** no evidence of intrahepatic lithiasis following laser lithotripsy and extraction of the stone fragments.

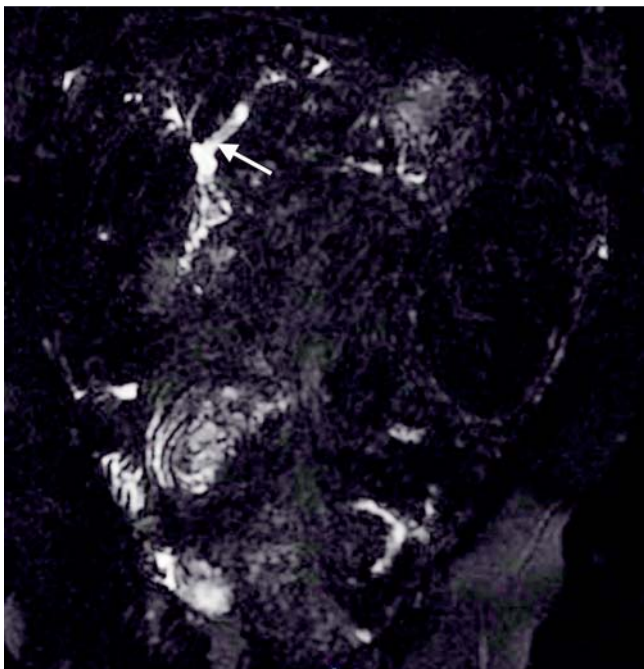
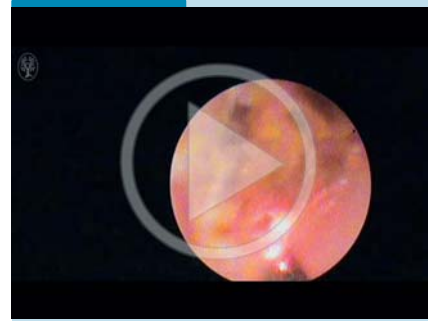


Fig. 4 Follow-up magnetic resonance cholangiopancreatography (MRCP) image showing no evidence of intrahepatic lithiasis (arrow in the site where lithiasis was previously observed).

Video 1



Percutaneous cholangioscopy with the single-operator direct-visualization SpyGlass system and application of laser lithotripsy.

3 Fuchs ES, Hartmann B, Jakobs R. Transgastric and percutaneous transhepatic rendezvous maneuver for the treatment of difficult intrahepatic stones. *Endoscopy* 2014; 46: E184–E185

Bibliography

DOI <http://dx.doi.org/10.1055/s-0042-100809>
Endoscopy 2016; 48: E49–E50
 © Georg Thieme Verlag KG
 Stuttgart · New York
 ISSN 0013-726X

Corresponding author

Félix I. Téllez-Ávila, MD, PhD
 Endoscopy Department
 Instituto Nacional de Ciencias Médicas y Nutrición
 Salvador Zubirán
 Avenida Vasco de Quiroga No. 15
 Colonia Belisario Domínguez Sección XVI
 Delegación Tlalpan C.P. 14080
 Ciudad de México
 México
 Fax: +52-55-54870900
felixtelleza@gmail.com

To the best of our knowledge, this is the first report of percutaneous cholangioscopy using SpyGlass with direct laser application (without the rendezvous technique) in a patient with complex intrahepatic stones and a history of recurrent cholangitis and chronic liver disease.

Endoscopy_UCTN_Code_TTT_1AR_2AJ

Competing interests: None

Félix I. Téllez-Ávila, Gilberto Duarte-Medrano, Francisco Valdovinos-Andraca, Víctor Gallardo-Cabrera, David R. Herrera-Mora

Department of Endoscopy, Instituto Nacional de Ciencias Médicas y Nutrición Salvador Zubirán, Mexico City, Mexico

References

- 1 Mori T, Sugiyama M, Atomi Y. Gallstone disease: management of intrahepatic stones. *Best Pract Res Clin Gastroenterol* 2006; 20: 1117–1137
- 2 Du L, D'Souza P, Thiesen A et al. Percutaneous transhepatic cholangioscopy for indeterminate biliary strictures using the SpyGlass system: a case series. *Endoscopy* 2015; 47: 1054–1056