

Endoscopic resection of a giant esophageal fibrovascular polyp

A 66-year-old woman consulted because of dysphagia and occasional regurgitation of a lump of tissue during episodes of vomiting over the previous 9 months. A computed tomography (CT) scan showed a giant esophageal mass emerging in the upper esophagus. Evaluation by endoscopic ultrasound (EUS) showed that the mass was very hypoechoic, and it was suspected to be lipoma.

An endoscopic procedure was performed with the patient intubated, using a large-channel gastroscop (Pentax, Japan) and CO₂ insufflation. The endoscopy showed a polyp with a diameter of 5 cm at its base and a length of 15 cm (Fig. 1a). The mucosal appearance was normal and its lower part was ulcerated.

Resection was commenced with the submucosal injection of saline mixed with adrenaline (1:10000) at the base of the

polyp. The polyp was gradually dissected step by step at its base, using first a triangle-tip electro-surgical knife (Fig. 1b,c) then a hook knife (Olympus, Japan) (Fig. 1d; Video 1) using the Endocut current. Hemostasis was achieved using Coagrasper forceps (Olympus). The polyp was then caught with a snare (Fig. 1e) and extracted using an over-tube (Fig. 2). No complications such as bleeding or perforation occurred. Histological analysis confirmed the fibrovascular nature of the polyp, which had been completely resected.

Even though fibrovascular polyps are rare, they may cause morbidity and mortality, which makes their resection mandatory [1,2]. In such situations, two types of

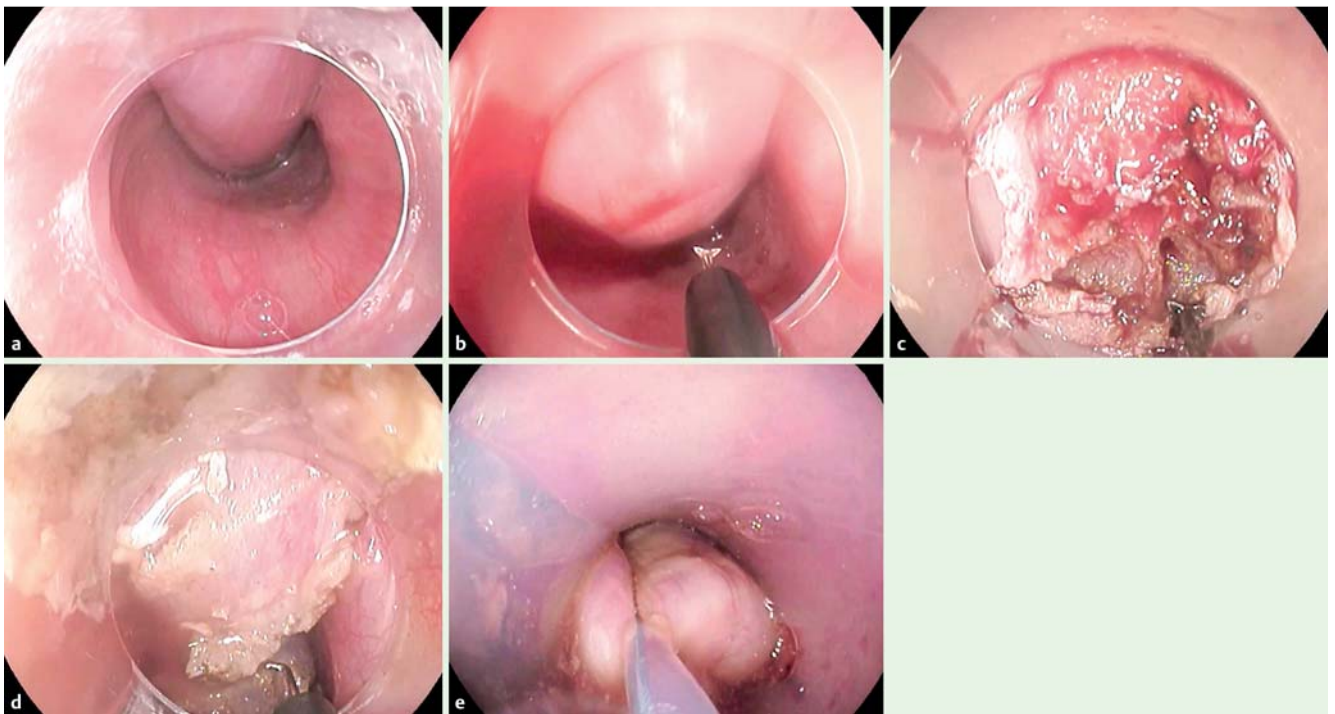
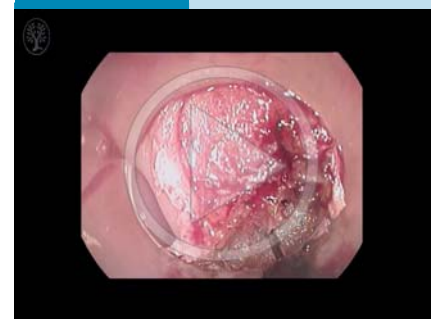


Fig. 1 Endoscopic views showing: **a** a fibrovascular polyp with its base implanted just under the Killian area; **b** the initial stages of dissection using a triangle-tip electro-surgical knife; **c** the ongoing dissection; **d** completion of the dissection using a hook knife; **e** the polyp being caught with a snare.

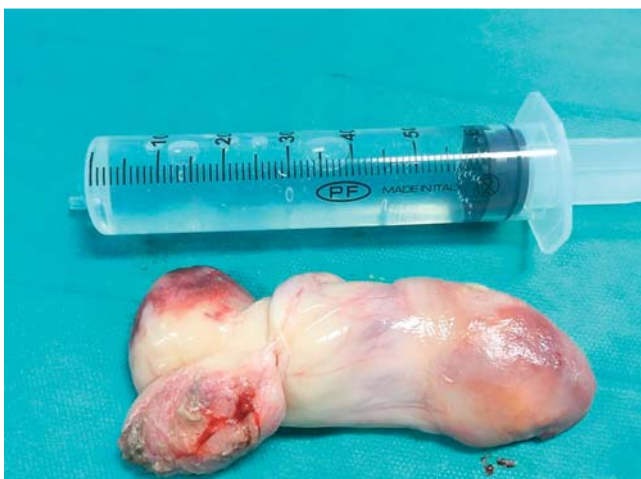

Fig. 2 Macroscopic appearance of the resected polyp.

Video 1



Endoscopic resection of a giant fibrovascular polyp using first a triangle-tip knife and then a hook knife.

therapeutic approach are available: surgical or endoscopic [1]. Because of the risk of uncontrolled bleeding, it is conventionally recommended that polyps larger than 80 mm are not treated endoscopically [1, 3]. Esophageal surgery is however known to be complex, associated with morbidity, and not always technically feasible.

By using a dissection knife, we were able to safely remove this large polyp endoscopically. This is a new endoscopic approach, as in all the previously published cases, fibrovascular polyps have been removed with a polypectomy snare [3–5]. In conclusion, endoscopic treatment of a giant fibrovascular polyp can be performed safely and effectively using appropriate equipment.

Endoscopy_UCTN_Code_TTT_1AO_2AG

Competing interests: None

Diane Lorenzo, Jean Michel Gonzalez, Marc Barthet

Service de Gastroentérologie, Hôpital Nord, Marseille, France

References

- 1 Lee SY. Recurrent giant fibrovascular polyp of the esophagus. *World J Gastroenterol* 2009; 15: 3697
- 2 Mishra PK, Goel N, Saluja SS et al. Management of giant fibrovascular polyp of esophagus. *Am Surg* 2012; 78: E538–E540
- 3 Park J-S, Bang BW, Shin J et al. A case of esophageal fibrovascular polyp that induced asphyxia during sleep. *Clin Endosc* 2014; 47: 101
- 4 Murino A, Eisendrath P, Blero D et al. A giant fibrovascular esophageal polyp endoscopically resected using 2 gastroscopes simultaneously (with videos). *Gastrointest Endosc* 2014; 79: 834–835
- 5 Zhang J. Successful endoscopic removal of a giant upper esophageal inflammatory fibrous polyp. *World J Gastroenterol* 2009; 15: 5236

Bibliography

DOI <http://dx.doi.org/10.1055/s-0042-101857>
 Endoscopy 2016; 48: E69–E70
 © Georg Thieme Verlag KG
 Stuttgart · New York
 ISSN 0013-726X

Corresponding author

Diane Lorenzo, MD
 Hôpital Nord
 chemin des Bourrelly
 Marseille
 France
 Fax: +33-4-91961311
 diane.lorenzo@gmail.com