Treatment of pancreaticoportal fistula by endosonography-guided rendezvous

Pancreatic fistula may occur as a complication of chronic pancreatitis [1–3]. However, a communicating fistula between the pancreatic ductal system and the portal vein is a rare and difficult-to-treat complication [4].

We present the first report of endoscopic ultrasound (EUS)-guided main pancreatic duct rendezvous treatment of a symptomatic case of pancreaticoportal fistula. The case was complicated by a partial portal vein thrombosis, related to a pancreatic pseudocyst from chronic pancreatitis.

A 69-year-old man presented with abdominal pain and weight loss during the previous 6 months. Laboratory tests revealed anemia (hemoglobin 7.7 g/dL) an increased amylase (7759 U/L) and an albumin of 3.4 g/L. Clinical history and abdominal magnetic resonance imaging (MRI) led to a diagnosis of pancreatic pseudocyst related to underlying alcoholic chronic pancreatitis. The MRI further showed a dilatation of the portal vein related to partial thrombosis (▶ **Fig. 1**).

We performed an endoscopic retrograde pancreatography (ERP) that revealed a cystic collection in the head of the pancreas with stenosis and dilatation of the main pancreatic duct and secondary ducts. We were unable to pass a guidewire through the pancreatic duct stricture (▶ **Fig. 2**). However, it was passed through a pancreaticoportal fistula, and the portal vein was visualized immediately after contrast injection.

We then attempted an EUS-guided rendezvous maneuver. We accessed the main pancreatic duct through the stomach with a 19G needle, obtained pancreatography, and passed a 0.035-inch guidewire along the main duct through the minor duodenal papilla into the duodenum (▶ **Fig. 3**). With the duodenoscope it was possible to grasp the guidewire and reposition it in the tail of the pancreas. We finally introduced a fully covered biliary self-expandable metallic stent (8 cm × 10 mm) across the pan-

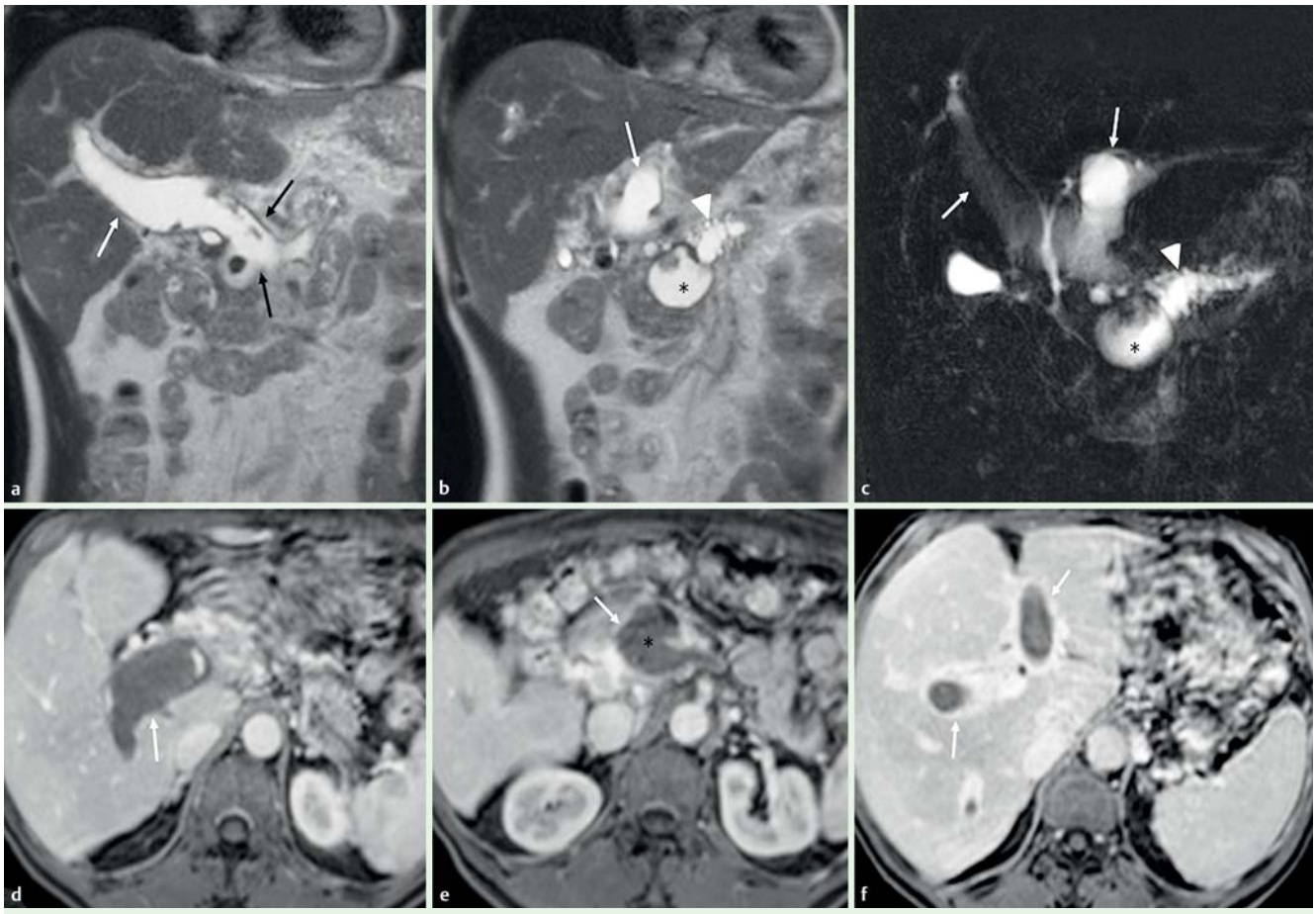

Fig. 1 A 69-year-old man underwent magnetic resonance imaging (MRI) 5 months after the onset of abdominal pain and weight loss. The MRI images showed portal vein thrombosis associated with increased caliber and parietal post-contrast enhancement: **a, b** coronal T2-weighted; **c** magnetic resonance cholangiography (MRC); **d, e** portal phase, post-gadolinium, fat-suppressed, T1-weighted; **f** late phase, post-gadolinium, fat-suppressed, T1-weighted. The pancreatic–portal communication, probably related to the pancreatic head pseudocyst is seen in part **a** (black arrows). The portal vein thrombus (white arrows, **a–c**) appears hyperintense on the T2-weighted and MRC images, most likely because of liquefaction caused by pancreatic juice. Lack of enhancement of the portal vein caused by thrombosis is shown on post-contrast T1-weighted images (white arrows, **d–f**), and parietal portal vein enhancement, probably related to inflammation, can be better seen on the late post-contrast phase image (**f**). The pancreatic head pseudocyst (*) is seen in parts **b**, **c**, and **e**. The dilated main pancreatic duct (arrowhead) is seen better in parts **b** and **c**. The normal biliary tree and gallbladder can be seen in part **c**, partially superimposed by portal vein thrombosis.

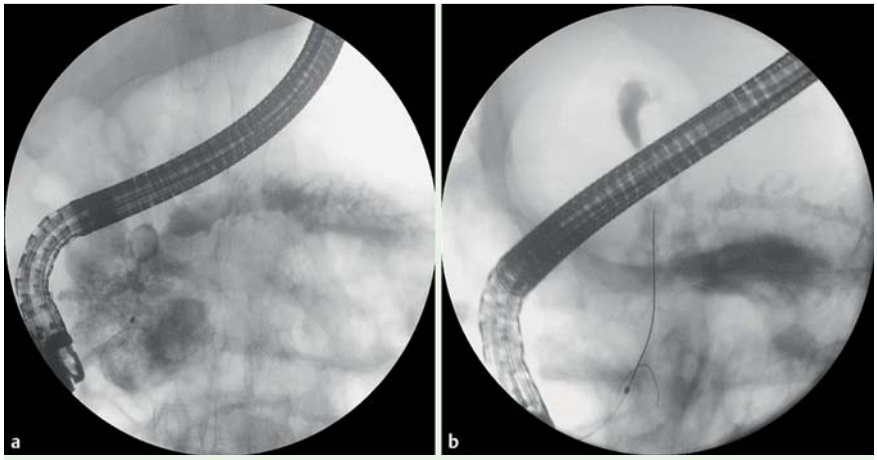

Fig. 2 Endoscopic retrograde pancreatography (ERP) via the major duodenal papilla shows: **a** a pancreatic cystic collection with stenosis and dilatation of the main pancreatic duct and secondary ducts; **b** the guidewire passing into a pancreaticoportal fistula.

Video 1



Treatment of pancreaticoportal fistula by endosonography-guided rendezvous.

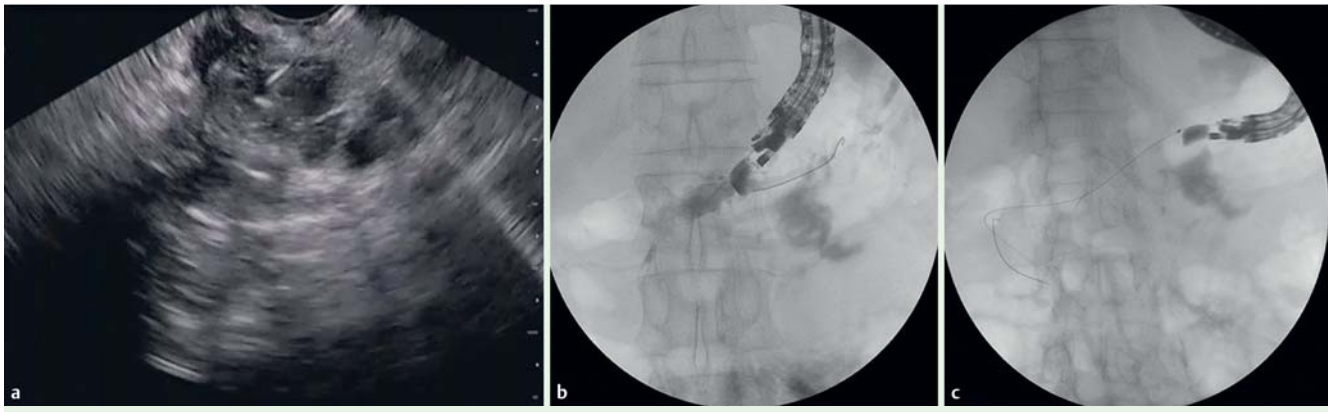

Fig. 3 **a** Endoscopic ultrasound (EUS) shows the 19G needle inside the main pancreatic duct. **b** EUS-guided pancreatography and the insertion of the guidewire. **c** Passage of the guidewire through the minor duodenal papilla.

creaticoportal fistula and the main pancreatic duct stenosis (▶ **Fig. 4**).

Reported treatments for this condition range from conservative medical management to some variation of pancreatectomy [5]. Because of the rarity of the condition, there is a clear need for individualized treatment. In our patient, the insertion of the fully covered self-expandable metallic stent led to marked clinical improvement, reduction of serum amylase (389 U/L), and improvement of the abnormalities visible on MRI; these improvements were found to be persistent at 6-month follow-up.

Endoscopy_UCTN_Code_TTT_1AS_2AD

Competing interests: None

Rafael Kemp[1], José C. Ardengh[2], José E. Brunaldi[3], Jorge Elias-Junior[4], Valdair F. Muglia[4], Leonor G. Savarese[5], José S. dos Santos[1]

[1] Department of Surgery and Anatomy, Ribeirão Preto School of Medicine, University of São Paulo, São Paulo, Brazil
[2] University Hospital of the Ribeirão Preto School of Medicine, Department of Surgery and Anatomy, University of São Paulo, São Paulo, Brazil; Echoendoscopy Unit, 9 de Julho Hospital, São Paulo, Brazil
[3] University Hospital of the Ribeirão Preto School of Medicine, Department of Surgery and Anatomy, University of São Paulo, São Paulo, Brazil
[4] Department of Internal Medicine, Ribeirão Preto School of Medicine, University of São Paulo, São Paulo, Brazil
[5] University Hospital of the Ribeirão Preto School of Medicine, Department of Internal Medicine, University of São Paulo, São Paulo, Brazil

References

1 *Van Steenbergen W, Ponette E.* Pancreaticoportal fistula: a rare complication of chronic pancreatitis. Gastrointest Radiol 1990; 15: 299–300
2 *Hastier P, Buckley MJ, Dumas R* et al. Pancreaticoportal fistula after endoscopic cystogastrostomy in chronic calcifying pancreatitis. Pancreas 1998; 17: 208–210
3 *Chang LH, Francoeur L, Schweiger F.* Pancreaticoportal fistula in association with antiphospholipid syndrome presenting as ascites and portal system thrombosis. Can J Gastroenterol 2002; 16: 601–605
4 *Itoi T, Kasuya K, Sofuni A* et al. Endoscopic ultrasonography-guided pancreatic duct access: techniques and literature review of pancreatography, transmural drainage and rendezvous techniques. Dig Endosc 2013; 25: 241–252
5 *Ng TS, Rochefort H, Czaplicki C* et al. Massive pancreatic pseudocyst with portal vein fistula: case report and proposed treatment algorithm. Pancreatology 2015; 15: 88–93

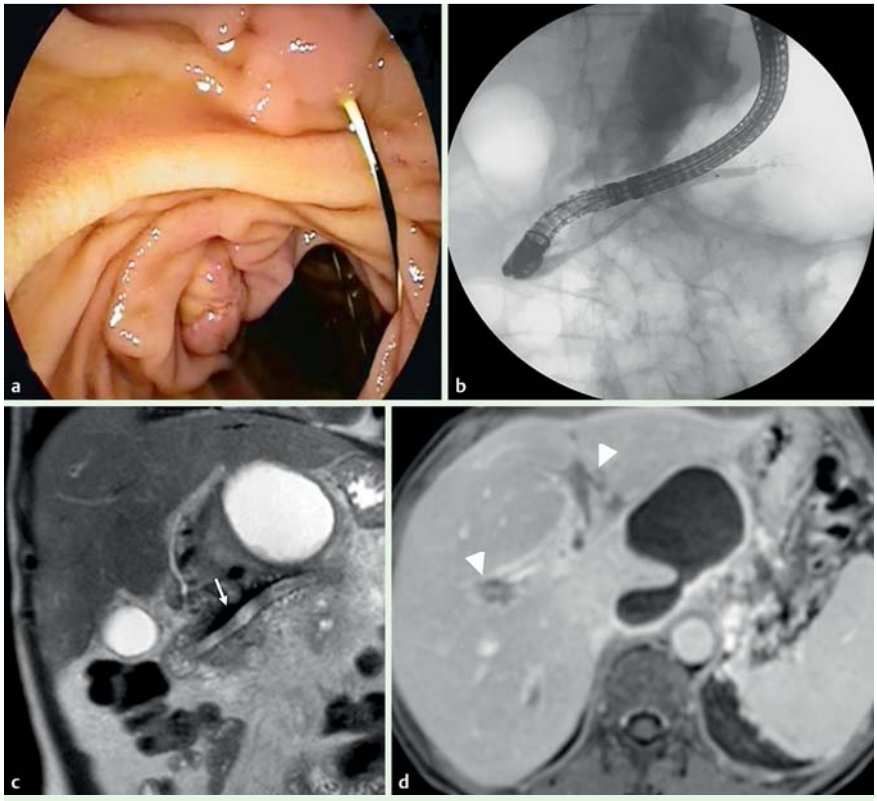

Fig. 4 **a** Endoscopic view of the guidewire exiting the minor duodenal papilla. **b** Fluoroscopy shows insertion of the fully covered self-expanding metal stent (SEMS). **c, d** Follow-up magnetic resonance imaging (MRI) after 1 month shows the SEMS inside the main pancreatic duct (white arrow), and persistence of portal vein thrombosis but with a marked decrease in the caliber of the portal vein (arrowheads).

Bibliography
DOI http://dx.doi.org/10.1055/s-0042-102448
Endoscopy 2016; 48: E92–E94

ISSN 0013-726X

Corresponding author
Rafael Kemp, MD, PhD
Department of Surgery and Anatomy
Ribeirão Preto School of Medicine,
University of São Paulo
Avenida Bandeirantes
3900 Monte Alegre
14049-900, Ribeirão Preto
São Paulo
Brazil
Fax: +55-16-36022618
rkemp@fmrp.usp.br