High resolution cholangioscopic electrohydraulic lithotripsy for fragmentation and extraction of impacted cystic duct stones

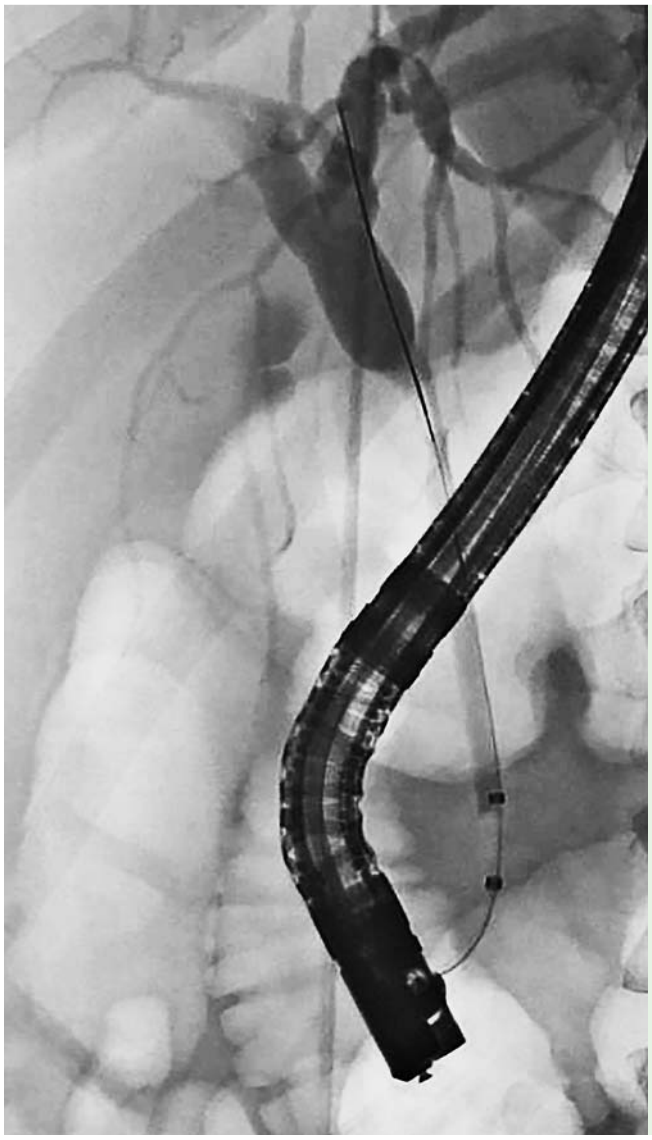

Fig. 1 A 29-year-old postpartum woman presented with right-sided abdominal pain and jaundice: fluoroscopic image from initial endoscopic retrograde cholangiopancreatography (ERCP), showing a filling defect at the level of the cystic duct, representing an impacted cystic duct stone.

Video 1

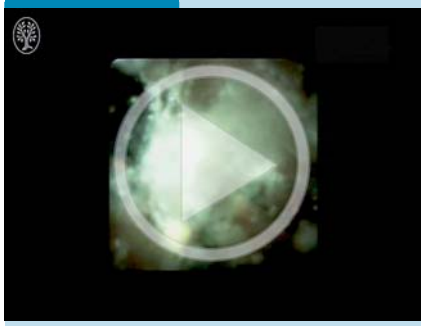

In a 29-year-old postpartum woman, presenting with right-sided abdominal pain and jaundice, high resolution cholangioscopy shows the impacted cystic duct stone and fragmentation of the stone by electrohydraulic lithotripsy probe. An endoscopic view of balloon extraction of the stone fragments is shown.

A 29-year-old woman presented with right-sided abdominal pain and jaundice. The patient was postpartum but otherwise healthy. Her total bilirubin level was 74 µmol/L. Abdominal ultrasound revealed a 9-mm dilated proximal common bile duct (CBD), a suspected CBD stone and a distended gallbladder with gallstones. The patient underwent endoscopic retrograde cholangiopancreatography (ERCP); however, no obvious filling defects were seen in the CBD. A convex filling defect was seen protruding from the cystic duct confluence, with proximal dilatation and an absence of gallbladder filling (**Fig. 1**). Sphincterotomy was performed, and but the stones could not be extracted by means of balloon sweeps. A plastic biliary stent was placed and the patient underwent laparoscopic cholecystectomy. Intraoperative choledochoscopy revealed an impacted stone at the cystic duct confluence. Despite attempts to extract the stone with three wire baskets and two Fogarty catheters, the stone could not be removed.

Repeat ERCP with high resolution single-operator peroral cholangioscopy (SpyGlass DS system; Boston Scientific, Marlborough, Massachusetts, USA) [1] was performed (**Video 1**). Cholangiography revealed a filling defect at the cystic duct level. A balloon occlusion cholangiogram revealed absence of cystic duct filling (**Fig. 2**). The SpyGlass DS system was then maneuvered into the CBD under fluoroscopy, and high resolution cholangioscopy was performed. An 8-mm stone impacted in the cystic duct was visualized (**Fig. 3 a**). An electrohydraulic lithotripsy (EHL) probe was used to fragment the stone (**Fig. 3 b**). The SpyGlass system was removed from the CBD, and a balloon was used to successfully extract the fragments from the cystic duct and CBD (**Fig. 4**).

EHL has previously been paired with multioperator and low resolution cholangioscopy for fragmentation of CBD, cystic duct, and gallbladder stones [2–5]. Here we present the first report of a safe, single-operator procedure for high resolution identification and fragmentation of cystic duct stones, which can potentially spare patients invasive, technically difficult, and costly re-operations.

Endoscopy_UCTN_Code_TTT_1AR_2AH

Competing interests: R. Mohamed is on the national advisory board of Boston Scientific.

This document was downloaded for personal use only. Unauthorized distribution is strictly prohibited.

Fig. 2 Fluoroscopic image from repeat ERCP, showing absence of cystic duct filling with balloon occlusion cholangiogram.

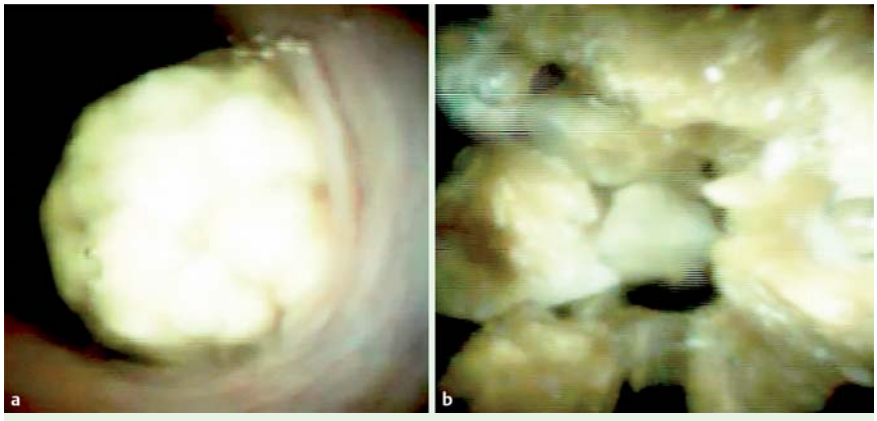

Fig. 3 High resolution cholangioscopic images acquired using the SpyGlass DS system, showing: **a** an impacted stone at the cystic duct confluence; **b** fragmentation of the impacted cystic duct stone by means of an electrohydraulic lithotripsy (EHL) probe.

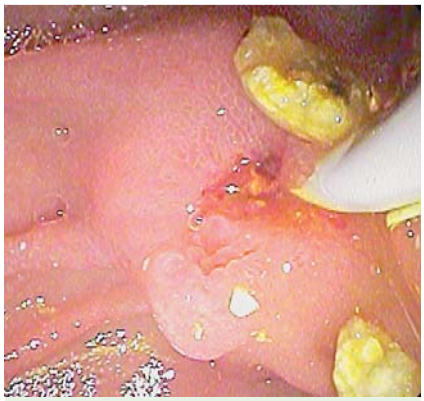

Fig. 4 Endoscopic image showing balloon extraction of the fragments of the previously impacted cystic duct stone from the common bile duct after electrohydraulic lithotripsy.

Nauzer Forbes, Takuya Ishikawa, Rachid Mohamed

Division of Gastroenterology, University of Calgary, Calgary, Alberta, Canada

References

1 *Chen YK, Pleskow DK*. SpyGlass single-operator peroral cholangiopancreatoscopy system for the diagnosis and therapy of bile-duct disorders: a clinical feasibility study (with video). Gastrointest Endosc 2007; 65: 832–841
2 *Swahn F, Edlund G, Enochsson L* et al. Ten years of Swedish experience with intraductal electrohydraulic lithotripsy and laser lithotripsy for the treatment of difficult bile duct stones: an effective and safe option for octogenarians. Surg Endosc 2010; 24: 1011–1016
3 *Arya N, Nelles SE, Haber GB* et al. Electrohydraulic lithotripsy in 111 patients: a safe and effective therapy for difficult bile duct stones. Am J Gastroenterol 2004; 99: 2330–2334
4 *Chen YK, Nichols MT, Antillon MR* et al. Peroral cholecystoscopy with electrohydraulic lithotripsy for treatment of symptomatic cholelithiasis in end-stage liver disease (with videos). Gastrointest Endosc 2008; 67: 132–135
5 *Binmoeller KF, Thonke F, Soehendra N*. Endoscopic treatment of Mirizzi's syndrome. Gastrointest Endosc 1993; 39: 532–536

Bibliography

DOI http://dx.doi.org/10.1055/s-0042-103928
Endoscopy 2016; 48: E88–E89
© Georg Thieme Verlag KG
Stuttgart · New York
ISSN 0013-726X

Corresponding author
Nauzer Forbes, MD
Therapeutic Endoscopy Program
University of Calgary
6D27, TRW Building 3280 Hospital Drive
NW Calgary Alberta T2N 4Z6, Canada
Fax: +1-403-5925090
nauzer.forbes@medportal.ca

This document was downloaded for personal use only. Unauthorized distribution is strictly prohibited.