

Resection of rectal carcinoids with the newly introduced endoscopic full-thickness resection device

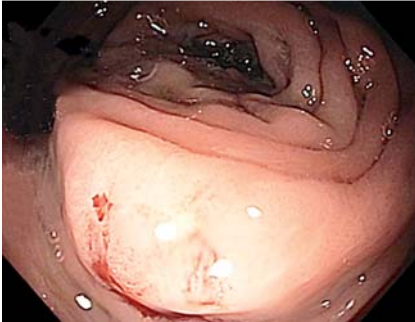


Fig. 1 Endoscopy revealed a small polypoid ulcer with protruding walls.

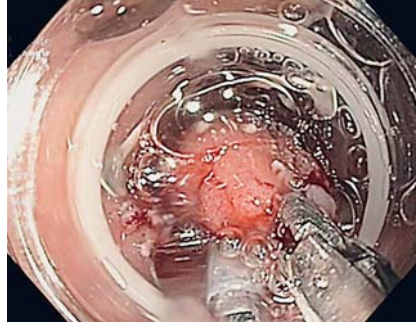


Fig. 2 The lesion was grasped with the grasping forceps and pulled into the clear distal cap of the full-thickness resection device (Ovesco, Tübingen, Germany).

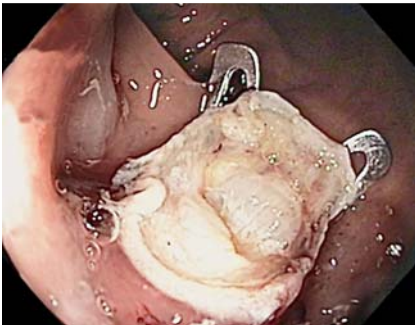


Fig. 3 Resection site after endoscopic full-thickness resection, with the over-the-scope clip (Ovesco, Tübingen, Germany) in place.

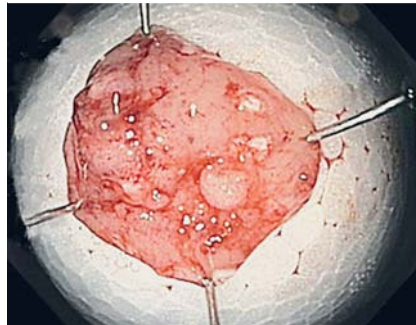


Fig. 4 Resection specimen pinned onto cork, showing the lateral argon plasma coagulation markings.

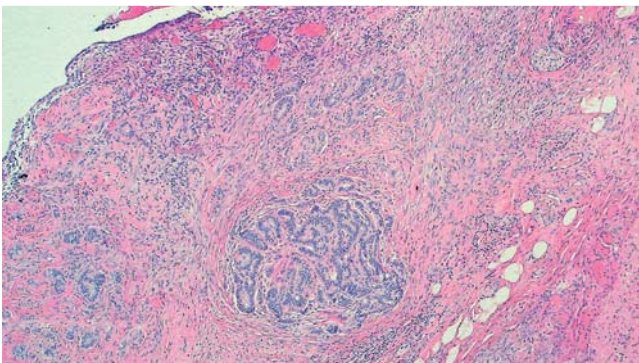


Fig. 5 Histology revealed a typical carcinoid tumor, R0 resected.


Rectal carcinoids show an increasing incidence and are malignant tumors that can metastasize [1]. According to the recent guidelines of the European Neuroendocrine Tumor Society, rectal carcinoids of less than 2 cm in diameter could be resected endoscopically [2]. As highlighted in a recent systematic review and meta-analysis, the best endoscopic treatment option is endoscopic submucosal dissection (ESD) or so-called modified endoscopic

mucosal resection techniques, including the band-ligation and cap-fitted techniques [3,4].

Here, we introduce for the first time the potential of the new endoscopic full-thickness resection device (FTRD; Ovesco, Tübingen, Germany) for the safe and effective removal of rectal carcinoid tumors.

A 55-year-old woman undergoing screening colonoscopy was found to have a rectal polyp of 5 mm, which was initially

Video 1



Resection of a rectal carcinoid using the full-thickness resection device (Ovesco, Tübingen, Germany).

resected using biopsy forceps. Histology revealed a rectal G1, R1, carcinoid, so the patient was referred to our unit 1 week later for further therapy. Endoscopy revealed a small polypoid ulcer with protruding walls that impeded rectal ESD (Fig. 1). Accordingly, the decision was made to resect the lesion using the FTRD. First, the lesion was marked circumferentially by argon plasma coagulation (Erbe VIO; Erbe, Tübingen, Germany). The FTRD was then mounted onto the endoscope, as previously described, and the endoscope was reinserted into the rectum [5]. The grasping forceps (Ovesco) was advanced through the working channel of the endoscope, and the lesion was grasped and subsequently pulled into the clear distal cap of the FTRD (Fig. 2). Next, an over-the-scope clip (OTSC; Ovesco) was deployed, thereby creating a full-thickness duplication of the colonic wall. Subsequently, the pseudopolyp above the clip was resected using the preloaded snare in Endo Cut Q mode, and the polyp was removed while inside the cap. Afterwards, the FTRD was removed from the scope and the resection site was inspected; there were no signs of bleeding or perforation (Fig. 3, Fig. 4). The total procedure time was 7 minutes.

A clear liquid diet was started 6 hours after the procedure, and the patient was discharged home after 2 days. Final histology revealed a full-thickness resection specimen with rectal carcinoid pT1, L0, V0, Pn0, R0; G1 (Fig. 5). Meanwhile we have successfully treated a second patient

with a rectal carcinoid (pT1a L0 V0 Pn0, R0, G1, sm3) using the FTRD (Video 1). This case is of interest for several reasons. This is the first description of endoscopic full-thickness resection of rectal carcinoids using the new FTRD. We have shown that endoscopic full-thickness resection of rectal carcinoids using the proposed technique is safe and effective to achieve R0 resection of tumors that are difficult to resect by standard resection techniques, such as those with submucosal fibrosis or ulcerous tissue. In addition, we provide a detailed description of the technical procedure, which may assist further use of the technique. Finally, our report adds to the growing literature on the use of advanced endoscopic resection methods for endoscopic removal of neuroendocrine tumors. In conclusion, our case highlights that, in properly selected patients, endoscopic resection of rectal carcinoid tumors using the FTRD is safe and effective, and permits a complete resection with no complications.

Endoscopy_UCTN_Code_TTT_1AQ_2AC

Competing interests: None

Martin Grauer¹, Andreas Gschwendtner², Claus Schäfer^{1,*}, Helmut Neumann^{3,*}

¹ Medical Clinic II, Klinikum Neumarkt, Neumarkt, Germany

² Institute of Pathology, Klinikum Amberg, Amberg, Germany

³ Department of Medicine 1, Interdisciplinary Endoscopy, University of Erlangen-Nuremberg, Erlangen, Germany

References

- 1 *de Mestier L, Brixi H, Gincul R et al.* Updating the management of patients with rectal neuroendocrine tumors. *Endoscopy* 2013; 45: 1039–1046
- 2 *Caplin M, Sundin A, Nillson O et al.* ENETS Consensus Guidelines for the management of patients with digestive neuroendocrine neoplasms: colorectal neuroendocrine neoplasms. *Neuroendocrinology* 2012; 95: 88–97
- 3 *Zhou X, Xie H, Xie L et al.* Endoscopic resection therapies for rectal neuroendocrine tumors: a systematic review and meta-analysis. *J Gastroenterol Hepatol* 2014; 29: 259–268

4 *Neumann H, Ramesh J, Wilcox CM et al.* Resection of carcinoids in the duodenal bulb using the band ligation technique with the Duette mucosectomy device. *Endoscopy* 2013; 45: 365–366

5 *Schmidt A, Bauerfeind P, Gubler C et al.* Endoscopic full-thickness resection in the colorectum with a novel over-the-scope device: first experience. *Endoscopy* 2015; 47: 719–725

Bibliography

DOI <http://dx.doi.org/10.1055/s-0042-104651>
Endoscopy 2016; 48: E123–E124
 © Georg Thieme Verlag KG
 Stuttgart · New York
 ISSN 0013-726X

Corresponding author

Helmut Neumann, MD, PhD

Department of Medicine I
 University of Erlangen-Nuremberg
 Ulmenweg 18
 91054 Erlangen
 Germany
 Fax: +49-9131-8535209
helmut.neumann@uk-erlangen.de

* These authors contributed equally to this work.