

PEG closure in the second attempt

Authors

Leif Schiffmann^{1,2,3}, Marin Roth⁴, Florian Kuehn³

Institutions

- ¹ Westmecklenburg-Klinikum, Hagenow, Germany
- ² Evangelische Krankenhaus Lippstadt, Lippstadt, Germany
- ³ Rostock University Medical Center, Rostock, Germany
- ⁴ Ovesco Endoscopy AG, Tübingen, Germany

submitted

12. February 2016

accepted after revision

18. April 2016

Bibliography

DOI <http://dx.doi.org/10.1055/s-0042-107071>
 Published online: 19.5.2016
 Endoscopy International Open 2016; 04: E759–E760
 © Georg Thieme Verlag KG
 Stuttgart · New York
 E-ISSN 2196-9736

Corresponding author

Leif Schiffmann
 Westmecklenburg-Klinikum
 Parkstr.12
 19230 Hagenow
 Germany
 leif@dr-schiffmann.de

Background and study aims: This case report demonstrates successful endoscopic treatment of a persistent gastrocutaneous fistula after removal of a percutaneous endoscopic gastrostomy (PEG) in a 21-year-old patient with mucoviscidosis after

lung transplantation. Because the initial OTSC clip (gastric) did not close the fistula sufficiently, we had to remove it and replace it with a larger OTSC clip (colon) in a second intervention. That clip finally sufficiently closed the fistula.

Introduction

Percutaneous endoscopic gastronomies (PEGs) are common for long-term feeding of patients. In some cases, PEG removal after a period of time is possible. Generally, the fistula closes spontaneously.

ing, there was discharge of chymus from the fistula in increasing amounts.

Because the patient wanted to have the fistula closed without undergoing an operative procedure, we offered to use an over-the-scope (OTSC) clip. During gastroscopy, the inner ostium of the PEG was identified using the tip of an endoscopic argon plasma coagulator as a sensing device and was closed with an OTSC clip (OTSC 11 a for gastroscopes). Unfortunately, fluids continued to run through the PEG channel. Therefore, we performed another gastroscopy. The clip was not optimally placed (▶ Fig. 2) and thus secretion continued from the stomach.

Four weeks later, we removed the former clip using the OVESCO DC Cutter. The tip of the Cutter is shaped like a C. It was placed on both thin sides of the clip (▶ Fig. 3a and ▶ Fig. 3b). A direct impulse current of 140A was used to heating the nitinol in the clip and separate it into two parts

Case report

We report on a 21-year-old patient who suffered from mucoviscidosis and had a PEG in place for more than 15 years. One year after lung transplantation, the patient's general condition had improved and the PEG was no longer necessary for feeding. However, the fistula did not close spontaneously within 6 months after the PEG removal (▶ Fig. 1a). Directly after eating and drink-

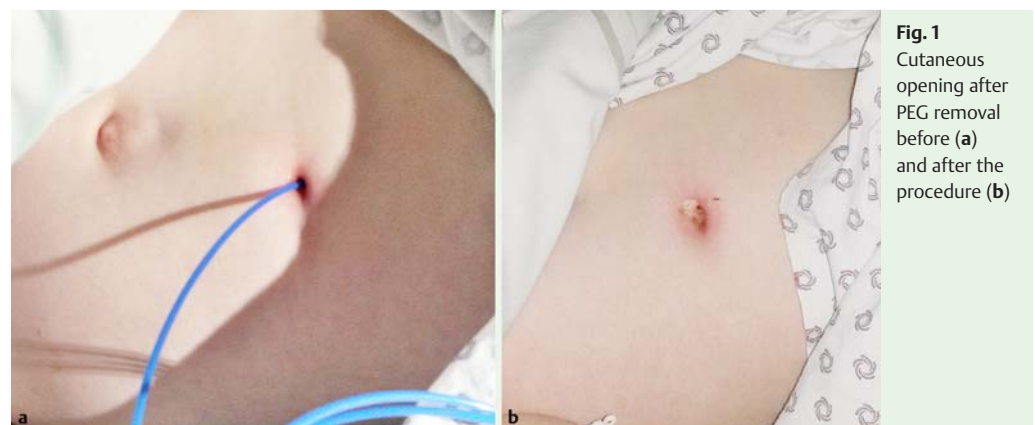


Fig. 1
 Cutaneous opening after PEG removal before (a) and after the procedure (b)

License terms



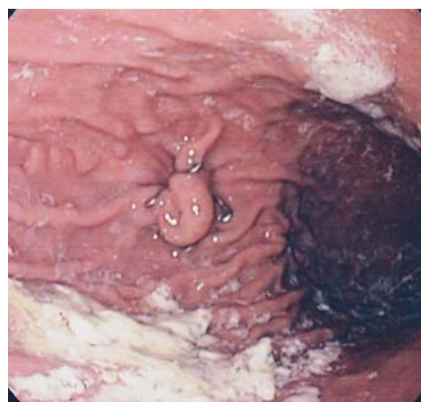

Fig. 2 Insufficient first OTSC clip

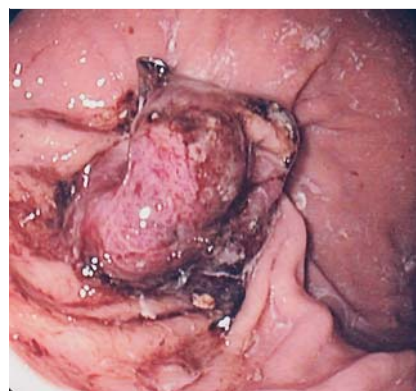


Fig. 4 New OTSC clip in situ

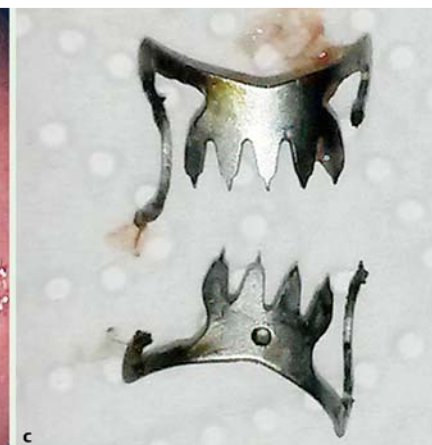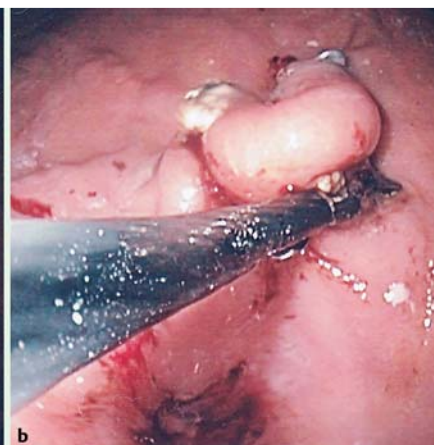

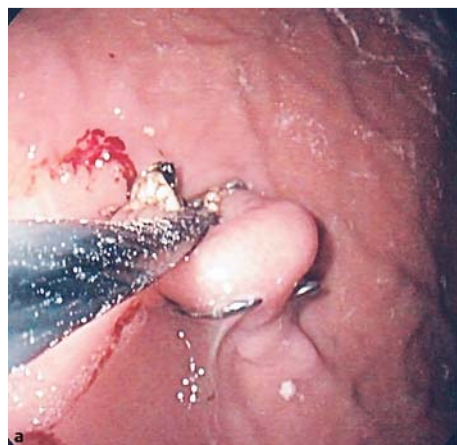
Fig. 3 Cutting the OTSC clip (a and b) and OTSC clip after salvage (c)

thermally (► **Fig. 3c**). With a grasper, the parts of the clip were pulled into a plastic cap on top of the endoscope and removed with the endoscope. (The plastic cap is necessary to avoid any damage to the wall of the esophagus). Then we debrided the fistula orifice with Argon Plasma Coagulation and placed a bigger OTSC clip (OTSC 14t for colonoscopes) using a simple Olympus colonoscope, thus closing the inner ostium. Both sides of the inner ostium were grabbed with the OVESCO Twin Grasper and the tissue was then pulled into the cap. Using this technique, we were able to place the clip precisely and sufficiently (► **Fig. 4**).

Since the procedure, fluid discharge from the patient's stomach has ceased (► **Fig. 1b**). The last consultation was 3 months after the clip placement.

Discussion

This is the first case report of cure of relapse leak from a PEG fistula after failed OTSC closure by removal of the first clip and replacement of it with a second, larger one in a single procedure. A special OTSC clip also exists for closure of anal fistulas (OTSC Proctology), which has been used successfully to treat high anal fistulas. The ordinary OTSC-Clip is used to control bleeding and to close fresh perforations in the upper and lower gastrointestinal tract. Outcomes with that device are so successful that its use is recommended by the European Society of Gastrointestinal Endoscopy for management of (iatrogenic endoscopic) gastrointestinal perforations [1].

The OTSC clip also has been used in other demanding situations. With the OTSC system, Bertolini et al. successfully closed a gastrocolocutaneous PEG migration colonoscopically [2].

In our case, we had the rare combination of a very old PEG channel in an immune-compromised patient after lung transplantation. We used the OTSC clip to close the channel because we believed that the procedure would be easy and represent a low risk to the patient. The only negative aspect was that we had to repeat the procedure. We assume that, during the first attempt at closure, the clip was not properly attached to both edges of the inner ostium of the fistula. The tissue around the inner ostium was probably too scarred and firm for the small atraumatic clip. We have placed several other clips before for fresh perforations or bleeding without any problems. To increase the rate of success with closure of large and complex fistulas like this one, it is of utmost importance use tools such as the Anchor or the Twin Grasper to enclose in the device sufficient tissue from both edges of the fistula and, after the closure is complete, to ensure that not too much tension is placed on the tissue.

Competing interests: Martin Roth works for Ovesco AG.

References

- 1 Paspatis GA, Dumonceau JM, Barthet M et al. Diagnosis and management of iatrogenic endoscopic perforations: European Society of Gastrointestinal Endoscopy (ESGE) Position Statement. *Endoscopy* 2014; 46: 693–711
- 2 Bertolini R, Meyenberger C, Sulz MC. First report of colonoscopic closure of a gastrocolocutaneous PEG migration with the over-the-scope-clip system. *World J Gastroenterol* 2014; 20: 11439–1442