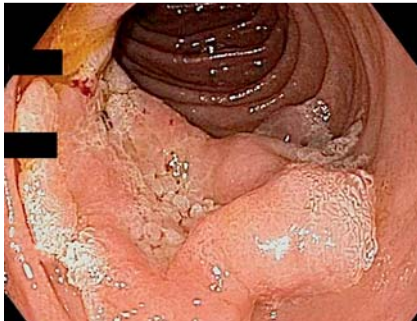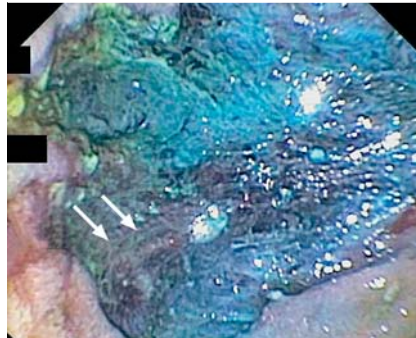


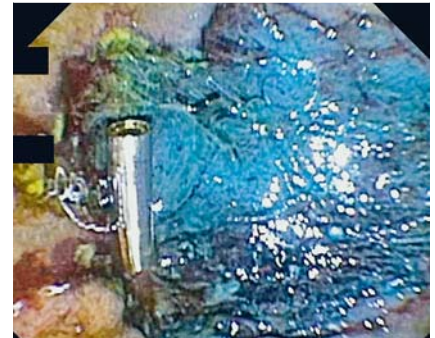
## Delayed perforation caused by an endoscopic clip following uncomplicated endoscopic resection of a large sporadic nonampullary duodenal adenoma



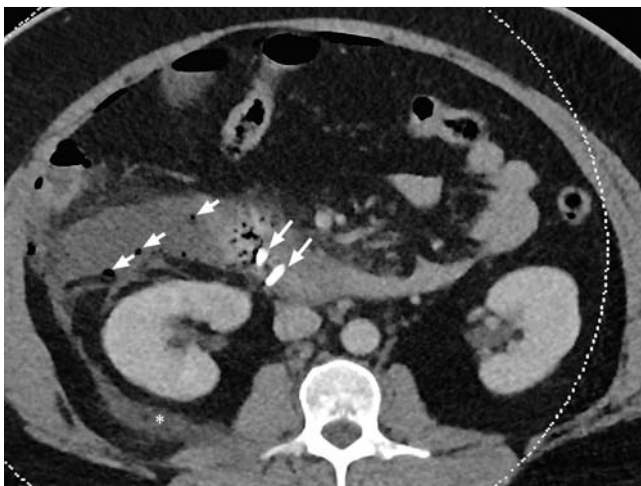
**Fig. 1** Duodenal adenoma prior to endoscopic mucosal resection. The adenoma was just distal to the ampulla and involved half the duodenal circumference.



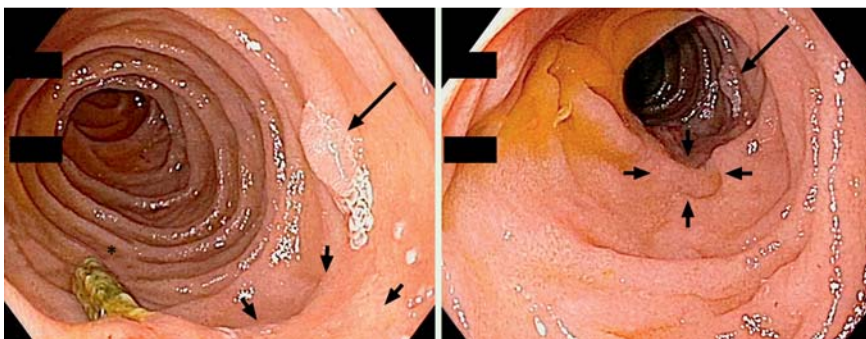
**Fig. 2** Endoscopic mucosal resection site (lateral descending duodenal wall), with arrows marking the subsequently clipped submucosal vessel.



**Fig. 3** A hemostatic clip (Instinct Endoscopic Hemoclip; Cook Medical, Limerick, Ireland) was placed over the vessel. A second clip was placed further distally and is not shown.



**Fig. 4** Axial contrast-enhanced computed tomography scan of the upper abdomen. Multiple retroperitoneal gas locules (arrowheads) surround the two duodenal hemostatic clips (arrows). Extensive edema and fat stranding extends to the right perinephric space and Gerotas fascia (star).



**Fig. 5** Scar (arrow heads), residual adenoma (long arrow), and clip (star) on follow-up endoscopy 1 year later.

A 42-year-old woman was referred for resection of a sporadic, 60-mm, high grade tubulovillous adenoma in the descending duodenum (Fig. 1). Submucosal injection of gelofusine, methylene blue, and diluted adrenaline (Fig. 2) was followed by piecemeal endoscopic mucosal resec-

tion (EMR) using an EVIS EXERA II 180 duodenoscope (Olympus, Tokyo, Japan) and snare (SnareMaster SD-230U-20; Olympus). Minor bleeding from vessels along the lateral resection margin settled spontaneously, and two clips (Instinct Hemoclip; Cook Medical, Limerick, Ire-

land) were placed, taking care to grasp adjacent mucosa (Fig. 3). The EMR site was carefully re-inspected and no further bleeding was observed.

Overnight the patient developed abdominal pain and fever. Computed tomography scan showed a moderate amount of free retroperitoneal air and fluid consistent with duodenal perforation (Fig. 4). Intraoperative findings revealed that one clip had perforated the duodenum, and was protruding into the retroperitoneum. The area was debrided and duodenal exclusion was performed. The perforation was managed with T-tube placement into the duodenal lumen.

Histology confirmed high grade tubulovillous adenoma with no involvement of the muscularis propria. Surveillance endoscopy at 6 months revealed a scar with an adjacent area of residual adenoma that was amenable to further resection (Fig. 5).

EMR is a highly effective and widely practiced method for removing large adenomatous polyps in the gastrointestinal tract [1,2]. In the richly vascularized, thin-walled, and relatively fixed duodenum, bleeding and perforations are known complications of EMR and the risks increase with polyp size [2,3]. Delayed bleeding occurs in 30% of cases [4,5]. Coagulation techniques have been suggested for the treatment of immediate or delayed bleeding, though this may increase the risk of perforation. Endoscopic clips are a well established treatment for bleeding and perfora-

tion in the entire gastrointestinal tract. However, we believe clips should be used with great caution following wide field EMR in the duodenum because of the risk of clip-related delayed perforation.

Endoscopy\_UCTN\_Code\_CPL\_1AH\_2AZ

**Competing interests:** None

**Moritz von Wulffen<sup>1,2</sup>, Alexander Huelsen<sup>1,2</sup>, Tom O'Rourke<sup>2,3</sup>, Nivene Saad<sup>2,4</sup>, Saurabh Gupta<sup>1,2</sup>**

<sup>1</sup> Department of Gastroenterology and Hepatology, Princess Alexandra Hospital, Brisbane, Queensland, Australia

<sup>2</sup> School of Medicine, University of Queensland, Brisbane, Queensland, Australia

<sup>3</sup> Department of Hepatobiliary Surgery, Princess Alexandra Hospital, Brisbane, Queensland, Australia

<sup>4</sup> Department of Radiology, Princess Alexandra Hospital, Brisbane, Queensland, Australia

## References

- 1 Lepilliez V, Chemaly M, Ponchon T et al. Endoscopic resection of sporadic duodenal adenomas: an efficient technique with a substantial risk of delayed bleeding. *Endoscopy* 2008; 40: 806–810
- 2 Aschmoneit-Messer I, Richl J, Pohl J et al. Prospective study of acute complication rates and associated risk factors in endoscopic therapy for duodenal adenomas. *Surg Endosc* 2015; 29: 1823–1830
- 3 Chathadi KV, Khashab MA, Acosta RD et al. The role of endoscopy in ampullary and duodenal adenomas. *Gastrointest Endosc* 2015; 82: 773–781
- 4 Bourke MJ. Endoscopic resection in the duodenum: current limitations and future directions. *Endoscopy* 2013; 45: 127–132
- 5 Fanning SB, Bourke MJ, Williams SJ et al. Giant laterally spreading tumors of the duodenum: endoscopic resection outcomes, limitations, and caveats. *Gastrointest Endosc* 2012; 75: 805–812

## Bibliography

**DOI** <http://dx.doi.org/10.1055/s-0042-109053>  
*Endoscopy* 2016; 48: E211–E212  
 © Georg Thieme Verlag KG  
 Stuttgart · New York  
 ISSN 0013-726X

## Corresponding author

**Moritz von Wulffen, MD**

Department of Gastroenterology and Hepatology  
 Princess Alexandra Hospital  
 199 Ipswich Road  
 Woolloongabba  
 Queensland 4102  
 Australia  
 Fax: +61-7-31765111  
 m.vonwulffen@uq.edu.au