

Endoscopic esophageal perforation extending upwards along the carotid arteries

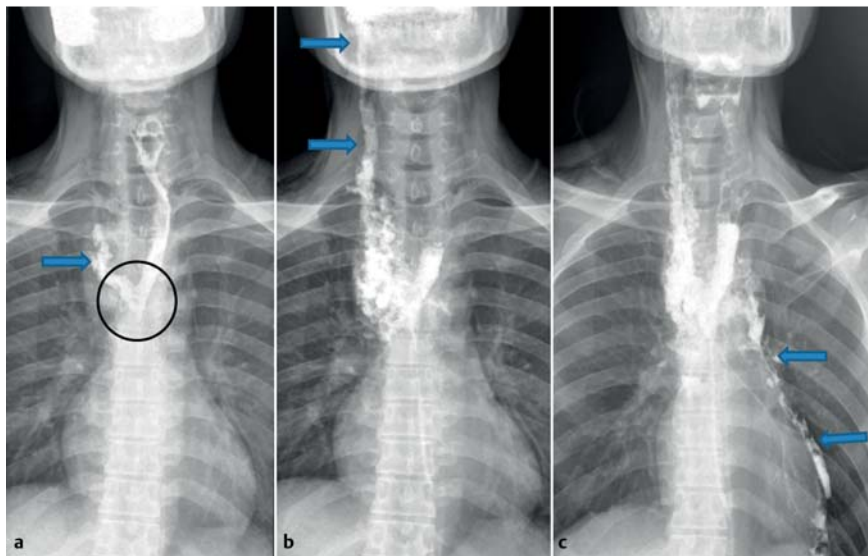


Fig. 1 A 21-year-old man complained of neck pain following second dilation procedure for an esophageal stricture caused by ingestion of a corrosive agent. Fluoroscopic images following oral contrast administration showing: **a** contrast leak (arrow and circle) from the mid esophagus; **b** the contrast tracking along the carotid sheath on the right side (arrows); **c** the contrast then spreading along the surface of the pericardium (arrows).

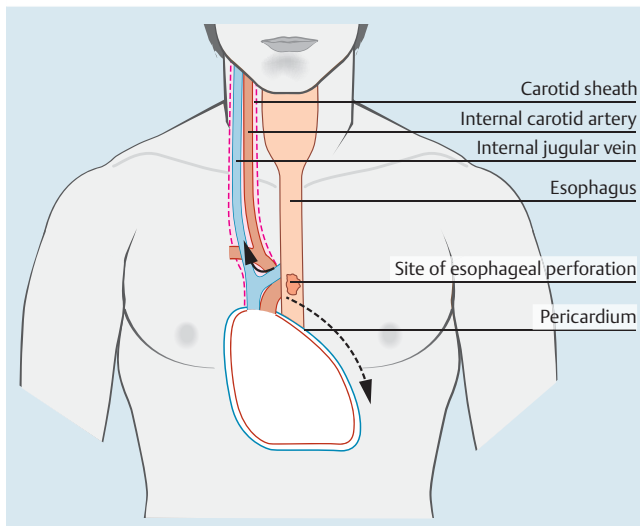
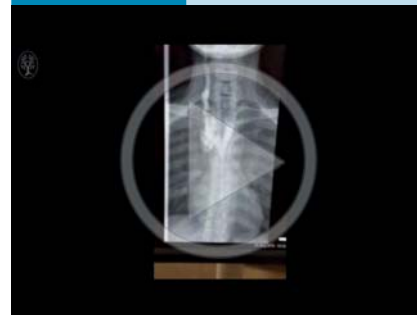

Fig. 2 Schematic diagram showing the site of the esophageal perforation and leaking of contrast along the carotid sheath (solid arrow) and over the surface of the pericardium (dotted arrow).

A 21-year-old man presented to gastroenterology services with progressive dysphagia, 6 weeks after ingestion of dichlorvos (2,2-dichlorovinyl dimethyl phosphate), an organophosphate insecticide used to control household pests. Barium swallow revealed a long stricture involving the middle and lower thirds of the esophagus. The difficulties, complications, and failure rates of endoscopic dilation for long strictures were explained to the pa-

tient, and surgery was advised. However, the patient wanted a trial of endoscopic management prior to surgery. Esophagogastroduodenoscopy revealed a stricture starting at 20 cm from the incisors. It was dilated up to 10 mm with a controlled radial expansion (CRE) balloon (CRE single-use wireguided balloon dilator; Boston Scientific, Natick, Massachusetts, USA). However, the endoscope could not be negotiated beyond the stricture. A

Video 1



Contrast esophagogram, following attempted endoscopic balloon dilation for a benign esophageal stricture, reveals leaking from the mid esophagus. The contrast is seen to track progressively along the right side of the neck in the expected location of the carotid sheath.

week later, a second session of endoscopic dilation was performed with an 8 – 10-mm balloon (Boston Scientific), during which the first stricture at 20 cm was dilated up to 10 mm, and the scope could be negotiated past the stricture. A second stricture starting at 24 cm was noted, and this was dilated up to 10 mm. After dilation, the scope could be passed as far as 27 cm; but further advancement was abandoned because of a circumferential ulceration seen at 27 cm.

In the immediate post-procedure period, the patient complained of right-sided neck pain. On examination, mild crepitus was felt, raising suspicion of an iatrogenic esophageal perforation. Water-soluble contrast study revealed a leak in the mid esophagus. The contrast was seen to track into the neck along the right carotid sheath as far as the skull base. Later the contrast outlined the left pericardial surface (● Fig. 1, ● Video 1).

Our patient was immediately taken for surgery. Intraoperatively, a 3 × 1-cm perforation was seen, 10 cm below the cricopharynx. Transhiatal esophagectomy with cervical esophagostomy was done. A feeding jejunostomy was also created. The patient was discharged after an uneventful 1-week postoperative period. The patient's condition is being improved for definitive surgery.

The carotid sheath is a condensation of cervical fascia around the common and

internal carotid arteries, the vagus nerve, and the internal jugular vein, with contributions from prevertebral, pretracheal, and deep cervical fascias. The prevertebral lamina of the cervical fascia covers anterior vertebral muscles; its superior extension is attached to the base of the skull and inferiorly it extends to the superior mediastinum and blends with the anterior longitudinal ligament. The pretracheal lamina is very thin; it is attached superiorly to the arch of the cricoid cartilage, and continues below as far as the superior mediastinum, where it fuses with the pericardium [1,2]. The esophagus and trachea are located in the space between the pretracheal and prevertebral fascia. In our patient, the leak site was at the level of the T4 vertebra (Fig. 2). The contrast first leaked into the middle mediastinum on the right side and later tracked up along the right carotid sheath to the base of skull, then spreading to the left pericardial surface (Fig. 2). Although dichlorvos is a potentially corrosive agent, to the best of our knowledge, no human case of esophageal stricture caused by dichlorvos has been reported

so far in the literature. Esophageal perforation can occur in 0.1%–0.3% patients during routine endoscopy [3,4]. Neck pain is a common presentation after cervical esophageal perforation; however, it is rarely observed in cases of thoracic esophageal perforation. Also, contrast extravasation along the carotid vessels is rare; in the present case it can be explained on the basis of the fascial attachments.

Endoscopy_UCTN_Code_CPL_1AH_2AG

Competing interests: None

Yalaka R. Reddy¹, Pankaj Gupta², Sarthak Malik¹, Bipada Mallick¹, Anupam Lal², Saroj K. Sinha¹, Rakesh Kochhar¹

¹ Department of Gastroenterology, Postgraduate Institute of Medical Education and Research, Chandigarh, India

² Department of Radiodiagnosis, Postgraduate Institute of Medical Education and Research, Chandigarh, India

References

- 1 Standring S, Borley NR, Collins P et al., eds. Gray's anatomy: Anatomical basis of clinical practice. 40th edn. London: Churchill Livingstone, Elsevier; 2008
- 2 Sinnatamby CS, ed. Last's anatomy: Regional and applied. 12th edn. London: Churchill Livingstone, Elsevier; 2011
- 3 Pereira-Lima JC, Ramires RP, Zamin I Jr et al. Endoscopic dilation of benign esophageal strictures: report on 1043 procedures. Am J Gastroenterol 1999; 94: 1497–1501
- 4 Hernandez LV, Jacobson JW, Harris MS. Comparison among the perforation rates of Maloney, balloon, and Savary dilation of esophageal strictures. Gastrointest Endosc 2000; 51: 460–462

Bibliography

DOI <http://dx.doi.org/10.1055/s-0042-109698>
Endoscopy 2016; 48: E240–E241
© Georg Thieme Verlag KG
Stuttgart · New York
ISSN 0013-726X

Corresponding author

Yalaka R. Reddy, MD, DM
Department of Gastroenterology
Postgraduate Institute of Medical Education and Research (PGIMER)
Sector 12, Chandigarh
India 160012
Fax: +91-40-32213369
yrrpgi@gmail.com