

Endoscopic septotomy of a magnet-induced neo-septum in a large mid-esophageal diverticulum

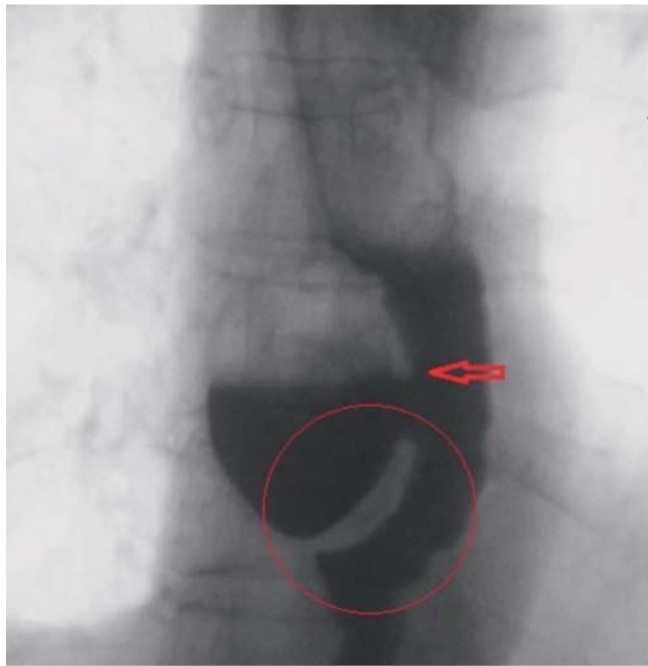


Fig. 1 Esophagogram showing a mid-esophageal diverticulum with a narrow neck.

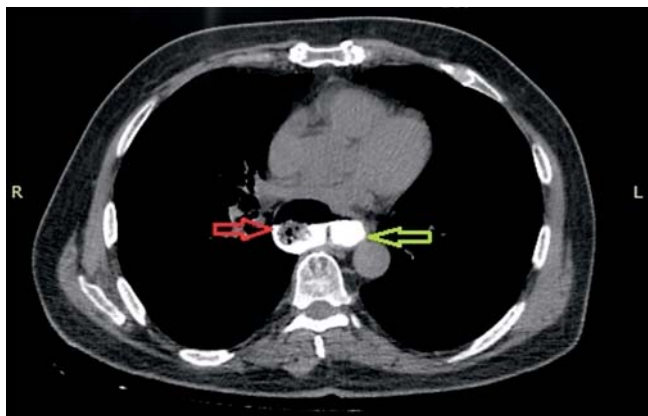


Fig. 2 Computed tomography (CT) image of the esophageal diverticulum.

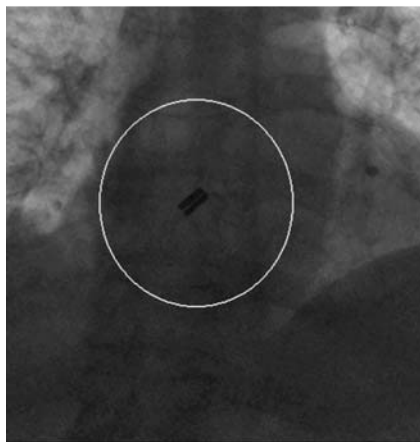


Fig. 3 Radiographic image showing the magnets in position and attracted to each other to form a neo-septum.

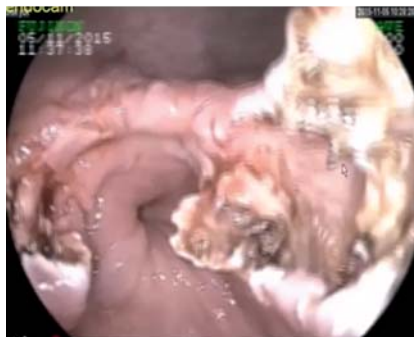

Fig. 4 Endoscopic view after neo-septotomy had been performed.

A 72-year-old man who was complaining of dysphagia, regurgitation, and difficulty with passage through the esophagus was diagnosed with a mid-esophageal diverticulum with a diameter of 40 mm. A contrast esophagogram (▶ **Fig. 1**), a computed tomography (CT) scan (▶ **Fig. 2**), and an endoscopic examination revealed that the diverticulum had a narrow neck and was filled with food particles. Because of the patient's age and comorbidities, which included coronary heart disease and hypertension, and his reluctance to undergo major surgery, non-surgical treatment options were explored. Inspired by a mini-series involving three cases [1], we attempted to use magnets to perform a fusion between the esophageal wall and the wall of the diverticula to induce a neo-septum. Once the neo-septum had been formed, it would be possible to perform septotomy with electrocautery and to widen the narrow neck so that food could washout easily, thereby avoiding obstructive symptoms.

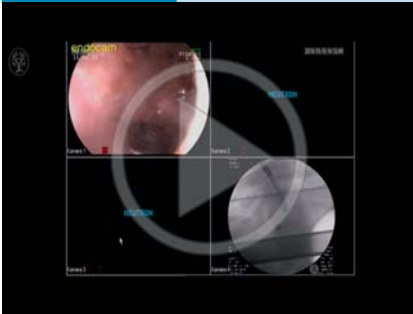
One of the ring-shaped magnets was stabilized in the gastric lumen with a grasper and the other magnet was placed at the base of the diverticulum. The magnet in the diverticulum was held steady as the gastric magnet was pulled up through the esophageal lumen. When the two magnets reached the same plane, they were attracted to each other, thereby causing the base of the diverticulum to fuse with the esophageal wall (▶ **Fig. 3**). By 4 weeks after the procedure a neo-septum had been formed through the pressure and attraction between the magnets. Diverticular septotomy with a needle-knife and marsupialization of the diverticulum were performed without complications (▶ **Fig. 4**; ▶ **Video 1**). After 10 days, the patient was asymptomatic and a repeat contrast esophagogram showed a diverticulum with a wide neck that allowed contrast material to evacuate easily (▶ **Fig. 5**).

This report is the second in the literature detailing treatment of an esophageal diverticulum using endoscopic septotomy of a neo-septum induced by magnets. These endoscopic procedures allowed the patient to avoid major surgery with satisfactory results and no complications.

Endoscopy_UCTN_Code_TTT_1AO_2AN

Competing interests: None

Video 1



Radiographic and endoscopic views of magnets being placed to induce a neoseptum and, 4 weeks later, diverticular septotomy and marsupialization of the diverticulum being performed.

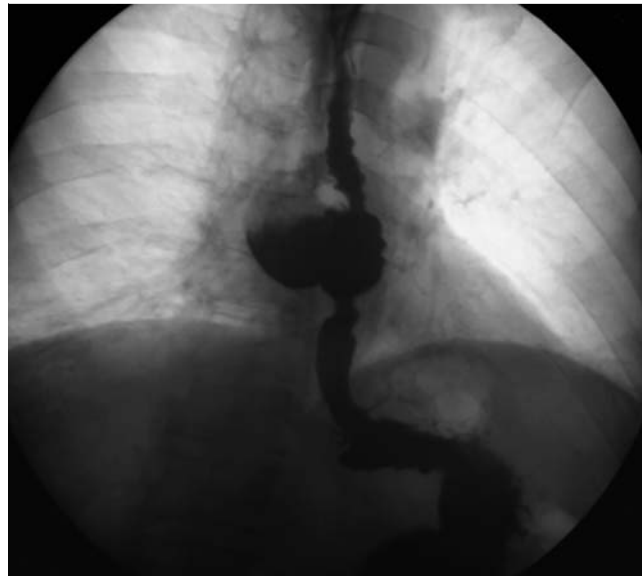


Fig. 5 Esophagogram showing easy evacuation of contrast medium from the wide neck of the diverticulum after neoseptotomy.

**Selcuk Disibeyaz, Fatih Saygili,
Erkin Oztas, Orhan Coskun**

Gastroenterology Clinic, Turkiye Yuksek
Ihtisas Education and Research Hospital,
Ankara, Turkey

Reference

- 1 Bouchard S, Huberty V, Blero D et al. Endoscopic treatment of large esophageal diverticula using a magnetic anastomosis device: report of three cases. *Gastrointest Endosc* 2015; 81 Suppl: AB455

Bibliography

DOI <http://dx.doi.org/10.1055/s-0042-110486>
Endoscopy 2016; 48: E244–E245
 © Georg Thieme Verlag KG
 Stuttgart · New York
 ISSN 0013-726X

Corresponding author

Fatih Saygili, MD
 Turkiye Yuksek Ihtisas Training
 and Research Hospital
 Sihhiye
 06040 Ankara
 Turkey
 Fax: +90-312-3124120
 fsaygili78@yahoo.com