Pedunculated gastric neuroendocrine tumor: a case report

Authors Kenichi Takeda[1,2], Shin-ei Kudo[1], Fumio Ishida[1]

Institutions [1] Digestive Disease Center, Showa University Northern Yokohama Hospital
[2] Department of Gastroenterological Medicine, Kakunodate Municipal Hospital

submitted 15. April 2016
accepted after revision 19. August 2016

Bibliography
DOI http://dx.doi.org/10.1055/s-0042-116489
Published online: 30.9.2016
Endoscopy International Open 2016; 04: E1136–E1139

E-ISSN 2196-9736

Corresponding author
Shin-ei Kudo
Digestive Disease Center
Showa University Northern Yokohama Hospital
35-1 Chigasaki-chuo, Tsuzuki
Yokohama 224-8503
Japan
Fax: +81-045-949-7263
kudos@med.showa-u.ac.jp

Background and study aims: Gastric neuroendocrine tumors (NETs) are rare lesions that develop from neuroendocrine cells. NETs are classified into 3 types based on the rate of mitosis and Ki-67 labeling index; the NET G1 type is synonymously referred to as carcinoid. Gastric NETs are usually discovered as submucosal tumors during upper gastrointestinal endoscopic examination. This study reports a rare case of pedunculated gastric NET. The lesion was found as a result of gastroendoscopy. The gastric lesion was a pedunculated polyp with a reddish head. We performed endoscopic submucosal dissection and an en-bloc resection of the gastric lesion. The resected specimen was evaluated histopathologically and diagnosed as a carcinoid (NET G1).

Introduction

Neuroendocrine tumors (NETs) are neoplasms that develop from the neuroendocrine cells of diffuse neuroendocrine systems. Gastric NETs are rare lesions, representing approximately 7% of all NETs and less than 1% of all stomach neoplasms [1]. According to the histologic classification of tumors developed by the World Health Organization in 2010, NETs are classified as G1 to G3 based on the rate of mitosis and the Ki-67 labeling index; NET G1 is synonymously referred to as a carcinoid [2,3]. The prevalence of NETs is relatively high, as many NETs are slow-growing or of uncertain malignant potential, and even malignant NETs are associated with prolonged survival [4].
Gastric NETs usually have the endoscopic appearance of a submucosal tumor, as they grow from deep within the mucosal layers [5,6]. A pedunculated gastric NET is very rare. Herein, we report a case of an 87-year-old man with a pedunculated gastric NET treated by endoscopic surgery.

Case Report

An 87-year-old man was hospitalized because of abdominal pain. He had a history of hypertension and was taking medication to lower blood pressure (enalapril maleate 2.5 mg/day, amlodipine besilate 5 mg/day). We performed gastroendoscopy to search for disease of the gastrointestinal tract and found a polypoid lesion in the stomach. The gastric lesion was a pedunculated polyp with a reddish head (**Fig. 1**, **Fig. 2**). The lesion was 20 mm in diameter. The borderline of epithelial change between the head and the stalk region was unclear endoscopically. Observation with a narrow band image system revealed dilated vessels at the head of the lesion. Because the stalk of the lesion was thick and rich in inflammatory change (**Fig. 1**, **Fig. 2**), we were concerned that if the polyp was neoplastic, the lesion could have potentially invaded the stalk. We were also concerned that the lesion could potentially have had a thick tumor-feeding blood vessel, especially a thick feeding artery, in its stalk. The polypoid lesion was biopsied, and histopathological examination revealed hyperplastic tissue.
Because the patient and his family hoped to have the gastric lesion resected endoscopically, we planned to perform endoscopic treatment for the polypoid lesion in the stomach. We decided to perform endoscopic submucosal dissection (ESD), which would enable us to resect the lesion en-bloc and also allow us to confirm blood vessels as needed during procedure. An en-bloc resection was done without any trouble associated with endoscopic treatment. The resected specimen was evaluated histopathologically (**Fig. 3**). The mucosa surrounding the lesion was highly atrophic with intestinal metaplasia. The tumor cells had a solid structural appearance from the deep mucosal layer to the submucosal layer. Immunostaining examinations were conducted, and the lesion was found to be positive for chro-

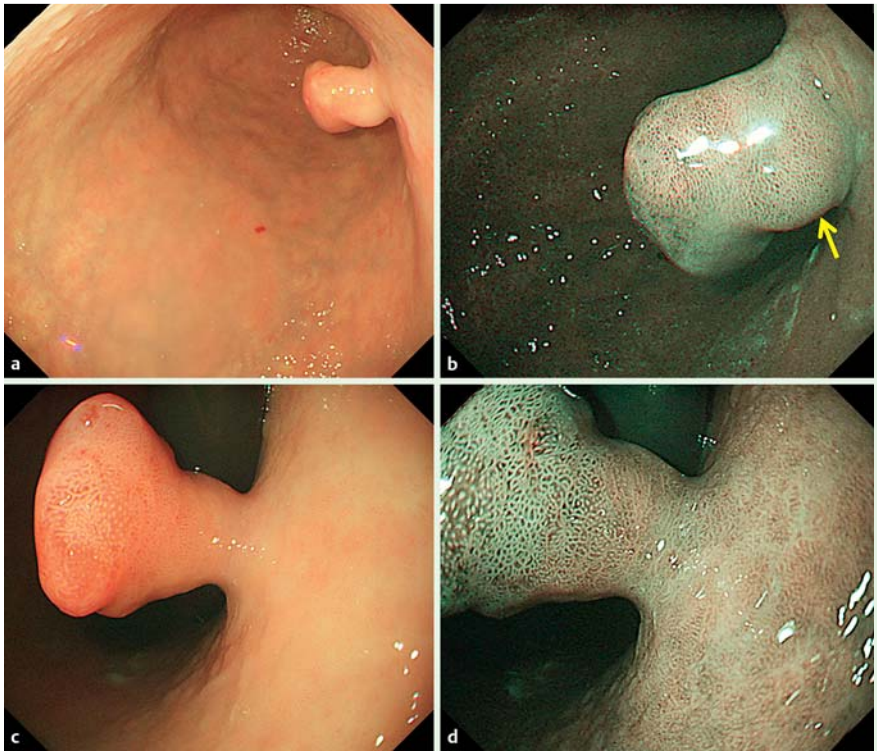

Fig. 1 Endoscopic images of the carcinoid tumor. **a** and **b**: view of the tumor looking down from the oral side. **c** and **d**: view of the tumor looking up from the anal side. **a** White light image of the carcinoid tumor located posterior to the corpus. The tumor was about 20 mm in diameter. **b** Narrow band image showing a bulging area (yellow arrow) on the tumor stalk. **c** White light image of the tumor showing its reddish head compared with the stalk. **d** Narrow band image showing a lack of dilated vessels in the stalk. The demarcation line between the head and the stalk was unclear.

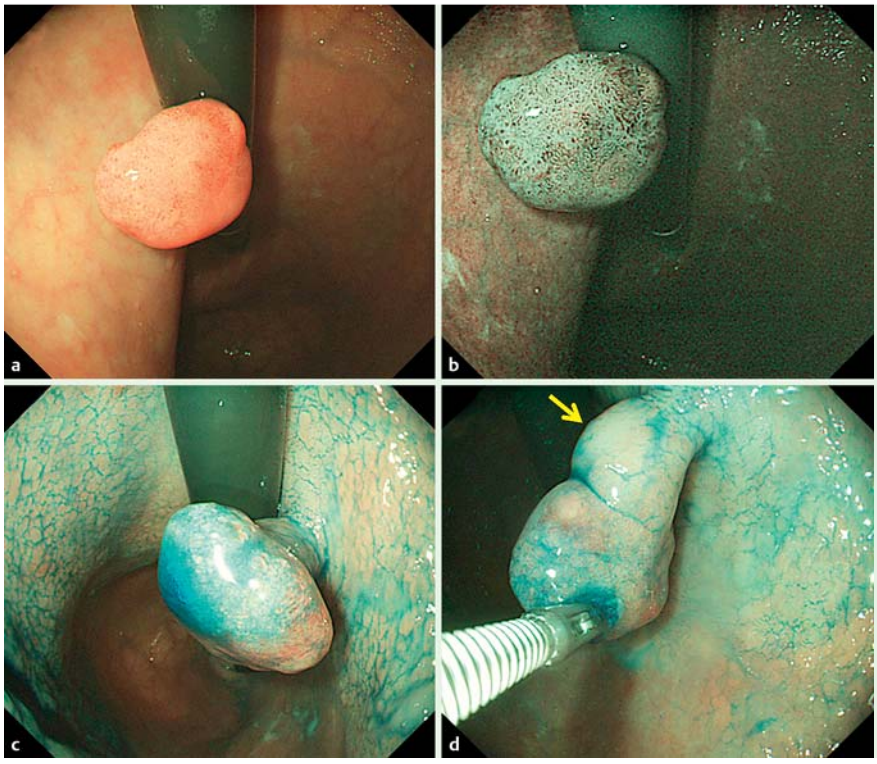

Fig. 2 Endoscopic images of the carcinoid tumor looking up from the anal side. **a** White light image showing that the head portion was reddish and had an eroded mucosal area. **b** Narrow band image showing dilated vessels on the head portion of the tumor; in some areas the vessels were unclear because of erosion caused by inflammation. After spraying with indigo carmine, **c** the head portion of the tumor was coated with mucus, especially in the eroded area, and the surface of the tumor was relatively smooth. **d** While there was a color difference between the head and the stalk, the tumor appeared to form a seamless surface. From this view, the bulging area of the tumor stalk (yellow arrow) was more visible.

mogranin A and synaptophysin (▶ **Fig. 4**). Although pseudopyloric glands were not observed, endocrine cell micronests (ECMs) were observed. The Ki-67 positive index was less than 2%. Thus, the lesion was finally diagnosed pathologically as an NET G1, pM-pSM, ly0(D2–40), v0(EM), pHM0, pVM0 (▶ **Fig. 4**).

Computed tomography showed no evidence of pituitary tumor or pancreatic tumor. The serum gastrin level evaluated 9 months after the patient stopped taking a proton pump inhibitor was elevated at 552 pg/ml (normal range: 42–200 pg/ml). We biopsied the mucosa of the gastric antrum, and found no evidence of overexpression of G cells pathologically. Chronic gastritis was widely seen endoscopically, and the *Helicobacter pylori* antibody titer was markedly increased at 24.3 U/mL (normal range: <10 U/mL). The serum level of vitamin B12 was 879 pg/mL (normal range: 233–914 pg/ml), and serotonin was 154.5 ng/ml (normal range: 81–262 ng/ml). The results for anti-parietal cell antibody and anti-intrinsic factor were negative.

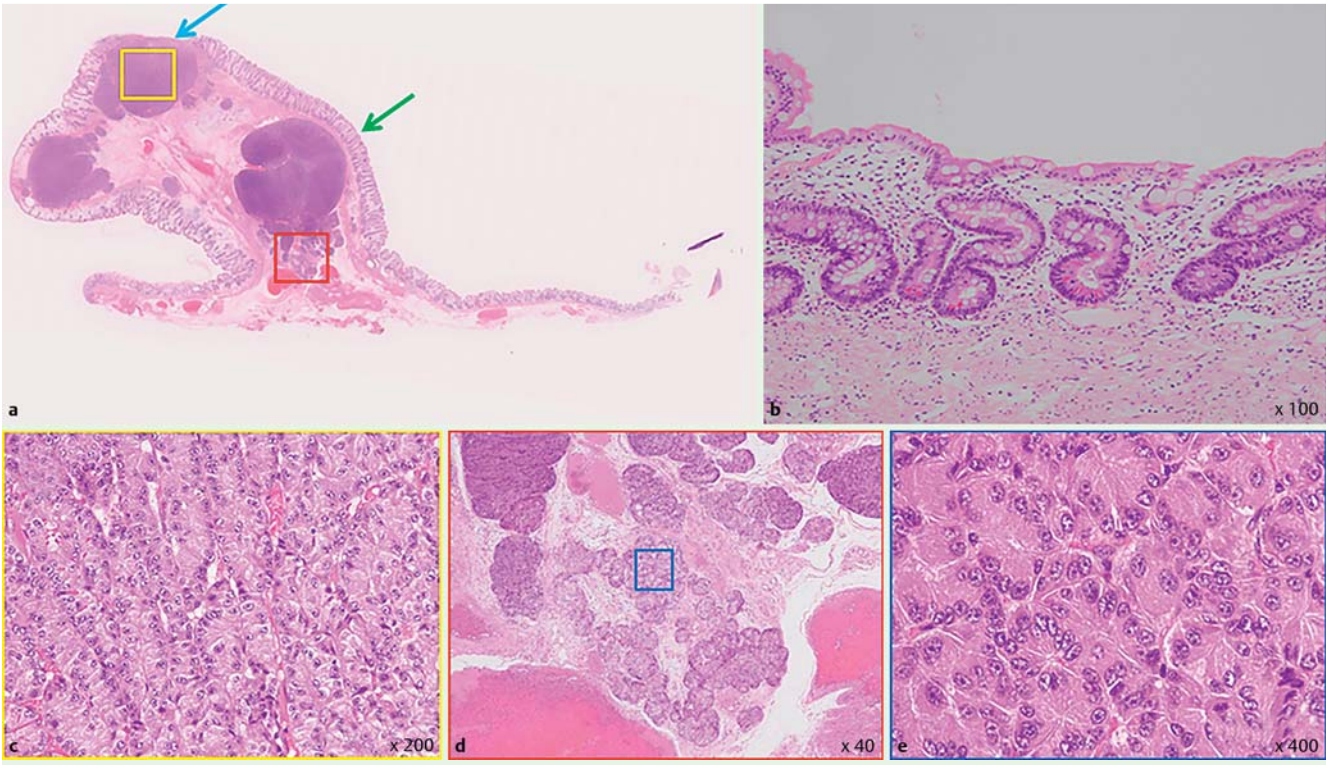

Fig. 3 Tissue cross-sections stained with hematoxylin & eosin. **a** Loupe image of the carcinoid. The head of the tumor had a mucosal deficit caused by biopsy (blue arrow). The bulging area is again apparent; the loupe image shows that this was caused by the carcinoid mass (green arrow). **b** The mucosa surrounding the lesion contained highly atrophic changes. **c** Small tumor cells with small rounded or oval nuclei formed cord-like structures. **d** and **e**: In the stalk of the tumor there were carcinoid tumor cells forming honeycombed structures.

After extended consultation with the patient and his family, who preferred to avoid surgical treatment, we decided on a strategy of close monitoring without additional surgical treatment. We checked the condition of the patient periodically, and computed tomography and gastroendoscopy showed no evidence of local or other metastatic recurrences. One year after the ESD was performed, the patient was in good condition without carcinoid tumor recurrence.

Discussion

Gastric NETs are classified into 3 subtypes: Type I lesions arising in patients with chronic atrophic gastritis, including autoimmune gastritis and *H. pylori*-associated atrophic gastritis; Type II lesions associated with gastrin-producing neoplasms in patients with multiple endocrine neoplasia or Zollinger–Ellison syndrome; and Type III gastric lesions, which are sporadic carcinoids without specific background factors [7]. In this case, the disease was negative for both anti-parietal cell antibody and anti-intrinsic factor. However, the gastric mucosa was highly atrophic, with *H. pylori* infection, elevated gastrin, and the presence of ECMs. Hence, we diagnosed the lesion as a type I gastric carcinoid.

The aim in treating gastric NET should always be to maintain good quality of life for as long as possible [4]. Carcinoids generally have an excellent prognosis, especially type I gastric carcinoid tumors, which have low malignant potential and low frequency of metastasis [4,7,8]. Patients managed by lesion resection and endoscopic follow-up have a 100% survival rate when the lesions are confined to the submucosa and there are no metastases during observation [8]. In many cases surveillance only is appropriate, although limited surgery with endoscopic polypectomy and/or antrectomy may be preferable [4].

In the current case, the patient had hoped for endoscopic treatment of his gastric lesion. ESD is reportedly more feasible than endoscopic mucosal resection for removal of type I gastric carcinoid [7]. Complete histologic resection was performed by ESD in the current case, and no complications such as bleeding or gastric perforation occurred during or after endoscopic treatment. If polypectomy had been performed for this lesion, the cut edge of the tumor would have been positive for neoplasia, because the carcinoid tumor had invaded to the level of the submucosal layer in the stalk of the polyp.

Pedunculated carcinoid tumor is very rare, and there are only a few previously reported cases [9,10]. However, the previous reports did not contain detailed endoscopic findings or images of pedunculated carcinoid tumor. In this report, we describe detailed endoscopic findings of pedunculated carcinoid tumor with endoscopic images (**Fig. 1**, **Fig. 2**). As this was our first case of pedunculated gastric carcinoid tumor, we did not initially consider the lesion a carcinoid tumor. This case shows that it is difficult to immediately diagnose a NET based on endoscopic findings. Based on the endoscopic findings in the current case, we initially believed that the lesion was potentially a hyperplastic polyp or neoplastic lesion with strong inflammatory changes on its surface. Fisher reported that a pedunculated gastric carcinoid develops because peristalsis causes formation of a pedicle and a pedunculated polyp [9]. Peristalsis could misalign the carcinoid tumor and the gastric muscle layer, and cause the tumor to extend to the submucosal layer toward the inner cavity. Because gastric carcinoids are slowly progressive tumors, they change shape slowly over time from a semi-pedunculated to a peduncu-

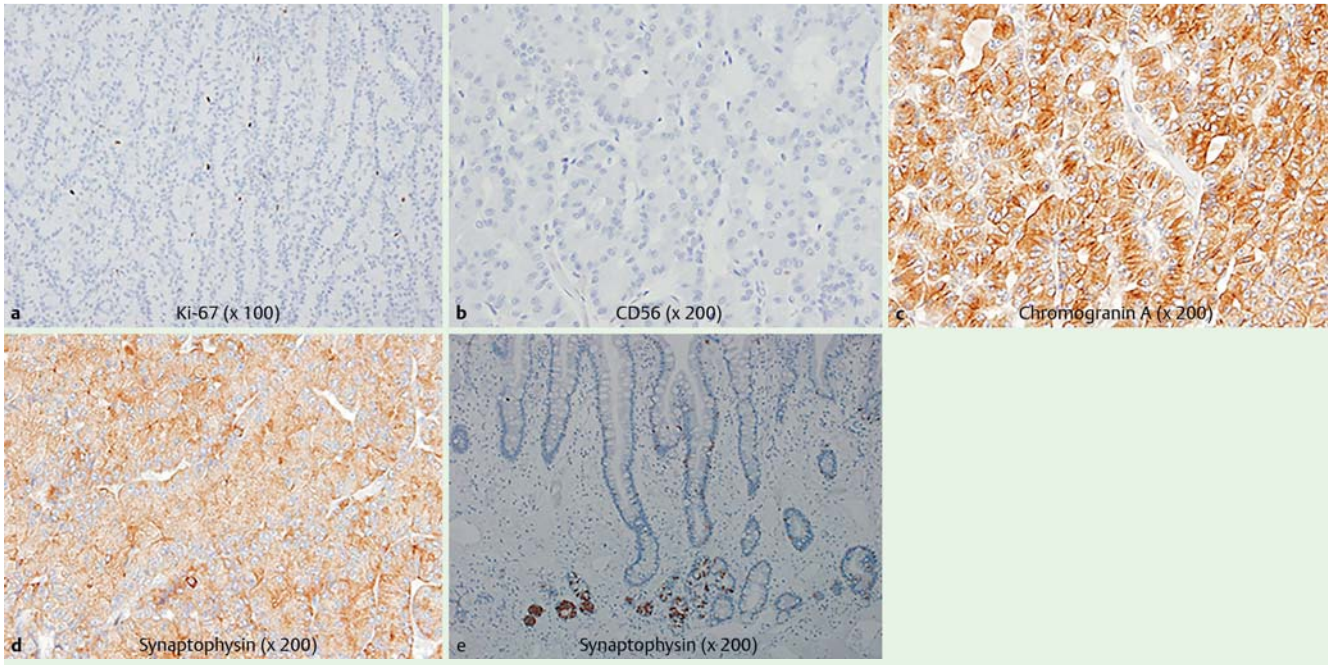

Fig. 4 Histologic immunostaining images. **a** Immunohistochemistry for Ki-67 showed a Ki-67 index of less than 2%. **b** Immunohistochemistry for CD56 was negative. **c** Immunohistochemistry for chromogranin A was positive. **d** Immunohistochemistry for synaptophysin was positive. **e** Immunohistochemistry for synaptophysin showed endocrine cell micronests in the mucosa surrounding the carcinoid tumor.

lated polyp. In the current case, because the patient had never had an endoscopic examination, the gastric carcinoid grew slowly and gradually formed into a pedunculated polyp. Furthermore, the tumor mass was located in the stalk, which was recognizable as a bulging area of the tumor stalk (**Fig. 1**, **Fig. 2**), and served as a prop by forming a solid part of the stalk.

Because our institute (Kakunodate Municipal Hospital) did not have an ultrasonographic endoscope, we were not able to perform endoscopic ultrasonography (EUS) of the lesion, which might have provided more detailed information regarding the submucosal layer. In cases of pedunculated gastric lesion where the lesion originates from the submucosal layer or the lesion may potentially have invaded the submucosal layer, EUS provides valuable information that helps in selecting the treatment strategy.

Competing interests: None

Acknowledgements

The authors wish to thank Yasuhumi Omori, MD, PhD, and Aki Nishijima-Matsunobu, MD, PhD, from Akita University Graduate School of Medicine, Department of Molecular and Tumor Pathology, for evaluating the histopathologic findings of our case.

References

1 *Nikou GC, Angelopoulos TP.* Current concepts on gastric carcinoid tumors. Gastroenterol Res Pract. Epub 2012 Dec 17
2 *Rindi G, Arnold R, Bosman FT* et al. Nomenclature and classification of neuroendocrine neoplasms of the digestive system. In: Bosman FT, Carneiro F, Hruban R et al., eds. WHO classification of tumours of the digestive system. Lyon: International Agency for Research on cancer (IARC); 2010
3 *Tsushimi T, Mori H, Harada T* et al. Laparoscopic and endoscopic cooperative surgery for duodenal neuroendocrine tumor (NET) G1: report of a case. Int. J. Surg Case Rep 2014; 5: 1021–1024
4 *Ramage J, Davies A, Ardill J* et al. Guidelines for the management of gastroenteropancreatic neuroendocrine (including carcinoid) tumours. Gut 2005; 54 (Suppl. 04): iv1–16. DOI: 10.1136/gut.2004.053314
5 *Hirai M, Matsumoto K, Ueyama H* et al. A case of neuroendocrine tumor G1 with unique histopathological growth progress. World J Gastrointest Endosc 2013; 5: 605–609
6 *Ichikawa J, Tanabe S, Koizumi W* et al. Endoscopic mucosal resection in the management of gastric carcinoid tumors. Endoscopy 2003; 35: 203–206
7 *Sato Y.* Clinical features and management of type 1 gastric carcinoids. Clin J Gastroenterol 2014; 7: 381–386
8 *Delle Fave G, Kwekkeboom DJ, Van Cutsem E* et al. ENETS Consensus guidelines for the management of patients with gastroduodenal neoplasms. Neuroendocrinology 2012; 95: 74–87
9 *Fisher JK.* Multiple sessile and pedunculated gastric carcinoids. Mo Med 1984; 81: 81–85
10 *Bhatnagar S, Borg-Grech A.* Gastric polyposis caused by multiple carcinoids and early carcinoma. J Clin Pathol 1995; 48: 589–591