Neuroendocrine tumor of the pancreas with cystic appearance mimicking a progressive intraductal papillary mucinous neoplasm: pitfall in medical imaging

Pancreatic cystic lesions are increasingly being recognized on imaging studies. Among these, intraductal papillary mucinous neoplasms (IPMNs) frequently exhibit a spectrum of neoplastic transformation and follow-up is recommended according to the Sendai [1] and Fukuoka criteria [2], with the preference being for magnetic resonance imaging (MRI) [3]. Endoscopic ultrasound (EUS) can help to verify the absence of thickened walls or mural nodules [2].

We report on a 75-year-old woman who was referred to our emergency department with nausea and chest pain. Her physical examination was unremarkable and her laboratory parameters were within the reference ranges, except for a slightly elevated lipase. Computed tomography (CT) of the abdomen revealed a cystic lesion between the body and tail of the pancreas (**Fig. 1**). On EUS, a connection between the cystic lesion and the main pancreatic duct (MPD) was seen (**Fig. 2**) and therefore a branch duct IPMN was diagnosed. MRI showed a 1.8 × 1.5-cm cyst with a connection to the MPD (**Fig. 3** and **Fig. 4**).

After 2 months the patient was re-examined with a contrast-enhanced EUS. The cyst showed an increased size with a persistent contrast-enhancing thickened wall (**Fig. 5**; **Video 1**). Because of these "worrisome features" of the lesion and its rapid growth (now 24 mm) a 19-gauge needle biopsy was performed. The fluid showed a carcinoembryonic antigen (CEA) level of 212.3 U/mL and a positive string sign [4], suggestive of mucinous cyst content [5]. A lipase value of 114812 U/mL proved that there was involvement of the pancreatic duct.

Histology unexpectedly revealed cells of a well-differentiated neuroendocrine tumor (**Fig. 6**) with no evidence of a mucinous epithelium. Immunohistochemistry showed positivity for synaptophysin and somatostatin receptor. The patient was referred for a surgical resection.

This case adds to concerns about the current management of pancreatic cystic lesions and shows that every neoplasm of the pancreas that involves the pancreatic duct can mimic IPMN. In pancreatic cysts with worrisome features, a thorough investigation should be undertaken.

Endoscopy_UCTN_Code_CCL_1AZ_2AB

Competing interests: None

Fig. 1 Computed tomography (CT) scan in arterial phase showing a cystic lesion between the body and tail of the pancreas (red arrow).

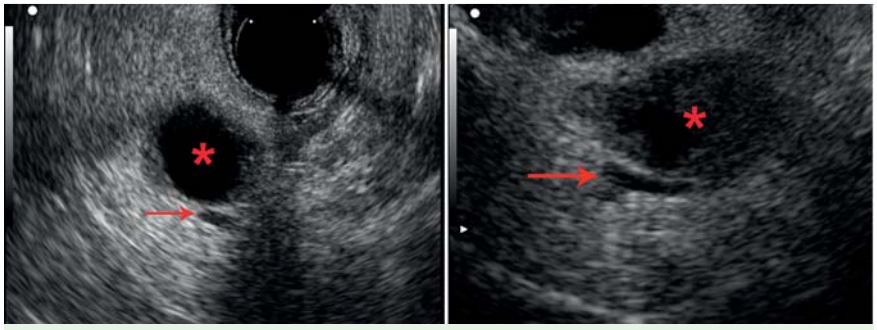

Fig. 2 Endoscopic ultrasound (radial scanner) images of a pancreatic cyst (*) of 19 mm in size with thickened walls that was in connection with the pancreatic duct (thin arrow).

Fig. 3 Magnetic resonance imaging (MRI) scan (T1-weighted, fast low-angle shot images with contrast medium) showing the communication of the cyst with the main pancreatic duct, and an enhancing thickened nodule (arrow).

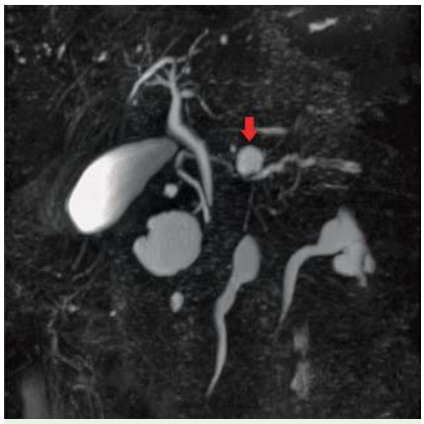

Fig. 4 Magnetic resonance cholangiopancreatography (MRCP) showing the typical appearance of an intraductal papillary mucinous neoplasm (IPMN) of branch duct type.

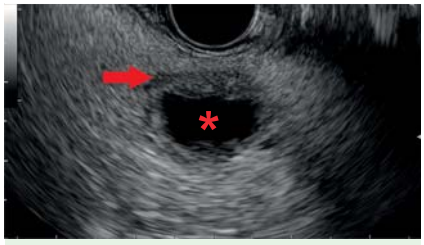

Fig. 5 Endoscopic ultrasound (EUS) image (Hitachi Aloka Medical ProSound F75) after 2 months showing that the cyst (*) has increased in size and now has a maximum diameter of 24 mm with a thickened edge (arrow).

This document was downloaded for personal use only. Unauthorized distribution is strictly prohibited.

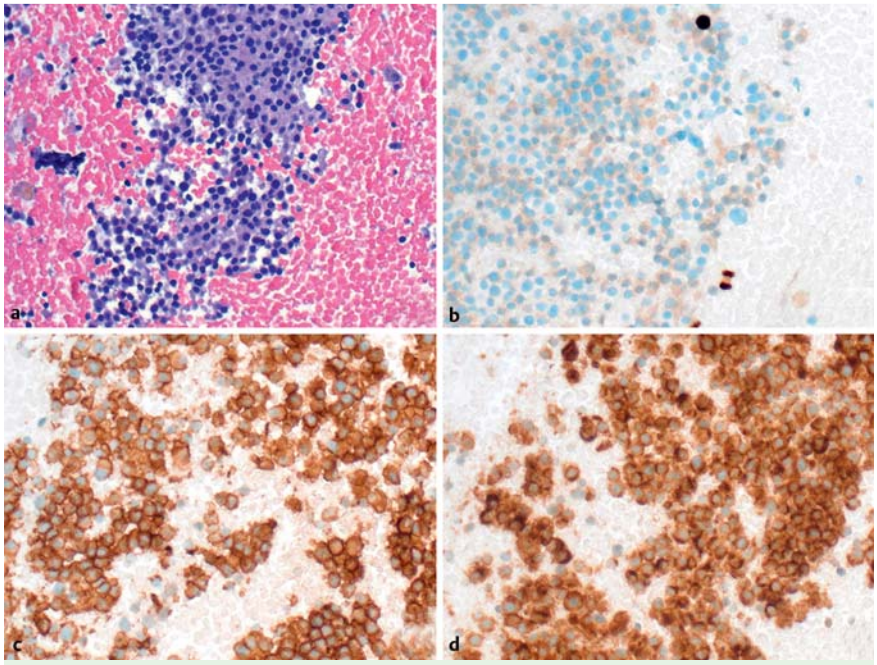

Fig. 6 Histology of the 19-gauge biopsy (magnification × 40 in all images) showing monomorphic, plasmacytoid-like small cells consistent with a neuroendocrine tumor (NET) and pancreatic exocrine tissue in the background stained: **a** with hematoxylin and eosin (H&E); **b – d** immunohistochemically demonstrating: **b** low mitogenic activity with the Ki-67 index being < 5 % (MIB1 antibody); **c** positivity for somatostatin receptor 2; **d** positivity for synaptophysin.

Video 1

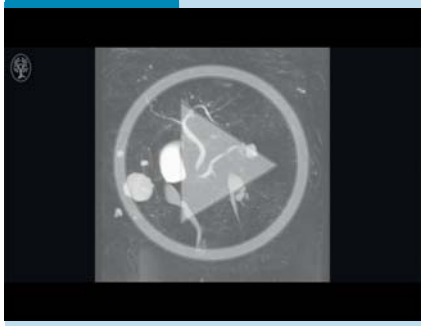

Magnetic resonance imaging (MRI) showing a pancreatic cyst with connection to the main pancreatic duct and thickened walls; magnetic resonance cholangiopancreatography (MRCP) suggesting a branch duct intraductal papillary mucinous neoplasm (BD-IPMN); contrast-enhanced transabdominal and endoscopic ultrasound (EUS) using 4.8 mL SonoVue (equates to Lumason) showing the hyperenhanced thickened wall and a fine needle biopsy of the lesion being taken.

Francesco Vitali[1], Deike Strobel[1], Lukas Pfeifer[1], Marc Heinrich[2], David Wachter[3], Markus F. Neurath[1], Dane Wildner[1]

[1] Department of Medicine 1, Friedrich-Alexander University Erlangen-Nürnberg, Germany
[2] Institute of Radiology, Friedrich-Alexander University Erlangen-Nürnberg, Germany
[3] Institute of Pathology, Friedrich-Alexander University Erlangen-Nürnberg, Germany

References

1 *Tanaka M, Chari S, Adsay V* et al. International consensus guidelines for management of intraductal papillary mucinous neoplasms and mucinous cystic neoplasms of the pancreas. Pancreatology 2006; 6: 17 – 32
2 *Tanaka M, Fernandez-del Castillo C, Adsay V* et al. International consensus guidelines 2012 for the management of IPMN and MCN of the pancreas. Pancreatology 2012; 12: 183 – 197
3 *Berland LL, Silverman SG, Gore RM* et al. Managing incidental findings on abdominal CT: white paper of the ACR incidental findings committee. J Am Coll Radiol 2010; 7: 754 – 773
4 *Leung KK, Ross WA, Evans D* et al. Pancreatic cystic neoplasm: the role of cyst morphology, cyst fluid analysis, and expectant management. Ann Surg Oncol 2009; 16: 2818 – 2824
5 *Maker AV, Carrara S, Jamieson NB* et al. Cyst fluid biomarkers for intraductal papillary mucinous neoplasms of the pancreas: a critical review from the international expert meeting on pancreatic branch-duct-intraductal papillary mucinous neoplasms. J Am Coll Surg 2015; 220: 243 – 253

Bibliography

DOI http://dx.doi.org/10.1055/s-0042-116820
Endoscopy 2016; 48: E302–E303
© Georg Thieme Verlag KG
Stuttgart · New York
ISSN 0013-726X

Corresponding author

Dane Wildner, MD
Department of Medicine 1
Friedrich-Alexander-Universität
Erlangen-Nürnberg
Ulmenweg 18
91054 Erlangen
Germany
Fax: +49-9131-8535252
dane.wildner@uk-erlangen.de

This document was downloaded for personal use only. Unauthorized distribution is strictly prohibited.