

Application of a diathermic dilator for negotiating near-total antropyloric strictures

Three patients with caustic substance-induced near-total antropyloric obstruction with recurrent vomiting were found to have a totally blocked antropyloric region with no flow of contrast distally (● Fig. 1). Patient characteristics, the treatment provided, and the outcome are summarized in ● Table 1.

After the patient had given informed consent, esophagogastroscopy was carried out with the patient under conscious sedation. The site of narrowing was identified as a dimple or depression. Attempts were made to pass a 6–8-mm wire-guided, through-the-scope balloon dilator (CRE; Boston Scientific Corp., Natick, Massachusetts, USA) into the duodenum. When this failed, it was followed by passing a hydrophilic 0.025-inch guidewire (Visiglide; Terumo Corp., Shibuya-ku, Tokyo, Japan) under fluoroscopy. A 6-Fr wire-guided coaxial diathermic dilator (Cysto-Gastro-Set; Endo-Flex GmbH, Voerde, Germany) was threaded over the guidewire under

fluoroscopic guidance to the level of the stricture. It was used to traverse the cicatrized segment step by step by applying an intermittent diathermy current (cut mode, 40W, ERBE electrosurgical unit (ERBE USA Inc., Marietta, Georgia, USA) until the dilator passed through the entire length of the stricture (● Video 1). Subsequent dilations were carried out in an incremental manner, ranging from 6 mm to 15 mm, with wire-guided through-the-scope balloon dilators twice weekly as described previously, with a close watch for complications [1]. The patients were followed up periodically for 12 months and then imaging was repeated (● Fig. 1). Ingestion of caustic substances leads to gastric cicatrization and gastric outlet obstruction in 36%–44% of patients [2–4]. All three patients in this report had near-total antropyloric obstruction that was negotiated using a coaxial diathermy dilator followed by balloon dilation. To the best of our knowledge, this is the first re-

port to describe the use of this technique in patients with caustic-induced gastric outlet obstruction. A review of the literature found that a similar diathermy catheter has been used to dilate tight bile duct and pancreatic duct strictures [5].

In conclusion, our case series describes for the first time the application of a coaxial diathermy dilator for the management of near-total gastric outlet obstruction.

Endoscopy_UCTN_Code_TTT_1AO_2AH

Competing interests: None

Pradeep Siddappa¹, Yalaka Rami Reddy¹, Pankaj Gupta², Ajay Gulati², Vikas Gupta³, Saroj Kant Sinha¹, Rakesh Kochhar¹

¹ Department of Gastroenterology, Postgraduate Institute of Medical Education and Research, Chandigarh, India

² Department of Radiodiagnosis, Postgraduate Institute of Medical Education and Research, Chandigarh, India

³ Department of Surgical Gastroenterology, Postgraduate Institute of Medical Education and Research, Chandigarh, India

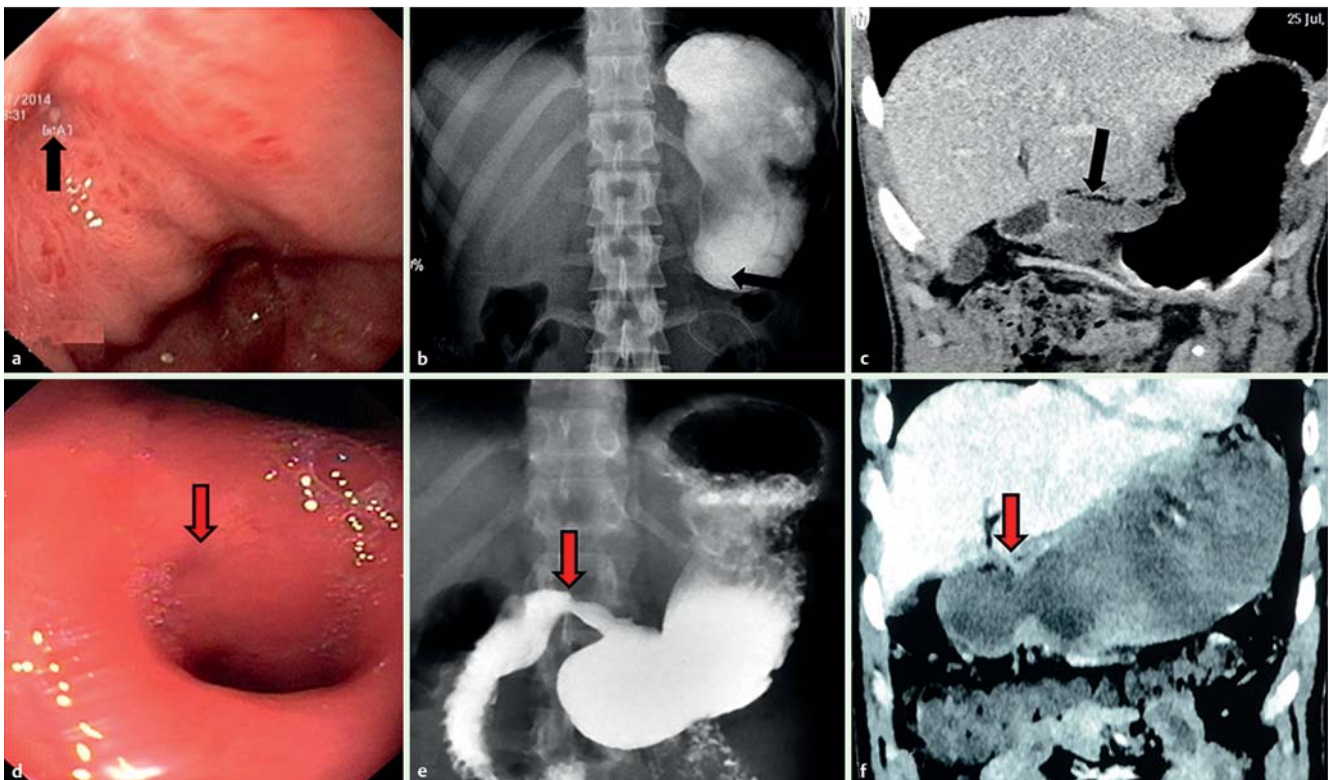


Fig. 1 a–c Complete gastric outlet obstruction (black arrow) visualized by: a endoscopy; b barium study; and c computed tomography (CT). d–e The opened up pyloric orifice following dilation (red arrow) visualized by: d endoscopy; e barium study; and f CT.

Table 1 Caustic substance-induced near-total antropyloric obstruction treated with diathermic dilation: demographic details, characteristics, endoscopic findings, and outcomes of three patients.

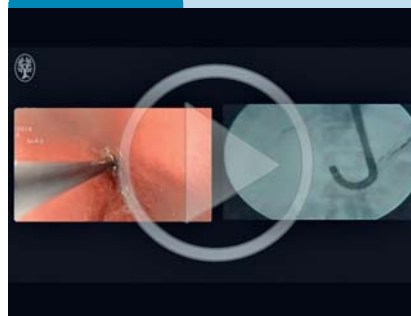
| | Patient 1 | Patient 2 | Patient 3 |
|--|--|---|---|
| Age, years | 21 | 28 | 18 |
| Sex | Male | Male | Female |
| Caustic substance | Sulphuric acid | Sulphuric acid | Nitric acid |
| Interval to presentation after acid ingestion, weeks | 14 | 10 | 4 |
| Symptoms | Vomiting, weight loss | Dysphagia, vomiting, weight loss | Vomiting, weight loss |
| Site of involvement | Antropyloric region | Antropyloric region | Antropyloric region |
| Associated ulceration at first dilation | Absent | Healing ulcer | Healing ulcer |
| Associated esophageal stricture | No | Yes | No |
| CECT abdomen | | | |
| Stricture length, mm | 30 | 16 | 17 |
| Wall thickness, mm | 10 | 9 | 8 |
| First dilation | 4 mm (Hurricane balloon; Boston Scientific Corp., Marlborough, Massachusetts, USA) | 4 mm (Hurricane balloon; Boston Scientific Corp., Marlborough, Massachusetts USA) | 6 mm (CRE balloon; Boston Scientific Corp., Marlborough, Massachusetts USA) |
| Dilations to reach 15 mm, n | 9 | 5 | 10 |
| Intralesional steroid injections, n | 8 | 4 | 10 |
| Follow-up, months | 12 | 11 | 10 |
| Outcome | Successful | Successful | Successful |
| Complications | None | None | None |

CECT, contrast-enhanced computed tomography.

References

- 1 Kochhar R, Poornachandra KS, Dutta U et al. Early endoscopic balloon dilation in caustic-induced gastric injury. *Gastrointest Endosc* 2010; 71: 737–744
- 2 Zargar SA, Kochhar R, Nagi B et al. Ingestion of corrosive acids. Spectrum of injury to upper gastrointestinal tract and natural history. *Gastroenterology* 1989; 97: 702–707
- 3 Zargar SA, Kochhar R, Nagi B et al. Ingestion of strong corrosive alkalis: spectrum of injury to upper gastrointestinal tract and natural history. *Am J Gastroenterol* 1992; 87: 337–341
- 4 Chaudhary A, Puri AS, Dhar P et al. Elective surgery for corrosive-induced gastric injury. *World J Surg* 1996; 20: 703–706
- 5 Kawakami H, Kuwatani M, Kawakubo K et al. Transpapillary dilation of refractory severe biliary stricture or main pancreatic duct by using a wire-guided diathermic dilator. *Gastrointest Endosc* 2014; 79: 338–343

Video 1



Diathermic dilation of near-total antropyloric stricture. Endoscopic view of the procedure (left) and the corresponding fluoroscopic image (right). After placement of the guidewire across the stricture site deep into the duodenum, the diathermic dilator was negotiated over the guidewire through the entire length of the stricture. This was followed by balloon dilation of the tract.

Bibliography

DOI <http://dx.doi.org/10.1055/s-0042-118453>
Endoscopy 2016; 48: E365–E366
 © Georg Thieme Verlag KG
 Stuttgart · New York
 ISSN 0013-726X

Corresponding author

Rakesh Kochhar, MD
 Department of Gastroenterology
 Postgraduate Institute of Medical Education
 and Research (PGIMER)
 Chandigarh 160012
 India
 Fax: +91-172-2744401
 dr_kochhar@hotmail.com